

Recording the Frankfort-Mandibular-Plane Angle Using Oriented Mandibular Radiogram and Sectioned Oriented Cast

BERCU FISCHER, D.D.S.
New York, New York

INTRODUCTION

IN THE ANGLE ORTHODONTIST of January and April, 1943, a method was given for measuring the changes in position and axial inclination of the maxillary and the mandibular incisors before and after treatment.

The changes in a labio-lingual and a vertical direction were measured from two reference planes perpendicular to each other, the Frankfort plane and the pre-auricular plane.

While the Frankfort and pre-auricular planes on the sectioned cast and graphs made from it, enable us to measure all the changes in the maxillary incisors, there is an additional factor that must be considered when measuring the changes in the mandibular incisors. This factor is the postural relationship of the mandible to the rest of the cranium. The inclination of the mandible as related to the cranium, affects the steepness of the occlusal plane and the procumbency of the lower incisors as measured from the Frankfort plane. Therefore, in accounting for the changes in the axial inclination of the mandibular incisors, it becomes necessary to know to what extent the position of the mandible itself is responsible for the change.

To measure the relationship between the mandible and the rest of the head we can use one of two angles: (1) The Frankfort-mandibular-plane angle, that is the angle formed by the lower border of the mandible and the Frankfort plane when the maxillary and the mandibular teeth are in occlusal contact, or (2) The preauricular-mandibular-plane angle, that is the angle formed by the lower border of the mandible and the preauricular plane when the maxillary and the mandibular teeth are in occlusal contact. Being that I use the Frankfort plane to measure the axial inclination of the incisors, I prefer the Frankfort-mandibular plane angle. The method of recording and measuring this angle will now be described.

METHOD

In a general way the method consists of taking oriented sagittal radiograms of the mandible in order to obtain the mandibular plane and then transferring this plane to the graph obtained from the sectioned oriented cast.

After the preparation of the sectioned oriented cast with its incisor-axial-angle (Fig. 1,A), a metal wire about 025 gauge is placed to coincide with the incisor-axial-line on the sectioned cast and extending about an inch above the biting surfaces of the teeth (Fig. 1,B). A modeling compound

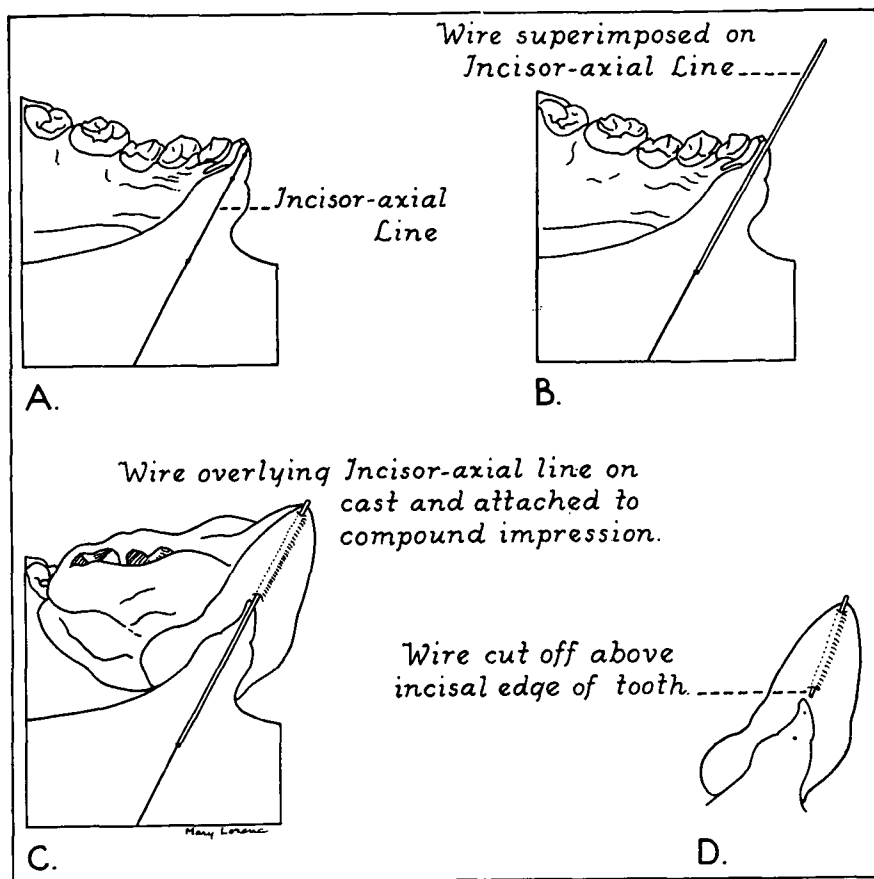


Fig. 1.—Steps in the preparation of the wire for radiographic technique. A. Incisor-axial-line on sectioned cast. B. Wire super-imposed on incisor-axial-line. C. Wire overlying incisor-axial-line on cast and attached to compound impression. D. Section of wire imbedded in impression ready for insertion in the mouth.

impression is taken in the mouth on the left side corresponding to the sectioned oriented cast. This impression extends from the first molar posteriorly to the left lateral incisor anteriorly. Enough compound is added to the occlusal surface to separate the jaws for at least an inch. After chilling the impression and trimming away undercuts, it is transferred and seated on the sectioned oriented cast. With the impression thus seated on the cast, the wire is held in proper position on the incisor-axial-line and the portion of the wire extending beyond the teeth occlusally is attached by means of sticky wax to the mesial side of the compound of the impression (Fig. 1,C). Care must be taken that the wire is not moved out of position in this process. After chilling, the impression and wire are removed from the sectioned cast and the wire is cut above the incisal edge of the mandibular left central incisor tooth thus leaving a segment of the wire imbedded in the impression

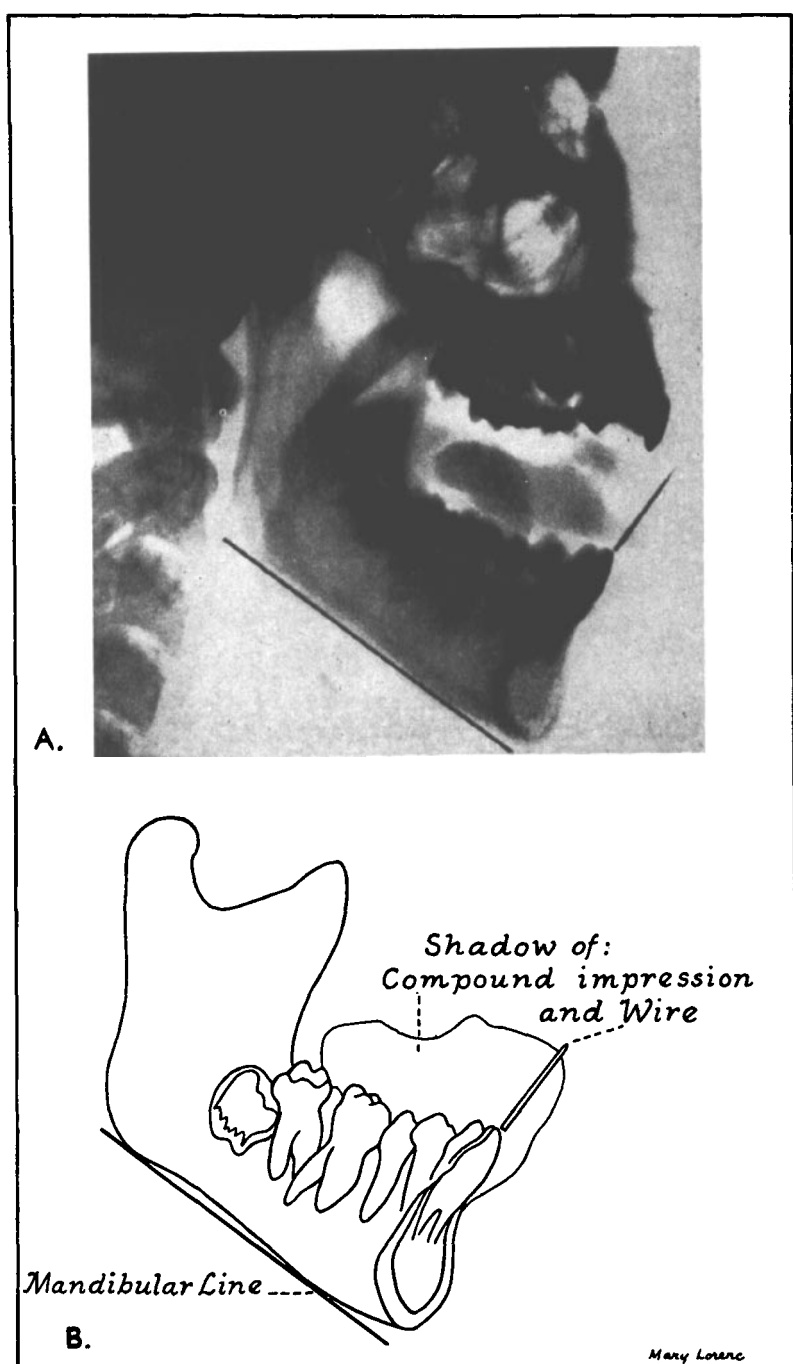


Fig. 2.—A. Radiogram of mandible showing incisal wire and mandibular line. B. Tracing of mandibular radiogram.

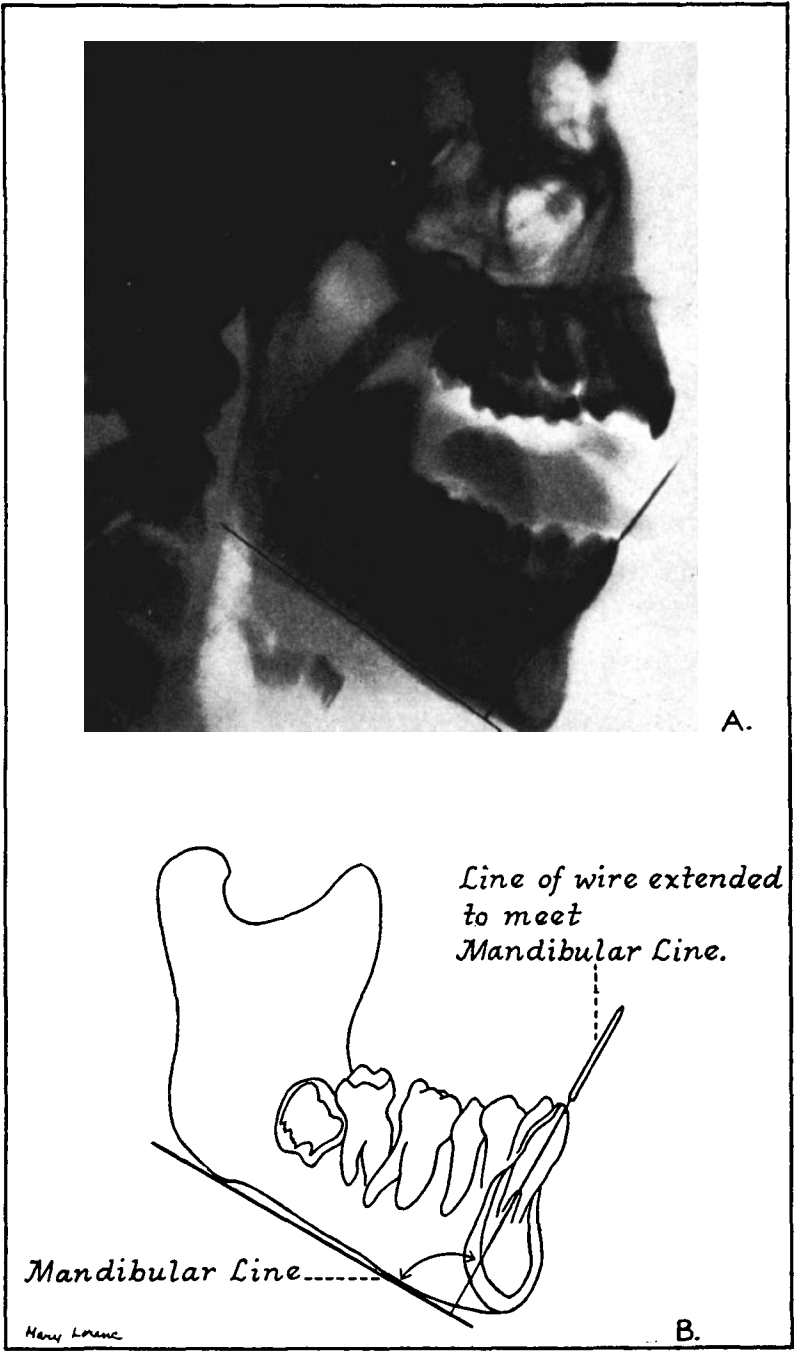


Fig. 3.—A. Incisor line extended from wire to intersect mandibular line on the radiogram forming the incisor-mandibular plane angle. B. Tracing of radiogram.

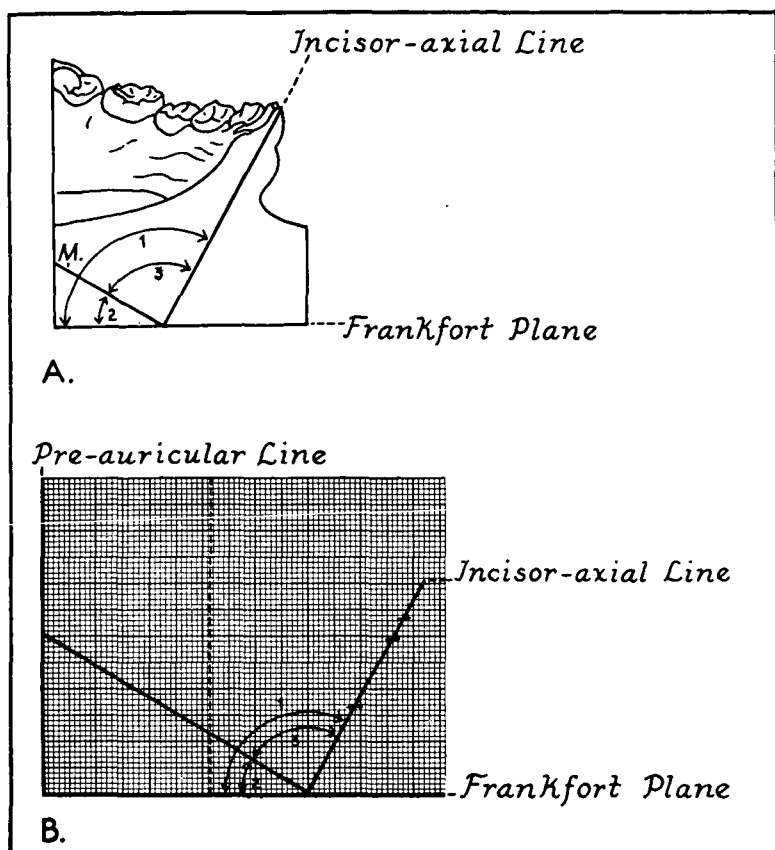


Fig. 4.—Steps in making graph from sectioned cast. A. Sectioned cast showing (1) the incisor-axial angle, (2) the Frankfort-mandibular plane angle and (3) the incisor-mandibular plane angle. (M) Mandibular plane. B. Graph made from sectioned cast showing the three angles and the various planes.

(Fig. 1,D). The patient is placed in the head-positioner for the sagittal radiogram. The compound impression with the wire is now reseated in the mouth and the radiogram is taken.* When the radiogram is developed it will have on it the picture of the wire representing the incisor-axial-line (Fig. 2,A). (Note: As we are interested in getting a true sagittal radiogram of the mandible only, it does not matter that the teeth are not in occlusion.) The mandibular line is drawn on the radiogram (Fig. 2,A) and by extending the line of the wire until it intersects this line we obtain the incisor-mandibular plane angle (Fig. 3). (Margolis).† By means of a protractor this angle is transferred to the graph obtained from the sectioned oriented cast by superimposing the incisor-axial-lines and the vertexes.

* Grateful acknowledgment is here made to Dr. Edward Klein for his help and suggestions in the radiographic technique.

† Margolis defines the incisor-mandibular plane angle as "the angle formed by the long axis of the mandibular central incisor and the mandibular plane."

The complete graph is shown in Fig. 4, B. On this graph we have four angles: the incisor-axial angle, the incisor-mandibular-plane angle, the Frankfort-mandibular-plane angle and the preauricular-mandibular-plane angle.

DISCUSSION

The sectioned oriented cast makes possible the recording of the various changes produced in the position and axial inclination of the maxillary and mandibular incisors. Labio-lingual and vertical changes in the position of the incisors are measured from the preauricular and Frankfort planes. From the preauricular plane the following changes are measured: (1) Tipping of the crowns of the incisors labially or lingually with the roots relatively unchanged. (2) Tipping of the incisor roots labially or lingually with the crowns relatively unchanged. (3) Tipping of the crowns in one direction and the roots in an opposite direction. (4) Bodily movement of the teeth labially or lingually.

Changes in the axial inclination of the maxillary and mandibular incisors are measured by means of the maxillary and mandibular incisor-axial-angles. Since changes in the mandibular-incisor-axial angle may be due to (1) a change in relationship between the incisors and the lower border of the mandible, (2) a change in the relationship of the lower border of the mandible to the Frankfort plane or (3) both, two additional angles must be measured. These are the incisor-mandibular plane angle and the Frankfort-mandibular-plane angle. The employment of these angles and angular relations enables us to locate the site of the change.

The radiographic technique employed here has the following advantages: (1) The wire identifies the incisor tooth whose axial angle we wish to record. (2) It shows the relationship of the particular root to the surrounding bone. The divergence of the root from the wire is into the bone rather than away from it (Fig. 5). Normally, the incisor root diverges from the crown in a lingual direction, forming the crown root angle. (3) The operation can be repeated with each incisor tooth and the average axial angle obtained. This is especially important where the incisors are irregular and the angulation of one tooth does not give a true indication of the condition.

SUMMARY

In this presentation a method has been described for the recording of the Frankfort-mandibular-plane angle. This angle together with the incisor-axial angle and the incisor-mandibular plane angle as shown on the graph of the sectioned cast make possible the recording of changes in axial inclination of the incisor teeth. The radiographic technique described in the text

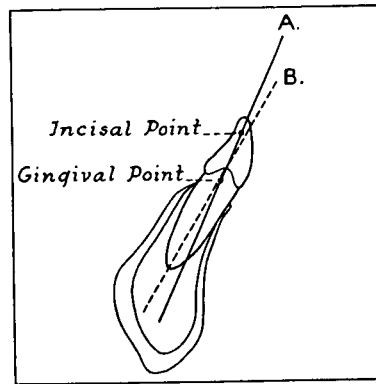


Fig. 5.—The crown-root angle of the lower incisor. A. Crown axis. B. Root axis. The divergence of the root is towards the lingual.

identifies the tooth whose axial position we wish to record and also shows the relationship of the root of the tooth to the surrounding bone. The present article together with the one published in *THE ANGLE ORTHODONTIST* of January and April, 1943, give a complete method for the recording of tooth movement produced by orthodontic treatment or through growth and development.

Among the various factors responsible for facial typical form, the postural inclination of the mandible as related to the cranium and the procumbency of the incisors seem to play an important part. The accumulation of data obtained with the oriented sectioned cast and graphs should enable us to discover (1) the relative contribution of these factors to the typical pattern of the face and (2) the influence of orthodontic treatment upon these factors. The work also points the way to further investigation into the values of these factors in the diagnosis and classification of oral deformities.

2 East 54th Street

BIBLIOGRAPHY

- BRODIE, ALAN G.: "On the Growth Pattern of the Human Head from the Third Month to the Eighth Year of Life," *The American Journal of Anatomy*, 68(2):209-262.
- FISCHER, BERCU: "The Denti-phore," *American Journal of Orthodontics and Oral Surgery*, 26(10):941-954, Oct., 1940.
- KALETSKY, THEODORE: "A Simple Way to Produce Consistently Accurate Intraoral Roentgenograms and a Modification of the Technic of Dental Roentgenography," *The Journal of the American Dental Association*, XXVI:390-398, March, 1939.
- MARGOLIS, HERBERT I.: "The Axial Inclination of the Mandibular Incisors," *The American Journal of Orthodontics and Oral Surgery*, 28(10), Oct., 1943.
- MARTIN, R.: *Lehrbuch der Anthropologie*, G. Fischer, Jena, 1928.
- MCLEARN, IDA, MORANT, G. M. and PEARSON, KARL: "On the Importance of the Type Silhouette for Racial Characterisation in Anthropology," *Biometrika*, XXb, Parts III and IV.
- NOYES, HAROLD J., RUSHING, CHARLES H. and SIMS, HUGH A.: "The Angle of Axial Inclination of Human Central Incisor Teeth," *ANGLE ORTHODONTIST*, 12(3 and 4), July and Oct., 1943.
- SPEIDEL, THOMAS D. and STONER, MORRIS: "Variation of Mandibular Incisor Axis in Adult Normal Occlusion," *American Journal of Orthodontics and Oral Surgery*, 30(10), Oct., 1944.
- TWEED, CHARLES H.: "The Application of the Principles of the Edgewise Arch in the Treatment of Malocclusions," *ANGLE ORTHODONTIST*, 11(1), 1941.