

## EIGHTEEN YEARS OF RESEARCH AT ILLINOIS (Cont.)

This study focused attention on a matter that had been ignored by the proponents of extraction, viz, the overbite. A deep overbite had long been held to have a deleterious effect on the denture. Here was shown the fact that, without exception, no correction took place in the overbite and in 62 percent the overbite was increased.

The student who was assigned the task of studying the behavior of teeth in cases treated without extraction wrote his thesis under the title:

### A Study of the Movements of Certain Teeth During and Following Orthodontic Treatment<sup>1</sup>

ROBERT LITOWITZ, D.D.S., M.S.

Miami Beach, Fla.

The introduction of roentgenographic cephalometry by Broadbent in 1931<sup>1</sup> resulted in many scientific contributions which have led to a better understanding of the problems of orthodontia. Investigations employing this technique have included serial studies of growing children, analyses of tooth and jaw relationships in the various classes of malocclusion, and studies on the results of orthodontic treatment.

Only a roentgenographic technique which allows precise orientation of the head to the apparatus permits a complete study of the quantitative changes incident to orthodontic treatment. The first attempt to employ this technique in an appraisal of orthodontic results was that made by Brodie, Downs, Goldstein, and Myer.<sup>5</sup> In that study, complete tracings were made of all headplates of every case and the sample included cases of each of the three classes of malocclusion. Superpositioning of serial tracings was made on Point R (registration point) with the Bolton planes kept parallel. Some of the conclusions drawn from that work were:

1. "The use of intermaxillary elastics changes the occlusal plane.
2. "Subsequent to treatment the occlusal plane tends to return to its original position.
3. "The disturbances in the angulation of individual teeth show a tendency toward recovery following active treatment. This is particularly true where growth is active.

---

<sup>1</sup>Submitted in partial fulfillment of the requirements for the degree of Master of Science, University of Illinois, 1947.

4. "Changes subsequent to treatment are limited to shiftings in the occlusal plane and to changes in axial positions of teeth in adult cases. In growing children there are, in addition, the typical changes that are expected in growth.
5. "Tooth movement does not seem to be as great as clinical observation has led us to believe. Apparently, growth and development account for a considerable part of the changes which take place during orthodontic treatment."

Downs,<sup>6</sup> analyzing tooth movement in a later paper stated:

"Our first attempts to correlate the readings showed conclusively that we could not use the methods of recordings that are accepted for growth studies, that is, the registration of pictures on the point R with the Bolton planes parallel and taking readings from R. This is because the first change in occlusal plane relationships causes a shift in the position of the mandible and significant errors appear in the readings.

Growth studies have shown that the angle formed by the lower border of the mandible and the posterior border of the ramus is very stable. It is permissible then to use these lines for mandibular registrations to determine the relative vertical and horizontal tooth position in serial tracings of individual cases."

With this method of superposition, Downs measured the movement of the mandibular incisor and the mandibular first molar, increases in arch length, and growth of the mandible. He also recorded changes of axial inclination of the mandibular incisor and first molar to the mandibular plane. The mandibular plane was determined by a line drawn from the most inferior point on the cross section of the symphysis and tangent to the lower border of the mandible posteriorly.

In 1941, Tweed<sup>17</sup> advanced a new treatment plan employing what he called "dynamic anchorage". His avowed purpose was to place the lower anterior teeth on the "ridge", that is, on the body of the bone. He claimed that for all the objectives of orthodontic treatment to be achieved, the lower incisors must stand upright, i.e., at right angles to the mandibular plane. Where this condition could not be attained with usual orthodontic methods, he advocated extraction of teeth to make it possible.

In 1940, Downs<sup>6</sup> pointed out three major problems that confront the orthodontist who attempts to gain all the objectives of treatment. These three problems are: 1) abnormal shifting of teeth causing a perverted relationship to their bases; 2) denture bases which are abnormal in their relationship to cranium and frequently to each other; 3) a combination of the above conditions. He emphasized that a practical plan of treatment should place the denture in a satisfactory relationship to its bases, to the maxilla and to the mandible.

In the last six years, numerous investigators have developed techniques with which to measure or observe the relationship of the lower incisors to the mandible. Tweed<sup>17</sup> and others have sectioned plaster casts to show variations of the axial inclination of the incisors and changes in the axial positions of these teeth due to treatment. For this purpose the base of the cast was made parallel to the occlusal plane.

Fischer used a dentiphore to register landmarks of the face and transferred the readings to a sectioned oriented cast, the base of which was parallel to the Frankfort plane. His purpose was to measure the "incisor-axial-angle", that is, the angle formed by the long axis of the central incisor with the base of the cast. Two years later, he<sup>10</sup> added sagittal roentgenograms of the mandible to his oriented cast in order to record the incisor-mandibular plane angle.

Noyes, Rushing, and Sims,<sup>13</sup> using the established cephalometric technique, studied the relationship of the long axis of the mandibular incisor to both the occlusal and mandibular planes, the relationship of maxillary incisor to the occlusal and maxillary planes (NS-PNS), and the relationship of the incisors to each other.

Margolis<sup>12</sup> related the mandibular incisor to the mandibular plane. He showed that the incisor-mandibular plane angle changed after treatment and subsequent to retention in the several cases reviewed. Tracings were superposed in one case, but the point or planes of superposition were not mentioned.

Brodie<sup>3</sup> measured the angular relationship between the mandibular incisor and the mandibular plane. This study embraced a total of 104 cases of Class I and Class II malocclusions. Class I gave a mean angle of 90.9 degrees, Class II, Division 1 a mean of 89.3 degrees, and Class II, Division 2 one of 86.6 degrees. The ranges provided some interesting information; in Class I the range was 28 degrees, in Class II, Division 1 it was 35 degrees, and in Class II, Division 2 it was 42 degrees. In discussing these figures, Brodie commented:

"These studies exemplify once more the fallacy of employing a mean as a criterion for the individual. With such a large range in this angle it would be impossible to employ it as a basis for clinical judgment. It would seem but logical to conclude that the axial inclination of the lower incisor, like any other anatomic feature, varies greatly and is probably just as much a part of the individual's pattern as are the other details of his physiognomy. That it changes very little during life is shown by Broadbent, who examined twenty-five white males at three stages between the third and eighteenth year. At three years of age the deciduous incisor stood at 92 degrees, at sixteen years its successor stood at 96 degrees, and at eighteen years it had returned to 94 degrees. This feature is undoubtedly just as dependent on such factors as ethnic origins and genetic admixtures as is any other, and to insist that all lower incisors must stand upright to be considered normal is just as untenable as to insist that all foreheads be high or all noses of the Roman variety."

Speidel and Stoner<sup>14</sup> investigated the axial inclination of the mandibular incisor to the mandibular plane by the accepted cephalometric technique on forty-two young male adults "who had definitely superior dental occlusal relationships". The average inclination was 92.64 degrees with a standard deviation of 6.15 degrees. The total range was the same as that obtained by Brodie for Class 1 malocclusion, viz., 28 degrees.

Hedges<sup>1</sup> in his study of treatment of Class II malocclusions plotted the course of movement of the maxillary molar related to the sella-nasion plane (S-N) on serial cephalometric x-rays. Movement of the mandibular molar was recorded by superposing the most anterior points of symphyses and the mandibular plane. It was shown that although the maxillary molar was tipped backward, it eventually regained its original inclination. Mandibular growth was shown to account for the major change in molar relationship induced by treatment.

Epstein<sup>8</sup> superposed serial cephalometric x-rays on the palatal planes with the anterior nasal spine registered, in order to study changes in molar relationship induced by extra-oral anchorage. He found that in some cases the maxillary molar was held stationary while the maxilla moved down-

ward and forward with growth. In others, there was distal movement of the maxillary molar.

The present investigation attempted to record movement of the mandibular incisors and the maxillary and mandibular first permanent molars during and after treatment and subsequent to the removal of all retention.

### METHOD AND MATERIAL

Twenty treated cases of malocclusion were analyzed according to the prescribed roentgenographic cephalometric technique of Brodie<sup>1</sup>, Downs<sup>7</sup>, and Broadbent<sup>2</sup>. The cases were all treated with the Edgewise Arch mechanism and were collected from the files of the Department of Graduate Orthodontia, University of Illinois. Of the fifteen cases presenting a Class I malocclusion, seven involved high maxillary cuspids bilaterally, and three involved a high maxillary cuspid on only one side. Of the five remaining Class I cases, one presented a complete lingual relationship of the mandibular denture to the maxillary denture. The remaining five cases were classified as Class II malocclusions.

Five cases presented adequate length of the mandibular arch. Fifteen cases showed an inadequate length of the mandibular arch, i.e., it was necessary to increase arch length in order to correct alignment, axial inclinations, contact points, and rotations of the teeth. In seven cases, it was necessary to increase mandibular arch length from two to five millimeters. In the remaining eight cases it was necessary to increase mandibular arch length from six to twelve millimeters.

All cases were considered clinically successful. They were treated to their normal occlusal relationships and remained stable subsequent to the removal of all retention.

Complete tracings were made from cephalometric headplates taken at the beginning of treatment, at the end of treatment, and from one to five years subsequent to the removal of all retention.

The behavior of the mandibular incisors and the maxillary and mandibular first permanent molars were investigated in the following manner (Fig. 1):

1. The mandibular plane was drawn from the most inferior point on the cross section of the symphysis and tangent to the lower border of the mandible posteriorly.
2. The palatal plane was established by connecting the anterior and posterior nasal spine (ANS-PNS).
3. A line was drawn through the midpoint of the incisal edge and the midpoint of the root apex of the lower incisor and extended to the mandibular plane.
4. A line was drawn through the buccal groove of the crown and the bifurcation of the roots of the left mandibular first permanent molar and extended to the mandibular plane.
5. A line was drawn through the buccal groove of the crown and the bifurcation of the buccal roots of the left maxillary first permanent molar and extended to the palatal plane.
6. A line was drawn halfway between the incisal tips of the upper and lower incisors and through half the cusp heights of the first permanent molars establishing the occlusal plane.

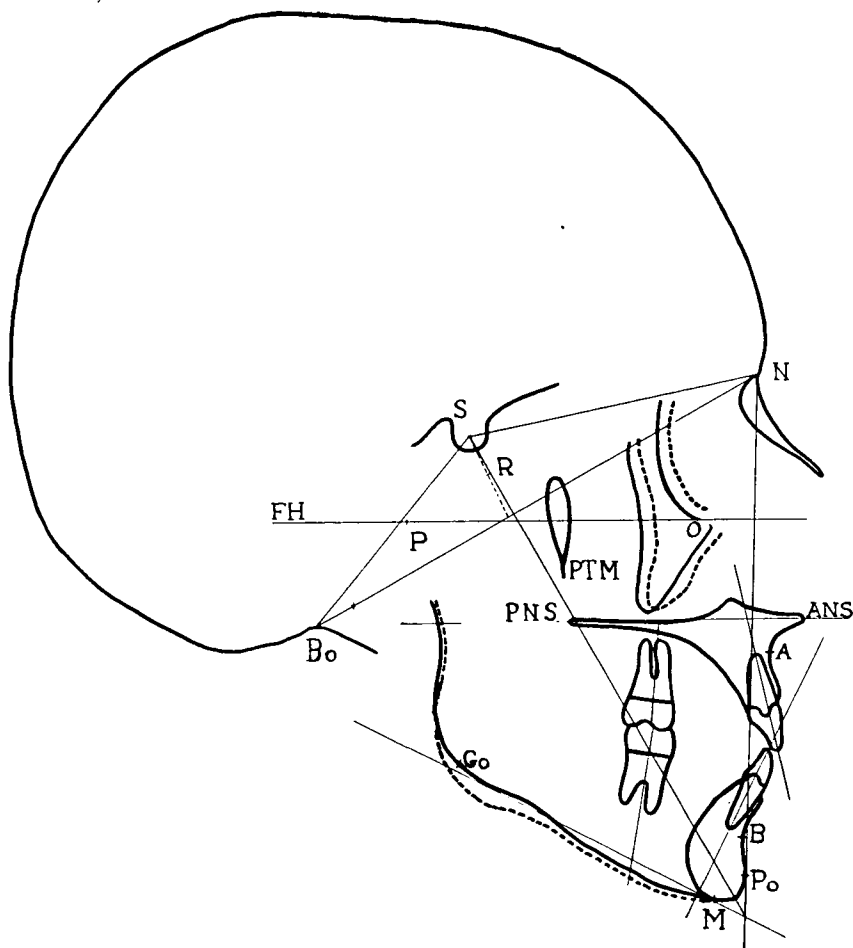


FIG. 1

## TRACING OF LATERAL HEAD ROENTGENOGRAM

S—Center of sella turcica, N—nasion, Bo—Bolton point, P—porion, O—orbital, FH—Frankfort horizontal, R—registration point, PTM—pterygomaxillary fissure, ANS—anterior nasal spine, PNS—posterior nasal spine, B—demarcates alveolar process from body of mandible, A—demarcates alveolar process from body of maxilla, Po—pogonion, Go—gonion.

In the maxilla, the palatal planes and points A (most posterior point on the midline below ANS)<sup>7</sup> of serial tracings were superposed. In the mandible, the mandibular planes and cross sections of the symphyses of serial tracings were superposed.

The following angles were read with a protractor to 0.5 degrees and tabulated:

1. Angle formed by the long axis of the mandibular left central incisor and the mandibular plane.
2. Angle formed by the long axis of the left mandibular first permanent molar and the mandibular plane.
3. Angle formed by the long axis of the maxillary first permanent molar and the palatal plane.

Linear measurements were made between original and subsequent positions of selected points by superposing the tracings of the successive x-rays. Mandibular measurements were made on a line parallel to the mandibular plan; maxillary measurements were made on a line parallel to the palatal plane.

Movement of selected points of the left mandibular central incisor were listed as labial (+) or lingual (—). Movement of selected points of the maxillary and mandibular first permanent molars were listed as forward (+) or backward (—). The distances moved by the following points during and subsequent to treatment were read to 0.5 mm. and tabulated:

1. The root apices of the left mandibular central incisor.
2. The incisal edges of the left mandibular central incisor.
3. The mesial root apices of the mandibular first permanent molar.
4. The mesial contact points of the mandibular first permanent molar crown.
5. The mesio-buccal root apices of the maxillary first permanent molar.
6. The mesial contact points of the maxillary first permanent molar crown.
7. Anteroposterior growth of the maxilla was measured by superposing the palatal planes and pterygomaxillary fissures of serial tracings and measuring between points A of successive tracings.
8. Anteroposterior growth of the mandible was measured by superposing the posterior borders and mandibular planes and measuring between points Po (Pogonion) or points B, most posterior point of the anterior surface of the symphysis (junction of the alveolar process and the body of the mandible) of successive tracings, whichever was more accurate.
9. Linear distance from the crown tips of the maxillary and mandibular left central incisors to the occlusal plane was measured on a perpendicular from the crown tips to the occlusal plane.

An additional analysis of all cases was made from models at the beginning of treatment, at the end of treatment, and subsequent to the removal of all retention. This was done in the following manner:

1. Arch length in both maxillary and mandibular models was determined by measuring the distance from the mesio-buccal angle of the first permanent molar around the arch to the mesio-buccal angle of the first permanent molar of the opposite side. This was done by means of a wire which was subsequently measured.
2. The width between the cusp tips of cuspids, first bicuspid, second bicuspid, and first permanent molars in each jaw was measured with calipers and recorded on graph paper.

## FINDINGS

1. Eight cases revealed forward (mesial) bodily movement of the left mandibular first permanent molar (Table II). Five of these continued to move mesially after retention. Six cases revealed backward (distal) bodily movement of the left mandibular first permanent molar. Four of these tended to return to their former positions, and two continued to move distally after retention.
2. Of the nine cases revealing bodily movement of the left maxillary first permanent molar in Table III, seven moved distally and two moved mesially during orthodontic treatment. In these cases, all of the crowns moved mesially after retention but the roots exhibited a variety of movement. Some moved mesially, some distally, and some remained stable.

TABLE I  
BEHAVIOR OF LEFT MANDIBULAR CENTRAL INCISOR  
20 CASES

<i>A. Analysis of Changes in Axial Inclination</i>	<i>After Treatment</i>	<i>Subsequent to Retention</i>	
No change in axial inclination	1	became more procumbent	0
Increase in axial inclination	12	tended to return	6
		continued to increase its axial inclination	6
Decrease in axial inclination	7	tended to return	2
		continued to decrease its axial inclination	5
<i>B. Analysis of Bodily Movement</i>			
Labial movement of crown and root apex	12	stable	2
		tended to return	10
Lingual movement of crown and root apex	2	root stable	1
		crown stable	1
<i>C. Analysis of Movement of Root Apex</i>			
No movement of root apex	1	moved lingually	0
Lingual movement of root apex	6	stable	2
		tended to return	1
		continued to move lingually	3
Labial movement of root apex	13	stable	3
		tended to return	10
<i>D. Analysis of Movement of Crown</i>			
No movement of crown	3	moved lingually	2
		moved labially	1
Lingual movement of crown	3	stable	1
		continued to move lingually	2
Labial movement of crown	14	stable	3
		tended to return	10
		continued to move labially	1

3. Twelve cases exhibited labial bodily movement of the lower left central incisor (Table I). Ten of the twelve tended to return to their original positions after retention.
4. Thirteen cases exhibited labial movement of the root apex of the left mandibular central incisor (Table I). Ten of these tended to return to their former positions after retention. Fourteen cases showed labial movement of the left mandibular incisor crown. Three remained stable and ten tended to return to their former inclination after retention.
5. In cases of deep overbite, it was evident that teeth can be depressed by orthodontic procedures (Figs. 2, 3, 4, and 5). However, such teeth return to, at least their original height in every case. In some, they exceed it.

TABLE II  
BEHAVIOR OF LEFT MANDIBULAR FIRST PERMANENT MOLAR  
20 CASES

<i>A. Analysis of Bodily Movement</i>	<i>After Treatment</i>	<i>Subsequent to Retention</i>	
No movement of crown and roots	0		
Mesial movement of crown and roots	8	tended to return	3
Distal movement of crown and roots	6	continued to move mesially	5
		tended to return	4
		continued to move distally	2
<i>B. Analysis of Root Movement</i>			
No movement of roots	2	stable	1
		moved mesially	1
Mesial movement of roots	11	stable	1
		tended to return	6
		continued to move mesially	4
Distal movement of roots	7	stable	2
		tended to return	4
		continued to move distally	1
<i>C. Analysis of Crown Movement</i>			
No movement of crown	3	stable	3
Mesial movement of crown	9	stable	1
		tended to return	3
		continued to move mesially	5
Distal movement of crown	8	stable	1
		tended to return	5
		continued to move distally	2

- 
6. Changes accompanying orthodontic treatment took place only in the alveolar process. The maxillary and mandibular bodies were unaffected. At the symphysis the alveolar process followed in the direction of movement of the mandibular incisors, and they moved together after retention (Figs. 2, 3, 4, and 5).
  7. Changes subsequent to retention took place in the denture area, that is, the teeth and their alveolar processes, by settling and adjustment. Growth of the maxilla and the mandible, and their alveolar processes corresponded to the growth patterns of the individual cases (Chart VIII).
  8. Twelve cases exhibited an increase of the axial inclination of the left mandibular central incisor to the mandibular plane. Of these, six cases had a tendency to return and six cases continued to move labially after retention (Figs. 2 and 3).
  9. Seven cases showed a decrease of the axial inclination of the left mandibular central incisor to the mandibular plane. Two such cases had a tendency to return after retention. Five cases continued the decrease (Figs. 4 and 5).



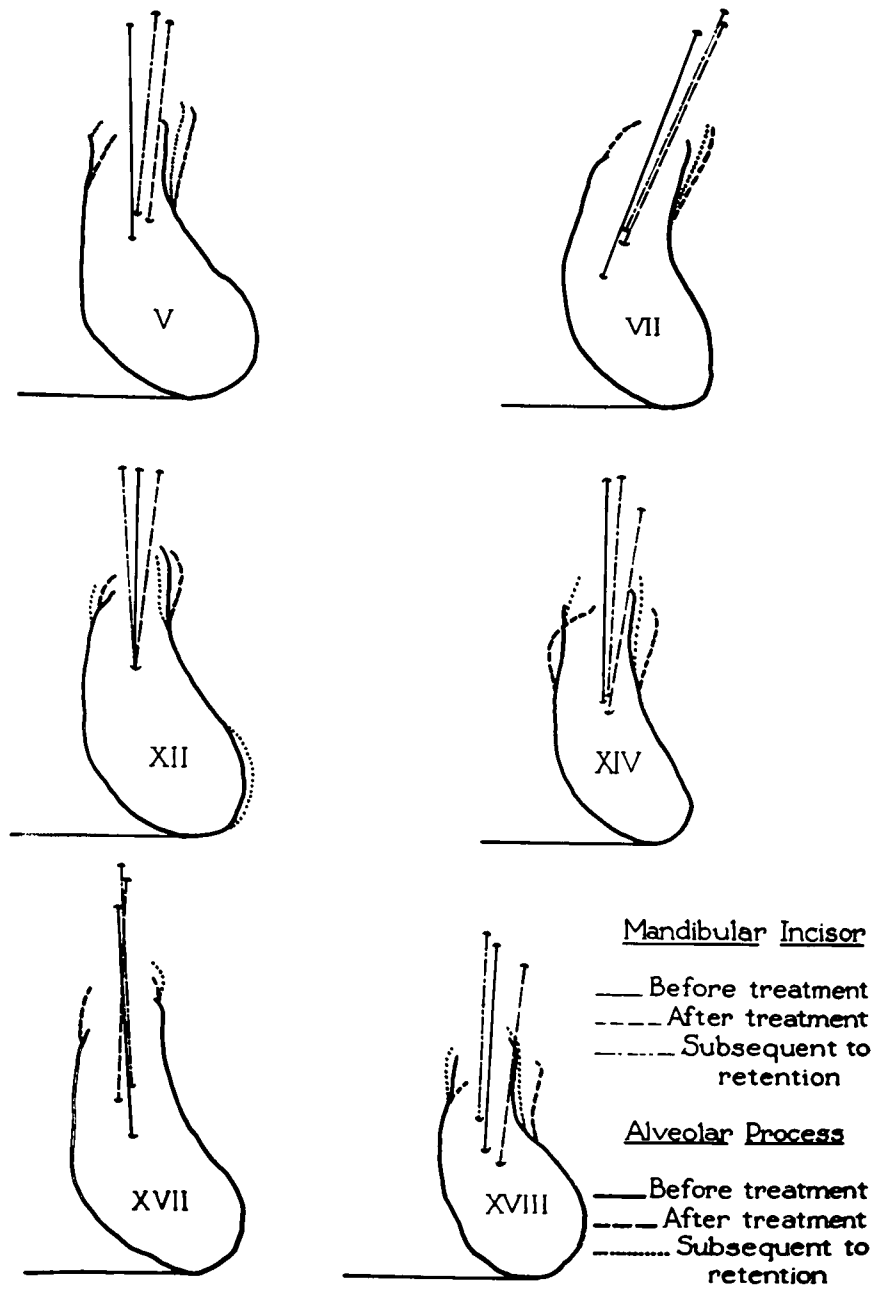


FIG. 2. Cases wherein the lower incisor tended to return subsequent to retention after an increase of the axial inclination due to treatment.

TABLE III  
BEHAVIOR OF LEFT MAXILLARY FIRST PERMANENT MOLAR  
20 CASES

A. <i>Analysis of Bodily Movement</i>	After Treatment	Subsequent to Retention	
No movement of crown and roots	2	crowns moved mesially roots tend to return but	2
Mesial movements of crown and roots	2	crowns continue to move mesially	2
Distal movement of crown and roots	7	roots unstable but crowns move mesially	7
B. <i>Analysis of Root Movement</i>			
No movement of roots	6	stable	3
		moved distally	2
		moved mesially	1
Mesial movement of roots	6	tended to return	5
		continued to move mesially	1
Distal movement of roots	8	stable	2
		tended to return	2
		continued to move distally	4
C. <i>Analysis of Crown Movement</i>			
No movement of crown	3	all moved mesially	
Mesial movement of crown	4	all moved mesially	
Distal movement of crown	13	all but one moved mesially	

10. Eleven cases exhibited a decrease of the axial inclination of the lower incisor to the mandibular plane after retention. They showed that there was a definite relapse after retention of the overbite corrected by treatment. Eight of the eleven cases showed a fifty percent or more relapse (Chart VII).
11. Nine cases exhibited an increase of the axial inclination after retention. One case only presented a fifty percent relapse of overbite correction. Two cases showed no change whatsoever, and the others showed only a slight tendency toward relapse (Chart VII).
12. In fifteen cases, where correction of the overbite was indicated and accomplished, relapse of some degree occurred after retention (Chart VII).
13. Charts V and VI demonstrate that relapse after retention of mandibular arch length gained and of expansion between the mandibular buccal segments seems to bear no relationship to the behavior of the mandibular incisors after retention.
14. The measurements taken from the plaster casts before and after treatment and subsequent to retention revealed that the lower arch was increased in length from one molar around to the other by treatment in practically every case. Such increases ranged in amount from 1 mm. to 12 mm. Similarly, there was a loss in this dimension following retention but in only a few cases was this loss complete.
15. In most cases there was an increase in the width of the arches as measured by inter-canine, first bicuspid, and molar distances. These increases ranged from 1 mm. to 10 mm. Some of this width was lost subsequent to retention but again the loss was not complete and there was a considerable difference in the percentage lost in the various cases.

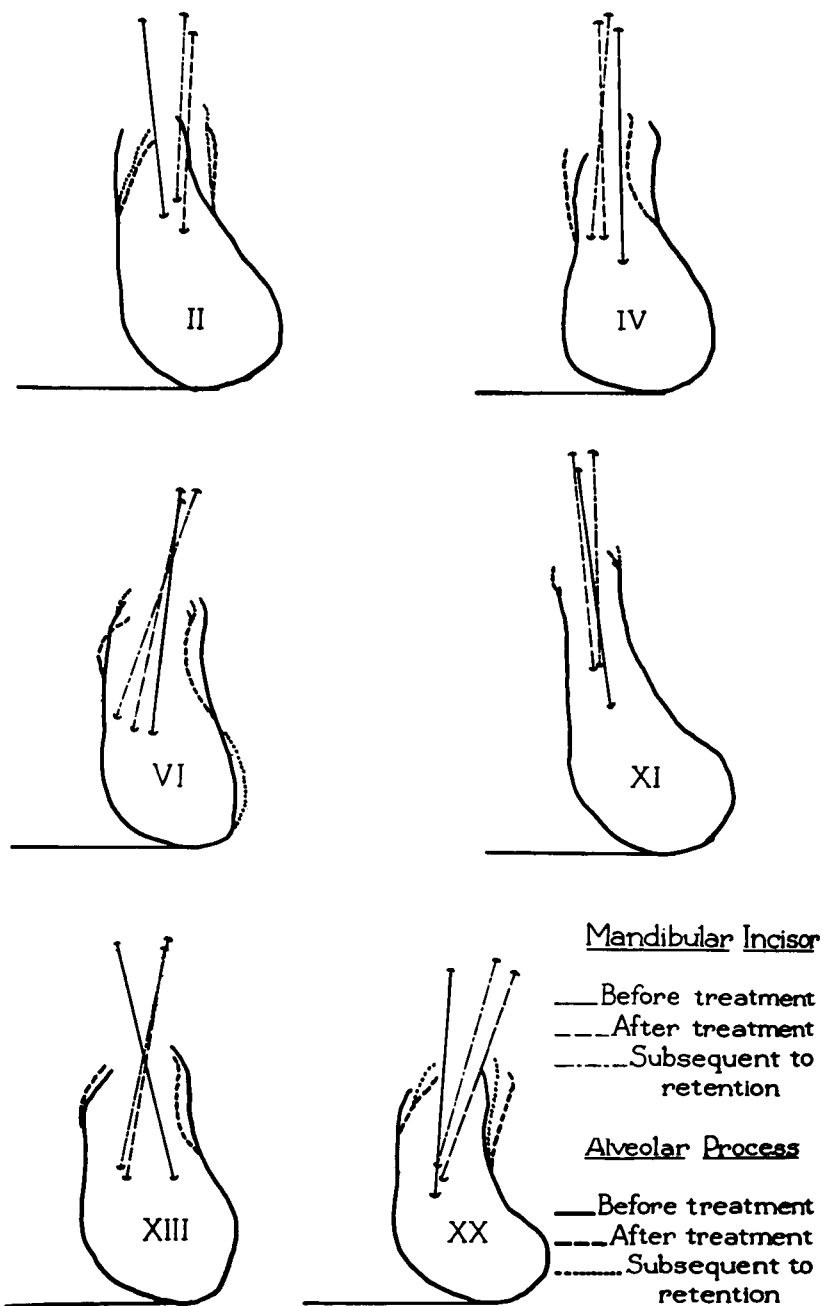


FIG. 3. Cases wherein the lower incisor had increased its axial inclination during treatment and continued the increase subsequent to retention.

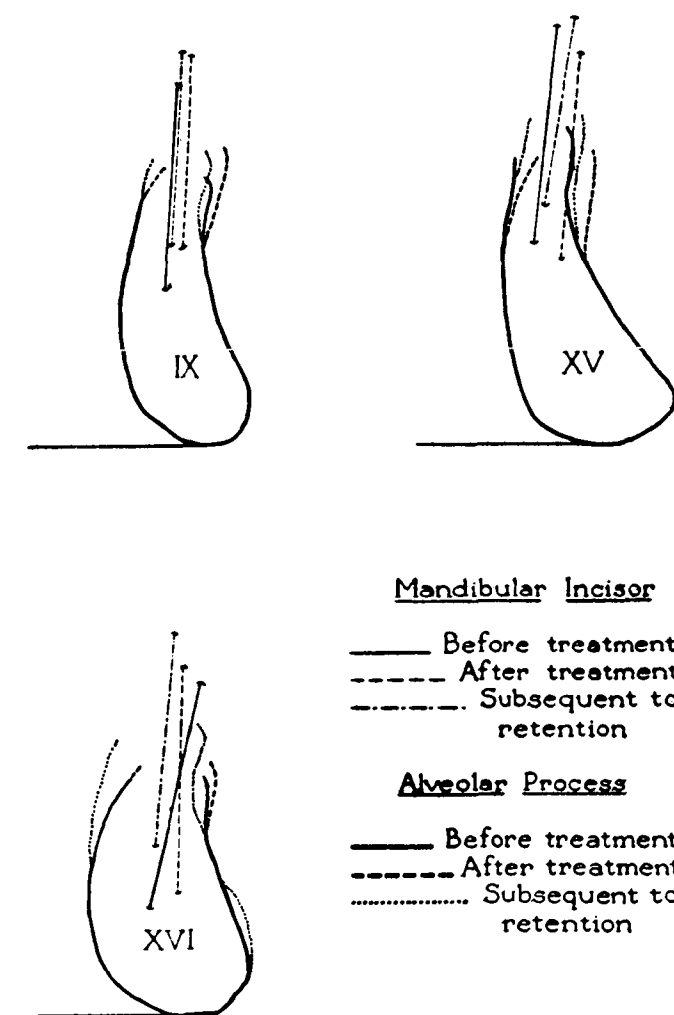


FIG. 4. Cases IX and XVI presented a decrease in axial inclination of the lower incisors due to treatment. In both cases, these teeth tended to return after retention. Case XV showed that the axial inclination of the lower incisor did not change during treatment, but became more procumbent following retention.

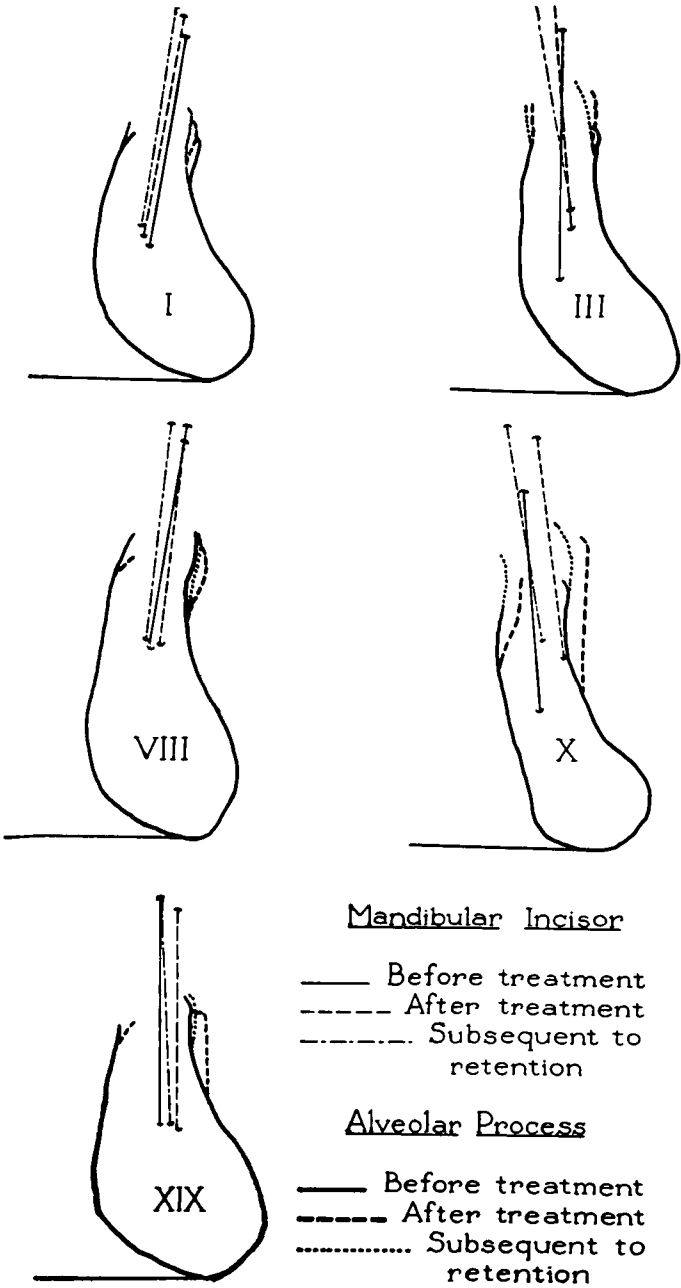


FIG. 5 These cases demonstrated a decrease of the axial inclination of the lower incisors to the mandibular plane during treatment and continued the decrease subsequent to retention.

CHARTS I AND II\*

AXIAL INCLINATION OF LEFT MANDIBULAR CENTRAL INCISOR  
GROUP A. CASES SHOWING A DECREASE OF AXIAL  
INCLINATION AFTER RETENTION

Case No.	1. Before treatment	2. After treatment	Difference between 1 and 2	3. After retention	Difference between 2 and 3
I	+9°	+8°	-1°	+7°	-1°
III	-1°	-6°	-5°	-12°	-6°
V	-3°	+4°	+7°	+3°	-1°
VII	+19°	+23°	+4°	+22.5°	-.5°
VIII	+7.5°	+5.5°	-2°	+5°	-.5°
X	-6°	-9°	-3°	-11°	-2°
XII	-1°	+4.5°	+5.5°	-4°	-8.5°
XIV	0°	+7°	+7°	+2°	-5°
XVII	-5.5°	0°	+5.5°	-4°	-4°
XVIII	+2.5°	-6°	+3.5°	+1°	-5°
XIX	0°	-1°	-1°	-3°	-2°

GROUP B. CASES SHOWING AN INCREASE OF AXIAL  
INCLINATION AFTER RETENTION

II	-7°	+1°	+8°	+2°	+1°
IV	-1.5°	-1°	+.5	+4°	+5°
VI	+6°	+11°	+5°	+19°	+8°
IX	+3.5°	+2°	-1.5°	+3°	+1°
XI	9°	-6.5°	+2.5°	-3°	+3.5°
XIII	-13°	+10.5°	+23.5°	+11.5°	+1°
XV	+6.5°	+6.5°	0°	+10°	+3.5°
XVI	+12°	+1°	-11°	+4.5°	+3.5°
XX	+4°	+14°	+10°	+15°	+1°

\*Same order of cases is followed in all charts.

CHART III

BEHAVIOR OF THE AXIAL INCLINATION OF THE MANDIBULAR FIRST  
PERMANENT MOLAR SUBSEQUENT TO RETENTION

RESPONSE TO TREATMENT	No. Cases	Stable	Tendency to Return	Continued to Move in Direction of Treatment Tipped distally
Stable .....	1			
Mesial tip .....	6	1	3	2
Distal tip .....	13		9	4

CHART IV

BEHAVIOR OF THE AXIAL INCLINATION OF THE MAXILLARY FIRST  
PERMANENT MOLAR SUBSEQUENT TO RETENTION

RESPONSE TO TREATMENT	No. Cases	Tendency to Return	Continued to Tip Mesially
Stable .....	1		1
Mesial tip .....	7		7
Distal tip .....	12	12	

CHART V

GROUP A. Case No.	ANALYSIS OF THE MODELS				SEGMENTS
	EXPANSION OF Increase between cuspidals after treatment	THE MANDIBULAR Relapse subsequent to retention	BUCCAL Increase between 1st bi- cuspidals after treatment	Relapse subsequent to retention	
I	4	2	2	0	
III	2	0	2	0	
V	2	2	8	3	
VII	0	0	7	0	
VIII	6	3	9	1	
X	2	1	4	0	
XII	4.5	1	10	.5	
XIV	4	2	—	—	
XVII	4	1	4	0	
XVIII	0	0	3.5	0	
XIX	4	0	8	1	
GROUP B.					
II	2	1	3	0	
IV	0	0	2	.5	
VI	2	0	6	0	
IX	4.5	2	8	2	
XI	6	3.5	8	4	
XIII	6	1	4	0	
XV	2	2	4	2	
XVI	1	1	6	1	

All measurements were made in millimeters.

CHART VI

ANALYSIS OF MANDIBULAR ARCH LENGTH			
Increase between molars after treatment	Relapse subsequent to retention	Gained by treatment	Lost subsequent to retention
4	1	5	6
6	0	3	3
10	2	10	5
4	1	9	3
8	2	7	5
7	1	12	4
4	.5	8	4
2	1	3	4
3.5	0	5	3
5	1	1	1
4	1	5	3
2	.5	3	2
2	.5	0	0
2	2	2	0
4	0	12	2
2	1	8	3
5	1	4	1
4	3	3	3
10	1	8	4

# CHART VII ANALYSIS OF OVERBITE

GROUP A Case No.	1. Original overbite	2. Overbite after treatment	Difference between 1 & 2 (correction of overbite)	3. Overbite after retention	Difference between 2 & 3 (relapse of over- bite correction)
I	2.5	2	.5	3	1
III	0	0	0	1	1
V	5	1	4	3	2
VII	4	.5	3.5	2	1.5
VIII	4.5	1.5	3	3.5	2
X	2	2	0		
XII	4.5	0	4.5	2	2
XIV	7	1	6	4	3
XVII	3.5	1.5	2	2.5	1
XVIII	6.5	.5	6	3.5	3
XIX	5	0	5	3.5	3.5
GROUP B					
II	4	2	2	1	1*
IV	3.5	1	2.5	2	1
VI	5.5	1	4.5	1.5	.5
IX	2	1.5	.5	2	.5
XI	1.5	1	.5	1	0
XIII	7	1	6	2.5	1.5
XV	5	0	5	2	2
XVI	2.5	2.5	0	2.5	0
XX	6	0	6	.5	.5

All measurements were made in millimeters.

\*The overbite continued to decrease subsequent to retention.

# CHART VIII

## ANTEROPosterior GROWTH OF THE MAXILLA AND THE MANDIBLE GROWTH OF THE MAXILLA      GROWTH OF THE MANDIBLE

GROUP A. Case No.	During treatment	Subsequent to retention	Total growth	During treatment	Subsequent to retention	Total growth
I	2	2	4	5	1.5	6.5
III	3	0	3	6	0	6
V	1	1	2	2	0	2
VII	2	.5	2.5	4	3	7
VIII	1.5	0	1.5	.5	.5	1
X	3	0	3	6	3	9
XII	0	0	0	1	0	1
XIV	0	1.5	1.5	3	4	7
XVII	1	2	3	3	2	5
XVIII	0	4	4	5	6	11
XIX	1	0	1	2	0	2
GROUP B.						
II	.5	0	.5	3	0	3
IV	1	1	2	2	2	4
VI	1	1	2	3	2	5
IX	2	0	2	2	1.5	3.5
XI	1.5	0	1.5	1	0	1
XIII	0	.5	.5	1	1	2
XV	2	1	3	1	1	2
XVI	.5	4.5	5	.5	6.5	7
XX	.5	1.5	2	2	2	4

All measurements were made in millimeters.



## SUMMARY

A study has been made of the movements of the lower incisor teeth and of the mandibular and maxillary first permanent molars during orthodontic treatment and subsequent to the removal of retention.

In the case of the mandibular molars it has been shown that these teeth may be moved bodily, or by tipping forces, in either a mesial or distal direction by orthodontic forces. Regardless of the type or direction of movement, however, the majority of cases showed a tendency for this tooth to return to its original position. An even stronger tendency was present for these teeth to move mesially after retention. A very few cases showed a continuation of distal movements after such movements had been instituted by treatment. We are at a loss to explain this behavior.

A similar though stronger tendency was exhibited by the maxillary molar. In this jaw, distal movement was accomplished in a large number of cases yet almost without exception there was a complete return of the tooth to its original position with a subsequent continuation of the mesial movement of the crown after retention.

Although the tendency for a return to the original position was prevalent in the behavior of the lower incisor teeth there were certain aspects to this behavior that differed from that in the molar. These teeth showed the effects of treatment to a greater degree; none of them were unaffected. In those where treatment had resulted in an increase in the axial inclination (greater procumbency) half tended to regain their former inclination and half became more procumbent. In others, where treatment had resulted in a decrease in the axial inclination, the majority continued to decrease after retention. Disturbance of the root apex or crown was followed by a return to the original position in almost every case, particularly if such movement had been in a labial direction.

In a vertical direction it was shown that teeth depressed by treatment regained their pretreatment height and in some cases exceeded it. Correction of the overbite in treatment had a strong tendency toward relapse after retention.

The tracings of the mandibular symphysis with the incisor tooth gave striking evidence that teeth do not move through bone but rather that the alveolar process is remodeled as the teeth change their positions. When teeth are moved labially the alveolar process follows and when relapse occurs the bone returns with the tooth.

The measurements taken with the plaster casts before and after treatment and subsequent to retention reveal that increases in lower arch length gained during treatment tended to decrease after retention, and that expansion gained by treatment similarly showed a loss after retention. Expansion between the first bicuspid demonstrated the least relapse tendencies of any teeth in the buccal segments.

In general, it was noted that the cases which exhibited the greatest amount of growth during the time covered by treatment showed the least amount of disturbance of the axes and positions of the teeth and the smallest degree of relapse subsequently.

## DISCUSSION

This study indicates that molar teeth, disturbed by orthodontic treatment, have a strong tendency to return toward their original relationships within their respective jaws after treatment. When it is recalled that a significant number of the cases studied were of the Class II variety, the successful treatment of which requires the movement of the upper and lower molars one full cusp in relation to each other and when it is further recalled that this new relation was successfully maintained in all cases the question arises, "where did the change occur?"

Several studies have previously been conducted on the behavior of the molar teeth during Class II treatment but to date no clean-cut, single conclusion has been reached as to the behavior of these teeth. In some, the maxillary molar has been shown to be moved back and in others it has been merely prevented from coming forward with growth. In still others, there has been demonstrable repositioning of the mandible. The need is apparent for a more precise method of detecting relatively minute changes.

When attention is turned to the incisors, some of the same tendencies are noted as are seen in molar behavior. As pointed out by Brodie,<sup>3</sup> these teeth tend also to return to their original pattern relationships. Not only do they tend to regain their previous axial inclinations but their root apices are shown to be remarkably stable. If these are moved either labially or lingually they return to their former positions within the alveolar process as shown in Figs. 2, 3, 4, and 5.

Another category of behavior which was investigated was the overbite of the incisors. The reduction of the overbite had been one of the objectives in the treatment of many of the cases studied and an effort was made to determine to what degree this objective had been attained. While it was found that the tendency to return partially or completely to the original conditions was present in fifteen of the twenty cases, the other five cases showed a quite different behavior. In these, the overbite either remained corrected or decreased further after treatment and retention. In order to explain this behavior it is necessary to point out several facts that enter into the treatment of these cases.

Thompson and Brodie<sup>16</sup> have shown that there is a stable resting position of the mandible. They have defined it as that position which results when all of the muscular and gravitational forces which operate on this bone are at equilibrium. In the average subject the teeth are separated by an interval of 2-3 mm. when the mandible is in this resting position. They have further shown that this amount of space (called "free-way") is demanded in all dentures and that if it is obliterated by means such as fillings, bridges, plates, etc. it is reestablished in a short period of time by the depression of those structures that bear the artificial replacements. In the case of fillings and bridges, the teeth which carry them are depressed; while in cases of full, tissue-born dentures, the bone beneath them is resorbed until the free-way is reestablished.

In orthodontic treatment involving the distal movement of molar teeth it is customary practice to tip the maxillary molar for purposes of expediting movement. The mandibular molar is given slight distal tipping forces to insure that it will not be tipped forward by the pull of the intermaxillary elastic which is attached to it. Such distal tipping forces tend to extrude the molars slightly into the free-way space and open the bite in the incisor region. Clinically, it appears that the incisors were being depressed but the

cephalometric findings of Brodie, Downs, Goldstein, and Myer<sup>5</sup> show that the mandible is driven downward to a slightly lower position. Because of the fact that the mandible cannot be maintained in this new position, probably because of increased muscle tensions, it slowly returns to its original resting point. This probably accounts for the fact that as the molars regain their axial inclinations the bite closes and the overbite increases once more. This would also explain why mandibular incisors that had been tipped labially by treatment tended to become more upright after orthodontic forces were removed. These teeth pass to the lingual of their antagonists during function and hence would tend to be driven into the arc of a smaller circle as the overbite returned.

Certain findings by Thompson<sup>15</sup> on the closing movement of the mandible to the clenched position from the resting position may well explain the behavior of those cases where (1) the incisors became more procumbent and (2) the overbite decreased following treatment. Thompson has shown that in those cases where malposed teeth interfere with the simple hinge-like movement, the entire mandible may be deflected as the teeth are occluded. Under such conditions the forces of occlusion, operating between the upper and lower arches, may become determinants in the behavior of the teeth during and after treatment. Regulating and aligning of the teeth of the maxillary arch in such cases would have the effect of removing from the lower arch the strong lingual forces operating to hold these teeth back. Moving labially, they would become more procumbent with treatment and this movement would continue after treatment until they reached the axial inclination demanded by the inherent pattern of the patient. Under such conditions the teeth, moving into the arc of a larger circle, would exhibit a decreased overbite.

The final point of interest investigated in these cases was the ultimate fate of arch length and arch width gained by treatment. It has been stated repeatedly that neither of these could be held, that relapse to the original dimensions always occurred. This does not seem to be true.

In every case, with one exception, where an increase in arch length was gained during treatment there was a loss following retention. Part of this loss can be explained, however, by the fact that the models of the cases after treatment were usually made immediately after the removal of the bands and therefore some of the length gained and lost represented the combined thickness of the bands of which there were at least twelve in each jaw. In nine of the twenty cases at least fifty percent of the lower arch length gained in treatment (1 mm. to 12 mm.) was maintained following retention. In a similar way, nine of the cases showed a maintenance of width gained between the bicuspid and such width decreased only slightly in the others.

420 Lincoln Road

### References

1. BROADBENT, B. HOLLY: 1931A New X-ray Technique and Its Application to Orthodontic Practice. *ANGLE ORTHODONTIST*, Vol. 1, No. 1.
2. IDEM: 1937 Bolton Standards and Techniques in Orthodontic Practice. *ANGLE ORTHODONTIST*, Vol. VII, No. 4.
3. BRODIE, ALLAN G.: 1944 Does Scientific Investigation Support the Extraction of Teeth in Orthodontic Therapy? *The Am. Jnl. Orth. and Oral Surg.* Vol. 30, No. 8.
4. IDEM: 1940 On the Growth Pattern of the Human Head From the Third Month to the Eighth Year of Life. *Am. Jnl. Anat.* Vol. 68, No. 2.

5. BRODIE, A. G., DOWNS, W. B., GOLDSTEIN, A., AND MYER, E.: 1938 Cephalometric Appraisal of Orthodontic Results, a Preliminary Report. *ANGLE ORTHODONTIST*, Vol. VIII, No. 4.
6. DOWNS, WILLIAM B.: 1940 A Study in Dental Arch Length. *ANGLE ORTHODONTIST*, Vol. X, No. 2.
7. IDEM: 1947 Unpublished Material.
8. EPSTEIN, WALTER N.: 1946 Analysis of Changes in Molar Relationships by Means of Extra-Oral Anchorage in Treatment of Malocclusion. *Master's Thesis*. Library of University of Illinois.
9. FISCHER, BERCU: 1943 Recording Tooth Movement with the Sectioned Oriented Cast. *ANGLE ORTHODONTIST*, Vol. XIII, Nos. 1 and 2.
10. IDEM: 1945 Recording the Frankfort-Mandibular Plane Angle Using Oriented Mandibular Radiogram and Sectioned Oriented Cast. *ANGLE ORTHODONTIST*, Vol. XV, Nos. 1 and 2.
11. HEDGES, ROBERT B.: 1946 Analysis of the Changes in Molar Relationships in Class II, Division 1 Malocclusions. *Master's Thesis*. Library of the University of Illinois.
12. MARGOLIS, HERBERT F.: 1943 Axial Inclination of Mandibular Incisors. *Am. Jnl. Orth. and Oral Surg.*, Vol. 29, No. 10.
13. NOYES, H. J., RUSHING, C. H., AND SIMS, H. A.: 1943 The Angle of Axial Inclination of Human Central Incisor Teeth. *ANGLE ORTHODONTIST*, Vol. XIII, Nos. 3 and 4.
14. SPEIDEL, T. D., AND STONER, M. M.: 1944 Variation of Mandibular Incisor Axis in Adult "Normal" Occlusion. *Am. Jnl. Orth. and Oral Surg.*, Vol. 30, No. 10.
15. THOMPSON, JOHN R.: 1946 The Rest Position of the Mandible and Its Significance to Dental Science. *Jnl. A. D. A.*, Vol. 33, Feb. 1.
16. THOMPSON, J. R., AND BRODIE, A. G.: 1942 Factors in the Position of the Mandible. *Jnl. A. D. A.*, Vol. 29, June 1.
17. TWEED, CHARLES H.: 1941 The Application of the Principles of the Edgewise Arch in the Treatment of Malocclusion. *ANGLE ORTHODONTIST*, Vol. XI, No. 1.

420 LINCOLN ROAD  
Miami Beach, Florida