

# Maintaining Mandibular Anchorage In Class II, Division 1, Treatment

HOWARD J. BUCHNER, D.D.S., M.S.D.  
Oak Park, Illinois

The gratifying changes which sometimes occur with the treatment of Class II, division 1, malocclusions could give the impression that they present no major problem to the orthodontist. However, if we consider some of the difficulties encountered in treating and retaining cases in this class, we will find the problem of mandibular anchorage always present to influence the mechanical approach, and to dictate the extent to which intermaxillary force can be used in correcting arch relationship.

Before one can outline a program of treatment, determining the nature of the movement and the mechanics to be used, it is necessary to diagnose the malocclusion.

One condition which is common to Class II, division 1 malocclusions is the distal positioning of the mandibular arch to the maxillary arch on one or both sides. While this describes the relationship of one arch to the other it leaves a number of variable characteristics not defined, such as: 1. arch form, 2. degree of inclination of the incisors, 3. the relation of the arches and supporting structure to each other and to face and cranium. This variation in relationship has been demonstrated repeatedly and is now generally recognized.

Angle made two hypotheses upon which he defined Class II, division 1 malocclusions, and upon which he based his treatment:

1. The constant position, in relation to other structures, occupied by the maxillary first permanent molar.

2. That stimulation caused by correct tooth relationship upon the face and jaws, would develop them to their ultimate perfection of balance and harmony.

Since we have become aware that considerable variations exists, it is necessary to analyze cases with an attempt to determine the nature of the variations. The work which Downs has completed on the study of the facial angle with cephalometric x-ray, should assist very much. He has determined the variation which exists in the several angular measurements of the normal face. This is a yard stick which can be used to determine the nature and extent of the aberration in the abnormal.

Upon the basis of the relationship of the dental arches to the face and cranium, Bercu Fischer has pointed out some important conditions. They can be listed essentially as follows: 1. protrusions of the maxillary dental arch; 2. retrusions of the mandibular dental arch, both functional and structural; 3. bimaxillary protrusions. He has also demonstrated occlusions that were very similar but which were in faces that were quite different. These he called type I, or forward divergent, and type II, or backward divergent.

It is obvious that there is a tremendous overlapping and blending of these groups, with only the extremes being well defined. To a very large extent, the nature of the growth in the mandible, the length of the ramus and of the body, and the angle between the two, influence the type or

pattern of the face as indicated in the forward and backward divergent types. Much confusion will no doubt be eliminated when we start to diagnose these malocclusions in terms of definite angular and linear measurements of structure instead of general groupings, as helpful as these may be.

It is recognized that correct tooth relationship has limitations in stimulating the face and jaws. However, it should be remembered that in Class II, division 1 cases, many of the facial and masticatory muscles have not been functioning normally. The incorrect position and function of this musculature has influenced the position of the teeth in some instances, to a great degree. It is important in diagnosis that we recognize this fact, and associate it intimately with our evaluation of tooth and bone relationships. Correct tooth relation cannot be maintained, nor can the maximum benefit of correct occlusion be gained unless correct and vigorous function is established.

It is possible to maintain mandibular anchorage, or at least avoid the abuse of mandibular anchorage while using intermaxillary force, in two ways: (1) by the proper selection of the time at which treatment is instituted, and (2) by the nature of the mechanics used. These will both be discussed in turn.

It has been common practice to treat Class II, division 1 malocclusions as early as possible. They have been treated in the deciduous denture between three and four years of age. If the case had already passed this stage before the orthodontist was consulted, it was treated in the mixed denture stage following the eruption of the permanent incisors and the six year molars. Other cases were not treated until the eruption of the canines and premolars.

Early treatment has been instituted to develop a correct mesiodistal relationship early in life so that correct functions could be established with a resultant favorable influence upon the structures of the face during this early developing period. This is a splendid theory, and has merit. It should be practiced particularly in extreme cases not only to influence growth factors and functions, but also, to avoid the possibility of developing personality complexes and social maladjustments.

Treatment in the deciduous denture, and also in the mixed denture, is frequently discouraging because of the tendency for at least a partial relapse, and also because of adjustments that are necessary as the canines and premolars erupt into place. It is not pleasant for the orthodontist, nor the patient, nor is it always best for the health of the teeth and supporting structure, to have a child under some form of treatment or observation from three to thirteen years of age, or even from seven to thirteen years of age. For that reason there seems to exist a trend toward postponing treatment, at least in the milder cases, until the eruption of the canines and premolars.

In attempting to check the time when orthodontists preferred to treat these cases, a questionnaire was sent to eight well qualified orthodontists located quite uniformly from coast to coast. Three of them preferred early treatment. Four of them treated in the permanent dentition except in very extreme case. One treated in the mixed dentition or early in the permanent dentition. While this sort of information is not an accurate barometer, it does indicate that there is at least a trend toward treatment in the permanent dentition.

In a reasonably large percentage of cases, the mandibular arch will be favorable enough so that by starting treatment at an ideal time, and preserving all the anchorage possible, they can be treated with intermaxillary force and still obtain a stable relationship.

I prefer to start these cases in the permanent dentition as soon as the mandibular teeth can be banded, and if possible, before the maxillary canines and premolars have erupted completely. In some instances, the maxillary canines and first premolars will have started to erupt while the maxillary and mandibular second deciduous molars are still in place. It seems logical to extract these second deciduous molars and place appliances immediately. At this stage, the mandibular arch with ten teeth erupted sufficiently so that they can be banded offers considerable resistance to displacement, while the lack of occlusal contact reduces the resistance to distal movement of the maxillary arch.

Recently, some have again attempted the use of occipital anchorage to hold or to move the maxillary arch back while the mandible developed forward. When satisfactory mandibular growth has occurred, the results have been encouraging. This method should help very much, and it should be used particularly where the deformity is severe and where mandibular anchorage is weak.

The round maxillary labial arch with a limited number of supporting bands and the removable mandibular lingual arch have been used quite universally. With a reasonable amount of skill and care, many types of tooth movements can be made. However, the mandibular appliance in particular is weak in the control of tooth movements and in the resistance to displacement of the mandibular teeth.

The use of the edgewise mechanism has made available more control of tooth movements than any other appliance. Its thorough, consistent use will keep the orthodontist out of a tremendous amount of trouble. Failure to band a sufficient number of teeth and to carry out precise detail in the use of the appliance has resulted in disappointment and failure. The reverse has also been true. Because the appliance has within its design the possibility of extensive control of tooth movements, every conceivable bend and torque has been placed in arch wires in an attempt to create movement or to resist it. This has no doubt resulted in too much control where control has not been indicated.

It is quite possible, that the use of second order bends with lingual crown torque in the incisor area of the mandibular arch, together with occipital anchorage, has resulted in a breaking down of mandibular anchorage rather than any resistance to displacement. As desirable and satisfactory as this type of movement may be, it does involve complicated mechanics. Unless it is done most expertly and with complete cooperation of the patient, the incisor roots will be moved labially, creating an incorrect tooth to bone relation, as well as destroying some bone tissue.

I question very much, if banding all the teeth in the maxillary arch of Class II, division 1, cases is always necessary or even desirable. If the second order bends are placed so that an equal pressure is brought to bear on each tooth in the buccal segments, and also, an equal amount of lingual crown torque on each incisor, then the movement will be effective provided that the patient wears the elastics constantly, and the appliance is re-activated at correct intervals. This is a big order! In all probability, the maxillary appliance frequently resists movement in the desired direction.

Too much lingual torque on the incisors will cause undesirable labial root movement in these teeth. Second order bends which are too severe will cause mesial root movement in the buccal teeth. This same movement may be caused by failure of a patient to wear elastics. Unless second order bends act equally on each tooth, the arch may become jammed so that movement is not as desired. A similar resistance to movement occurs when second orders and incisor torque are not coordinated. One must not conclude that use of second order bends has been all wasted effort. I do believe however, that there is still much to be learned about the appliance, and we must be cautious with its application, and critical in appraising the changes created by it.

In treating the cases presented in this paper, bands are placed on the ten or twelve erupted mandibular teeth. Any necessary corrections are made in arch form, individual tooth position, and curve of spee, by the use of an .021" round arch wire. The mandibular arch is then stabilized by obtaining bracket engagement with an .021" x .024" edgewise arch. The original arch is disturbed as little as possible in obtaining bracket engagement. No second order bends are used in this arch.

Bands are placed on the maxillary incisors and six year molars. Either an .021" round arch or an .021" x .024" edgewise arch may be used. There are weaknesses in the use of either arch which must be recognized, if they are to be used satisfactorily. The round arch is ideal for obtaining bracket engagement, and eliminates the necessity of controlling torque in the incisor brackets when an intermaxillary force is used. The long unsupported area between the laterals and the six year molars, together with the loose fit of the arch in the buccal tubes makes even a steel arch somewhat lacking in rigidity. However, if it is fitted closely to the teeth in the buccal segments and delicate elastics are used, it will usually work satisfactorily. The rectangular arch is ideal in every way, except that it will require some adjustment in the incisor area to avoid undesirable movement of the incisor roots, and also, to prevent the development of resistance to movement in the incisor area.

When the mandibular arch is stabilized, and the maxillary incisor brackets are engaged to a correctly fitted arch with stops in contact with each buccal tube, light intermaxillary force is applied continuously. During this period the maxillary molar crowns are tipped distally by placing a mild bend in the maxillary arch immediately in front of each buccal tube.

In some cases the maxillary arch will require some elongation to provide sufficient space for the canines. To accomplish this during the period when elastics are worn, stops are placed distal to each lateral bracket, and a very small closed coil spring is placed distal to the molar stops. This closed spring acts like a washer, to lengthen the arch wire. The length of the coil spring can be increased until sufficient space is obtained.

If spaces are present in the maxillary incisor area, these can be closed either with ligature traction or some form of spring force while elastics are being worn. As soon as correct arch length is obtained, stops are placed in contact with the buccal tubes.

Cases differ with respect to the length of time elastics must be worn. However, it is not at all uncommon to have the relationship of the arches corrected in a two month period. Sometimes it is possible to discontinue intermaxillary force completely. In other instances, particularly where muscle balance and function are not correct, it is desirable to continue the use of very mild elastics at night for a few months, not with the intention

of creating movement, but to resist any tendency for relapse while the buccal teeth erupt into position. During this period, an effort is made to establish correct function of the orbicularis oris, and to strengthen the action of the masseter-temporal group. The establishment of good function is as important as any part of treatment. Without it, most, or perhaps all cases in this class will fail.

After the arch relationship has been corrected, very frequently patients continue to leave the lips open in rest position, just as they did before treatment. They may also masticate food with the lips open instead of closed. They invariably smile with the lips open. A very splendid exercise can be instituted simply by having them voluntarily keep the lips closed in the rest position and while smiling. The opening and closing of the teeth in mastication produces an effective lip exercise, if the lips are kept closed during this function.

Various types of lower lip habits may persist following tooth movements. These may be, wetting the lower lip with the tongue, placing the lower lip between the teeth, or biting the lower lip. All of these habits affect the denture adversely. It may be necessary to get other members of the family to assist in reminding the patient when they indulge in such habits, since they frequently are not aware of it.

Vigorous masseter temporal exercises supply a very potent force for seating the cusps of the maxillary buccal teeth into position. The combination of strong function and complete seating of these cusps, assists in retaining a correct mesiodistal relation. As the maxillary canines and premolars erupt into position, bands are placed on any of these teeth which may require mechanical aid. Frequently they occupy satisfactory positions without assistance.

To demonstrate the selection of cases and the nature of the results obtained, a few cases will be presented briefly.

The first is a girl eleven years of age. The stage of tooth eruption is ideal for treatment. The second deciduous molars were extracted, and bands were placed on the ten erupted mandibular teeth, the maxillary incisors and six year molars. The relationship of the arches was corrected in two months. Very mild elastics were worn for twenty months. The case was retained with maxillary and mandibular removable retainers. Photographs are missing.

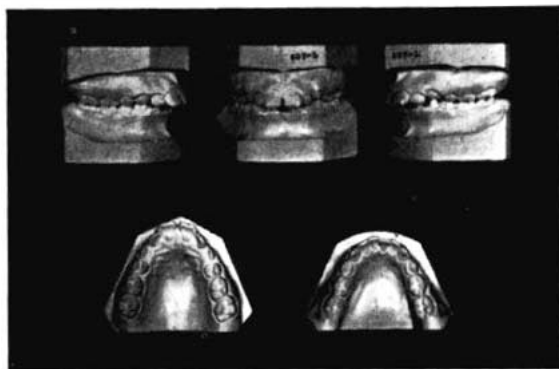


Fig. 1. Models of case (1) before treatment.

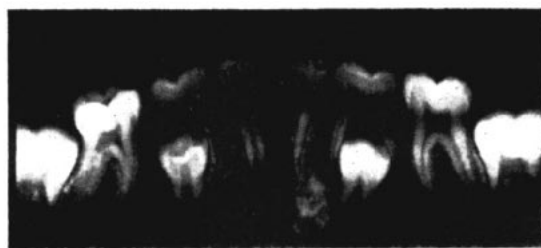


Fig. 2. Radiograph of the mandibular second deciduous molar area, showing the position of the erupting bicuspid.

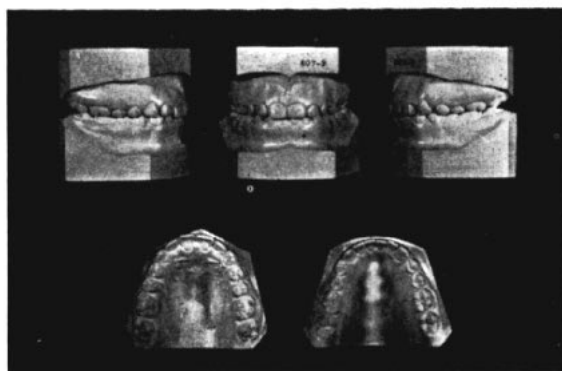

Fig. 3. Models of case (1) at the conclusion of active treatment.

The second case is that of a boy, age eleven years. Elastics were worn all the time for a two month period, during which the relation was corrected. The appliances were worn for fifteen months. The case has had no retention. The final models were made two years after all appliances were removed.

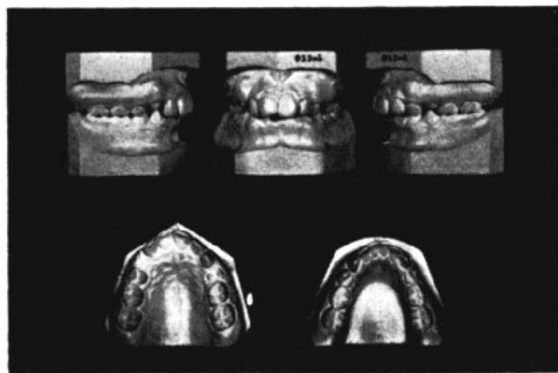


Fig. 4. Models of case (2) before treatment.

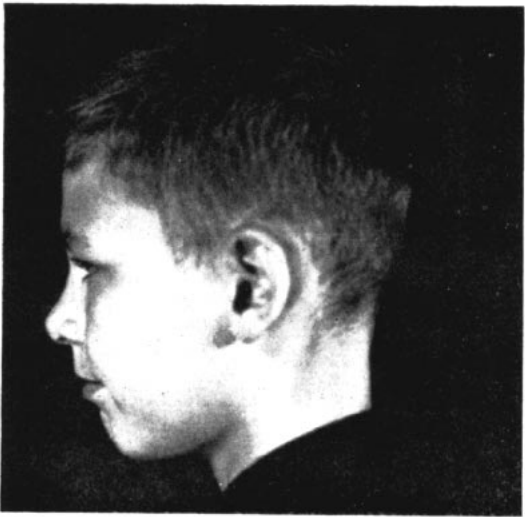

Fig. 5. Photograph of case (2) before treatment.

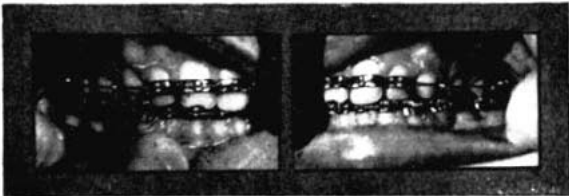

Fig. 6. Photograph of appliances used.

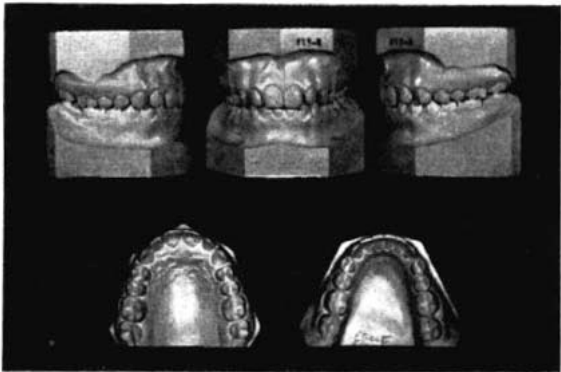


Fig. 7. Models of case (2) at the conclusion of treatment.

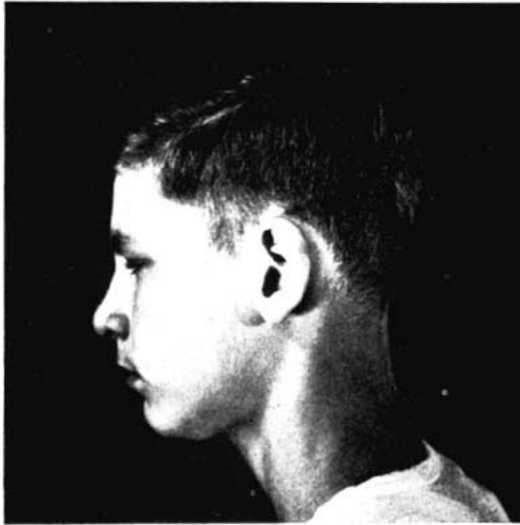

Fig. 8. Photograph of case (2) after treatment.

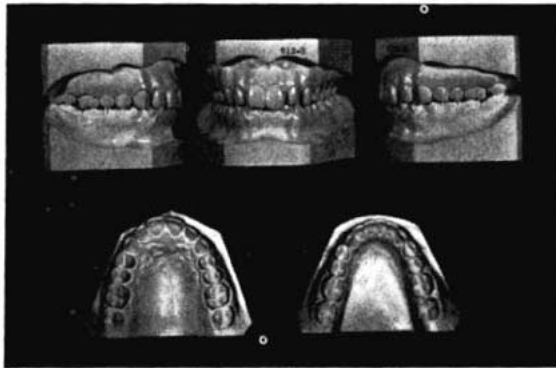


Fig. 9. Models of case (2) two years after appliances were removed. No retention.

The third case is a girl eleven years of age. The elastics were worn for eleven months; appliances were worn for twenty-two months. It was difficult to get the posterior teeth to occlude accurately. The teeth are not occluded well on the second set of models which were made when active treatment was completed. An upper Hawley retainer was worn for two years. The final models and photograph were made two and one-half years after retention was removed. A great deal of time was spent in trying to get satisfactory muscle function established. I believe that was largely responsible for the change between the second and third set of models.



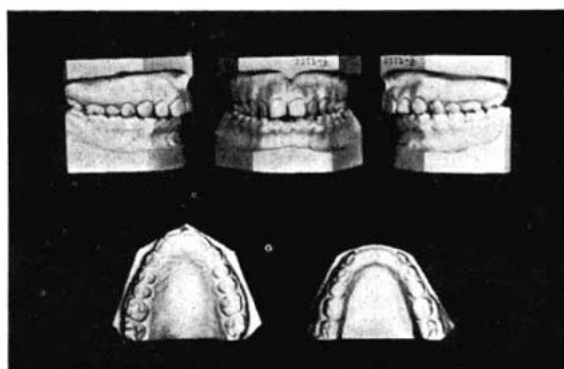


Fig. 10. Models of case (3) before treatment.



Fig. 11. Photograph of case (3) before treatment.

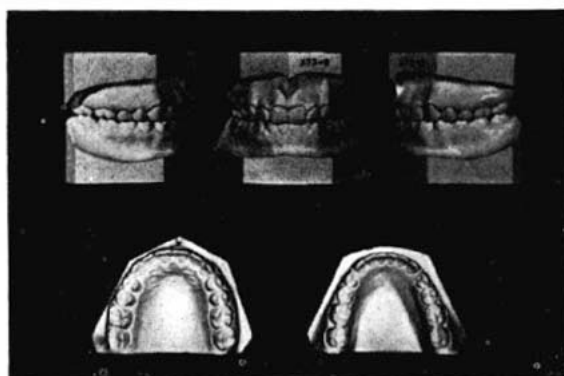


Fig. 12. Models of case (3) at conclusion of treatment.

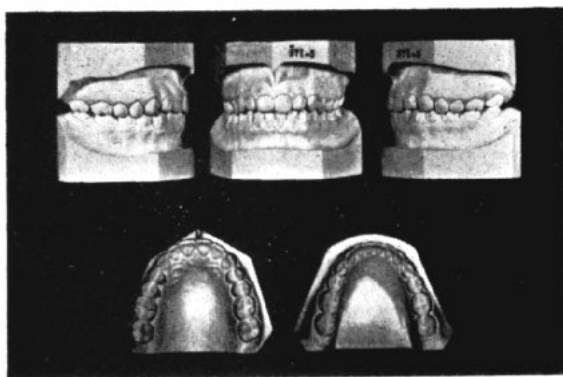


Fig. 13. Models of case (3) two and one-half years after removal of retention.

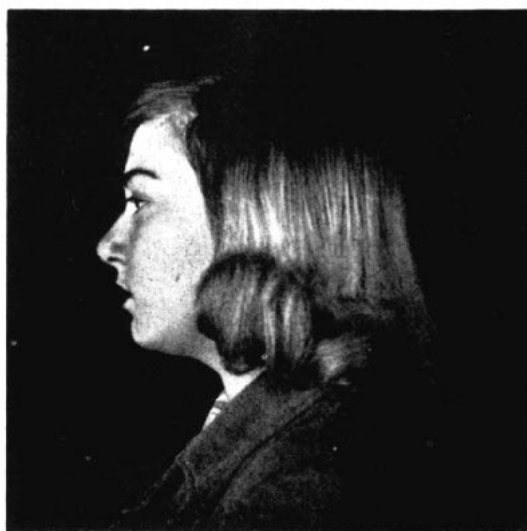

Fig. 14. Photograph of case (3) two and one-half years after removal of retention.

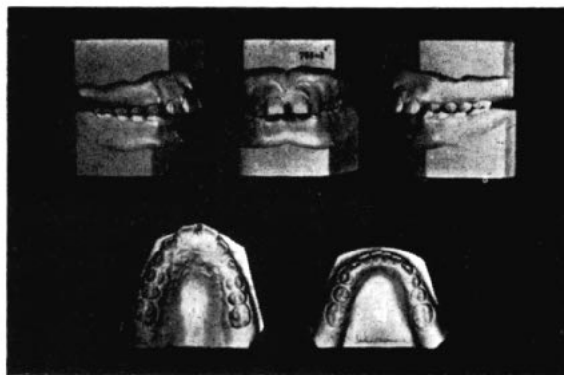


Fig. 15. Models of case (4) before treatment.

The fourth case is a boy, age eleven years. The relation of the arches was corrected in four months. Following this period, light elastics were worn at night. Appliances were removed in thirteen months. The case has been retained with an upper Hawley and a lower cuspid-to-cuspid retainer. The third model was made one year after the completion of treatment.

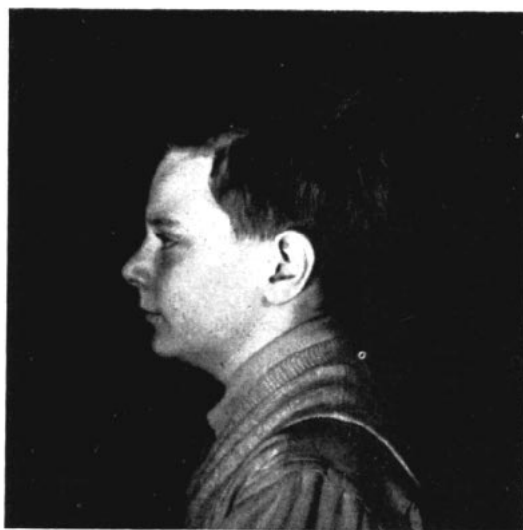

Fig. 16. Photograph of case (4) before treatment.

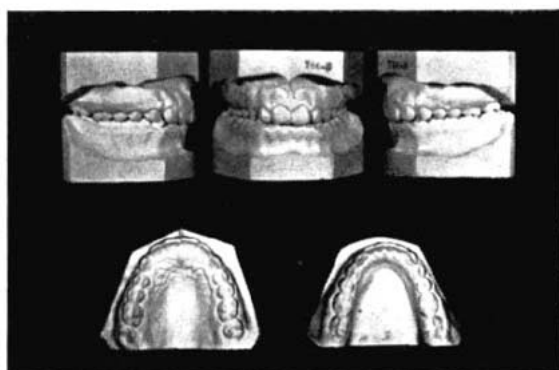


Fig. 17. Models of case (4) at conclusion of treatment.

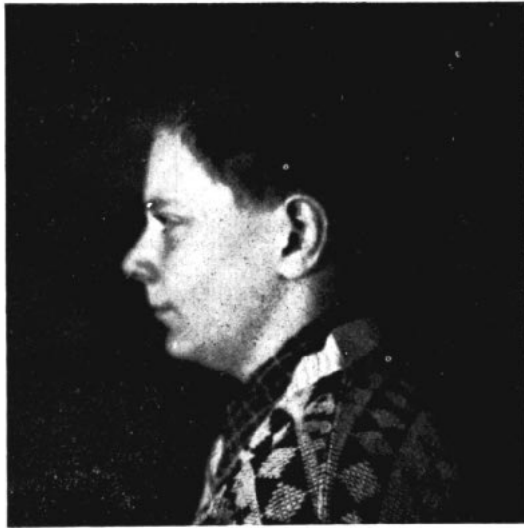

Fig. 18. Photograph of case (4) at conclusion of treatment.

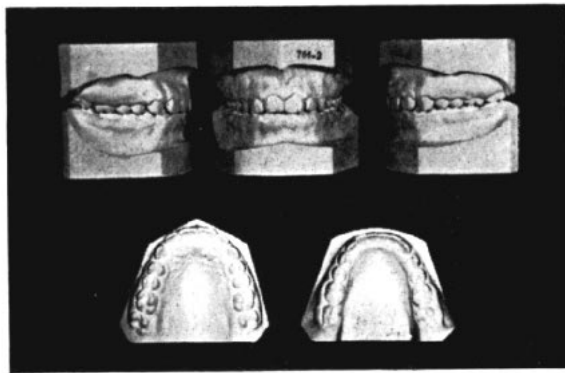


Fig. 19. Models of case (4) one year after the completion of treatment.

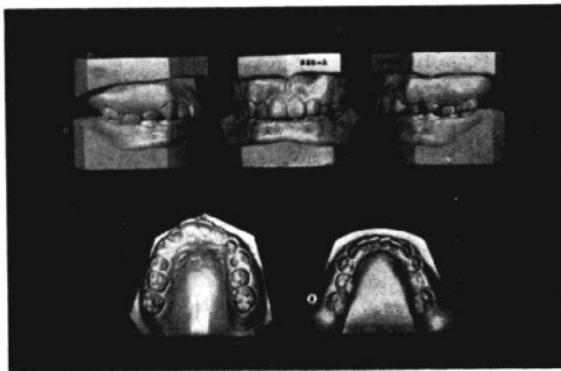


Fig. 20. Models of case (5) before treatment.

The fifth case is a girl ten years of age. The mesiodistal relation was corrected in four months. Treatment appliances were worn for nineteen months. It was difficult to get correct muscle function established. She had a speech impediment, and also had the habit of wetting and biting the lower lip. The maxillary arch was retained with a Hawley retainer. The mandibular arch has had no retention. The third model was made one and one-half years after completion of treatment.

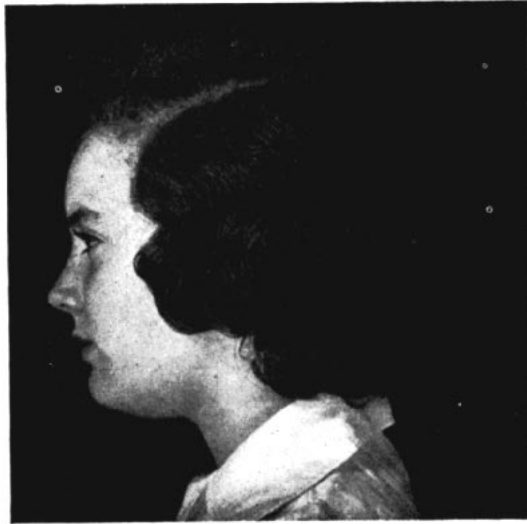

Fig. 21. Photograph of case (5) before treatment.

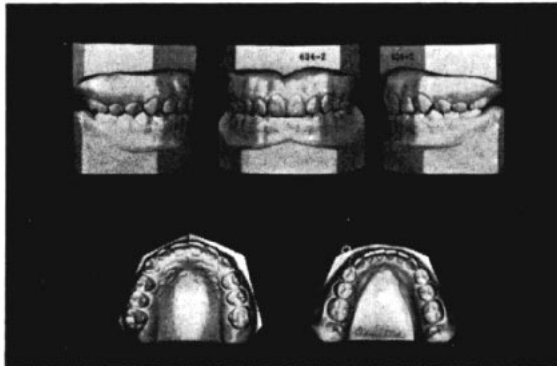


Fig. 22. Models of case (5) at conclusion of treatment.

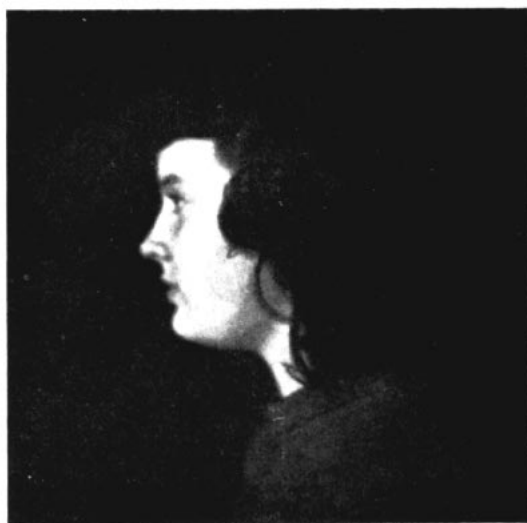

Fig. 23. Photograph of case (5) at conclusion of treatment.

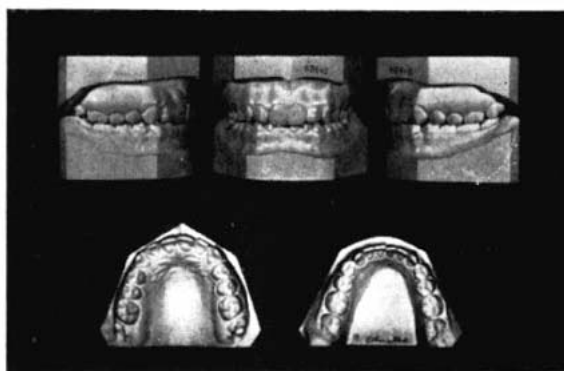


Fig. 24. Models of case (5) one and one-half years after treatment.

The sixth case is a girl, age eleven years. While watching the case in the mixed dentition, the fulness of the face in the denture area made me wonder if extraction might be indicated. As the canines and premolars started to erupt, it seemed as though treatment without extraction should be possible. The arch relation was corrected in fourteen months. Appliances were removed in eighteen months. No retention was used. The third model was made one and one-half years after completion of active treatment.

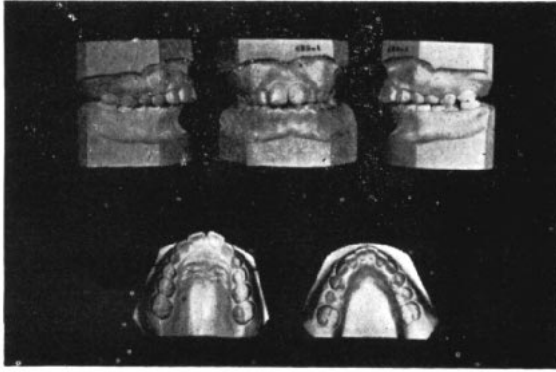


Fig. 25. Models of case (6) before treatment.

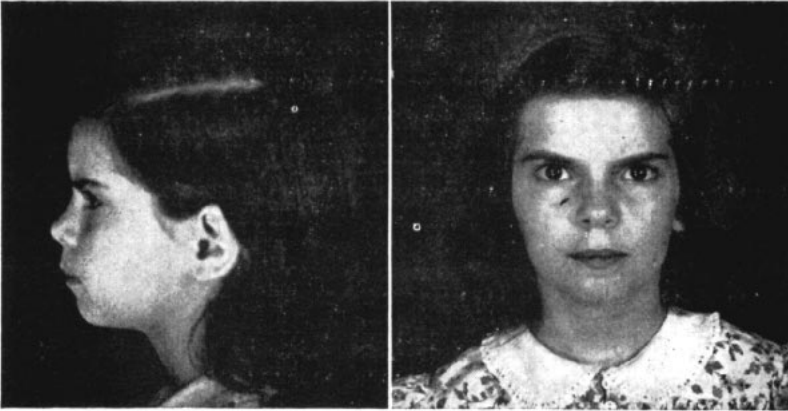

Fig. 26. Photographs of case (6) before treatment.

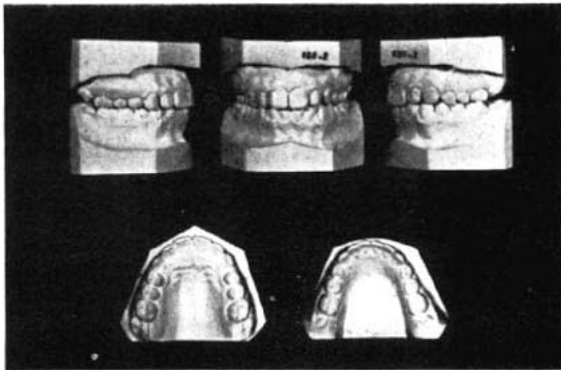


Fig. 27. Models of case (6) at conclusion of treatment.

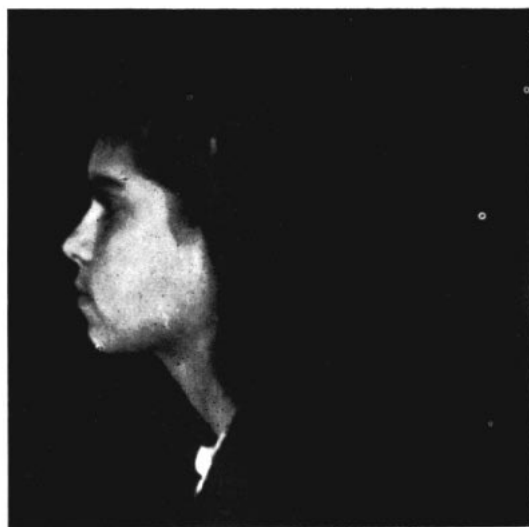

Fig. 28. Photograph of case (6) at conclusion of treatment.

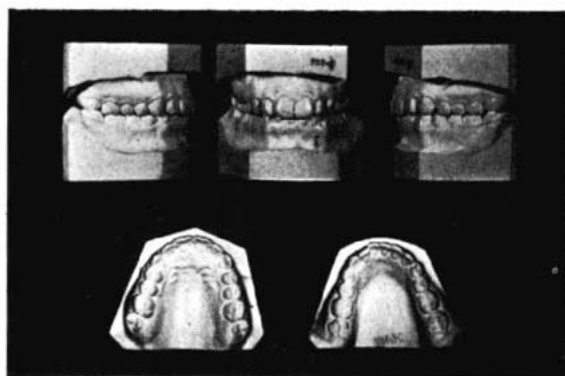


Fig. 29. Models of case (6) one and one-half years after treatment. No retention.

The seventh case is a girl, age eleven years. The arch relation was corrected in five months. Light elastics were worn at night for five months more. Appliances were removed in twenty months. Upper and lower removable retainers were worn for two years. The third model was made one year after retention was removed.



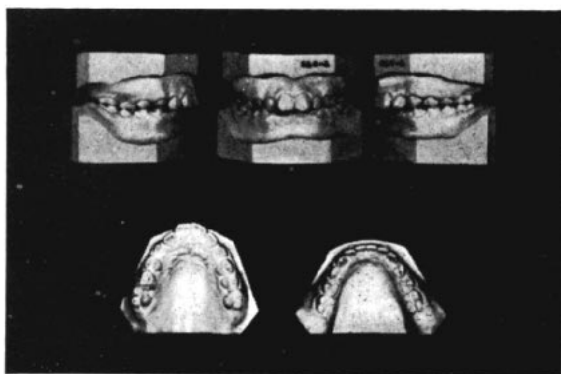


Fig. 30. Models of case (7) before treatment.

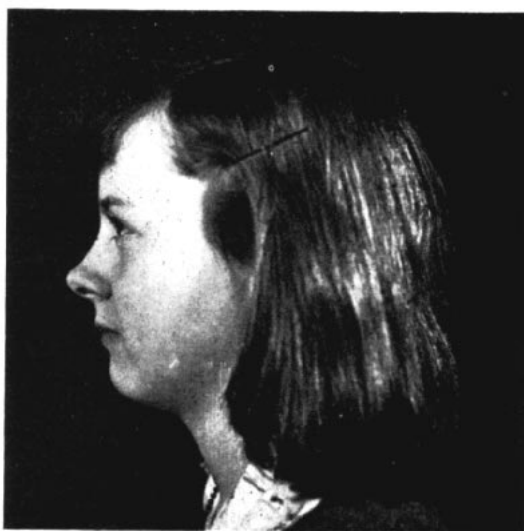

Fig. 31. Photograph of case (7) before treatment.

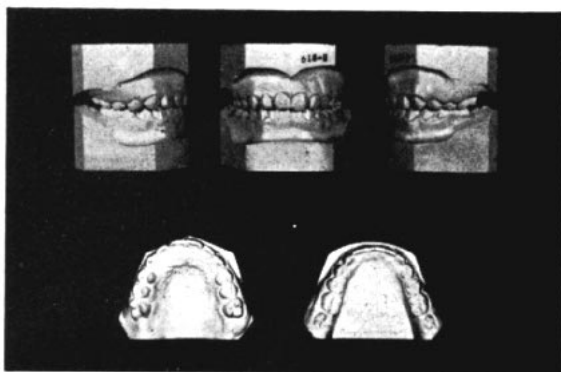


Fig. 32. Models of case (7) at conclusion of treatment.

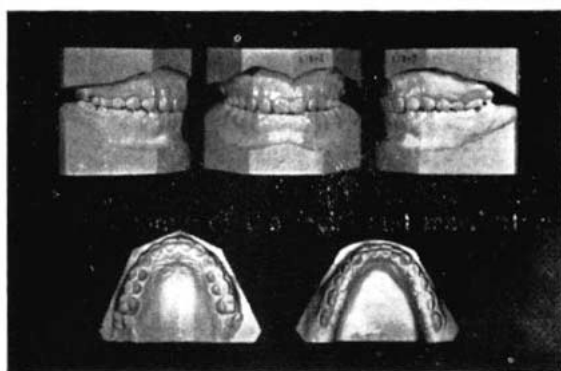


Fig. 33. Models of case (7) one year after retention was removed.

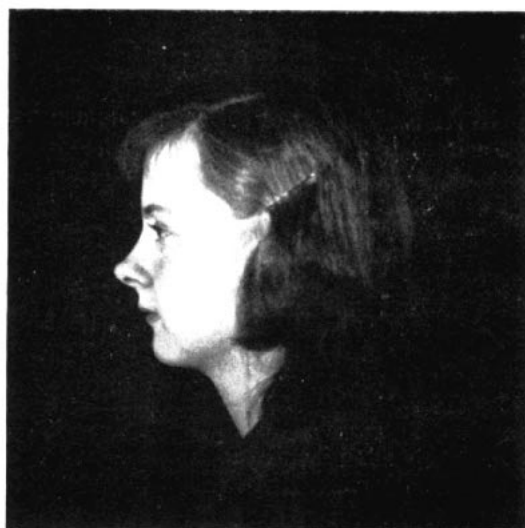

Fig. 34. Photograph of case (7) three years after treatment.

Although no bands were placed on the maxillary bicuspids of any of the cases, an increase in the width of the arch in this area was observed in every case treated. This indicates that these teeth make an adjustment as the arch relation is corrected, without any force from the appliance. It is possible that they tend to occupy such a position as they move distally to a wider area of bone structure. The force of occlusion from the mandibular arch no doubt is largely responsible for such a movement. The measurement of each model in this area before and after treatment is shown in Table I.

TABLE I				
Case	Width Across Upper First Bicuspid		Width Across Upper Second Bicuspid	
	Before	After	Before	After
1	26	29.2	30.7	33
2	28.5	30.2	30.3	35
3	26.5	29.5	31.5	34
4	29	30.1	32	34
5	29.5	31	28.8	37
6	26	27.8	26.5	31.2
7	25	28	30.2	33
8	25	28	30	33
9	26.5	28.5	32	34
10	25.2	29	30.5	34.5
Change in width in bicuspid area.				

Retention becomes largely a matter of judgment. If one can determine that the denture is in good relation to structure, and that the patient has cooperated to the maximum in establishing good functions, it may be possible to use no retention. The nature of the movement may be such that one arch will require retention while the other does not. Frequently both arches may require some retention. I know of no simple formula which can be applied to every case.

The time at which cases are treated, the nature of the appliance and the use of myofunctional therapy, are all involved in maintaining anchorage favorably. These factors may not reduce the length of time that appliances are worn, but they may reduce the amount of intermaxillary force. Stability of the denture seems to be enhanced by: 1. Using appliances as simply as possible, and avoiding any exaggerated tooth movements. 2. Keeping the use of intermaxillary force to the very minimum. 3. Permitting the maxillary canines and premolars to erupt into correct occlusal contact instead of moving them by appliance force. 4. Maintaining correct arch relation while establishing correct muscle function.

1011 Lake Street

#### BIBLIOGRAPHY

1. ANGLE, EDWARD H.: Malocclusion of the Teeth. Ed. 7. Philadelphia, 1907, S. S. White Dental Mfg. Co.; 448.
2. BRODIE, ALLAN G.: On the Growth and Pattern of the Human Head, From the Third Month to the Eighth Year of Life, *Am. J. Anat.* 68: 259, 1941.
3. BRODIE, ALLAN G.: Behavior of Normal and Abnormal Facial Growth Patterns. *Am. J. Orthodontics and Oral Surgery.* 26: 633-647, 1941.
4. DOWNS, WILLIAM B.: Variations in Facial Relationships: Their Significance in Treatment and Prognosis. *Am. J. Orthodontics.* 34: 812-840, 1948.
5. FISCHER, BERCU: Treatment of Class II Division I (ANGLE) II Differential Diagnosis and an Analysis of Mandibular Anchorage. *Am. J. Orthodontics* 34: 461-490, 1948.