

Reports of Cases

Case No. 1 is reported by Dr. Matthew H. Lashar, of Hollywood, California. Figures 1 to 3.

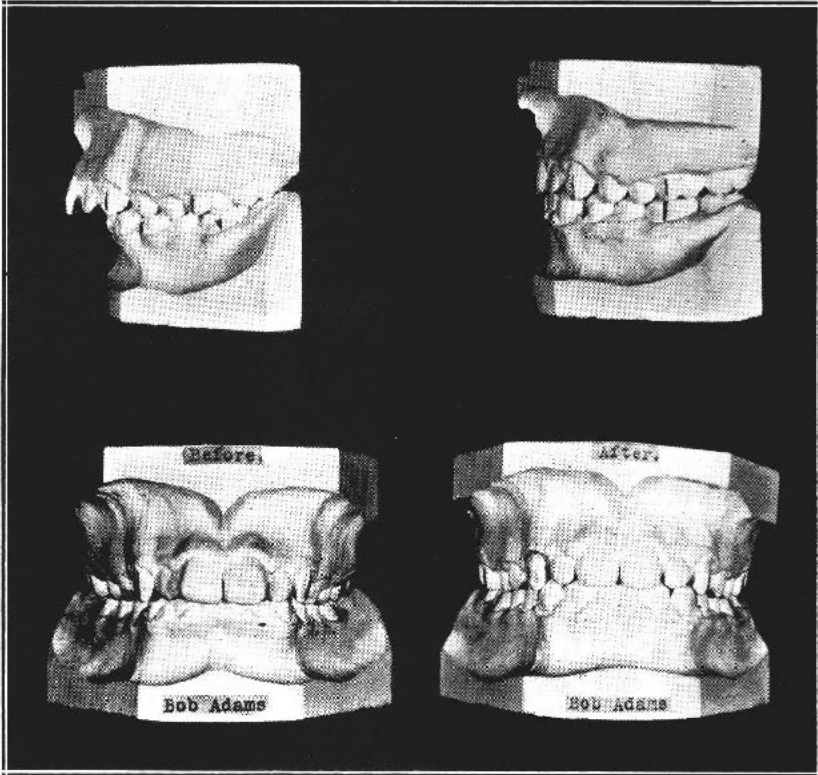


Figure 1

Age 13 Years—Classification—Class II, Division 1

Time of Treatment—From May 14th, 1928 to March 15th, 1929.

Type of Appliance—Angle's New Mechanism, Side-wise Archwire.

Retention—One year.

Type of Retainers—Maxillary—Plate, with Labial Wire, Mandibular—Cuspid to Cuspid, with Spurs.

Length of Time out of Retention—One year.

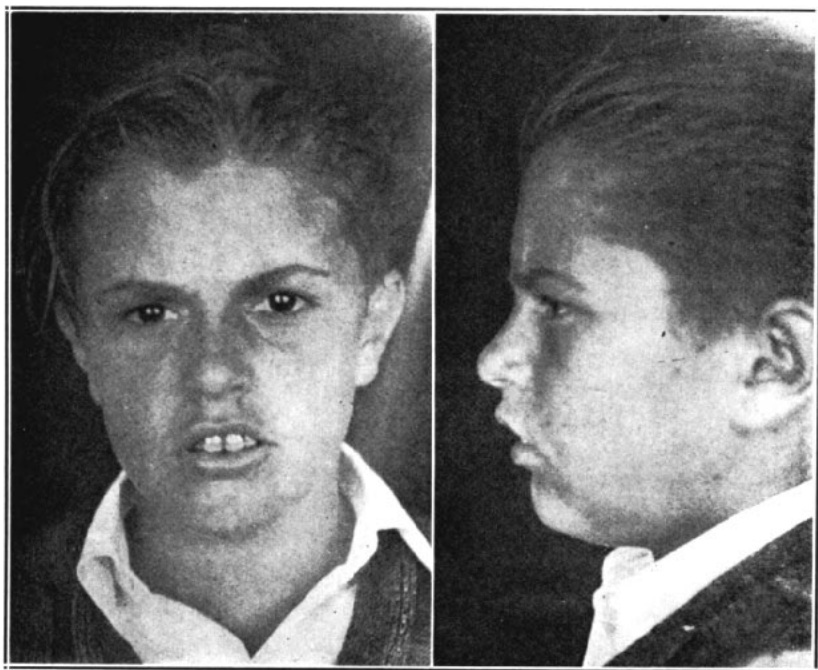


Figure 2
Photographs before treatment.

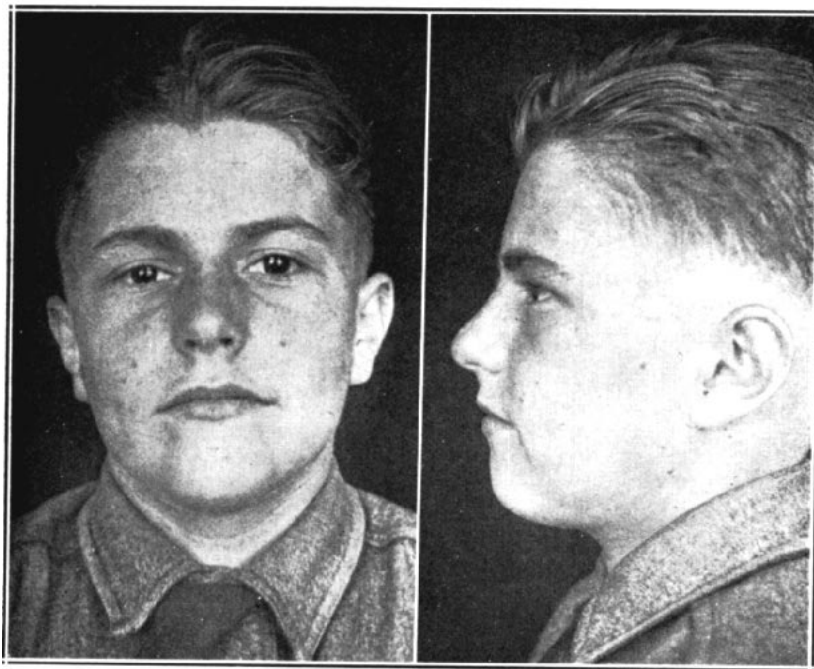


Figure 3
Photographs after treatment

Case No. 2 is reported by Dr. Charles H. Tweed of Phoenix, Arizona.
Figures 4 and 5.

1. Age of patient, 21 years.
2. Appliance placed September 1, 1930.
3. Time required for treatment, 11 months, 24 days.
4. Intermaxillary elastics applied September 18, 1930.
5. Elastics discontinued July 15, 1931.
6. Appliance removed and retainers inserted August 24, 1931.
7. Type of retention:
 1. Lower cuspid to cuspid lingual bar.
 2. Lower vulcanite plate with molar stops.
 3. Upper vulcanite plate with labial wire around four upper incisors. Rotations banded.
8. Relapse:
No relapse up to October 10, 1931.
9. Co-operation:
Splendid.
10. Models made immediately after appliances were removed.

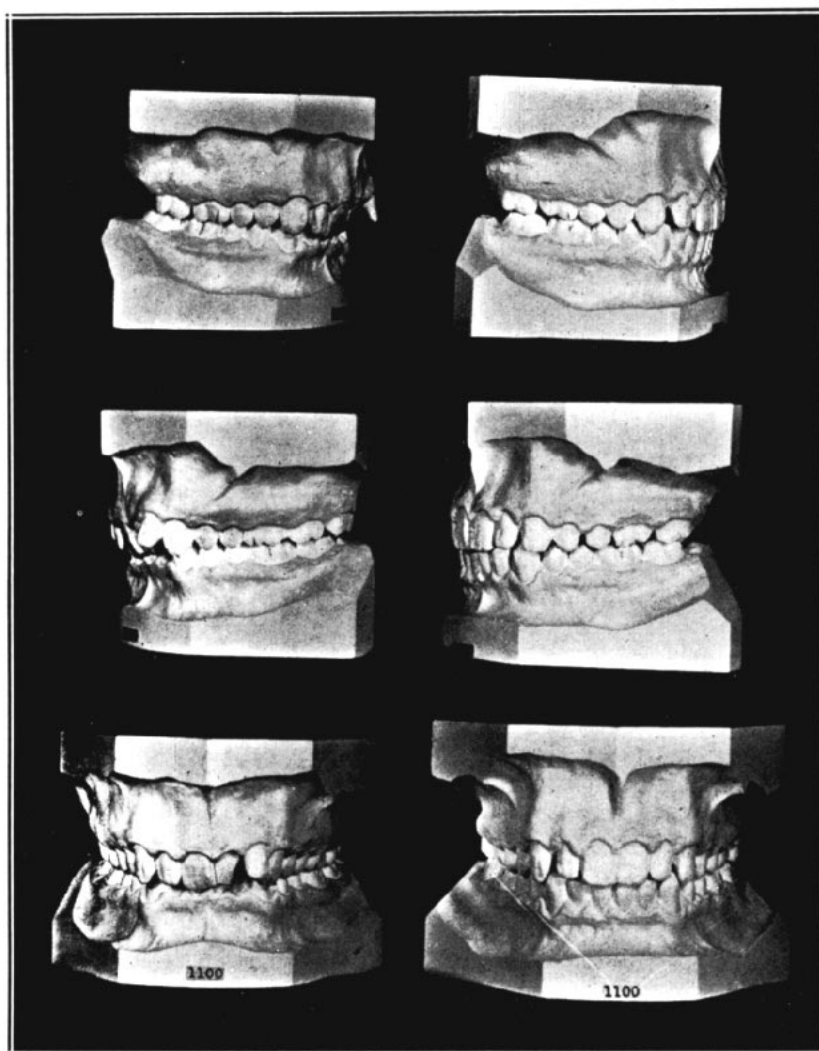


Figure 4

Comments on Case No. 2:

Jaw relationship normal and incisors edge to edge within six months. Picket fence bends in the arches gradually straightened out and large rubbers were worn to hold crowns while the roots of the teeth were being moved back into their correct axial inclinations.

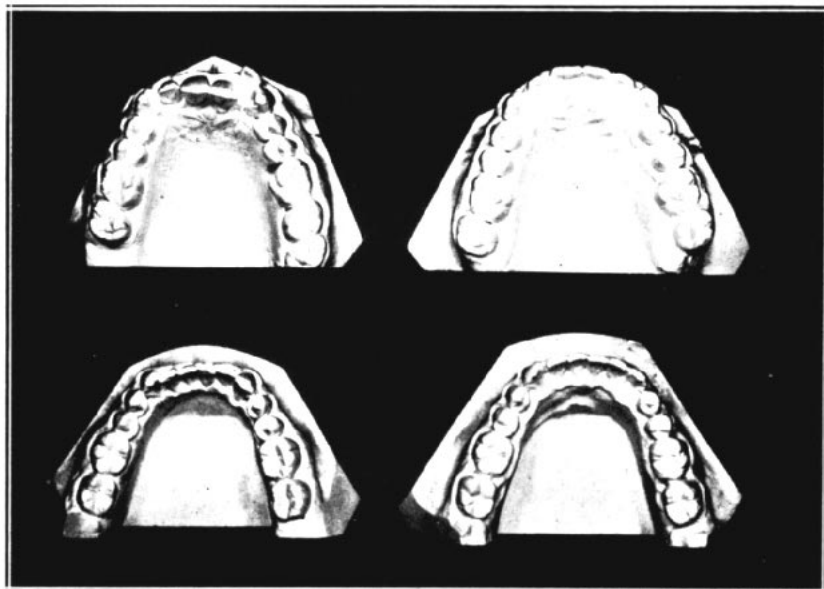


Figure 5

The upper left third molar was forced back so far that it was necessary to have it extracted.

Practically all Class II cases are overtreated in this office until an edge to edge relationship of the incisors has been reached. Occasionally in younger patients they are overtreated nearly to a Class III relationship.

Case No. 3 is also reported by Dr. Charles H. Tweed. Figures 6 and 7.

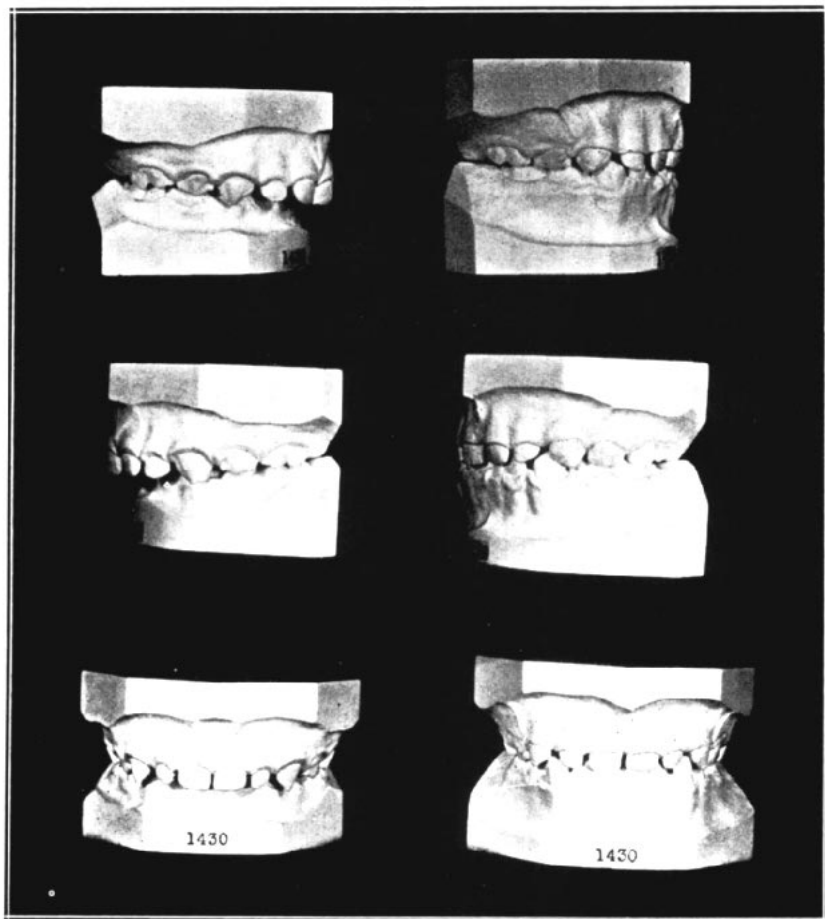


Figure 6

1. Age of patient, 38 months.
2. Appliance placed July 17, 1930.
3. Time required for treatment, 8 months, 28 days.
4. Elastics applied August 1, 1930.
5. Elastics discontinued March 15, 1931.
6. Appliances removed April 15, 1931.

7. Type of retention:

No retainers.

8. Relapse:

Jaw relationship normal with molars locked beautifully with slight over-bite in incisor region.

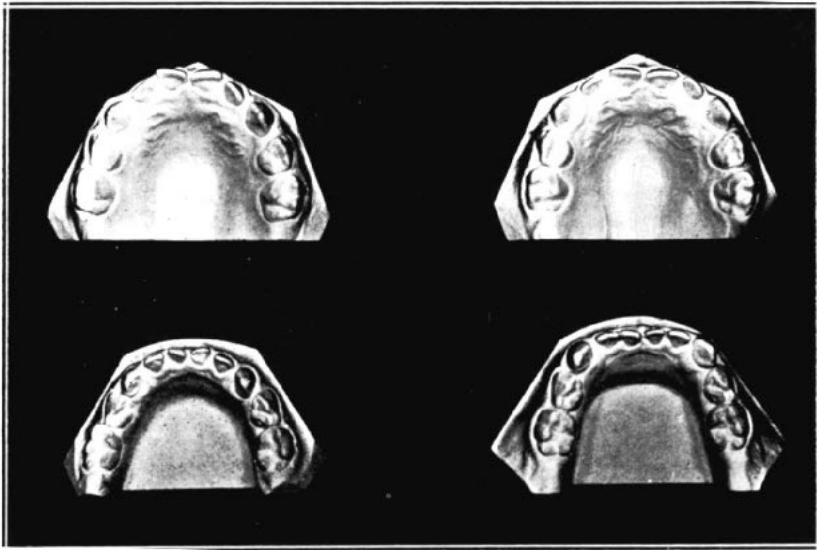


Figure 7

9. Co-operation:

Good.

10. Models made immediately after removal of appliance.

11. Comments:

Due to the age of the patient the wearing of intermaxillary elastics depended upon the watchfulness of the nurse. I would say that they were probably not worn more than half the time.

This malocclusion was the result of stomach sleeping. Of course the habit in sleep is now on the back. This young fellow was a tartar but the work was completed without a tear. After six months the jaw relationship is normal in spite of the fact that no retainers were used.