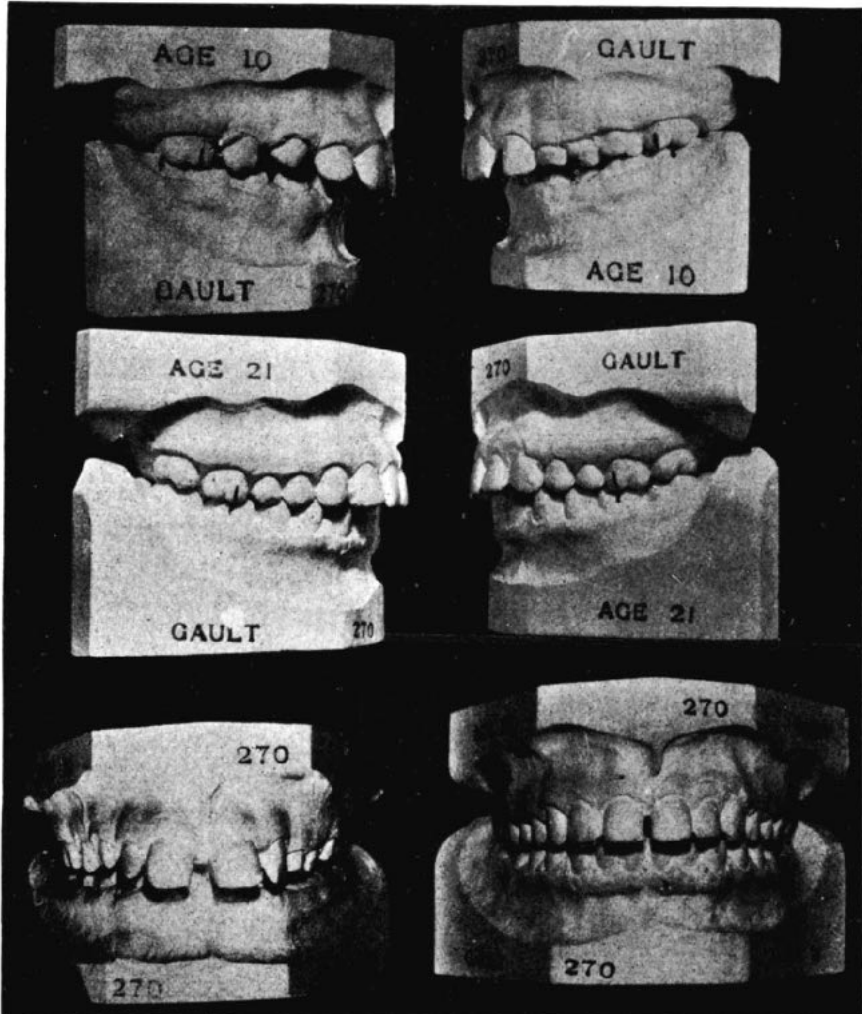


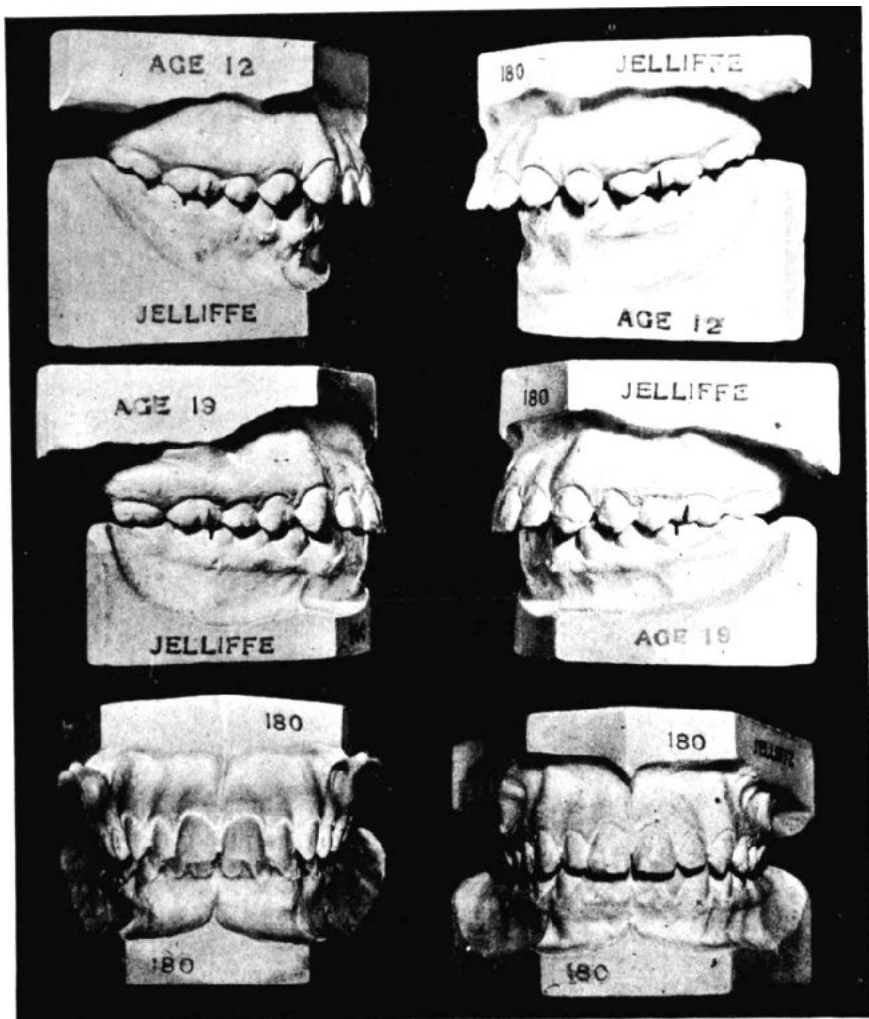
## Reports of Cases



Case 1

Do corrected overbites remain stable in the years succeeding orthodontic treatment? That a favorable prognosis may be rendered in many of these cases is shown by this report which is offered by Robert H. W. Strang of Bridgeport, Connecticut. The second series of models in all of these cases was taken several years after all appliances had been removed .

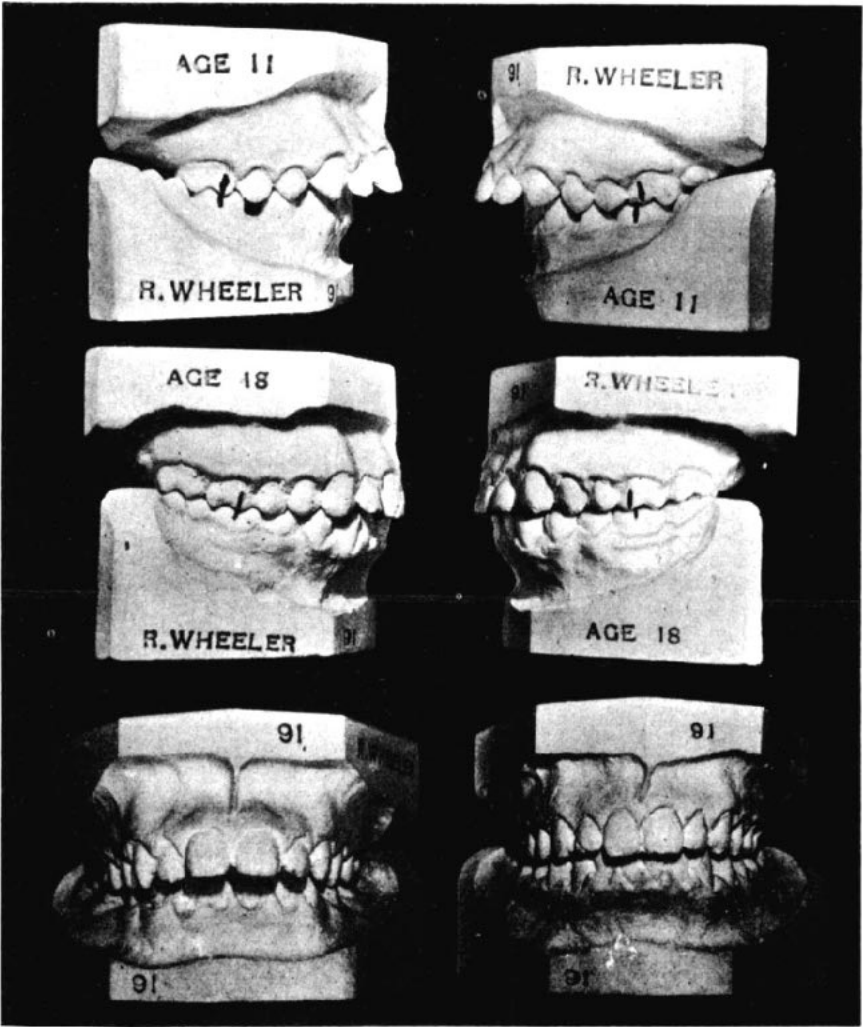
Case No. 1. (Gault) This case was treated by the use of a bite plate placed in position in conjunction with ribbon arch appliances and used throughout active treatment. The plate was considered necessary because



Case 2

the profile photographs of the patient showed a lack of vertical growth below the nose indicating an infraocclusion of the molar and deciduous molar teeth. The incisor teeth of both dentures were also depressed to a limited degree by appliance action.

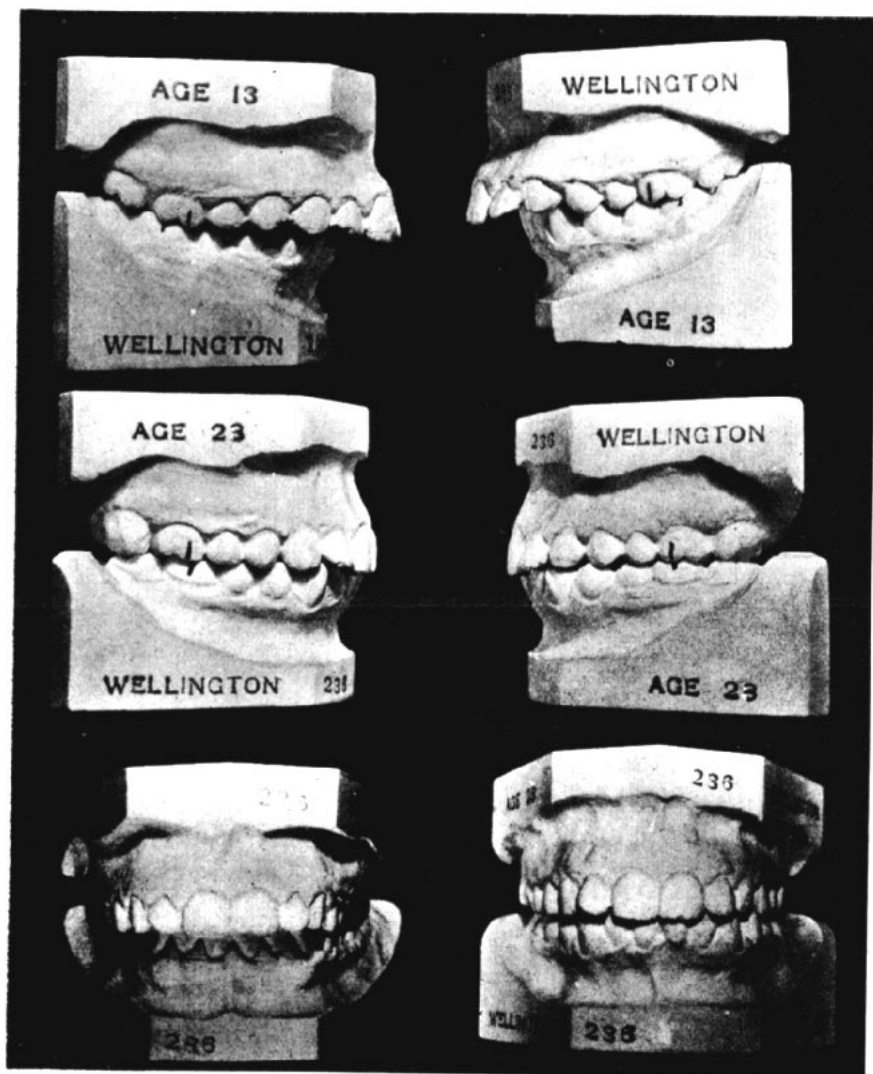
Case No. 2. (Jellife) This case was treated by the pin and tube appliance and a bite plate was used to gain vertical growth in the molar region.



Case 3

In reviewing this treatment it would appear as if some shortening of the incisors was indicated also, but at that time no appliance was available for effecting this tooth movement.

Case No. 3. (Wheeler) The appliances used on both dentures of this case were the plain round archwires, .040" in diameter, plain bands with spurs for rotations and brass ligatures for traction. A bite plate was used during



Case 4

the retention period. The "working retainer" was placed upon the mandibular denture, at the end of active treatment, to obtain the correct axial inclination of the incisor teeth.

Case No. 4. (Wellington) A plain round expansion archwire, with plain bands and brass ligatures, was used on the maxillary denture and a ribbon arch appliance, (one of the first cases in which this was applied by the operator), was adjusted to the mandibular teeth for stationary anchorage. A bite plate was used throughout active treatment. The models of the corrected case were taken at age 23, 5 years after all appliances were removed.