

Rapid Expansion Of The Maxillary Dental Arch And Nasal Cavity By Opening The Midpalatal Suture

ANDREW J. HAAS, D.D.S., M.S.

Cuyahoga Falls, Ohio

INTRODUCTION

Orthodontic and rhinologic literature from 1860 to about 1930 reveals considerable controversy over the desirability and possibility of splitting the hard palate at the midsagittal suture as a means of widening the dental arch and the nasal cavity. The findings in this paper are based on two rather distinct sources; the first, an animal study at the University of Illinois¹⁹; the second, a group of patients selected from the author's private practice.

The animal study was designed to determine if the midpalatal suture could be opened and, if so, to what extent. Also what would be the attendant effects of such an operation on contiguous oral and nasal structures? Another question suggesting itself was, "What, if anything, occurs in the mandible coincidentally with the maxillary changes?"

Based on certain encouraging findings produced by the animal study, it seemed logical to attempt to extend these benefits to those cases of malocclusion that require more than orthodontics, namely, facial orthopedics. Those cases where it was desirable or almost imperative to alter the denture base, if successful treatment was to be attained, formed the basis for selection of the clinical cases.

REVIEW OF LITERATURE

The contracted maxillary arch has always been of major concern to those

men who have interested themselves in the regulation of the teeth and the rapid expansion of this arch by forceful separation of the maxillae has been discussed for almost one hundred years. The first reference to the procedure that the present writer could discover was that of E. H. Angell⁷ in 1860. He fashioned a jackscrew across the roof of the mouth of a fourteen year old girl with its ends bearing against the first and second bicusps of one side and against only the second bicuspid on the other. The patient was directed to turn the nut of the jackscrew twice daily. Angell described the results as follows: "These directions were industriously followed and at the end of the two weeks the jaw was so much widened as to leave a space between the front incisors . . . showing conclusively that the maxillary bones had separated, while the left lateral incisor (previously in cross-bite) had been brought completely outside of the anterior teeth." An editorial by J. H. McQuillen which accompanied the article was prophetic of the arguments that repeatedly were to be raised against the operation: "With no disposition to assert that such a thing is utterly impossible, yet taking into consideration the anatomical relations existing between the right and left superior maxillae and the other bones of the face with which they articulate, such a result appears exceedingly doubtful. Even admitting the impression of the writer to be correct, it would be a very strong

argument against the use of such an apparatus, for surely the irregularity of the teeth is a trifling affair as compared with the separation of the maxillae, which could not take place without inducing serious disturbance in the surrounding hard and soft parts."

The procedure was, nevertheless, attempted with varying success by Farrar (1888), Goddard (1893), G. V. Black (1893), Monson (1898), G.V.I. Brown (1903), Ottolingu (1904), N.M. Black (1909), Landsberger (1910), Willis (1911), Wright (1912), Barnes (1912), Hawley (1912), Pullen (1912), Schroeder-Bensler (1913), Dewey (1914), Huet (1926), and Mesnard in 1929. Following this there was an almost complete abandonment of the method, at least in the United States, which was probably due to the widespread acceptance of a functional concept of development.

This concept held that, if the teeth were gently moved into their proper relations by conservative orthodontic means and if vigorous function followed, bone would grow to support them. Further than this, it was believed that such a widening of the dental arch resulted in an increase in the width of the nasal passages.

In spite of frequent failures to attain these objectives, such methods remained popular and almost unchallenged until 1938 when the staff⁶ of the Department of Orthodontics, University of Illinois, published the findings of an x-ray appraisal of treated orthodontic cases. Among the conclusions drawn from that study appeared the statement: "Actual bone changes accompanying orthodontic management seems to be restricted to the alveolar process." Since that time repeated investigations of a similar nature have verified the observation that changes induced by orthodontic methods in the dental arch and in the alveolar process

which holds them do not extend into the supporting bone. This means that there is no accompanying change in the nose.

Recently Moore²⁹ has suggested the possibility of changing the facial pattern by utilizing extraoral anchorage. Ricketts³³ has strongly stated his belief that extraoral anchorage can actually cause the entire maxilla to be moved posteriorly.

The appliances that have been employed by various men for the rapid separation of the maxillae have differed mainly in their methods of attachment to the teeth. Angell, as has been noted, merely fashioned a jack-screw between the teeth of the opposite sides of the mouth, probably by first making small pits in the teeth to receive the ends of the jack. Others have banded teeth and fastened the jack to the bands and still others have employed split plates of vulcanite rubber with bands and jack embedded in them. The principle is the same in all and each is capable of exerting great force.

Nearly all of the reporters who have employed the method have commented on the separation which appeared between the central incisors. In not a few cases this has been the cause of alarm and the treatment has been discontinued promptly.^{17, 20}

Others have disregarded this separation and continued to use the technique. They have failed, however, to comment on the subsequent behavior of the separated teeth. Recently, it has been shown by Derichsweiler¹³ and Korkhaus^{23, 24} that the teeth drift together again quite rapidly following their forced separation, even while the two maxillae are held apart. A number of writers have claimed that new bone formation filled the space between the separated maxillae, and this has been verified by both dissection and x-ray.^{5, 12, 13, 15, 23, 24}

According to Pfaff,³¹ Lohman,²⁶ and Derichsweiler,¹³ the first rhinologist to be interested in the separation of the maxillae was Eysell of Berlin, who, in 1886, suggested the possibility of influencing the inner conformation of the nose in this manner. He apparently met with complete skepticism on the part of his confreres and gave up the idea.

In 1903, G.V.I. Brown advocated the method for the specific purpose of obtaining greater nasal width. Brown wrote, "By the aid of pressure which is so gently applied that there is no pain and but little inconvenience, it is possible in all young persons to force the maxillaries apart by separating the median suture extending between the central incisor teeth and through the central part of the hard palate." Evidence of this was given by the fact that the central incisors were moved apart without any attachment to them or by any direct pressure being applied to them. Wright³⁷ made intranasal measurements on over thirty patients treated for nasal insufficiency by rapid expansion procedures. He measured the distance between antral walls below the inferior nasal concha and found increases up to 6.5 mm. All showed increases in width and from slight to marked improvement in intranasal respiration. Following Brown's method, Willis³⁶ reported a case of a female unable to do physical work because of difficulty in breathing. Using Brown's technique he separated the maxillae in three weeks to a distance that allowed the passing of a lead pencil barrel between the central incisors. Illustrations of plaster models verify this.

Derichsweiler¹³ and Korkhaus^{23, 24} have described the rapid spreading of the palatal suture on patients in their practices. The report of Derichsweiler is based on eighty cases and covers not only the separation of the maxillae and

the central incisors but also the deposition of bone at the suture, the expansion of the nose and the descent of the hard palate.

Debbane¹² in a recent radiographic and histologic study of the effect of orthodontic expansion of the midpalatal suture of the cat employed continuous and intermittent intercanine forces for a period of sixty-three to seventy days. He found increases in intercuspid width ranging from 4.5 mm to 8.5 mm. The maximum opening of the midpalatal suture however, was only 0.7 mm between the premaxillary bones, decreasing to zero in all cases between the palatine bones. These findings closely parallel those obtained by Dewey¹⁴ on dogs and seem to indicate that the carnivorous type of dentition is particularly adapted to withstand lateral pressure.

MATERIAL AND METHOD IN THE ANIMAL STUDY

The specimens used in the animal study were eight seven and three-fourths month old Duroc-Poland China pigs. They were litter mates weighing approximately one hundred and fifty pounds at the start of the study and two hundred and twenty-five pounds at completion, twelve weeks later. Six animals were designated as experimental, two as controls. The pig was chosen because it is an omnivore and able to withstand the experimental conditions of the study. It was further believed that animals of that age and size would have attained much of their ultimate jaw growth in width. The findings of the study were based on—

1. serial plaster casts of the jaws
2. vital staining of the bones
3. coronal serial cephalometric roentgenograms
4. embedded and sectioned tissue blocks
5. dissection of wet tissue specimens.

The appliance was an acrylic split palate with a jackscrew across the midline. It was anchored by posts inserted into deep pits prepared on the lingual surfaces of four teeth on each side of the dental arch. The appliances were expanded 1.8 mm each adjustment. Seven or eight adjustments were made over a ten day period giving about 12 to 15 mm of total extension.

Dental casts and serial cephalometric roentgenograms were made before, during and at completion of appliance manipulation. Alizarin injections were given after appliance regulation at four, fourteen, and thirty day intervals. Portions of the maxilla were embedded in polyester resin and sectioned. Others were dissected in the wet state and photographed.

FINDINGS IN ANIMAL STUDY

General The animals gave little or no indication of pain during the tightening of the screw and following the initial adjustment the maxillae offered little resistance to spreading. The opening of the suture was detected by passing needles through it and also by laying back a flap of palatal tissue for direct observation.

Dental Casts Increases of up to 15 mm in upper arch width were recorded in less than two weeks. The mandibular teeth tended to follow the maxillary teeth expanding without any direct appliance force.

Wet Specimens In the alizarinated specimens the new bone growth in the suture stained very deeply, while resorbing spines on the margin of the old suture easily delineated this new increment of bone. This bone was formed rapidly, completely bridging the gap in five weeks in one of the animals (Figure 1). Specimens obtained from animals sacrificed soon after expansion demonstrated considerable spacing of

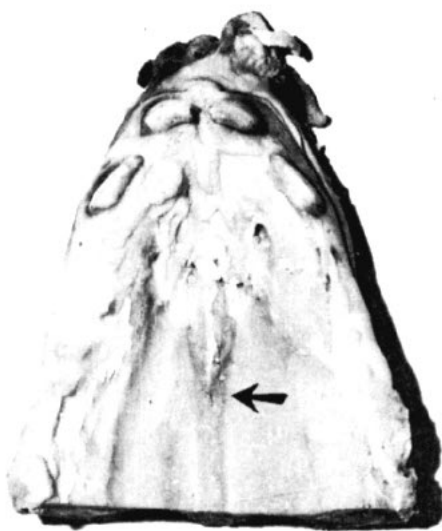


Fig. 1 This specimen shows the typical staining effect on the midpalatal suture in the experimental group. Note the deeply staining core of new bone with the old suture margins being delineated by white lines of resorption.

central incisors. Specimens of those sacrificed at a later date revealed that these spaces closed rapidly by tipping of the incisors toward the midline. Early opening of the suture was scissors-like in nature, while force continued for a longer period of time produced a more parallel opening.

Embedded Tissue Blocks Sections of experimental animals showed a marked thickening of the nasal septum at its articulation with the palatal crests of the maxillae. They demonstrated a bending of the alveolar processes with a lowering of the palatal vault. The teeth receiving the force of the appliance were tipped laterally (Figure 2).

Cephalometrics Coronal headplates of the experimental animals revealed some dramatic changes. These changes were recorded by making interconchal measurements across the fourth premolars (Figure 3). Internasal width increased up to 7 mm in one case. In another, 3

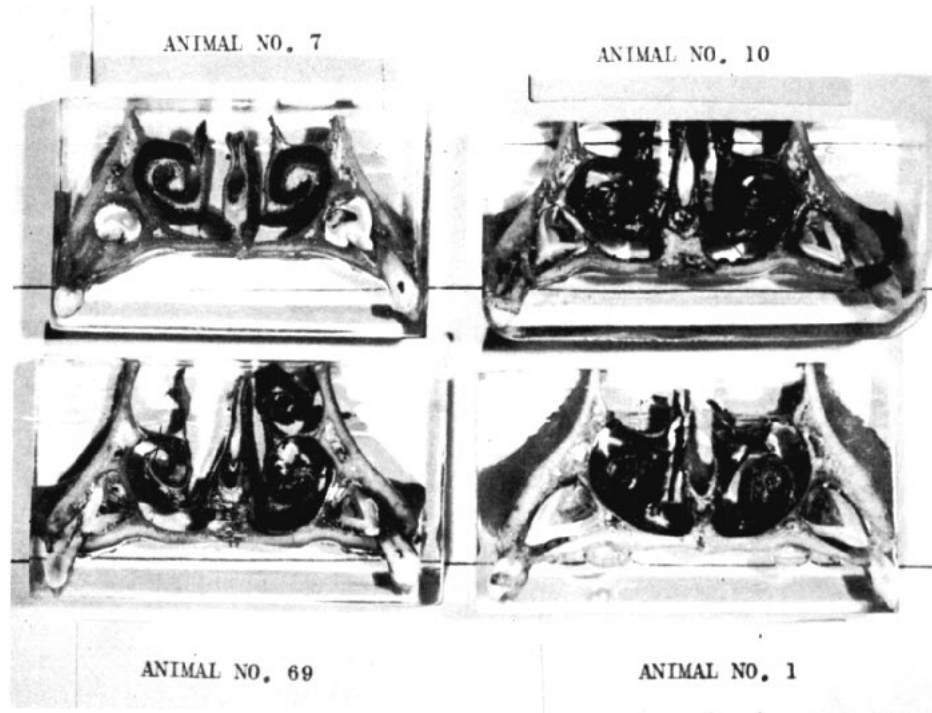


Fig. 2 Embedded tissue blocks of a control animal (No. 7) and three experimental animals show corresponding cuts through the first premolar region. Note the difference in the proximity of the plane to the palate. Further note the increased width of the base of the nasal septum formed by the palatal crests of the maxillae in the experimental animals.

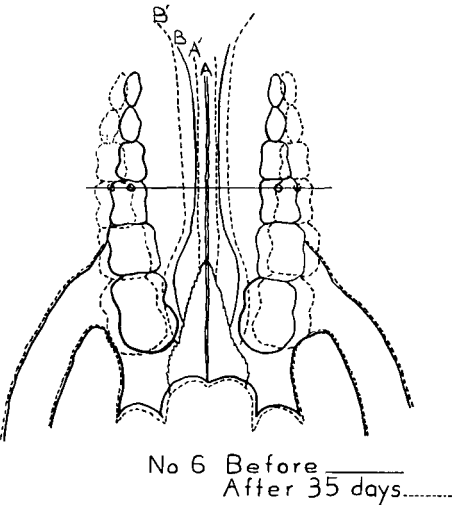


Fig. 3 Tracings of serial coronal headplates of an experimental animal superimposed on the vomer and registered on a line through images of amalgam implants. Note the increase in palatal width as well as the lateral movement of the shadow of the inferior concha (B, B') and suture margins (A, A').

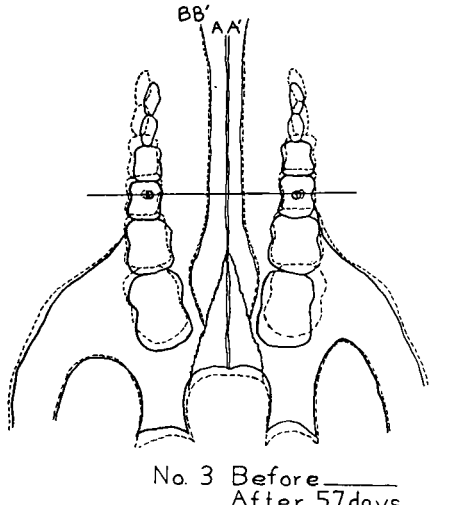


Fig. 4 Tracing of serial coronal headplates of a control animal superimposed as in Fig. 3. Note the slight increase in arch length and in the forward growth of the maxilla to gain space for second molars while the shadows of the inferior concha B, B' remain stable.

mm of intranasal space was achieved in forty-eight hours. Over a fifty-seven day period in one of the control animals (Figure 4) there was an increase in upper arch width of 3.6 mm yet no measurable change in nasal width.

The general conclusion that seems to be indicated by this investigation on pigs is that the midpalatal suture can be opened to a degree sufficient to cause a significant widening of the maxillary dental arch while at the same time increasing intranasal capacity. Further, the mandibular dental arch will expand a significant amount in response to altered natural forces.

CLINICAL STUDY

MATERIAL AND METHOD

With courage gained from the findings in the animal study the author began to selectively use a similar palate splitting operation in his clinical practice. The animal study indicated that this procedure might be of particular value in treating cases of severe maxillary compression where teeth are already in labial and buccal inclination and even in crossbite of the buccal teeth due to inadequacy of the bony base. This type of malocclusion has long been one of the greatest challenges in orthodontic therapy; unless the patient enjoyed extraordinary growth it has usually been doomed to relapse.

Other patients who seemingly could derive benefit from midpalatal suture opening are the severe mouth breathers who are seldom aided by anything short of resection of the concha. Examining the frontal head film of such a patient demonstrates among other things a very narrow nasal aperture literally filled by the concha crowding against an often deviated septum. Increasing intranasal capacity should facilitate nasal respiration and thus contribute to better general health.

It seems logical that such a procedure would give the clinician a tremendous assist in the treatment of his most difficult problem—the Class III case. Consider the advantage of correcting the usual bilateral crossbite associated with these cases in several weeks time.

The clinical aspect of this study involves the author's experience in the treatment of forty-five patients with maxillary or nasal insufficiency. Appliance design, rate of screw manipulation and objectives varied in many of these cases. Ten cases were selected for this report as they represented a similar purpose in treatment objectives, appliance design and screw manipulation. Five cases are male and five are female. The youngest patient was nine years of age; the oldest was eighteen.

The areas chosen for study were similar to those examined in the animal study, namely, the changes induced in the maxilla, nasal cavity and mandible.

Observations were made on frontal and lateral cephalometric headplates, dental casts, photographs, and from patients' comments on subjective symptoms. The appliance that was used in effecting the splitting is seen in Figure 5. It is fabricated by a direct-indirect technique. Bands are made, or selected for, and positioned on the upper permanent first molars and either the first premolars or the deciduous first molars. An impression is made, the bands transferred to it and a stone working model poured. Connecting bars are soldered to the buccal and lingual surfaces of each pair of bands. The lingual bars are extended anteriorly and posteriorly. These extensions are directed palatally to act as lugs to anchor the bands and bars to the split acrylic palate.

An expansion screw is mounted on a piece of base plate wax perpendicular to the long axis of the screw. The base plate wax is trimmed to conform to the contour of the palate in order that the

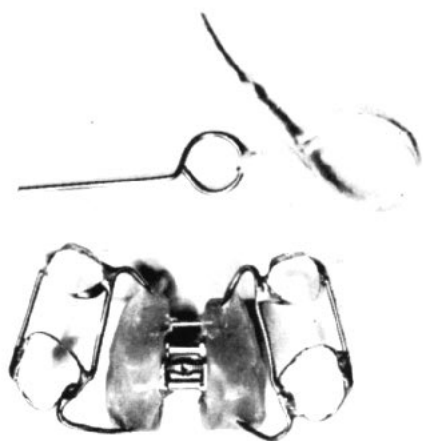


Fig. 5 Pictured is a fixed split palate appliance as it appears at stabilization. The .040 bar anterior to the screw was added when enough palatal width had been attained. At the top of the picture is the key that is used to turn the screw.

center of the screw lies directly over the midline and the lateral margins of the screw are raised about a millimeter from the palate. Elimination of the wax at a later stage gives the needed split in the appliance. Quick cure acrylic is applied to the cast by a dust-on method and built up to cover the screw and the anchor lugs of the lingual bars. The appliance is then separated from the stone model and trimmed making sure that all edges and corners that will contact palatal mucosa are well rounded.

An acrylic body is preferred rather than an all wire framework as much of the expanding force is exerted against the alveolar process and base bone rather than just teeth. Since the horizontal force of the screw against the inclined lateral walls of the palate would tend to displace the appliance, it would seem that if maximum suture opening is to be realized the appliance must be fixed. A removable expansion screw appliance will primarily tip teeth laterally.

Manipulation of Appliance

Most expansion screws available to-

day are calibrated to give 0.8 to 1 mm extension for each full turn of the screw. The construction of the screws is such that they must be turned a quarter turn at a time.

The technique that has given the author the most consistent results to date is as follows: after the appliance has been cemented, the screw is given one full turn over a fifteen minute period, a quarter turn each five minutes. A parent should be permitted to make the final turn to be certain he or she will understand the procedure. To avoid accidental swallowing or inspiration of the key a string should be attached to it and the parent instructed to wrap or loop the string about the fingers. For ease of manipulation, in construction the screw is so oriented that the key to operate it is inserted anteriorly and moved in a posterior arc.

The parent is instructed to turn the screw a quarter turn in the morning and a like amount in the evening. The patient is observed at approximately 7, 10, 14, 18, and 21 day intervals and the screw manipulation is discontinued when sufficient palatal width has been attained. As in many orthodontic procedures it seems best to overtreat to allow for subsequent uprighting of tipped teeth and recontouring of bent alveolar process.

To prevent the screw from turning back during function the appliance is stabilized the same day manipulation is stopped. A disc or bur is used to score both separated acrylic masses and a piece of .040 wire is fastened into these grooves across the palate with a dab of quick cure acrylic. The appliance is permitted to remain in place for approximately three months acting as a retainer to allow bone to be formed in the opened suture. The appliance is then removed and at the same sitting an acrylic palate processed from quick cure acrylic is inserted. The acrylic pal-

ate is subsequently worn throughout treatment and retention.

Lateral and frontal cephalometric headplates, intraoral occlusal films, intraoral photographs and dental casts were made just before the palatal splitting procedure began, at the time the appliances were stabilized to act as retainers, and again when the appliances were removed. Radiographic records are subsequently made on a check up basis until the case is completed.

CLINICAL FINDINGS

The patients rarely complain of discomfort. Inquiries made into subjective symptoms elicit astonishingly consistent replies even while making an effort not

to influence these replies. There is virtually unanimous agreement that the slight pressure felt when the screw is tightened is dissipated in minutes. Pressure is almost always felt at the alveolar process and vault of the maxillae, almost as frequently at the articulation of the maxilla, frontal and nasal bones. About half the patients cite pressure at the zygomaticomaxillary suture areas and a few at the zygomaticotemporal suture areas.

These pressure syndromes can be ascertained at the observation visits by giving the screw one or two quarter turns and asking the patient to point to the areas where pressure is experienced. Patients will usually notice from slight

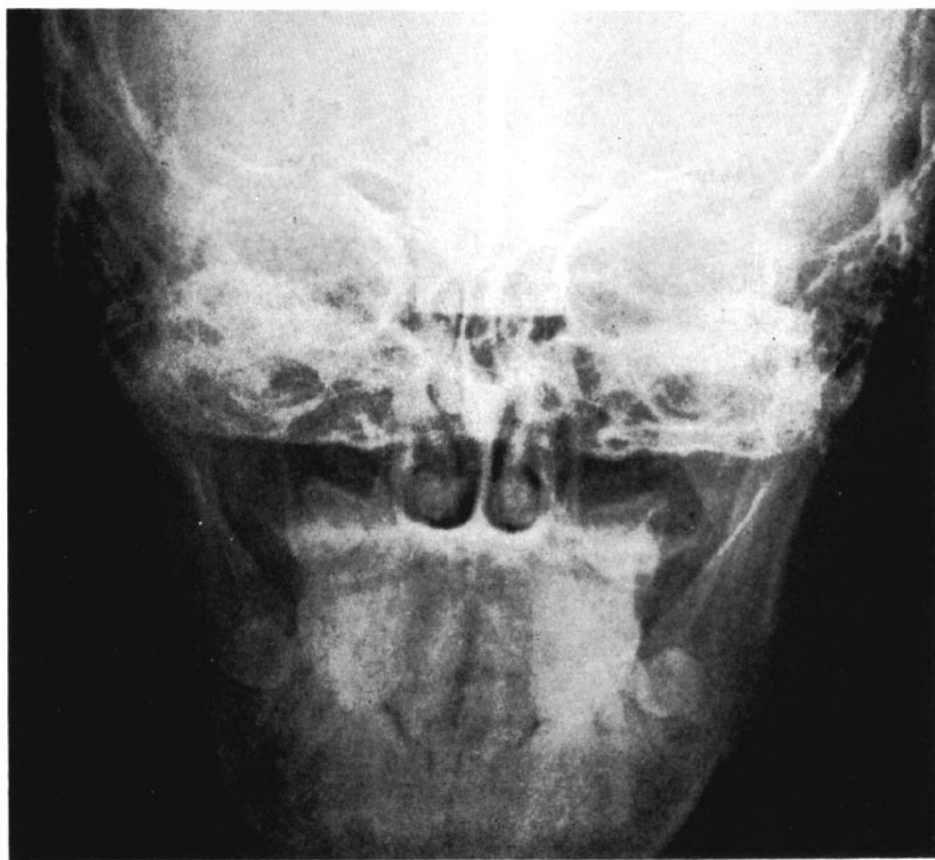

Fig. 6A

to marked improvement in nasal respiration depending on the severity of the nasal stenosis at the start of therapy. Those with the greatest degree of respiratory difficulty seem to notice the most improvement.

The soft tissue which lies immediately beneath the acrylic split palate presents a varied reaction to the operation. If in construction the appliance is carefully finished by rounding all edges of acrylic, the response of the tissue is good. At best no hypertrophy occurs; at the worst a moderate amount may occur, a reaction similar to that found in conjunction with the use of a Nance type palatal holding arch. If one is willing to accept the disadvantages attendant to applying all force directly to the teeth with an all wire frame-

work, soft tissue response is uneventful.

Frontal Headplate Finding

The frontal headplates present some of the most interesting findings associated with this study. Figure 6A and 6B are frontal headplates made before and after opening the midsagittal suture on a twelve year old male. In this particular case an 8 mm void was created between the maxillae at the intermaxillary suture. The nasal cavity was widened 4.5 mm and the unerupted third molars also demonstrated a 4.5 mm expansion. Serial frontal headplates for each patient were traced. Parallel vertical tangents were constructed to the points of greatest convexity on the lateral walls of the nasal aperture, the second or third molars,

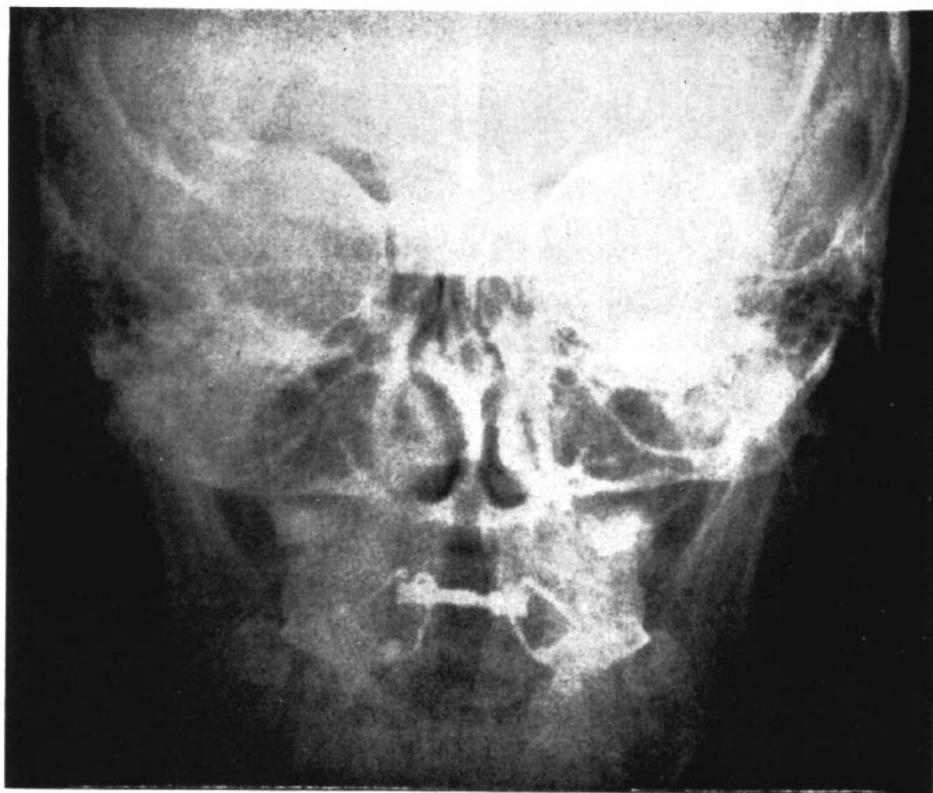


Fig. 6B

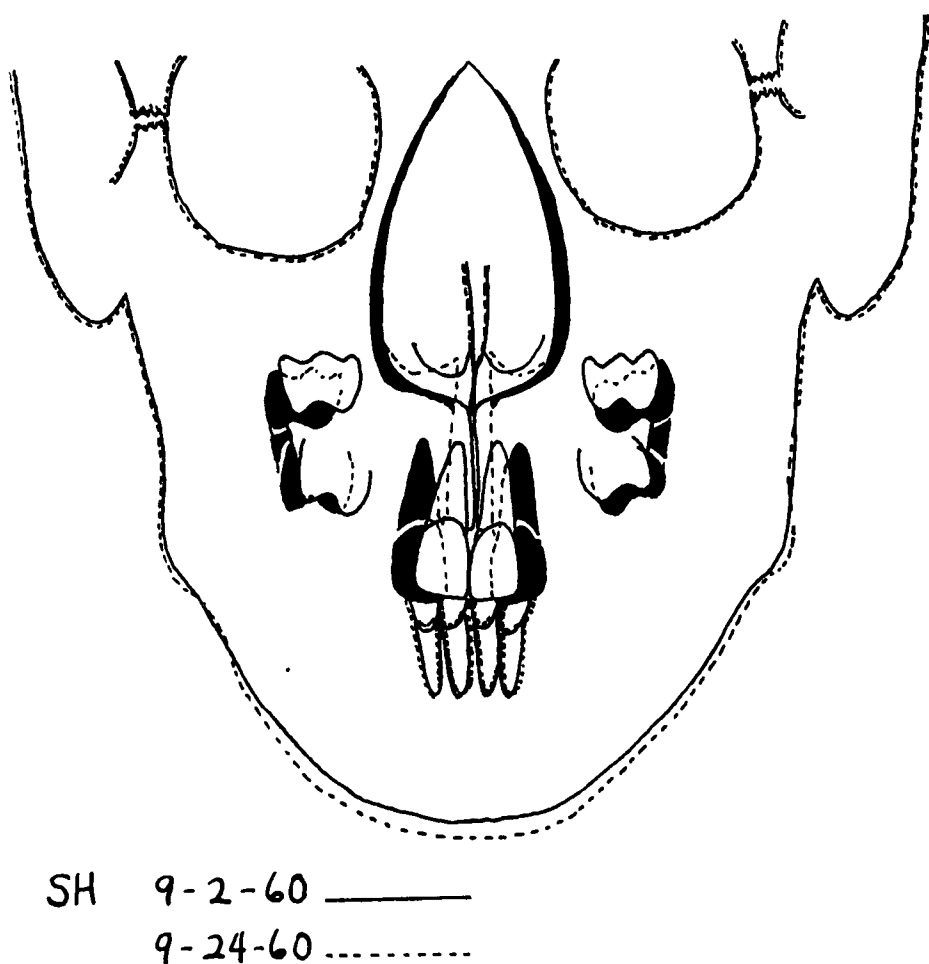


Fig. 7 A tracing of serial frontal headplates of a twelve year old male demonstrating a marked change in maxillary width over a twenty-two day period. The tracings were superimposed over cranial and mandibular outlines.

and the central incisors. A lineal measurement was then taken across each pair of tangents to record changes in nasal, intermolar, and interincisal width. The width of the suture opening can be measured directly and at various levels, e.g., between the palatal crests of the maxillae or at prosthion.

Two such tracings excluding the constructed tangents are superimposed in Figure 7. Note the marked maxillary and nasal changes occurring in twenty-two days. These changes are numerical-

ly recorded in Tables I and II. The shortcomings of making lineal measurements on the frontal headplates are realized. However, these measurements were made on or near midline structures and none were of a vertical nature. Also the remarkable consistency of these measurements in a series would seem to indicate that the error is comparable in all films of a series; thus the measurements have value on a relative rather than an absolute basis which is all that is intended.

TABLE I
Changes in Maxillary Width Following Opening of the Intermaxillary Suture

	Start nasal-intermolar		Stabilization max. defect Nasal-intermolar				Follow Up nasal-intermolar		
C. D.	28	60.5	(18)	6	32	66	(111)	32	65
S. H.	29	65	(22)	8	33.5	69.5	(107)	33	69
N. K.	30	58	(27)	6	32.5	62.5	(99)	32.5	62
L. W.	33.5	61	(18)	4.5	36	64.5	(122)	36.5	64.5
C. M.	28	57.5	(13)	4	30	59	(63)	30	59
S. W.	33	64	(20)	4	35	66	(256)	35	66
N. M.	32.5	60	(19)	3.5	35	62	(67)	35	62
D. B.	34	59.5	(28)	4	36	63.5	(49)	36	63.5
L. P.	36	64	(13)	4	38	68	(22)	38	67.5
J. W.	39.5	72	(12)	4.5	42	74.5	(464)	42.5	74.5

These ten cases illustrate the millimeter changes in nasal and intermolar dimension. The maxillary defect is a measurement of the void between the maxillae at prosthion at stabilization. The figures in parentheses indicate the number of days between taking headplates.

The explanation for the reaction of the central incisors to the spreading of the maxillae was the most challenging phenomenon in this study. (1) It was successively observed that the gap created between the central incisors was about one half as great as the distance the screw had been opened. (2) Tracings of frontal headplates demonstrated that the roots diverged a greater distance than the crowns during screw manipulation (Table II). (3) After manipulation ceased the roots continued to diverge while the crowns tipped toward the midline with a rapidity of movement suggestive of that seen in light wire therapy (Figure 8). (4) After the crowns drifted together the roots began to move medially so that the incisors eventually resumed original axial inclination (Figure 8, Table II). (5) This entire cycle, without benefit of unnatural forces, was completed in four to six months time even with incisors spaced as much as 8 mm after appliance manipulation.

Brodie⁷ reiterated that bone should be considered to be connective tissue

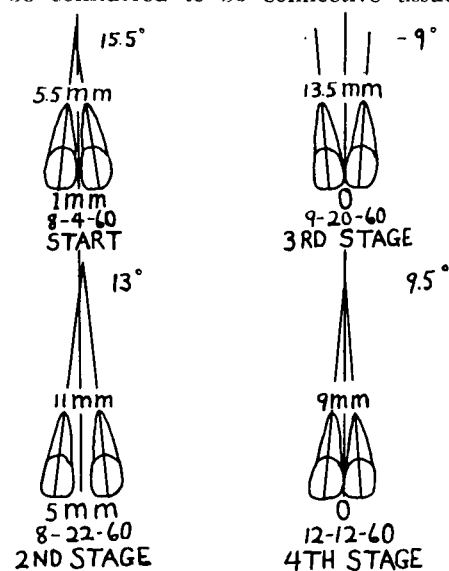


Fig. 8 These tracings show the action of the central incisors in case C.D. Note how the angle of inclination of the incisors changed from a $+13^\circ$ to a -9° in just twenty-nine days. In another fifty-three days it changed back to a $+9.5^\circ$.

TABLE II
Changes in Central Incisor Posture Following Opening of the Intermaxillary Suture

	root	Start crown	∠ of inc.	root	Stabilization crown	∠ of inc.	root	Early Follow Up crown	∠ of inc.	root	Later Follow Up crown	∠ of inc.
C. D.	5.5	1	15.5°	(18) 11	5	13 °	(29) 13.5	0	-9 °	(53) 9	0	9.5°
S. H.	6	0	7 °	(22) 14	6	3 °	(59) 15	0	-13 °	(48) 9	0	0°
N. K.	8.5	3.5	13 °	(27) 13.5	8	10 °						
L. W.	8	0.5	5.0°	(18) 13	4	-1 °				(122) 11	0	-3.5°
C. M.	6	0	12.0°	(13) 10.5	2.5	5 °	(63) 12	0	-3.0°			
S. W.	6	0.5	8.0°	(22) 10	3.5	6 °	(48) 10	0	-3.0°			
N. M.	7.5	0	7.5°	(19) 12	3.5	3.0°	(67) 14	0	-3.5°			
D. B.	8	0.5	5.5°	(28) 12.5	3	2.0°	(49) 13.5	0	-7.0°			
L. P.	7	0	8.0°	(13) 12.5	3.5	0.5°	(22) 14	2	-4.0°			
J. W.	6.5	0	10.0°	(12) 12	4.5	7.5°						

These ten cases illustrate the tremendous activity occurring between the central incisors. Interapical and intererown distances and changes in this distance are shown in millimeters. The angle of inclination is the angle formed by the long axis of each pair of central incisors. The figures in parentheses represent the number of days between taking headplates. No appliance of any kind ever touched the incisors during the time shown.

and not the unyielding structures we see in museums. He went on to hypothesize that orthodontic therapy might cause tensions in remote parts of the bone; recently he⁸ labeled one of these forces the transeptal fibers. These fibers are visualized as an integrated chain of periodontal-like fibers lying at a level somewhere below the gingival fibers and linking all the teeth in the dental arch together. The behavior of the central incisors in this study strongly suggests the existence of transeptal fibers with perhaps the presence of an elastic element.

Assuming the existence of these fibers the action of the central incisors might be explained as follows. (1) As the maxillae separated, the crowns of the central incisors began to move laterally and the transeptal fibers across the midline began to stretch. (2) Since these fibers are probably in the area of the lower third of the root, their pull causes the crowns of the incisors to start tipping medially while the roots begin diverging laterally with the fulcrum of this action being approximately in the middle third of the root, (Figure 8, Stage 2). (2) After appliance stabilization the continued action of these fibers causes the crowns to tip very rapidly toward the midline with the roots moving almost as fast laterally. Lineal measurements in Table II indicate the relationship between time and distance the crowns and roots move and the change in inclination of the incisors to each other. Figure 8, Stage 3 indicates the marked change in axial inclination which can occur in as little as four weeks. The fulcrum for this phase of the phenomenon is located closer to the root apices than during the time the screw is being extended. (3) When the crowns approximate, the class of leverage changes; the contracting crowns now become the pivot and the force of the tensed transeptal fibers

causes the roots to move medially toward their original position.

The frontal headplates also underscore the dramatic opening of the intermaxillary suture as witnessed by the void extending from the medial incisal edge of the central incisors superiorly through the articulation of the palatal crests of the maxillae and vomer. Table I indicates the width of this maxillary defect at stabilization. Subsequent headplates and occlusal films indicate that this defect is usually completely calcified in ninety days (Figure 9).

The obvious nasal result of spreading the maxillae is to increase internasal capacity. Table I establishes changes in nasal width ranging from 2 mm to 4.5 mm in from twelve to twenty-seven days of treatment. Succeeding frontal headplates demonstrate the remarkable stability of the increments of added nasal dimension. Changes in maxillary width were assayed by measuring between unerupted second or third molars (if the latter were present). The greatest increase in intertooth dimension was 5.5 mm, the least 1.5 mm. The intermolar change shows the same stability as does the internasal change. All the cases reported in Table I are still in retention. The data in Table I would also indicate that the opening of the intermaxillary suture is triangular in appearance with the base being toward the incisors and the apex in the nose. Most patients evince a similar pattern as case C.D. where the most inferior measurement of the maxillary defect at prosthion is 6 mm, the next highest across the molars is 5.5 mm and the most superior between the lateral nasal walls is 4 mm.

A measurement of the gap created between the palatal crests of the maxillae can also be used to determine the increase in nasal width; however, this area is later obscured by the healing process.

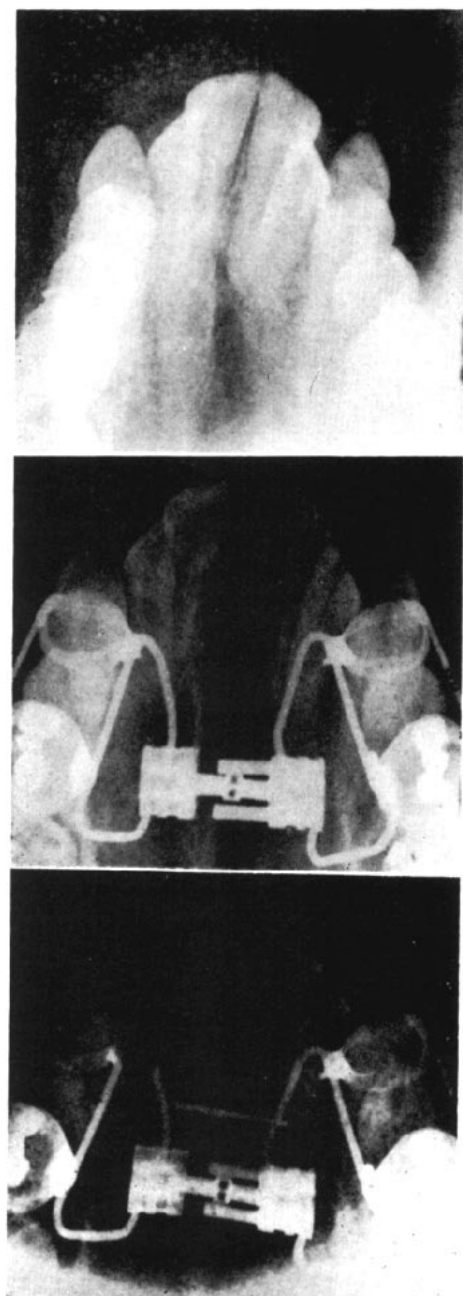


Fig. 9 (upper) is an occlusal exposure made prior to placement of the split palate appliance. (middle) The same patient twenty-one days later showing the large void created at the midpalatal suture. (lower) One hundred and seven days later showing complete calcification of the area.

The behavior of the maxilla was further scrutinized on tracings of the lateral headplates made before appliance placement and at stabilization, (Figure 10). The reaction of point A was of immediate interest. In all cases it moved forward and in five cases moved downward as well. Table III verifies this occurrence. Increases in the angle of convexity ranged from 1.5° to 8° , point A to facial plane measurement increased from 1 to 4 mm, and increases in angle SNA varied from 0 to 2.5° .

The tracing in Figure 10 raises the question of whether the increased severity of the Class II condition was not too much of a price to pay for the gain in arch length and greatly increased nasal ventilation. The angle of convexity increased 7° , point A to facial plane 4 mm and angle SNA 2° .

The answer may be provided in Figure 11 which indicates that during the four months following the splitting procedure, without any other appliances being placed, the angle of convexity decreased 4° , the point A to facial plane reading decreased 2 mm and angle SNA decreased 1° . This would seem to indicate that, as the maxillae move laterally, marked activity and adjustment must be occurring at the sutures of the cranial and facial bones with which the maxillae articulate. As sutures open and bones slide, the maxilla is displaced forward and sometimes downward. During the retention period this activity continues toward re-establishing the former proximity of the bones.

The forward movement of the maxilla can be of great benefit in the treatment of Class III and pseudo Class III cases. Figure 12 demonstrates a change in the Downs¹⁶ profile arc from slightly concave to slightly convex with the only treatment being the opening of the midpalatal suture. The al-

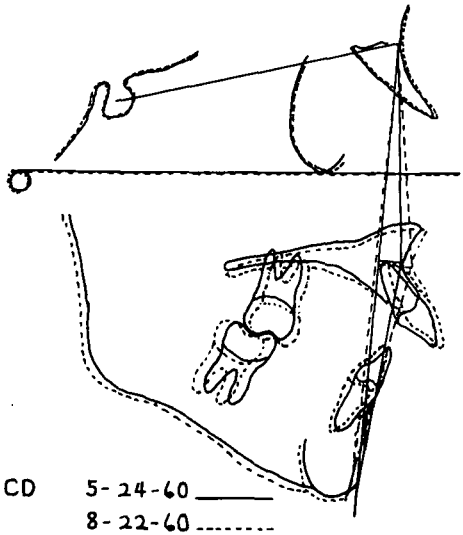


Fig. 10

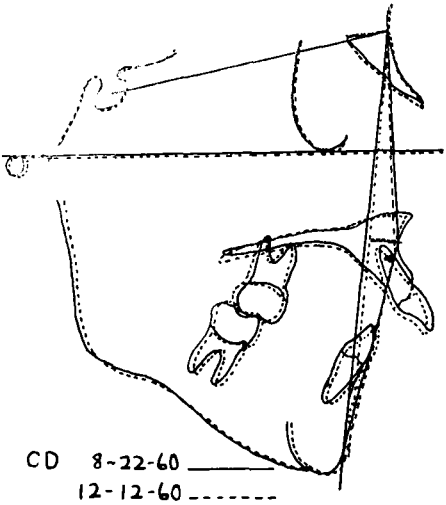


Fig. 11

tered position of the maxilla with concomitant disturbance of the occlusion also causes an opening of the bite with, of course, the corollary features of changes in mandibular plane angle and occlusal plane, posterior movement of pogonion and change in Y axis.

The response of the mandibular arch to splitting of the midpalatal suture was quite similar to that elicited in the animal study; namely, the mandibular teeth tended to follow the maxillary teeth by tipping laterally. Ten cases which had not received any treatment in the mandibular arch were selected. Inter canine and intermolar (first) widths were measured on the dental

casts before treatment and for varying amounts of time after treatment. In all cases the intermolar width increased from a minimum of 0.5 mm to 2 mm. Five cases showed no change in intercanine width, while four had increases of 0.5 mm to 1.5 mm, and one case lost .5 mm. There is no direct relationship between time involved and the amount of change in arch width.

GENERAL DISCUSSION
AND CONCLUSIONS

One of the most interesting findings in this study was the ease and extent to which the midpalatal suture can be opened. It was also surprising to find

TABLE III

	C.D.	S.H.	N.K.	L.W.	C.M.	S.W.	N.M.	D.B.	L.P.	J.W.
Convexity (deg.)	+7	+8	+3.5	+5	+5	+2	+3	+2	+3	+1.5
Pt. A to FP (mm.)	+4	+4	+2	+2.5	+2.5	+1	+1.5	+1	+1.5	+1
SNA (deg.)	+2	+2.5	0	+1.5	+1	+1.5	+1.5	+3.5	+1	+1.5

These ten cases illustrate the anterior displacement of the maxilla immediately after opening of the midpalatal suture ceased.

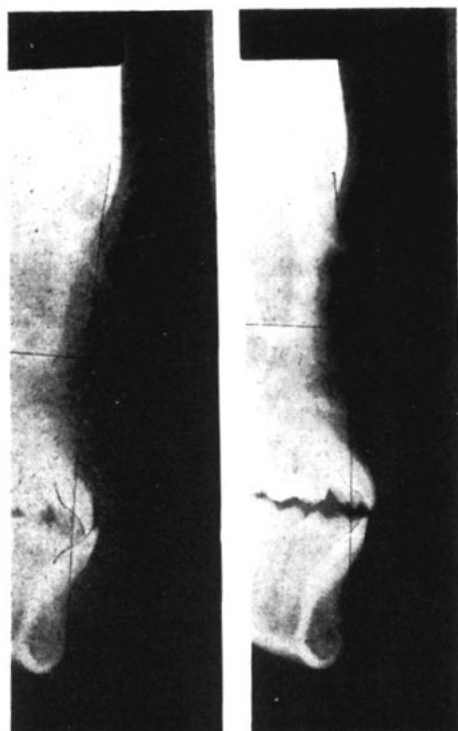


Fig. 12

an almost complete absence of pain. Derichsweiler,¹³ Korkhaus²² and others have commented on this lack of pain. Korkhaus reports the most common sensation to be pressure at the bridge of the nose.

Black⁵ advanced the theory that, in addition to the separation, the palatine processes of the maxillae were also lowered as a result of the outward tilting of the alveolar processes. He felt that it was this action that resulted in straightening of the deviated septum. Brown¹⁰ believed that when the suture opened the maxillae moved laterally and the deviated septum dropped down into the space between them. This study tends to support the former view. In addition to the lowering of the palatine processes it was apparent that as the suture opened new bone was laid down very rapidly; this would les-

sen the possibility of the septum occupying the space.

That the increment of arch width added by opening the midpalatal suture is permanent would seem to be assured through the repair of the defect by new bone. The permanency of the increment added by tooth movement and alveolar bending is questionable. Thorne³⁵ reported on twenty-eight cases subjected to opening of the midpalatal suture with a fixed split palate appliance. These cases were retained for varying amounts of time. Upon checking the stability of these cases one to two years after retention he found twenty-three cases showed either no change or an increase in the gained apical base and nasal cavity widths. The five cases which demonstrated a decrease in gained apical base and nasal cavity widths had very short retention periods.

Measurements and observations made from the various methods employed in the animal and the clinical study indicate that, as the screw is extended in a fixed split palate appliance, the earliest gross reaction is a lateral bending of the alveolar processes. This is followed by a gradual opening of the midpalatal suture. The palatine processes of the maxillae then begin to move inferiorly at their free margins to cause a lowering in the palatal vault. Possibly the bracing action of the zygomatic buttresses cause the separation between the maxillae to be wedged-shaped, with the apex of the wedge being in the nasal cavity and the base in the same plane as the palatine processes. The central incisors behave in a completely incongruous manner. Rather than follow their respective maxillae the roots diverge more than the crowns as the screw is opened. During stabilization the roots continue to diverge while the crowns converge. This action was interpreted as being due to the presence of tran-

septal fibers.

Baker² in research on the pig showed that arrested maxillary development resulted in marked mandibular deformity. In the present study it was found that the mandibular teeth tended to follow the maxillary teeth by increased buccal inclination. The significant increase of buccal tilt was probably due to a combination of several factors. The forces of occlusion were altered by the expansion so that the normal lingual vector of force on the mandibular buccal teeth was lost and the lateral movement of the maxillae widened the area of attachment of the buccal musculature. This resulted in a change of balance between the tongue and buccal musculature. As Brodie⁷ observed, "The interaction of the forces of these two antagonistic muscle masses would dictate the size and form of the arches as well as the axial inclination of the teeth." A diminishing influence of the buccal musculature would permit the tongue to exert a relatively greater force from within, manifesting itself in an increased buccal axial inclination of the mandibular teeth as well as an expansion of the arch. There is also the possibility that the thickness of the appliance, which was up to three-fourths of an inch, caused a downward displacement of the tongue during rest as well as occlusion, thus increasing its lateral force on the mandibular buccal teeth.

This procedure has been most beneficial in the treatment of Class III and psuedo-Class III malocclusions, cases of severe maxillary compression (including some cleft palate patients) and patients with pronounced nasal insufficiency. The operation is by no means a complete treatment for any of these patients. However, having orthopedically moved the maxillae into a more favorable relationship with the mandible expedites the treatment of the

patient. It reduces the amount of tooth movement necessary when fixed appliances are placed. The procedure not only results in an increase in dental arch width and hence its overall length but, also of equal importance, carries the attachment of the buccinator muscles laterally to a position where its crushing force on the mandibular arch is diminished. The latter would make judicious mandibular expansion a far safer maneuver.

In addition to these advantages must be mentioned the coincidental widening of the nose and lowering of its floor both of which, according to other authors, frequently make nasal breathing possible in individuals who have been habitual mouth breathers.

2637 17th Street

BIBLIOGRAPHY

1. Angell, E.H.: Treatment of Irregularities of the Permanent or Adult Teeth, *Dental Cosmos* 1: 1860
2. Baker, L.W.: The Influence of the Formative Dental Organs on the Growth of the Bones of the Face, *Am. J. Ortho.* 27: 489-506, 1941
3. Barnes, V.E.: Dental Impaction and Preventive Treatment, *Dental Cosmos* 54: 1-24, 1912.
4. Black, G.V.: Expansion of the Dental Arch, *The Dental Review* 7: Discussion 218-224, 1893
5. Black, N.M.: The Relation Between Deviation of the Nasal Septum and Irregularities of the Teeth and Jaw, *J.A.M.A.* 52: 943-945, 1909
6. Brodie, A., Downs, W., Goldstein, A., and Myer, E.: Cephalometric Appraisal of Orthodontic Results, *Angle Ortho.* 8: 261, 1938
7. Brodie, A.G.: The Fourth Dimension of Orthodontia, *Angle Ortho.* 24: 15-30, 1954
- 8.—In seminar with postgraduate students at the University of Illinois
9. Brown, G.I.V.: The Application of Orthodontia Principles to the Prevention of Nasal Disease, *Dental Cosmos* 45: 765-775, 1903
- 10.—The Surgical and Therapeutic Aspect of Maxillary Readjustment With Special References to Nasal Stenosis, Hare Lip, Cleft Palate, and Speech, *Dental Cosmos* 51: 7-17, 1909
11. Dean, L.W.: The Influence on the Nose

- of Widening the Palatal Arch, *J.A.M.A.* 52: 941-943, 1909
12. Debbane, E.F.: A Cephalometric and Histologic Study of the Effect of Orthodontic Expansion of the Midpalatal Suture of the Cat, *Am. J. Ortho.* 44: 187-218, 1958
 13. Derichsweiler, H.: "Die Gaumenrautsprengung", Fortschritte der Kieferorthopädie Band 14: Heft, 1953
 14. Dewey, M.: Development of the Maxillae with Reference to Opening the Median Suture, *Items of Interest* 35: 189-208, Discussion 271-282, 1913
 - 15.—Bone Development as a Result of Mechanical Force. Report on Further Treatment in Attempting the Opening of the Intermaxillary Suture in Animals, *Items of Interest* 36: 420-432, Discussion 432-438, 1914
 16. Downs, W.B.: Analysis of the Dentofacial Profile, *Angle Ortho.* 26: 191-211, 1956
 17. Farrar, J.N.: Irregularities of the Teeth and Their Correction, Volume 1: Chapter XVI 182-185, New York, N.Y., 1888
 18. Goddard, C.L.: Separation of the Superior Maxilla at the Symphysis, *Dental Cosmos* 35: 880-882, 1893
 19. Haas, A.J.: Gross Reactions to the Widening of the Maxillary Dental Arch of the Pig by Splitting the Hard Palate, *Thesis, University of Illinois*, 1958; Unpublished.
 20. Hawley, C.A.: A Study in Maxillary Movement, *Items of Interest*, 34: 426-451, 1912
 21. Huet, E.: Treatment of Imperfect Frontal Development of the Superior Maxilla by Separation at the Symphysis, *Dental Surgeon* 23: 665-668, 1926
 22. Korkhaus, G.: Discussion of Report: A Review of Orthodontic Research (1946-1950), *Internat. D. J.* 3: 356, 1953
 23. In seminar with postgraduate students in orthodontics at the University of Illinois: October, 1956
 24. Present Orthodontic Thought in Germany, *Am. J. Ortho.* 46: 187-206, 1960
 25. Landsberger, R.: Indications for the Expansion of the Maxilla, *Dental Cosmos* 52: 121, 1910
 26. Lohman, A.: A Treatment of Narrow Nasal Passages, *Dental Record* 35: 496-497 1915, *Register* 70: 14-16, 1916
 27. Mesnard, L.: Immediate Separation of the Maxillae as a Treatment for Nasal Impermeability, *Dental Record* 49: 371-372, 1929
 28. Monson, G.: Constricted Vaults, *Dental Cosmos* 40: 914-920, 1898
 29. Moore, A.W.: Treatment Factors in Class II Malocclusion, *Am. J. Ortho.* 45: 323-352, 1959
 30. Ottolengui, R.: Spreading the Maxillae Versus Spreading the Arch, *Items of Interest* 26: 836-855, 1904
 31. Pfaff, W.: Stenosis of the Nasal Cavity Caused by Contraction of the Palatal Arch and Abnormal Position of the Teeth: Treatment by Expansion of the Maxilla, *Dental Cosmos* 47: 570-573 1905
 32. Pullen, H.A.: Expansion of the Dental Arch and Opening the Maxillary Suture in Relation to the Development of the Internal and External Face, *Dental Cosmos* 54: 509-527, 1912
 33. Ricketts, R.M.: The Influence of Orthodontic Treatment on Facial Growth and Development, *Angle Ortho.* 30: 103-133, 1960
 34. Schroeder-Bensler: The Treatment of Narrow Nasal Passages, By Lohman, *Dental Cosmos* 35: 496-498, 1915
 35. Thorne, N.A. Hugo: Expansion of Maxilla. Spreading the Midpalatal Suture; Measuring the Widening of the Apical Base and the Nasal Cavity on Serial Roentgenograms, *Abst. Am. J. Ortho.* 46: 626, 1960
 36. Willis, F.M.: Rapid Separation of the Superior Maxillary Bones to Relieve Deflected Nasal Septum and Contracted Nares, *Dental Cosmos* 53: 784-786, 1911
 37. Wright, G.H.: I. A Group of Deformities of the Nasal Respiratory Tract, Coincident with Dental Irregularities. II. A New Instrument for Comparative Measurements, *Dental Cosmos* 54: 261-269, 1912