

Evaluation Of Cervical Anchorage Force In Treatment

S. J. KLOEHN, D.D.S.,

Appleton, Wisconsin

The introduction of the classification of malocclusion by Dr. Angle has frequently been credited for bringing order out of chaos in orthodontics. The order that was produced may be questionable, but the classification did provide a basis from which to start studies of similarities and variations and to provide better communication. The inferences and assumptions presented as facts for treatment planning and therapy based on classification impeded orthodontic progress almost as frequently as they stimulated. This was not primarily from any errors in the classification, but rather from the ever present concept of similarities of each classification with aims for providing rules to be followed blindly in treatment planning and appliance therapy.

For example, it was assumed the correction of a Class II malocclusion was successful when the maxillary and mandibular teeth were placed in correct alignment to each other and in correct interdigitation to their antagonists without much consideration about which teeth were moved and where. It was assumed appliance force, plus normal functioning relationship of the teeth, would stimulate growth of the mandible and the musculature providing the patient with the intended facial balance and denture stability.

The literature contains some evidence of such treated cases which were successful. However, a further analysis of the literature reporting frequent changes in appliances indicates all was not well. If necessity is the mother of invention, the failures in treatment

must have been frequent because of the many changes. It is interesting to note that many changes in appliances were directed toward increasing stability of the teeth intended for anchorage and toward stimulating tissue changes around those teeth to be moved.

History is most valuable in guiding our thinking today as well as providing direction for our advances in the future. Unfortunately, most of us do not take time to acquaint ourselves sufficiently with the work of our predecessors, so well recorded in the literature. Ignorance of the past does not guarantee freedom from its imperfections, more probably it assures the repetition of the past errors. Practically all of the recent changes in appliances and therapy are merely reintroduction of similar methods used years ago including extraoral anchorage, light forces with long range, heavy forces with short intermittent reaction, heavy brackets and arch wires to produce strong torque force, light round arch wires with only tipping action and many gadgets. The work of early investigators and clinicians is to be complimented. However, many of their conclusions, favorable and adverse, need further investigation which can be done with greater accuracy with our more efficient methods and tools.

The cephalometric method of analysis has proven a most efficient tool for the study of normal and abnormal growth and for the study and observations of tissue response and changes resulting from various mechanical forces. It has focused our attention on

the many variations within the normal and abnormal, treated and untreated occlusions. Many studies and analyses have been made of the effects of treatment telling us which teeth were moved, how much, and where. Cephalometrics has provided facts and conclusions, some of which seem valid and others questionable. The method is accepted as being most accurate, but many interpretations are debatable leaving much confusion.

One need only study the many conclusions presented on the cephalometric studies of the past few years on extraoral anchorage treatment. There are some who demonstrated, most convincingly, the distal movement of maxillary teeth and the inhibiting of normal forward growth of maxillary teeth and alveolar process. There are others who claim to have evidence of retarding the forward growth of the entire maxilla. Some can report only holding the maxillary teeth while the mandible continues its forward growth. Several studies demonstrated no change in the relationship of the maxillary and mandibular teeth inferring that the method and appliance is ineffective.

All this might be most confusing and discouraging except for our knowledge of the many variables. This means variability in the size and ages of the samples, variations in the individuals studied, in the method of application of force and type of mechanical appliance; last and most variable is the method of analysis of the cephalometric tracings and measurements. The many conclusions presented direct our attention to the difficulty encountered, in a growing individual, of measuring movement of teeth by appliances.

Extraoral force applied with identical mechanics in the same direction and magnitude produces different results in different individuals. In studies where the sample was small and the re-

sults not so favorable, some investigators became critical of the method and recommended changes in appliances. For example, the assumption was made that the fixation of the arch and face bow produced an over-eruption or elongation of the maxillary molars and an undesirable change in the plane of occlusion. The correction of this was attempted by changing the union between the face bow and arch from a fixed union to one of a ball and socket arrangement or by advocating occipital anchorage to change the pull of the force in an upward direction in angles varying from thirty to fifty degrees. I have not found the elongation of the molars nor the opening of the bite a problem; a great many Class II malocclusions have a deep overbite in which increase of vertical dimension in the buccal segment is desirable.

There are open-bite cases which demand changes in treatment planning and appliance therapy. The orthodontist must recognize these and design his treatment and appliance accordingly. Recently, the statement was made that the tubes on the molar bands must be placed as close to the gingival portion of the band as possible to obtain the desirable tooth movement.

The opinions and assumptions increase when an extraoral appliance is used in conjunction with a full band appliance. There are too many to enumerate and, in my opinion, there is insufficient evidence to warrant analysis or discussion. Every patient and every malocclusion has variations which will produce different reactions to any given therapy. These many variations include the growth pattern of the face, the plane of occlusion, the functional stroke of the mandible, patient cooperation and last, but by no means least, the variation in construction of the appliance and the clinician's skill in adjustment and management of the

appliance and the patient.

I have not used cephalometrics for analyses of treated cases, therefore much depends upon clinical analysis with models and photographs. A good functioning occlusion with good facial balance is the goal in all orthodontic treatment with acceptable evidence for the method.

The essential requisite for successful treatment with any extraoral appliance is sufficient force, applied over sufficient time, in the desired direction. Thus the first requirement is a comfortable appliance which is acceptable to the greatest number of patients. The cervical appliance fulfills this requisite in my hands more frequently than any other extraoral instrument. The amount of force is determined by tissue and patient reaction; pain is the best indicator.

Cervical appliances are being used today for guiding growth, moving teeth distally and reinforcing anchorage. These applications will be demonstrated by the presentation of the following cases.

The upper models in Figure 1 are right and left views of a Class II, Division I malocclusion in a male, nine years of age. The analysis indicated good mandibular growth with favorable alignment and arch form. The mandibular teeth were in good relationship to the supporting bone and in balance with the musculature. The maxillary teeth were one full cusp mesial in their relationship with the mandibular.

The plan of treatment was directed toward placing the maxillary teeth distally into correct relationship with the mandibular without disturbing the position and balance of the mandibular teeth. The mandibular teeth served as the goal to which the maxillary teeth were to be guided and moved. Bands were placed on the maxillary right and

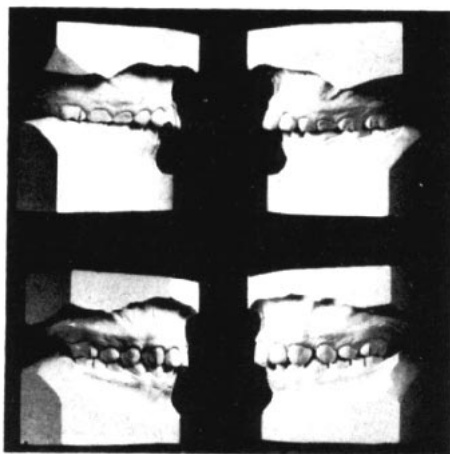


Fig. 1

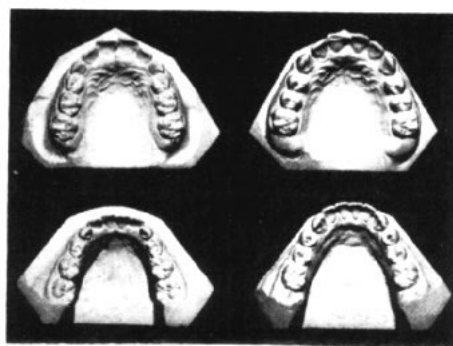


Fig. 2



Fig. 3

left first molars with cervical appliances to be worn seven nights a week, ten or twelve hours per night.

Lower models are right and left views taken three years and ten months later. All permanent cuspids and bicuspid are fully erupted and in good occlusion. The mandibular second molars are starting to erupt. The patient has excellent functioning occlusion with proper alignment of teeth and good facial balance.

This patient had bands only on the maxillary molars with a cervical appliance. Appliances were worn the last year to hold the molars while the cuspids and bicuspid were erupting into good functioning relationship. The time of wearing the appliance might have been reduced by waiting until the primary cuspids and molars were shed, but this is questionable. The chair time of the operator during cervical treatment with bands only on the maxillary molars is very short as compared with placing bands on the remaining teeth.

Figure 2 shows occlusal views before and after treatment. In Figure 3 are photos before and after treatment.

In Figure 4 (upper) are right and left views of a Class II, Division I malocclusion in a male, eight years of age. The facial growth has been acceptable. The mandibular arch was good with small open contacts in the lateral incisor, primary cuspid and primary first molar areas. There was some deficiency in vertical growth with the mandibular incisors functioning against the soft tissue of the palate. The maxillary teeth were mesial to the mandibular the width of one cusp with protrusion and open contacts of the maxillary incisors.

Treatment was planned to place the maxillary teeth distally into correct relationship to the lower teeth without changing the position of the mandibular teeth to their supporting structure. Bands were placed on the maxil-

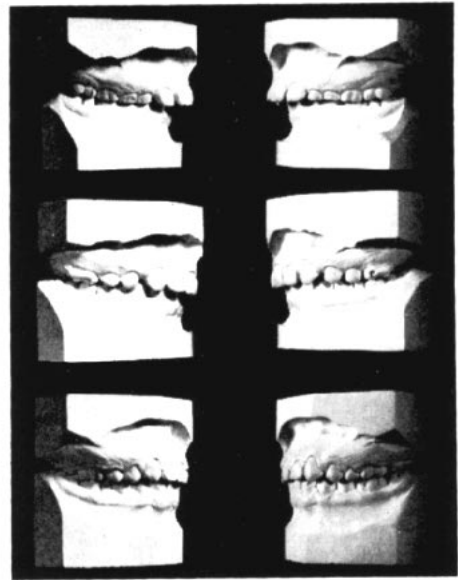


Fig. 4

lary first molars with cervical appliance to be worn at night. A Hawley bite plate was placed after the maxillary teeth started moving distally to remove the interference of the mandibular incisors and to encourage vertical growth in the buccal segments.

Right and left views taken after one year and ten months of treatment with cervical appliance at night and about eight months of wearing a Hawley bite plate in the daytime are depicted in Figure 4 (center). The primary teeth have been replaced by their permanent successors and the molars and bicuspid are in correct functioning relationship with the maxillary molars farther distal than normal. Overtreatment of the molars is desirable to encourage better posterior movement of the bicuspid. The bite has opened but the maxillary cuspids and incisors have not moved distally and lingually sufficiently. There are open contacts between the cuspids and first bicuspid with a distal axial inclination of these teeth. The question arises, would treatment at an earlier age have permitted better distal move-

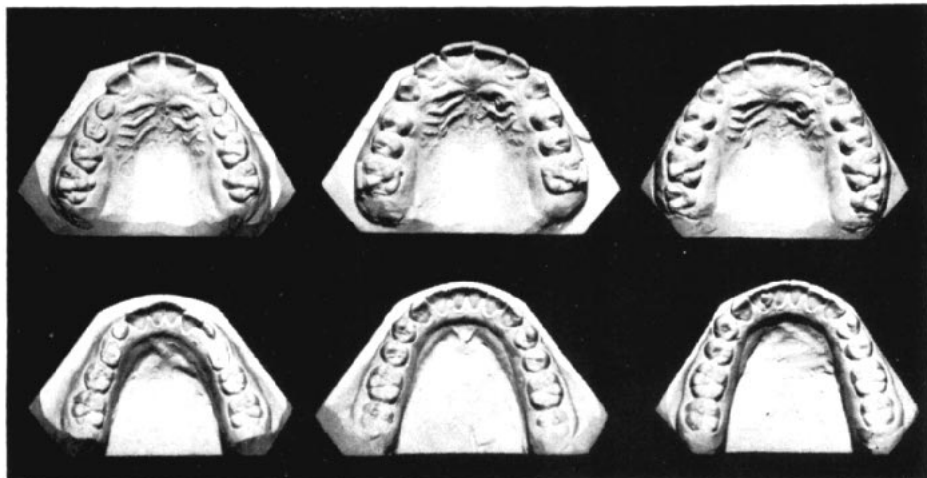


Fig. 5

ment of these teeth? This cannot be answered except by assumptions and opinions.

At this time edgewise bands were placed on the maxillary incisors and cuspids to move these teeth distally and lingually. Cervical appliance was continued on the molars to hold these teeth posteriorly while the rectangular arch was used on the incisors and cuspids.

Lower models (Figure 4) are right and left views after five months additional treatment.

The left models in Figure 5 are occlusal views before treatment; center models are occlusal views after one year and ten months of cervical appliance treatment, note open contacts between maxillary cuspids and bicuspids. On the right are occlusal views taken after five months of treatment with edgewise bands and a rectangular arch on the maxillary incisors and cuspids to close contacts and correct axial inclinations. The contact points in the mandibular arch closed without placing any appliance.

This patient had favorable growth with good facial balance (Figure 6). Clinically, there is considerable similarity between this case and the previ-

ous one. The cervical appliance treatment, to the best of my ability, was similar with equally good cooperation. The latter patient was one year younger chronologically, but his dentition was about two years older. He had all of his permanent teeth before his tenth birthday. These are variables which make it difficult to form a prognosis or definite rules regarding the most advantageous time of treatment.

Upper models in Figure 7 are right and left views of a Class II, Division I



Fig. 6

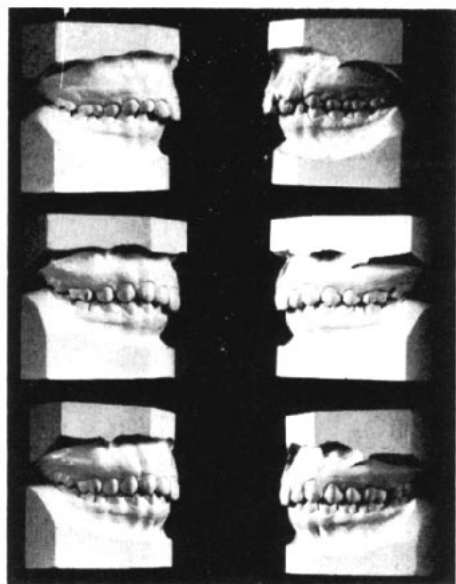


Fig. 7

malocclusion in a female, twelve years of age. All of the permanent teeth had erupted except the right maxillary cuspid. The parents became concerned because the left maxillary cuspid erupted in a buccal and mesial position and the right cuspid failed to erupt. The mandibular arch form and tooth alignment was acceptable with the teeth in good

relationship to the supporting bone and in good balance with facial musculature. The maxillary teeth were mesial to the mandibular with protrusion of the incisors and lack of sufficient space in the arch for the cuspids to assume their correct alignment.

Plan of treatment: A full complement of teeth could be maintained if the maxillary teeth could be moved posteriorly, increasing arch length sufficiently to provide space for the cuspid without changing the position of the mandibular teeth. Bands were placed on the maxillary first molar with a cervical appliance.

Center models (Figure 7) are right and left views after two years and ten months of cervical appliance treatment at night. The molars and bicuspid have moved distally into correct functioning relationship with their antagonists in the mandible. There was sufficient space for the cuspids which erupted in fair alignment, but there were details to be corrected, particularly of the cuspids and incisors. I suggested placing full appliances to place these teeth in better alignment and functioning relationship. The patient refused to have bands placed on the

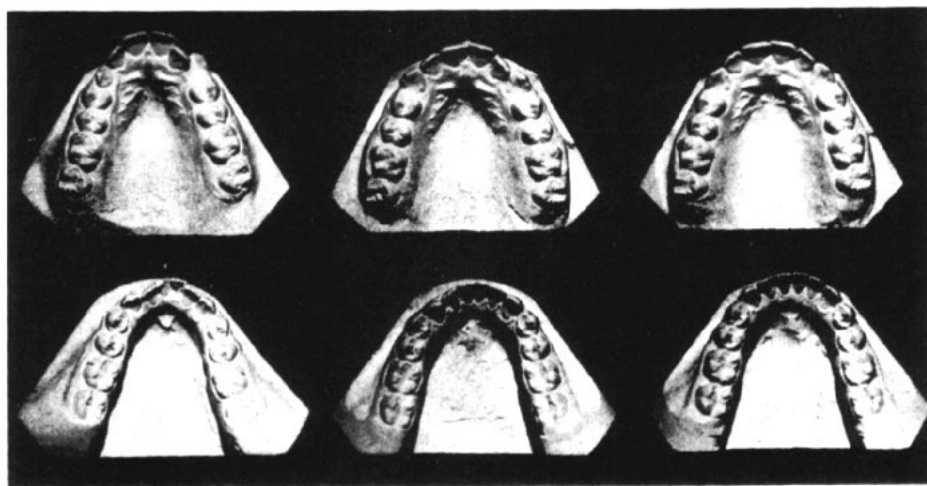


Fig. 8



Fig. 9

anterior teeth but was not satisfied with their alignment. It was impossible to convince her to permit me to place appliances for a short time. The only alternative was a positioner to be worn at night.

Lower models are right and left views after one year of wearing the positioner at night. This case, in my opinion, would have been more successful with only cervical appliance if treatment could have been started in the mixed dentition at about eight years of age.

Figure 8 shows the occlusal views, left before treatment, center after cervical appliance therapy, and right after wearing the positioner for one year.

The before treatment photos are illustrated in Figure 9 above and at the conclusion of treatment below. Her facial balance is acceptable with good functioning occlusion. In my opinion, treatment at an earlier age would have provided better facial balance. She was one of those difficult individuals who wanted correction of her malocclusion but refused to have bands on her anterior teeth.

Figure 10 (upper) shows right and

left model views of a Class II, Division I malocclusion in a male, seven years of age. The mandibular arch form is good with the teeth in good relationship to supporting structure and in good balance with the musculature. The maxillary teeth are anterior to the mandibular with severe protrusion of the incisors and the alveolar process. The facial musculature is well-developed but with hypotonicity in action.

Our plan of treatment was to inhibit the forward growth of the alveolar process and to move the maxillary teeth distally into correct relationships with their antagonists in the mandible. Bands were placed on the maxillary first molars with a cervical appliance. The teeth were in correct relationship after fourteen months, but the cervical appliance was continued another twenty-two months because of the denture protrusion. It was thought essential for best facial balance and development to inhibit the forward growth of the maxil-

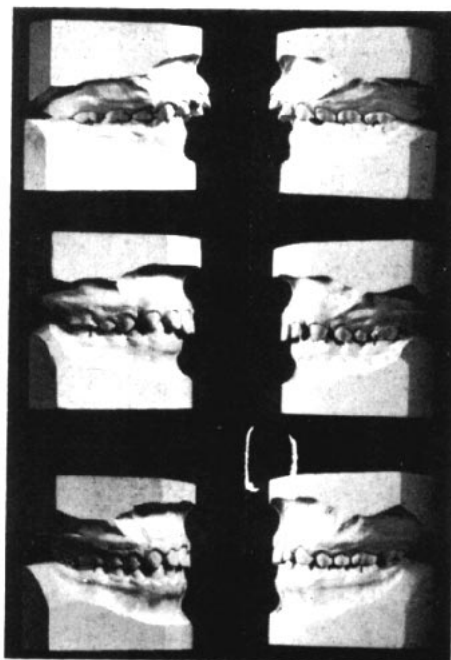


Fig. 10

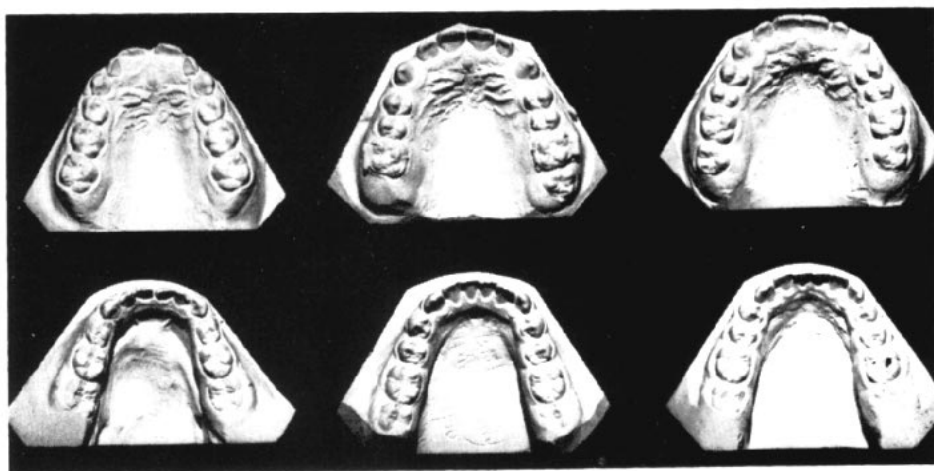


Fig. 11

lary denture as much as possible.

Right and left views of the same case after eruption of all the cuspids and bicuspid teeth are shown in Figure 10 (center). The teeth were in correct mesiodistal relationship with open contacts in the lateral incisor, cuspid and first bicuspid areas of both jaws. In my opinion, there was still a protrusion of the denture with considerable hypotonicity of the musculature. Full edge-wise arch appliances were placed on the upper and lower teeth to close con-

tact points and to obtain a better functioning relationship.

The lower models (Figure 10) are right and left views after twelve months of treatment. The teeth are in good alignment and functioning relationship and have remained the same over the past three years.

Figure 11 illustrates the occlusal views at the start of cervical appliance treatment (left), after eruption of cuspids and bicuspid teeth (middle), and after twelve months of full treatment (right).

In Figure 12 are seen the photographs before treatment and at the end of his second period of treatment. The facial balance may not be the ideal we like and strive to obtain. This is another individual with a different facial pattern, different growth pattern and different musculature. His is the type of case where cervical appliance use is most essential to obtain the best possible in facial balance, functioning relationship and stability of result.

Right and left views of a Class II malocclusion in a male fourteen years of age are illustrated in the upper models of Figure 13. The mandibular arch form and tooth alignment is good with just a slight crowding in the incisal



Fig. 12

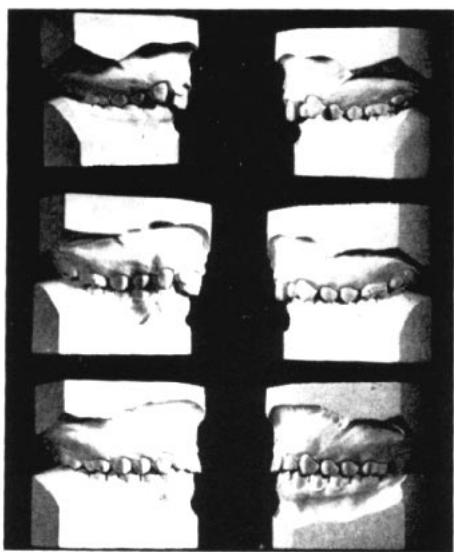

Fig. 13

area. The maxillary buccal teeth are mesial the width of one cuspid to their antagonists in the mandible. There is a severe crowding and overlapping of the maxillary incisors while the mandibular incisors are functioning against the soft tissue of the palate. The facial musculature is good with the mandibular teeth in favorable relationship to the supporting bone.

It was planned to move the maxillary buccal teeth distally to their correct relationship with the mandibular without disturbing the mesiodistal position of the mandibular teeth. Arch length would be increased sufficiently to place the maxillary incisors and cuspids into good alignment and relationships.

As in the other malocclusions bands were placed on the maxillary first molars with cervical appliance to be worn at night.

Center models of Figure 13 are right and left views after fifteen months of cervical appliance treatment. The mesiobuccal cusps of the maxillary molars occlude in the distal grooves of the mandibular first molars. The maxillary bicuspid and cuspids followed the molars, but left open contacts between these teeth. At this time full edgewise arch appliances were placed on the teeth of both arches with continuation of cervical anchorage appliance on the maxillary first molars.

The lower models of Figure 13 are right and left views after fifteen months of treatment with edgewise arch appliances and cervical anchorage.

The occlusal views of this case are

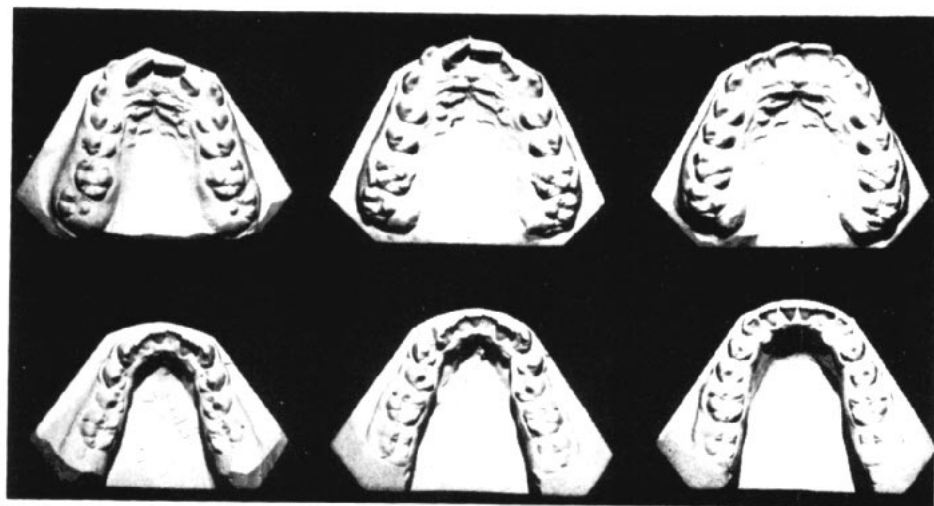


Fig. 14



Fig. 15

in Figure 14, before treatment models are on the left, after cervical anchorage treatment in the center, and after fifteen months of combination on the right.

I believe early treatment at about eight years of age with cervical appliance would have provided better facial development with more satisfactory facial balance than is recorded in Figure 15.

Lateral views of a Class II, Division II malocclusion in a female, eight years of age are shown at the top of Figure 16. The maxillary right primary cuspid, primary first molar and primary second molar had been lost at an early age resulting in a severe mesial drift of the permanent right first molar. It was completely mesial to the mandibular first molar with no occlusal contact. The distobuccal cusp of the left maxillary molar was occluding with the mesiobuccal cusp of the mandibular molar. The mandibular arch form was fair, with mesial tipping of the permanent first molars resulting from failure of eruption of the primary second molars because of ankylosis. The mandibular incisors were contacting the soft tissue of the palate about three-eighths

of an inch lingual to the maxillary central incisors. Facial musculature was well-developed.

Her lower teeth seemed to be in good relationship to the supporting bone but there was an apparent lack of vertical growth. The mandibular arch length could be made adequate by uprighting the first molars with distal tipping of these teeth. The mandibular teeth would still be in good balance, but could not serve as adequate anchorage for the pull of Class II elastics necessary to move the maxillary teeth distally. The maxillary teeth were mesial to the mandibular with a deficiency of vertical growth in the buccal segments. The upper central incisors appeared to be overerupted with the typical Class II, Division II lingual axial inclination.

Plan of treatment: Use a cervical appliance to move the maxillary first molars distally to their proper positions and inhibit their forward growth together with that of the alveolar process. Place bands on the mandibular first molars with a lingual arch to upright these teeth. Remove the ankylosed mandibular right and left primary molars. When the permanent cuspids and bicuspid erupt, place full edgewise arch appliances to open the bite, correct axial inclination of all teeth and place them in good functioning relationship.

In the center of Figure 16 are the right and left views after twenty-six months of cervical appliance treatment with bands only on the maxillary first molars and a lingual arch in the mandible. The molars are in correct relationship to their antagonists with all the permanent teeth erupted except the mandibular right second bicuspid; this tooth was late in formation with retarded eruption. Increase in vertical height in the molar area would have been desirable, but the cervical appliance failed to stimulate or produce this.

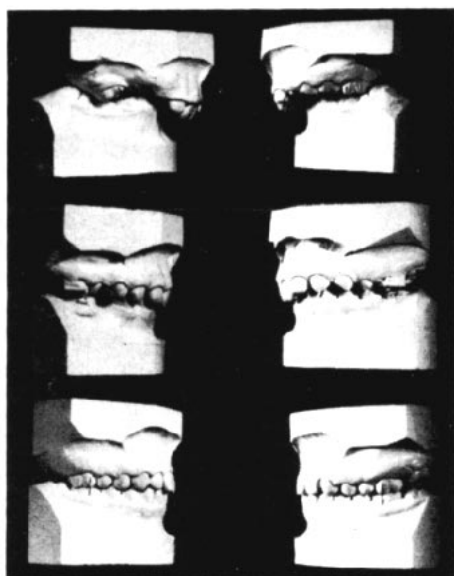

Fig. 16

Full edgewise arch appliances were then placed. Treatment continued for two years with a continuation of cervical appliance on the maxillary first molars. Treatment was prolonged by the delay in eruption of the mandibular right bicuspid.

Lower models of Figure 16 show right and left views at completion of treatment. The patient has a full com-

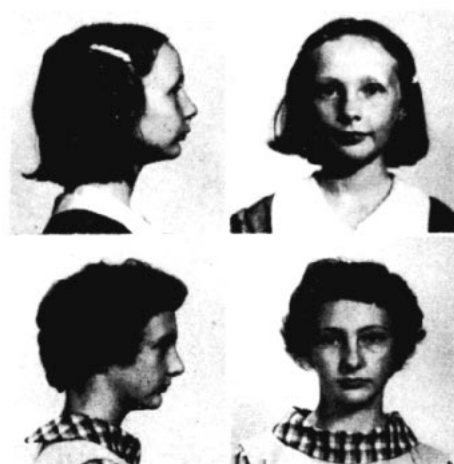

Fig. 18

plement of teeth in correct functioning relationship with good alignment and acceptable facial balance.

Occlusal views are depicted in Figure 17, left before treatment, middle after a cervical appliance and right after two years of combination treatment.

This was a long period of treatment, but the final result warranted the same. The patient was most cooperative and appreciative which is always rewarding. The vertical dimension of the face has improved (Figure 18). The denture is

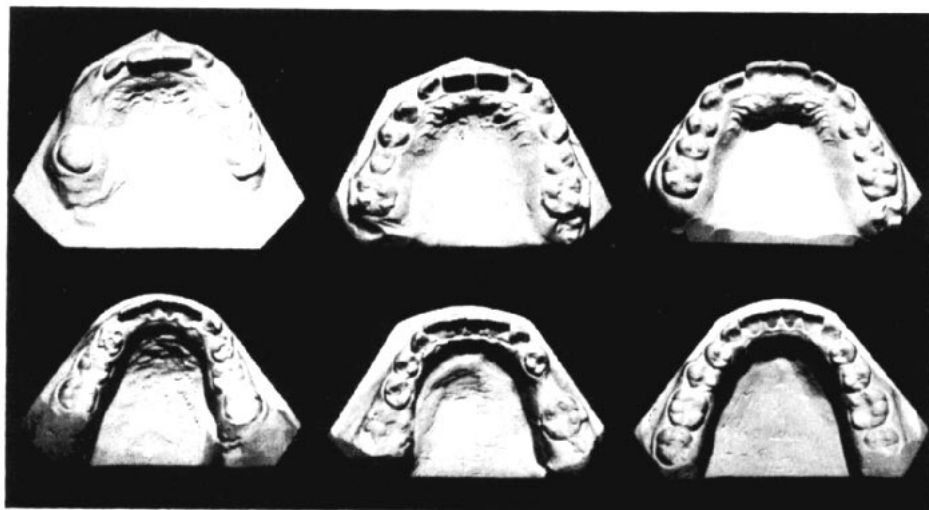
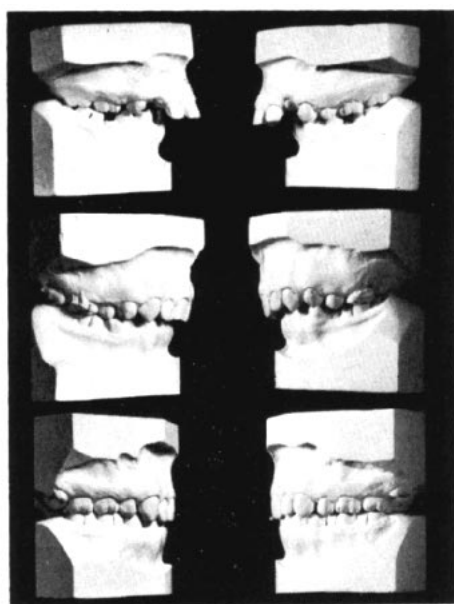
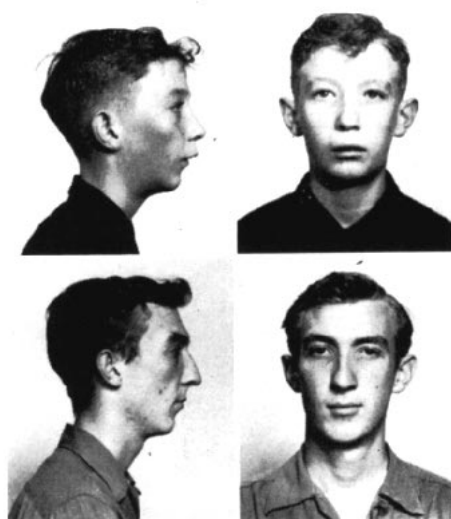

Fig. 17

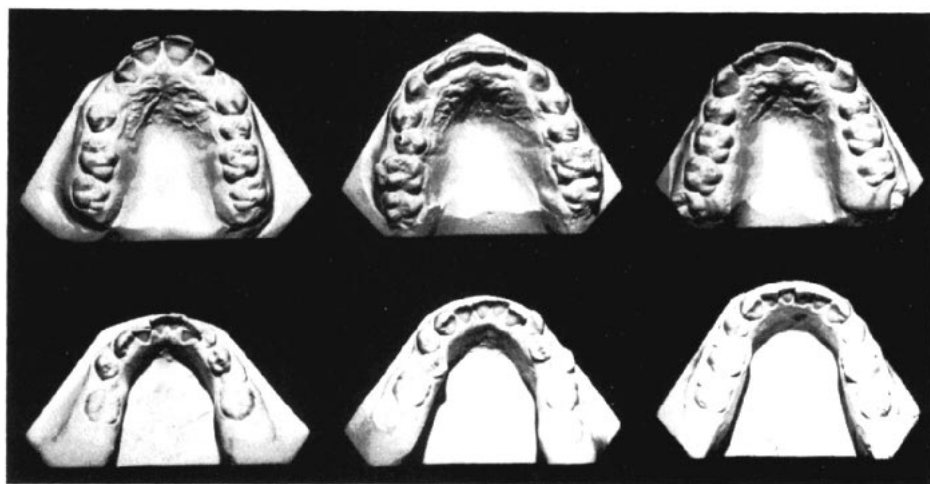
**Fig. 19**

in good functioning relationship and in stable balance. Cervical appliance treatment was the key to the success of treatment in this case.

Figure 19 (upper) are right and left views of a Class II, Division I malocclusion in a male, twelve years of age. The mandible appears to be retarded

**Fig. 21**

in development with an early loss of the primary molars. The mandibular first molars are tipped mesially inhibiting the eruption of the second bicuspid. The mandibular incisors were functioning on the soft tissue of the palate about three-fourths of an inch lingual to the maxillary incisors. The maxillary teeth were mesial to the mandibular with severe protrusion of the incisors.

**Fig. 20**

I feel there has been a severe disturbance in mandibular growth with lack of arch length and a discrepancy in maxillary development with the teeth mesial to supporting bone.

Plan of treatment: Start treatment with cervical appliances placing bands on the maxillary first molars to move the maxillary teeth distally and to inhibit the forward growth of the maxillary dental arch and alveolar process. This will permit observation of mandibular growth. When the maxillary buccal teeth are in correct functioning relationship, take complete records and plan final period of treatment.

Right and left views after twenty-two months of cervical appliance treatment with bands on only the maxillary first molars may be seen in Figure 19 (center). The molars are in Class I relationship with eruption of all the permanent teeth including the second molars. Mandibular growth was not favorable and the sacrifice of four bicuspid was necessary to place the teeth in good relationship to supporting bone and in a better balance with facial musculature. Full edgewise arch appliances were placed with continuation of cervical force on the maxillary first molars to keep these teeth from moving forward while closing spaces of extracted first bicuspid. The cervical appliance serves as excellent anchorage in stabilizing molars in treatment of disharmony where bicuspid are extracted, and the aims of treatment demand a distal and lingual movement of the cuspid and incisors.

The lower models of Figure 19 are views showing the result of sixteen months of edgewise arch treatment. These models were made four years after completion of treatment and two and a half years after all retention was removed. The maxillary third molars were starting to erupt. The mandibular third molars were impacted and had

been removed. There is about a one millimeter open contact between maxillary cuspid and second bicuspid.

On the left of Figure 20 are the occlusal models before treatment; the result of cervical appliance therapy is in the middle and the right views are those two and one-half years after discontinuing retention.

Figure 21 records his face before treatment and after retention.

SUMMARY AND CONCLUSION

These seven cases of Class II malocclusion are a very small sample but sufficient to give an indication of some of the variations each individual presents. The only similarity was the mesial relationship of the maxillary teeth to the mandibular — or the distal relationship of the mandibular to the maxillary. There might be a difference of opinion as to which it was in each case, but the basic plan of treatment remained the same, namely, the moving of the maxillary teeth distally without disturbing the position and balance of the mandibular teeth. The treatment of any malocclusion will be successful and stable if the teeth are placed in a dynamic balance within the limits of the patient's morphologic, physiologic and genetic patterns. The problem is, "What are the limits for each case?" Our treatment plan was based on the assumption that the mandibular teeth were in balance and in correct relationship to the supporting bone and surrounding musculature. The aim of treatment was directed toward moving the maxillary teeth distally into correct functional relationship to their antagonists in the mandible without moving the mandibular teeth mesially.

Cervical anchorage treatment served most efficiently toward this goal. The response in the alignment of all the teeth and in facial balance varied in each case. The time of treatment varied

not always by choice of the operator but by the opportunity afforded.

Studies on time of treatment do not permit any definite rules. The many variables of each case will always remain a challenge to the clinical orthodontist in treatment planning and mechanical therapy. The correct time to institute treatment will reduce the amount of appliance with the minimum disturbance of tissue and provide the best facial balance and stability in each case. We can assume early treatment is a distinct advantage in guiding growth.

Cervical anchorage treatment has proven most successful in my hands in obtaining the best facial balance and stability of occlusion. The force is gentle on the tissue and permits the moving of only those teeth that need to be moved, thereby reducing the stress and irritation on those in correct position. Mandibular arch length and width can be increased in some cases to correct slight rotations and overlapping contacts if these teeth are not used as anchorage for Class II elastics. Clinical evidence and cephalometric findings clearly indicate the mesial movement of mandibular teeth under the force of Class II elastics.

There is sufficient evidence of the distal movement of maxillary teeth by cervical anchorage force. The forward growth of the dental arch and alveolar process is inhibited in many cases. It is essential to continue investigations to determine the extent of the influence of this force on a growing face. Perhaps we can modify our therapy with reduction in treatment time and operator's chair time thereby making it possible to extend our services to many children denied them today.

Zuelke Bldg.

BIBLIOGRAPHY

1. Brodie, Allan G., Facial Patterns — A Theme in Variation. *Angle Ortho.* 16, 75-87, 1946.
2. Ketterhagen, Donald, Taking a Second Look at Head Cap Treatment. *Angle Ortho.* 27, 93-95, 1957.
3. King, Elbert W., Cervical Anchorage in Class II, Division I Treatment, A Cephalometric Appraisal. *Angle Ortho.* 27, 98-104, 1957.
4. Moore, Alton W., Observations on Facial Growth and Its Clinical Significance. *Am. J. Ortho.* 45, 399-423, 1959.
5. Moore, Alton W., Orthodontic Treatment Factors in Class II Malocclusion. *Am. J. Ortho.* 45, 323-352, 1957.
6. Newcomb, Morse R., Some Observations on Extraoral Treatment. *Angle Ortho.* 28, 131-148, 1958.