

Case Report

GEORGE N. BOONE, D.D.S., M.S.
Pasadena, California

HISTORY

This male patient was 13 years and 3 months of age when treatment was begun. His childhood growth and development were apparently normal. Both his mother and father appeared to have acceptable occlusions and well-balanced facial patterns. Neither a brother nor a sister had any serious dentofacial anomalies. There was, therefore, no reason to believe that heredity played an important part in the development of this malocclusion.

The patient was a mouth breather, a problem which had existed throughout his growing years. He suffered from hay fever and other allergies that caused nasal congestion. Undoubtedly, these conditions contributed to his mouth breathing. As a result, his mouth was open a great deal of the time, apparently causing the oral muscles to function abnormally.

Even though the patient had an open bite, there were no tongue thrusting or faulty swallowing habits that we could detect. He had experienced the usual childhood diseases, but none that we believe could have influenced his need for orthodontic treatment to any great degree. The teeth were relatively free of decay, and the gingival tissues appeared to be healthy. The lip and cheek muscles lacked normal tissue tone, probably caused by persistent mouth breathing and by protrusion of the teeth.

DIAGNOSIS

Before treatment was begun the patient had a markedly protrusive malocclusion and a definite imbalance of the facial musculature. The lips were

strained when they were closed. The face was of convex form and the mandibular plane was unusually steep (Fig. 1).

An examination of the mouth and of the models, made at the beginning of treatment, revealed an open bite in the anterior region and a midline deflection. Occlusion in the posterior areas, particularly in the molar regions, was good, but the cuspids had a tendency toward an end-to-end relationship (Fig. 1). The maxillary anterior teeth were slightly crowded and the right second bicuspid was very badly rotated.

The mandibular posterior teeth appeared to be well positioned over the supporting bone. The arch form was ovoid in character. The mandibular anterior teeth were crowded with an arch length discrepancy of minus 6 millimeters.

Intraoral x-rays revealed normal root formation surrounded by a normal alveolar bone. A supernumerary tooth was located between the mandibular right first molar and second bicuspid impinging on the first molar root.

A cephalometric evaluation, using the Steiner analysis, revealed the following (Fig. 2). The SNA angle was 75.5 degrees. The SNB angle was 72.5 degrees. The ANB angle was 3 degrees, indicating a Class I with a tendency towards a Class II, Division 1 type malocclusion. The maxillary incisors were 9.5 millimeters forward of, and at 28 degrees, to the NA line. The mandibular anterior teeth were 8 millimeters forward of, and at 25 degrees, to the NB line. These figures indicate that both the maxillary and mandibular incisors were definitely protrusive in rela-

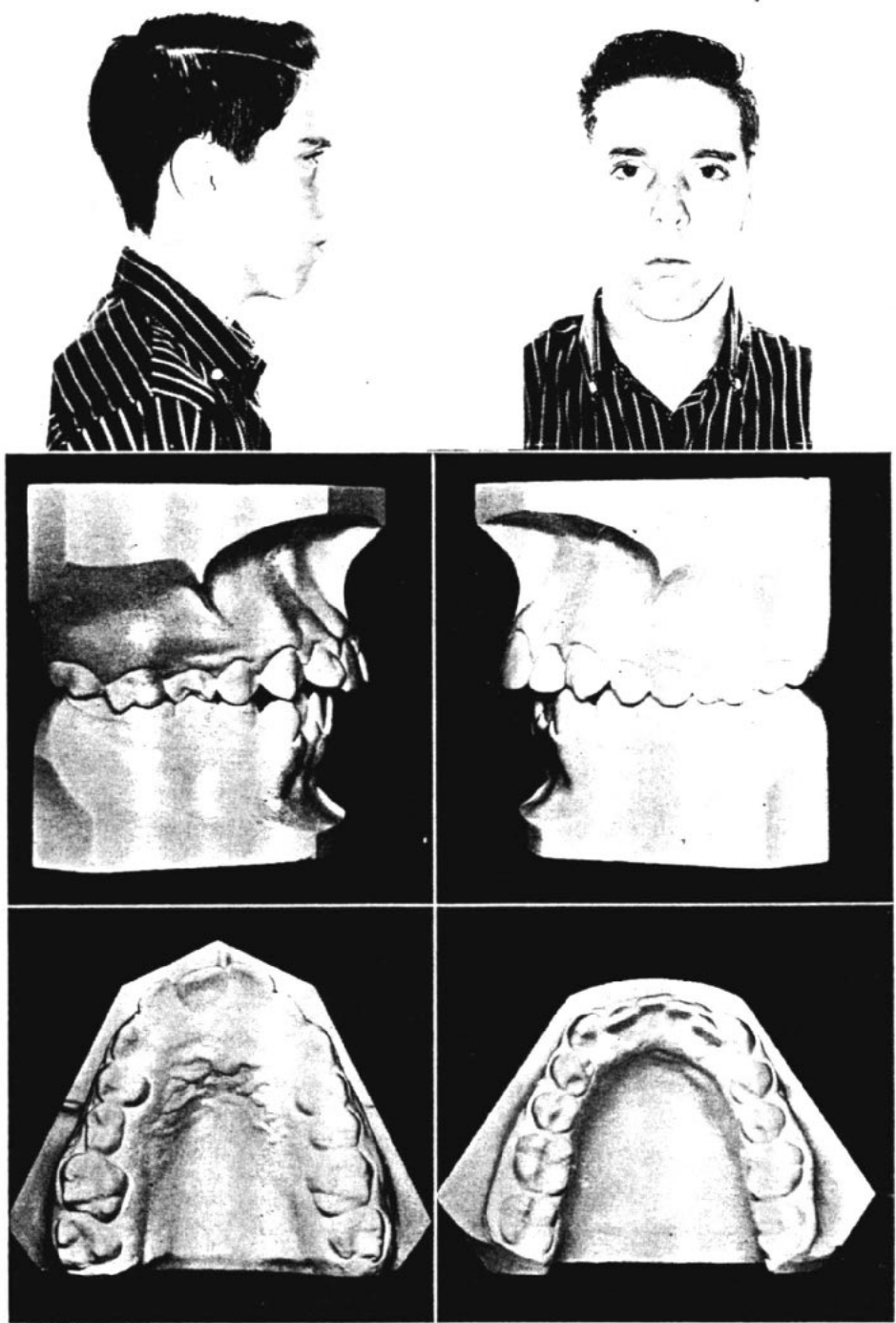


Fig. 1

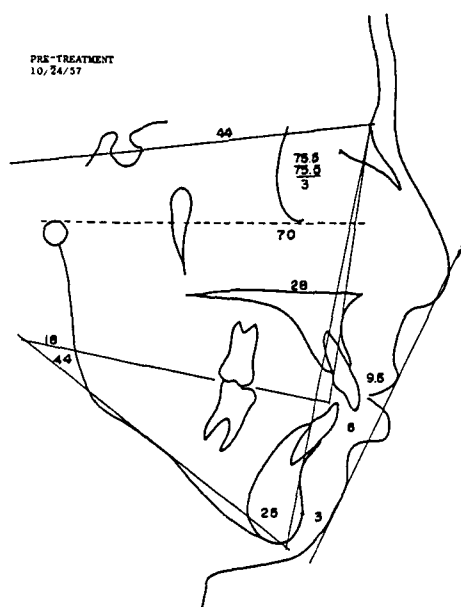


Fig. 2

tion to their supporting bone.

Pogonion was 3 millimeters forward of the NB line, more than average for a boy of his age, especially when the teeth are protrusive. The mandibular plane was at 44 degrees to the SN line. This is steep and indicates a lack of vertical height in the ramus of the mandible. The occlusal plane was at 18 degrees to SN which is slightly higher than normal. SL measured 44 millimeters indicating a lack of anteroposterior growth of the body of the mandible.

The width of the lower six anterior teeth was 79 percent of the width of the maxillary anterior teeth (Bolton Index).

ETIOLOGY

Persistent mouth breathing was probably one of the most important factors in this dentofacial anomaly. There also appeared to be some discrepancies in the relationship between the size of the teeth and the supporting bone.

PLAN OF TREATMENT

The goals and plans for treatment were established by evaluating the case in several ways. Two of the more important ones were based upon the demands of the jaw relationships as expressed by the ANB angle and the prominence of the chin as expressed by the measurement of pogonion to the NB line. Both of these were evaluated before treatment and considered in the treatment plan.

In considering the ANB angle and its variation from the norm, it was believed that the ANB angle, which was 3 degrees, could be reduced to 2 degrees by orthodontic treatment. If this were accomplished, the maxillary incisors could then be placed 4 millimeters ahead of the NA line and the mandibular incisors 4 millimeters ahead of the NB line, according to Steiner's suggested arrangements.

For a determination of the relationship of the mandibular anterior teeth to pogonion, the following items were considered. Because the mandibular anterior teeth would be retracted during treatment, B point and the NB line would also be retracted; and because of future appositional growth in the chin area, the pogonion measurement would be increased. Therefore, it was felt that the measurement of pogonion to the NB line would increase from 3 millimeters to 5 millimeters during the time of treatment.

Many orthodontists believe that an ideal relationship of the mandibular lower incisors and pogonion to the NB line should be a one to one ratio. Because of this, the mandibular anterior teeth were estimated to be placed 5 millimeters ahead of the NB line which does give a one to one relationship.

It can be noted that there was a difference in the positioning of the anterior teeth as dictated by the ANB angle and as indicated by the demands

of pogonion. This difference was resolved by establishing an average between the two. This resolved goal shows an ANB angle of 2 degrees, the maxillary incisors 4.5 millimeters ahead of the NA line, and the mandibular incisors 4.5 millimeters ahead of the NB line. Pogonion was estimated at 5 millimeters ahead of the NB line.

It was necessary to vary from this particular formula for this patient. It was decided that the maxillary and mandibular incisors, if placed 4.5 millimeters ahead of the NA and NB lines, with this patient's facial type, would make a flat or concave type profile. Therefore, the treatment goal was individualized so that the maxillary incisors would be placed 5.5 millimeters and at 24 degrees to the NA line, and the mandibular incisors 5.5 millimeters and at 31 degrees to the NB line. The resulting prescription is an individualized treatment goal for this patient designed to conform to our concepts of good orthodontic treatment for him.

Treatment plans and methods were determined by use of the lower arch chart of the Steiner analysis sheet.

This evaluates problems which help us to determine and plan individualized appliance therapy for each patient (Fig. 3).

Treatment planning for the patient was evaluated by considering the following points.

It was decided that the position of the lower central incisor, that was traced, did express the anteroposterior position of a majority of the mandibular teeth. Since it was accepted as expressing this position, no value was marked in the box captioned, "Correcting Arch Form Moves 1".

The lower arch tooth size discrepancy was measured indicating a lack of 6 millimeters in arch perimeter length.

We felt that the buccal teeth were well-positioned over the supporting bone and, therefore, there was no indication that these arches should be expanded or contracted. No value was placed in the plus or minus column for expansion.

In relocating the mandibular anterior teeth it was felt that to move them back from 8 millimeters ahead of the NA line to the planned positions of

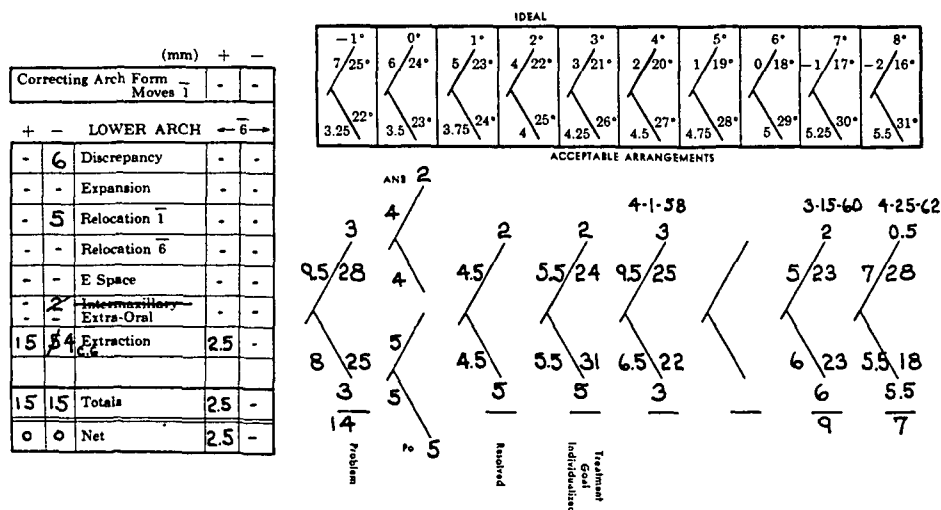


Fig. 3

5.5 millimeters ahead of this line would cause a crowding of 2.5 millimeters on the left side and 2.5 millimeters on the right side. This amounts to a total loss of space of 5 millimeters in both mandibular buccal segments.

No value was placed in the plus or minus column for relocating the mandibular first permanent molars because it was felt that the second and third permanent molars were in close proximity, distally. It was believed that there would be little opportunity to successfully reposition the first molars distally and permanently maintain them there.

There were no primary teeth remaining so there was no opportunity to save any "leeway" space which might have existed under the second primary molars before they were shed.

The first permanent molars were in good mesiodistal relationship to each other, but the cuspids had a tendency towards an end-to-end relationship. There was protrusion of the maxillary anterior teeth. If these conditions were corrected by the use of intermaxillary elastics, the mandibular molars would come forward about 1 millimeter on each side giving a value of minus 2.

In reviewing the treatment plan chart to this point it was found that there was nothing on the plus side, and 13 on the minus side. When the four bicuspid are removed, an average of 15 millimeters (7.5 on each side) is provided in the extraction areas. In closing this space, using regular methods, the anterior teeth will be retracted two-thirds of the distance, and the posterior teeth will come forward one-third. Therefore, a value of 15 was placed on the plus side for space provided and 5 on the minus side for recording the forward movement of the posterior teeth.

We now have totals of 15 on the plus side and 18 on the minus side of the treatment planning chart. This re-

maining 3 millimeter difference on the minus side could be eliminated by the use of cervical gear instead of intermaxillary elastics and by reducing the forward movement of the mandibular molars during space closure from 5 to 4 mm by using Class III elastics against a stabilized maxillary arch (Fig. 3).

A treatment plan and an appliance therapy, thus decided upon, would eliminate the arch length discrepancy of 6 millimeters and reduce the protrusion of the teeth.

Because of the badly rotated maxillary right second bicuspid and the supernumerary tooth in the mandibular right buccal segment, the following teeth were decided upon for removal: maxillary right second bicuspid, maxillary left first bicuspid, mandibular right second bicuspid and mandibular left first bicuspid. By removing the second bicuspid in the right buccal segments, a difficult rotation problem in the maxillary arch was eliminated and the removal of the mandibular supernumerary tooth was facilitated. This did, however, complicate the problem of symmetry during the space closing procedure.

An edgewise appliance of chrome alloy was used. The bracket slots were .018 × .025 in dimension and were angulated to the long axes of the teeth in the following manner: the maxillary central incisors were angulated with 2 degrees distal root tip; the maxillary lateral incisors were angulated with 4 degrees distal root tip. These angulations were used to artistically position these teeth. The mandibular central and lateral incisors were not angulated. The maxillary and mandibular cuspids were given 6 degrees distal root tip to help to parallel the roots in the extraction area, to position them artistically and to give them better functional relationships.

Maxillary bicuspid and molar brackets were not angulated, but an addi-

tional tube was placed on the first molar to engage a cervical gear. The mandibular bicuspid received 6 degrees, the first molars received 8 degrees and the second molars received 10 degrees of distal crown tip. This allowed the teeth to be uprighted into good functional positions and the roots to be paralleled.

Treatment was initiated by banding the buccal segments in the maxillary arch after the bicuspid was removed. A sectional archwire was placed and stabilized with a cervical gear. The mandibular buccal teeth were also banded at this time. The cuspids were retracted using mandibular sectional archwires for space closing and up-righting of the posterior teeth.

When spacing occurred between the mandibular anterior teeth, these teeth were banded and, using a closing loop archwire, retraction was continued. After the spaces were completely closed, rotations and the alignment completed, the mandibular arch was stabilized with an $.018 \times .025$ rectangular archwire.

Closing loop sectional archwires were placed in the maxillary buccal segments and the cuspids retracted until spacing occurred between the maxillary anterior teeth. At this time the maxillary anterior teeth were banded and, using a closing loop archwire of $.017 \times .025$ the maxillary spaces were closed and retraction continued. Rotations and alignments were completed with both round and rectangular archwires. Maxillary and mandibular finishing archwires, with up and down elastics, were placed to accomplish interdigation and cusp seating of the teeth.

PROGRESS OF THE CASE

The patient was under active treatment for approximately twenty-six months visiting the office on the average of once every three weeks. He was very cooperative, had excellent oral hy-

giene habits, a good nutritional program, and a willingness to help in every way with the orthodontic treatment. There were no unusual complications. Care had to be taken during the space closing stages to maintain symmetry because of the asymmetrical nature of the bicuspid extractions.

RETENTION

Maxillary and mandibular Hawley type retainers were used during the retention period. They were worn continually for the first three months and then at night only for approximately 18 months. When this case was treated, mandibular fixed cuspid-to-cuspid retainers were not in common use in this office, but since then have become an integral part of our retention procedures. It is believed that if such an appliance had been used, stability of this patient's mandibular anterior region might have been enhanced.

RESULTS ACHIEVED

The photographs at the end of the treatment indicate a reduction in the protrusion of the denture producing a much more pleasing appearance in the lower third of the face. Facial muscles appear to have better tone, and the muscular strain that was present before treatment has disappeared. The patient now keeps his lips closed and breathes normally (Fig. 4).

Models taken at the end of treatment reveal a reduction of the anterior protrusion in both the maxillary and mandibular arches. The midline deviation has been corrected and the open bite closed. The anterior teeth have been aligned into acceptable arch form. The posterior occlusion appears to be good (Fig. 4).

Intraoral x-rays indicate that the teeth and the surrounding tissues are healthy, and that there has been little or no bone loss or root resorption. The

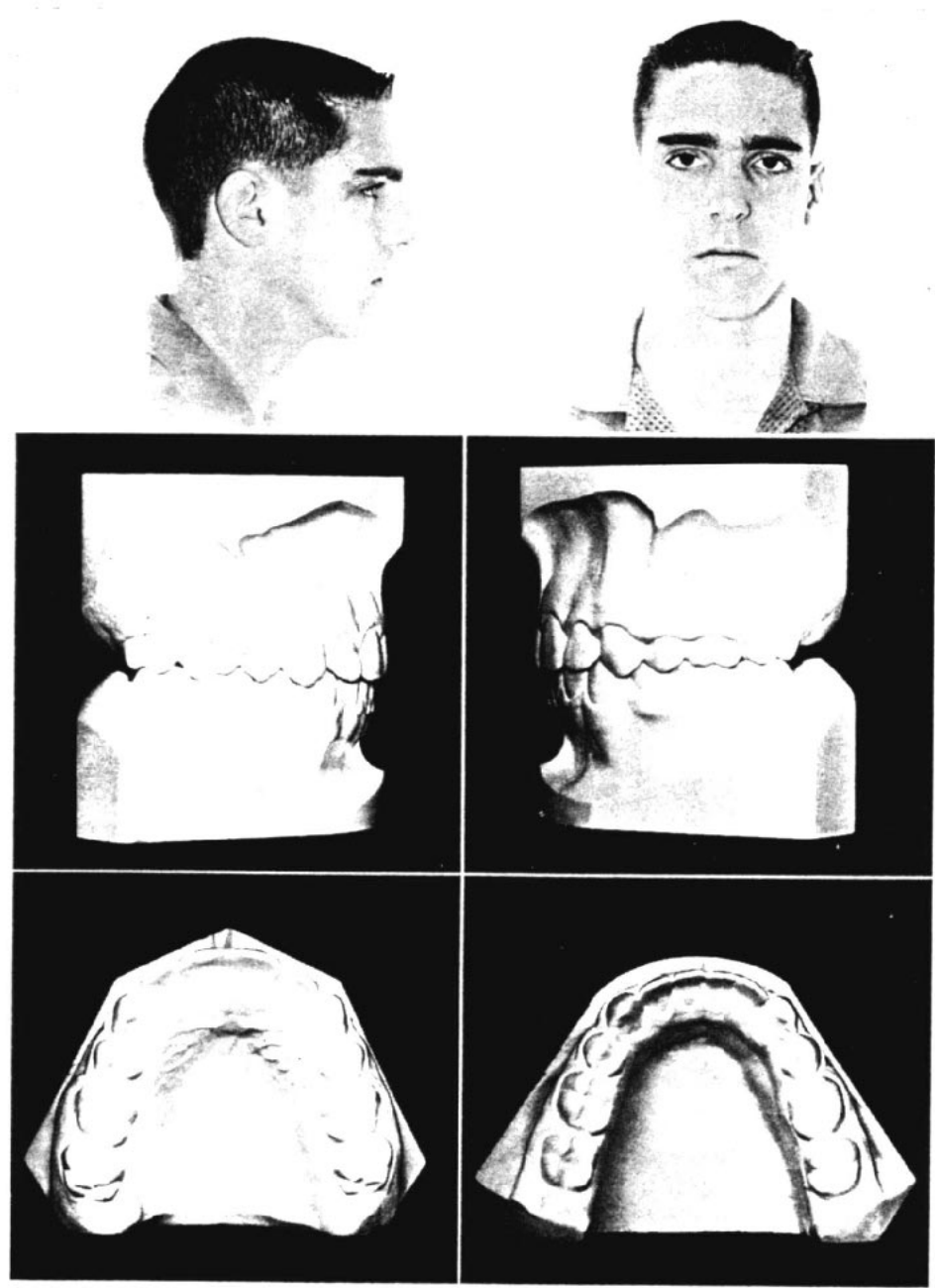


Fig. 4

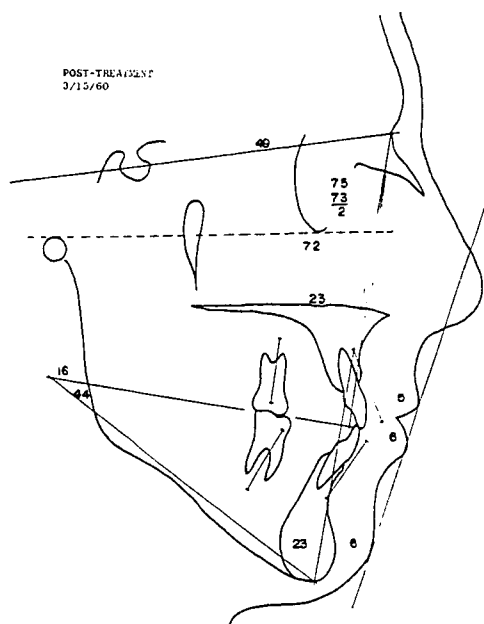


Fig. 5

extraction sites are closed, the crowns in contact, and the roots well positioned.

In the cephalometric analysis the following changes were noted (Fig. 5). The ANB angle was reduced from 3 degrees to 2 degrees as predicted in the treatment plan; the maxillary incisors were moved from 9.5 millimeters, at 28 degrees, to 5 millimeters, at 23 degrees, to the NA line; the mandibular anteriors were moved from 8 millimeters, at 25 degrees, to 6 millimeters, at 23 degrees, to the NB line; pogonion increased from 3 millimeters to 6 millimeters in front of the NB line. Both the mandibular plane angle and the occlusal plane angle changed little during treatment indicating that an acceptable vertical dimension had been maintained. SL increased from 44 to 49 millimeters suggesting that growth occurred in the length of the mandible.

OBSERVATIONS AND CONCLUSIONS

There was some concern regarding

the eventual stability of this case because of the original anterior open bite and the protrusive nature of the denture.

We feel that the treatment goals were achieved. There was an improvement in the patient's profile, in the function of the denture, and in esthetics. Much of the credit for these results must be attributed to a good growth pattern throughout treatment and to an interested and cooperative patient.

POSTTREATMENT FINDINGS

Approximately four years after treatment had begun, and two years after the appliances were removed, another survey was made.

In the photographs taken at that time it is evident that there was a continued improvement in the profile and in muscular balance (Fig. 6). This change can be attributed to a further good growth response. It is interesting to compare the three profiles, the one at the beginning of treatment, at the end of treatment and in the postretention period, and to see the changes that have occurred in the contour of the face and in the muscular balance.

In studying the models taken in the posttreatment period it was found that there was continued stability of the anterior overbite and overjet. The posterior occlusion and general arch form seemed to be acceptable. A slight crowding or relapse in the mandibular anterior region was noticeable, but this probably could have been lessened or prevented by the use of a fixed cuspid-to-cuspid retainer.

The intraoral x-rays still show well-formed dental units surrounded by healthy bone.

The cephalometric evidence indicates that the results of orthodontic treatment were satisfactory and stable (Fig. 7). The only significant change in the last tracing was in the reduced SNA

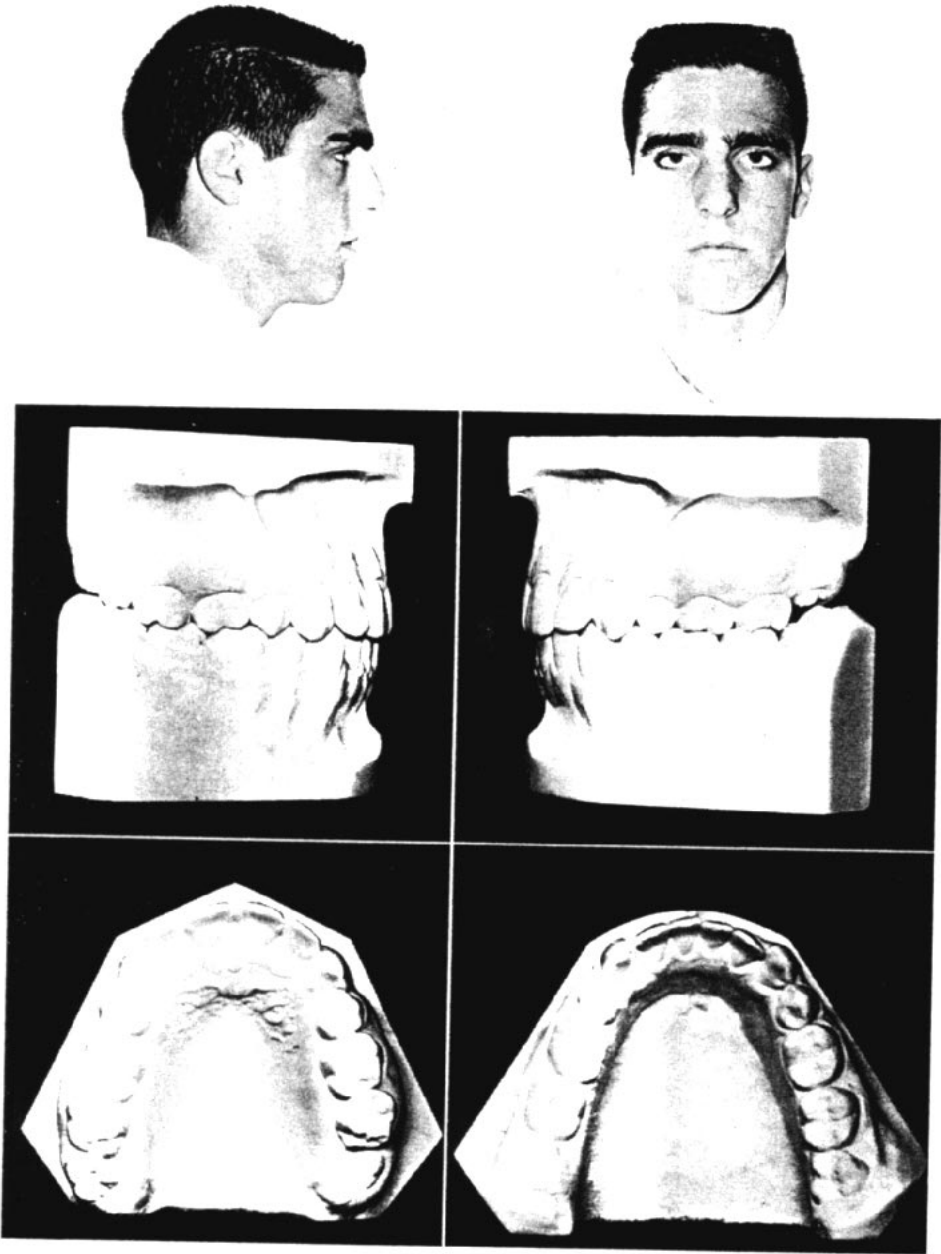


Fig. 6

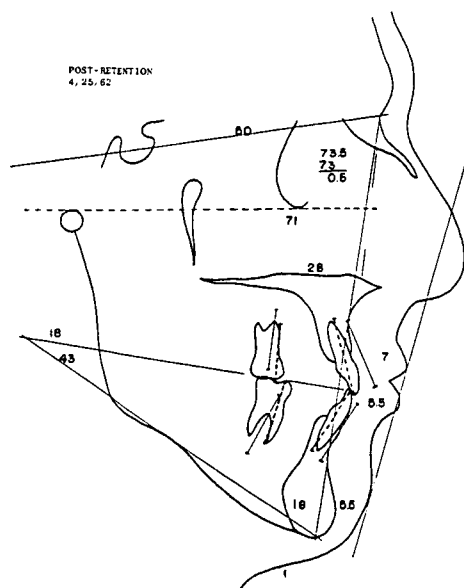


Fig. 7

angle which was caused by a recontouring of the bone in the area of point A to conform to the roots of the anterior teeth that were retracted during treatment. This changed the ANB angle from 2 to 0.5 degrees during the time that has elapsed. The incisor and molar lines indicate that the teeth have moved very little and that the case appears to be stable.

3925 East Huntington Drive