

# The Value of the PM Reference Line for Estimating Natural Head Position

DAVID D. FEUER, D.D.S.

Anthropologists, for their craniometric studies of skulls in the middle of last century, and orthodontists, for their cephalometric studies of the living in the middle of this century, have devoted an inordinate amount of effort to identify a reference line or reference plane that could be applied universally for the study of facial morphology.

After much debate anthropologists settled on the Frankfort Horizontal plane as the best approximation of the "upright"<sup>1</sup> or natural head position in the living for the orientation of skeletal material.<sup>2</sup> Orthodontists adopted the Frankfort Horizontal apparently without even realizing that they were not dealing with skulls but with living subjects who could be oriented directly in their natural head posture, rather than indirectly through the use of this intracranial reference line.

Downs,<sup>3</sup> who depended on the Frankfort Horizontal for his cephalometric analysis, voiced words of warning about relying on the location of two anatomic landmarks to approximate upright head positioning which is a physiologic state. Since patients can orient themselves in their natural head position with remarkably reproducible results when taking head radiographs, an extracranial vertical can be used to construct the horizontal for the Downs' analysis or to verify the inclination of the anterior skull base (nasion-sella turcica) at 82 degrees for the Steiner analysis.<sup>4</sup>

Recently, Enlow et al. introduced a

method for analysis based on three vertical and four horizontal equivalent dimensions of facial parts.<sup>5</sup> The authors proposed a geometric construction oriented on a vertical line drawn through the intersection of the great wings of the sphenoid with the planum sphenoidale or cranial floor and tangent to the maxillary tuberosities. This posterior nasomaxillary vertical, or PM vertical, was the key reference line to which all other lines were drawn either perpendicularly or parallel.

The PM line was claimed to be approximately perpendicular to the line of vision and to represent a reference line consistent with the anatomically "neutral" position of the head.<sup>6</sup> The latter may be taken to stand for natural head position particularly since the PM line was presumed to be perpendicular to the visual axis. Natural head position was defined by Broca in 1862 as follows: "When a man is standing and when his visual axis is horizontal, his head is in the natural position."

The orientation of the proposed grid system is critical for the correct assessment of facial shape, as in all methods of cephalometric analysis. Therefore, the method of Enlow et al. has been studied with reference to natural head position as the basis for head orientation common to all individuals and universally adopted for clinical examination in orthodontics and anthropological study.

## MATERIALS AND METHODS

Fifty lateral head radiographs of 18 to 20 year old female students of the Forsyth School of Dental Hygienists were used to identify on tracing paper

---

Clinical Fellow in Orthodontics, Harvard School of Dental Medicine-Forsyth Dental Center, Boston, Massachusetts.

the landmarks for the posterior nasomaxillary line as well as nasion and sella turcica. These radiographs had been obtained while each subject assumed natural head position by looking into a small mirror at eye level, free of support from ear rods and other devices employed in conventional cephalometric techniques as described by Moorrees and Kean.<sup>2</sup>

In addition to the intersection of the shadows of the great wings of the sphenoid with the cranial base and the most posterior inferior outline on the pterygomaxillary fissure, averaging left and right contours, the most dorsal point on the curved outline of the posterior aspect of the maxilla was identified also on the premise that it could be located with greater precision than the inferior aspect of the pterygomaxillary fissure and to test its relation to the extracranial vertical. Two points were marked on the extracranial vertical plumbline registered on each radiograph.

Coordinates of all landmarks were obtained by means of an Oscar analog reader and decimal converter. Angles between the vertical, the PM line determined by two different landmarks at its caudad aspect and the nasion-sella turcica line were determined by the computer together with statistical analysis of the data.

#### FINDINGS

The PM vertical had an average inclination of 9.0 degrees to the vertical, the angle opening caudally, with a standard deviation of 4.4 degrees and a range of 18.7 degrees. Reproducibility of locating landmarks for the PM line, expressed as the mean difference of two successive and independent observations, was 0.2 degrees with a standard deviation of 0.9 degrees.

When using the posterior aspect of the maxilla rather than the pterygo-

maxillary fissure, the mean angle of the new PM line and the vertical was 12.4 degrees, with standard deviation of 5.7 degrees and a range of 23.9 degrees. Because of this large range of variation, the most inferior and posterior point on the pterygomaxillary fissure was considered to be the more preferable landmark.

To illustrate that the findings of cephalometric analysis can be dramatically affected, often with opposite and, therefore, contradictory results from clinical reality, the facial configurations of three patients with different malocclusions will be presented. For this purpose the Enlow et al. grid system has been oriented both on the PM line and the extracranial vertical, the subjects being radiographed in natural head posture.

The first patient, who had a Class III malocclusion, revealed clinically a slightly retrognathic maxilla and a mildly prognathic mandible. The occlusal plane angle was essentially within normal limits but the mandibular plane angle was steep. Findings according to the Enlow method, oriented on the PM line, yielded bimaxillary prognathism (Fig. 1). Furthermore, the inclination of the anterior cranial base (SN) became markedly caudad. When the extracranial vertical was used for the orientation of the Enlow coordinate system, a mildly retrognathic maxilla and prognathic mandible became evident in accordance with the clinical examination (Fig. 2).

The Class II, Division I malocclusion of patient 2 occurred as a result of a prognathic maxilla and a normal mandible, the Enlow grid system being oriented according to the extracranial vertical (Fig. 3). The occlusal plane angle and mandibular plane angle were well within normal limits but somewhat flat. The skull base appeared to have a

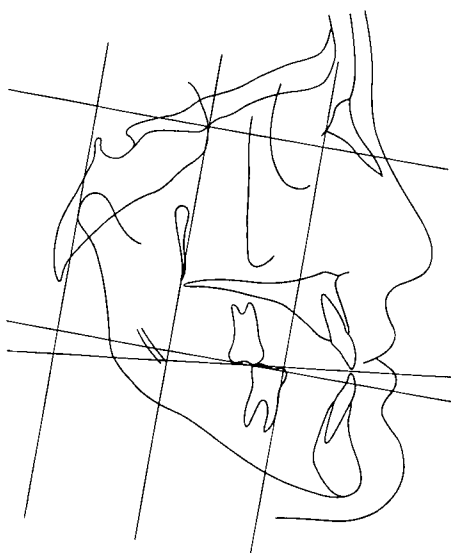

Fig. 1. Enlow et al. analysis of the facial configuration of a patient with a Class III type malocclusion. The coordinate system was oriented on the PM line following the method of Enlow revealing bimaxillary prognathism.

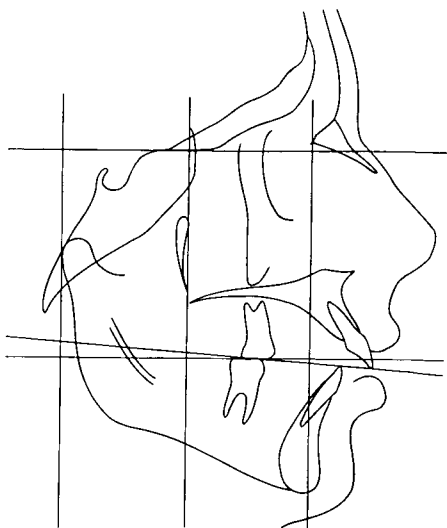


Fig. 3. The facial configuration of a patient with a Class II, Division I malocclusion revealed a prognathic maxilla and "normal" mandible, both clinically and according to the Enlow coordinate system oriented on the extra-cranial vertical.

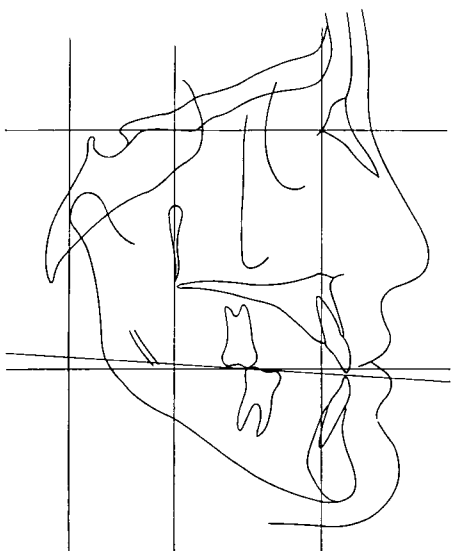


Fig. 2. Enlow analysis of the facial configuration of the patient with a Class III type malocclusion shown in Figure 1. Natural head posture was assumed during radiography and the coordinate system was oriented on an extracranial vertical (plumb) reference line. Findings support the clinical assessment of mildly retrusive maxilla and mildly prognathic (mesognathic) mandible.

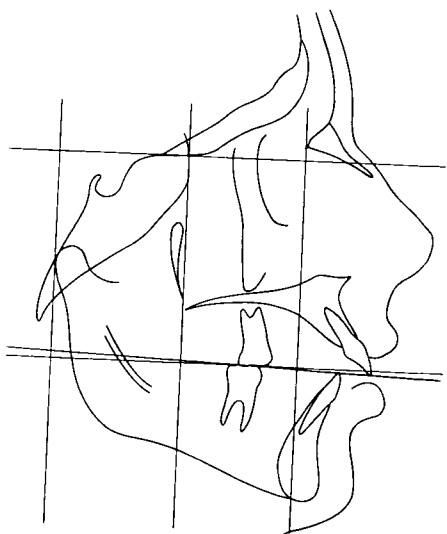


Fig. 4. When the Enlow system was oriented on the PM line, the facial configuration of the patient with a Class II, Division I malocclusion, shown in Figure 3, was found to be bimaxillary prognathic, the prognathism being proportionately greater in the maxilla than in the mandible.

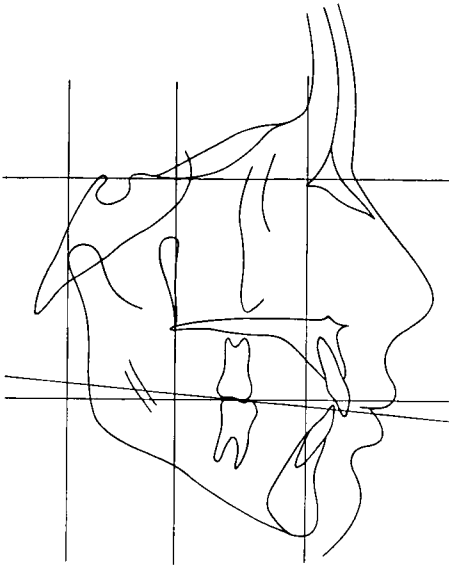


Fig. 5. "Normal" maxilla and mandible characterized the facial configuration of a patient with a Class I type malocclusion both clinically and according to the Enlow coordinate system oriented on the extracranial vertical.

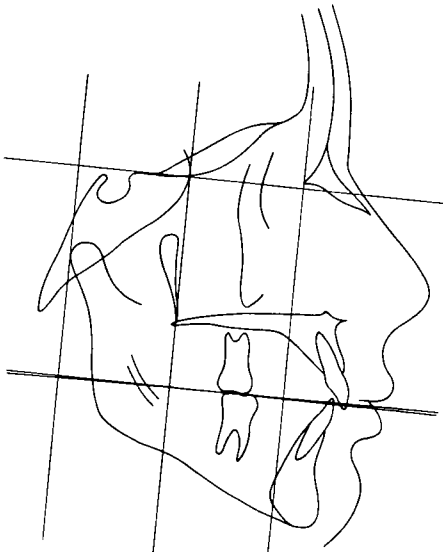


Fig. 6. When the Enlow system was oriented on the PM line instead of the extracranial vertical, the facial configuration of the patient with a Class I malocclusion, shown in Figure 5, was found to have marked bimaxillary prognathism.

caudad inclination. The Enlow protrusion measurement, with orientation on the PM line, indicated bimaxillary prognathism which was proportionably greater in the maxilla than in the mandible (Fig. 4). Assessment of the facial configuration obtained with the extracranial vertical concurred with the clinical evaluation.

The third patient had a Class I malocclusion with normal maxilla and normal mandible, an orthognathous face (Fig. 5). The occlusal and mandibular plane angles were essentially normal. Cephalometric study with the Enlow system oriented on the PM line gave a pronounced bimaxillary prognathous facial contour with the maxillary and mandibular anterior teeth proclined (Fig. 6).

### DISCUSSION

Inferences from the method of cephalometric analysis of intrinsic facial form and growth proposed by Enlow et al. can be made more meaningful when the relationship of the two principal intracranial landmarks that determine the orientation of their coordinate system is studied as the first step in the procedure. This suggestion implies that the coordinate system is set at the dorsal aspect of the maxilla with its vertical axis parallel to the extracranial vertical without necessarily intersecting the shadows of the great wings of the sphenoid.

When this correction is made, the arbitrary definition of the cranial "floor" or cranial "base" overlying the mandibular ramus may be lost but without violating Enlow's objective to assess form and the existence of dimensional horizontal and vertical imbalances. Moreover, the corrective procedure suggested will give a more realistic neutral occlusal axis in its relation to the functional occlusal axis.

The study of growth increments<sup>8</sup> is likewise improved by the more precise definition of horizontal and vertical growth trends which are analyzed as separate entities by Enlow et al.<sup>6</sup>

Nonetheless, the PM line may be retained to define the anatomic boundary of the superior and posterior aspects of the ethmomaxilla at its junction with the cranial floor, as approximated by the outlines of the middle cranial fossa,<sup>7</sup> and the posterior aspect of the maxilla. The cant of this boundary line to the anterior skull base and to the vertical thereby furnishes a key to the basic architectural design of the face.

The principle of natural head posture enhances further exploration of the variations in facial pattern and facial growth with the method of Enlow et al.

#### CONCLUSION

The concepts presented were intended to provide a means for the best utilization of the Enlow et al. analysis of facial form. Natural head posture is a prerequisite for any cephalometric analysis of facial shape to produce a meaningful and useful diagnostic evaluation for treatment planning. Natural head posture makes it possible to use an extracranial vertical reference line rather than reliance on the PM line for orientation. For that matter, the validity of any intracranial line must be established in each individual instance because the biologic variation of

landmarks affects the inclination of the different intracranial reference lines. An extracranial vertical line can be used instead provided that the patient was in natural head posture when radiographed. It is, therefore, suggested that a line through the pterygomaxillary fissure parallel to the vertical be used for orientation of the Enlow et al. grid system.

140 Fenway  
Boston, Mass. 02115

#### REFERENCE

1. Thurow, R. C.: *Atlas of orthodontic principles*, Mosby Co., St. Louis, 1970.
2. Moorrees, C.F.A. and Kean, M.R.: Natural head position, a basic consideration for the analysis of cephalometric radiographs. *Amer. J. Phys. Anthropol.*, 16:213-234, 1958.
3. Downs, W. B.: The role of cephalometrics in orthodontic case analysis and diagnosis, *Amer. J. Orthodont.*, 38:162-182, 1952.
4. Steiner, C.C.: Cephalometrics in clinical practice, *Angle Orthodont.*, 29:8-29, 1959.
5. Enlow, D. H., Moyers, R. E., Hunter, W. S. and McNamara, J. A.: A procedure for the analysis of intrinsic facial form and growth, *Amer. J. Orthodont.*, 56:6-23, 1969.
6. Enlow, D. H., Kuroda, T., and Lewis, A. B.: The morphological and morphogenetic basis for craniofacial form and pattern, *Angle Orthodont.*, 41:161-188, 1971.
7. van der Linden, F.P.G.M., and Enlow, D. H.: A study of the anterior cranial base, *Angle Orthodont.*, 41:119-124, 1971.
8. Enlow, D. H. and Moyers, R. E.: Growth and architecture of the face, *J. Amer. Dent. Assoc.*, 82:763-774, 1971.