

Part  
II

# Abnormal Function of the Temporomandibular Joints and Related Musculature

## Orthodontic Implications

John R. Thompson

---

*Continued from page 163 (April, 1986)*

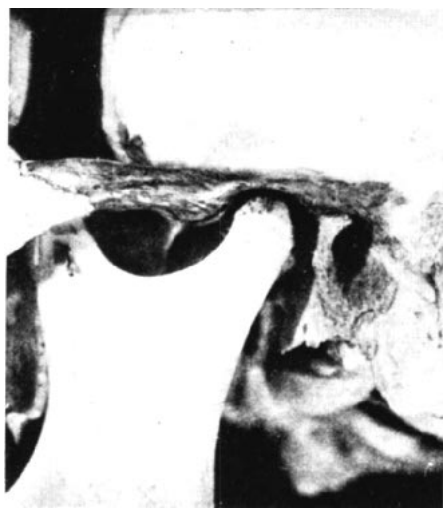### — Functional Relationships —

#### *The Condyle*

A skull dissection (Fig. 15) by the anatomist ARNOLD ZIMMERMAN (1951) shows the close approximation of the anterosuperior surface of the condyle to the posteroinferior surface of the articular eminence. There is considerable space posterior to the condyle that is normally filled with fibrous tissue rich in nerve endings and blood vessels.

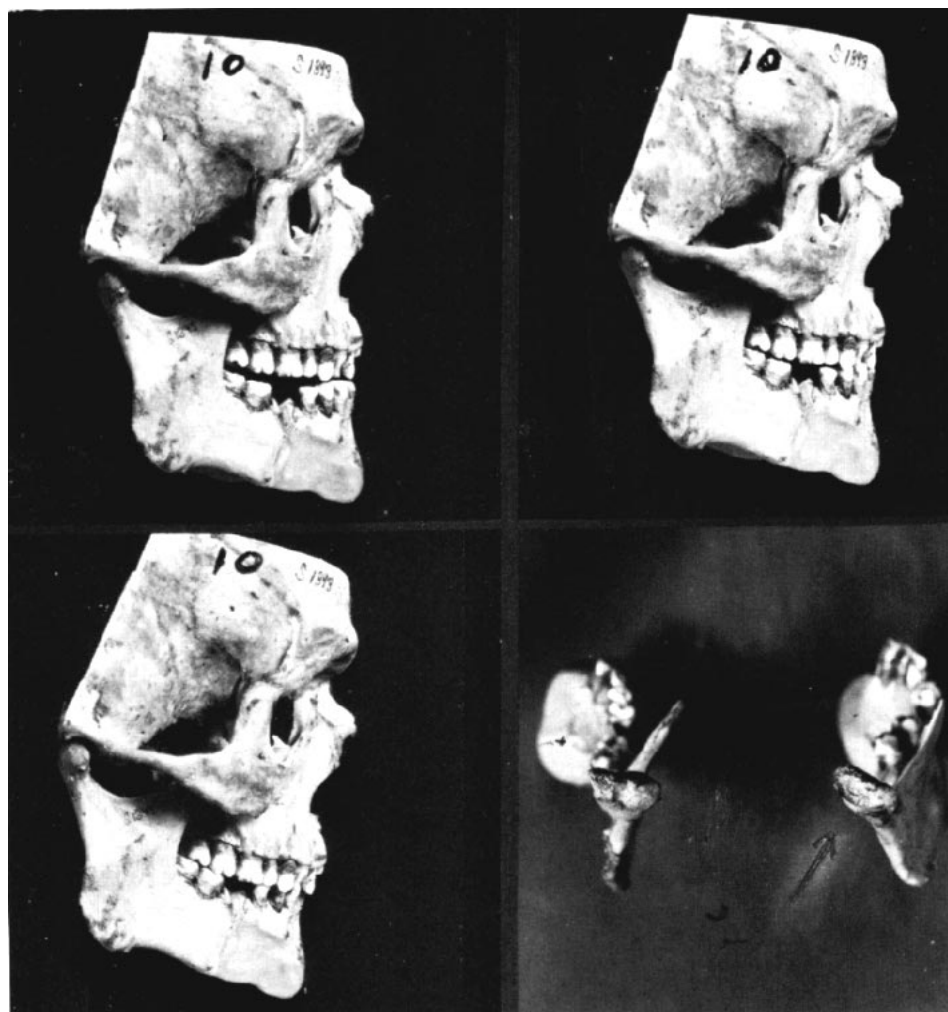
Figures 16 and 17 show two temporomandibular joint dissections on skulls.

The dental malocclusion in Fig. 16 is Class II, but the maxillary incisors cannot be classified as either division 1 or division 2. Such atypical cases frequently involve posterior mandibular displacement. Note the crowding of the maxillary incisors and the absence of a maxillary first bicuspid. The absence of the bicuspid may be the result of either early extraction or congenital absence, which is rare for this tooth; in any event, the space is completely closed.



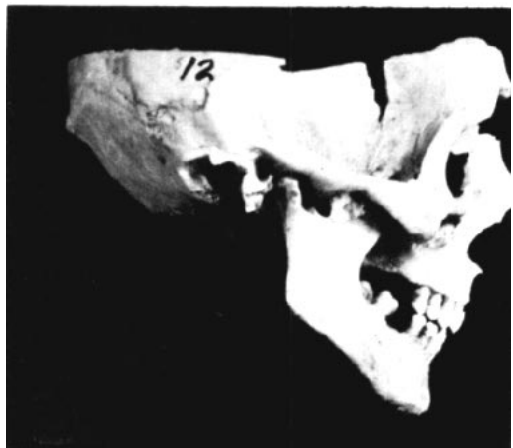
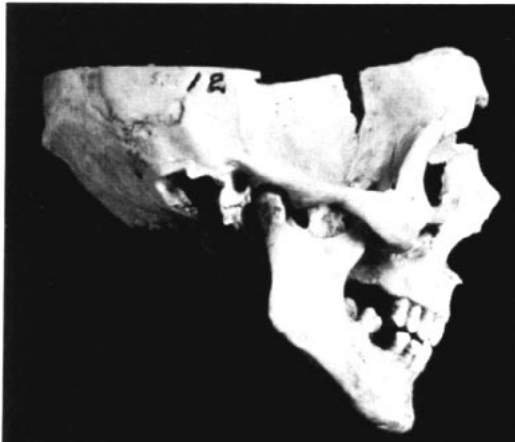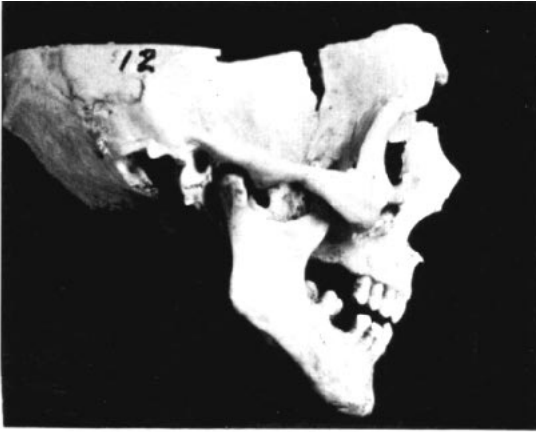**Fig. 15**  
Skull dissection of a temporomandibular joint in full occlusion position, showing proximity of the condyle to the articular eminence.

— Arnold Zimmerman



**Fig. 16**

Skull demonstrating posterior displacement. The first photo is in simulated rest position with the condyle in normal relation to the articular eminence. The second shows incisor interference on normal hinge closure, and the final photo shows full occlusion with posterior displacement. The lower right photo shows posterosuperior condyle erosion.



**Fig. 17**

A series demonstrating the same occlusal dysfunction as the first three photos in Fig. 16, on a different skull.

The dental malocclusion in Fig. 17 is Class I, but the mandibular first and second bicuspid have migrated mesially because of early loss of the cuspid, which is not evident in the photograph.

The maxillary incisors in both skulls are upright and positioned too far to the lingual, causing incisor interference. This is confirmed by the attrition on the labial surfaces of the mandibular incisors and lingual surfaces of the maxillary incisors.

In both skulls, when the mandible is related to the maxilla with the anterosuperior surfaces of the condyles in close apposition to the posteroinferior surfaces of the articular eminences — the normal relation — and the teeth separated to simulate rest position (first photos), the lower incisors are almost directly below the uppers. As the mandibles are rotated in hinge closure, the initial dental contacts are on the incisors (second photos).

Continued closure follows abnormal upward and backward paths to occlusion. In full closure (third photos), there are now large spaces anterior to the condyles. The normal posterior spaces have been reduced so that there is bone contact between the posterosuperior surfaces of the condyles and the postglenoid tubercles and tympanic plates. It is reasonable to assume that this is the situation in the adult case reports that follow.

The final photo in Fig. 16 shows a posterior view of the condyles. Direct examination of the mandibles found bone resorption on the posterosuperior surfaces of the condyles and exostoses of bone on the superior and anterosuperior surfaces, giving the "lopping forward" appearance seen occasionally on radiographs of adults. One might logically ask whether this is the result of abnormal functional loads.

The mandibular condyle can be positioned too far posteriorly by the intercuspatation of the teeth. Figure 18 shows the skulls of individuals approximately 5 and

13 years old. In the first views, both mandibles are related to the maxilla in Class I relation, with the condyles in normal relation to the eminences. There is a small space between the anterosuperior surfaces of the condyles and the posteroinferior surfaces of the articular eminences.

A much larger space is seen behind both condyles. This space is normally filled with fibrous tissue containing nerve endings and blood vessels. In the lower views, the mandibles are shown with the teeth moved into a Class II relation. The condyles are now in bony contact with the postglenoid tubercle and tympanic plate.

### *Dental Relations*

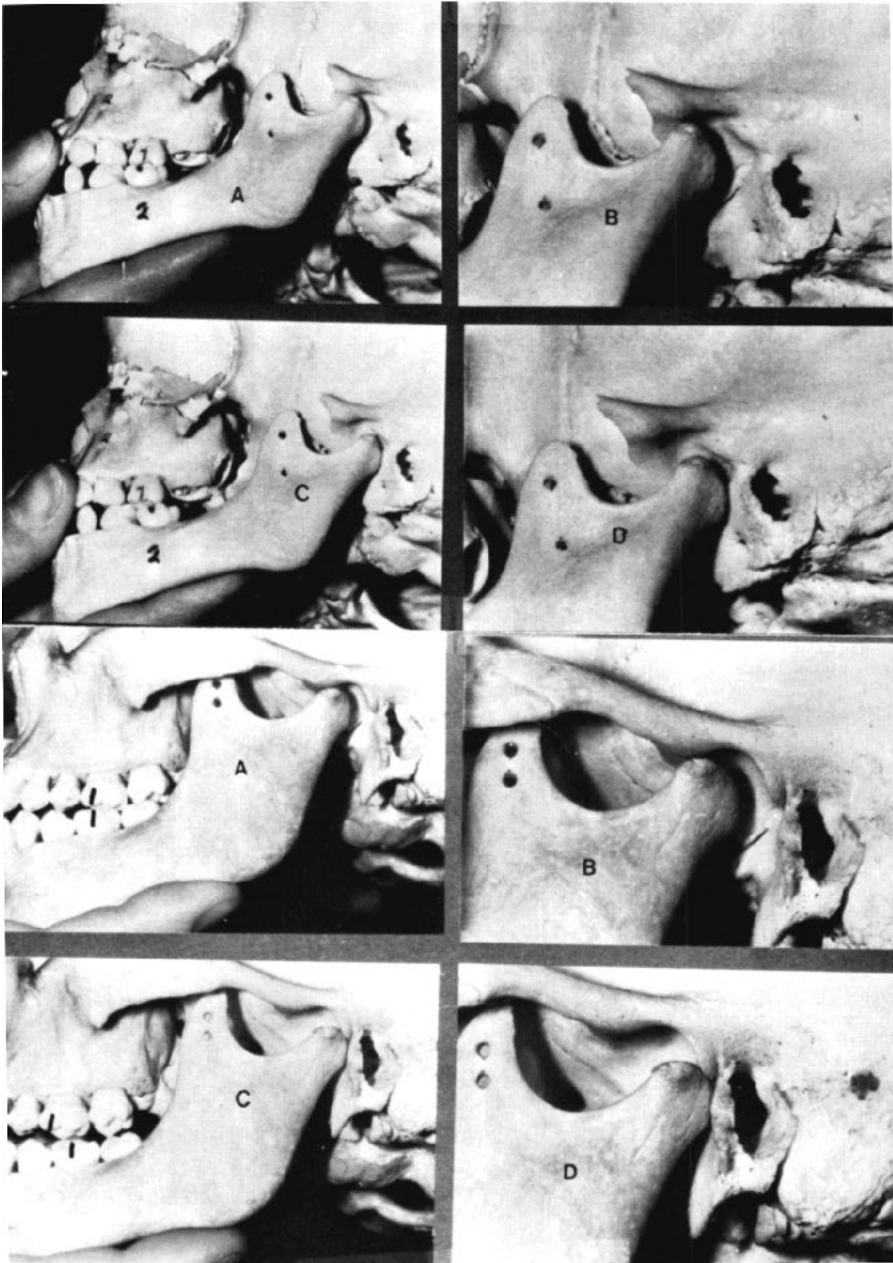
When the teeth play a dominant rather than a passive role, the components of the triad of dentistry — teeth, joints, and muscles — are at odds with one another. The dominant directing tooth structure must be moved by orthodontics or restorative dentistry, or removed by equilibration or extraction.

In straight-face skeletal patterns, functional problems tend to be in the horizontal plane, with incisor interference causing posterior displacement.

In the convex, "poor" pattern face, functional problems tend to be in the vertical plane, with posterior interferences preventing normal relations of condyle, disk and eminence in functional movements. In these subjects there often is no freeway space, due to overeruption of the maxillary molars resulting from abnormal tongue and circumoral muscle function.

### *Incisors*

In many "diagnostic analyses" and appliance-based techniques, the corrected position of the maxillary incisors in the face is dictated by statistically generated



**Fig. 18.** Two skulls, of individuals approximately 5 and 13 years of age. A and B show normal relationships with teeth in habitual occlusion. C and D show the mandibles retruded, with condyles impinging on the tympanic plate and postglenoid tubercle.

or esthetically based "norms" that are unrelated to individual variation or function. There is a great deal more to it than that, and our thinking must be extended beyond the static to the dynamic.

Normal temporomandibular joint function requires that the maxillary incisors be positioned and inclined so that incisor interference does not dictate mandibular position or movement. Normal incisor function involves passive contact of incisors in occlusion and in functional mandibular excursions, with condyle - disk - eminence relations in normal firm contact.

All tooth-contact movements of the mandible should occur within the limits of the freeway space (THOMPSON 1981). Tooth guidance will then not extend the closing muscles beyond their normal postural resting lengths, so that the masticatory force within the musculature diminishes to a minimal level and the teeth can come into contact with only slight pressure.

If tooth guidance is so steep that the closing muscles are lengthened beyond resting length during functional tooth-contacting movements, as when steep incisor guidance causes hinge-opening rotation of the mandible during protrusion, a conflict will exist between muscles and incisor teeth. The directing incisor teeth cause abnormal movements in the temporomandibular joints.

### *Posterior Interferences*

Posterior cuspal guidance that is too steep also creates a conflict between the joints and directing teeth, with frequent muscle involvement.

The descent of the condyle on the eminence normally disarticulates the nonfunctioning posterior teeth, but in molar interference, the molar guidance forces the condyles to follow tooth-dictated paths. The result is flaccid, clicking joints.

The term *flaccid* in this context refers to looseness of the normally taut fibrous attachment of disk to condyle, caused by stretching or tearing of the fibers, so the disk and condyle no longer move in unison. The movement may be difficult, and even painful. The teeth are not passive in these situations; they actually dictate the mandibular movement.

### *Equilibration*

Some carefully selected interferences may be relieved by occlusal equilibration, but this is a very limited procedure. In young teeth, equilibration can quickly intrude into sensitive areas, often before achieving the desired effects. It is best limited to eliminating minor premature contacts of teeth where it is certain that only minimal tooth structure need be removed.

**Posterior mandibular displacement** cannot be corrected by occlusal equilibration. The magnitude of most such displacements requires much greater adjustments than can be achieved by removal of incisor tooth structure. Tooth movement and/or splinting are usually necessary to allow adequate repositioning of the mandible in these cases.

The relationships of normal and abnormal teeth and joints are shown in Figures 19-22.

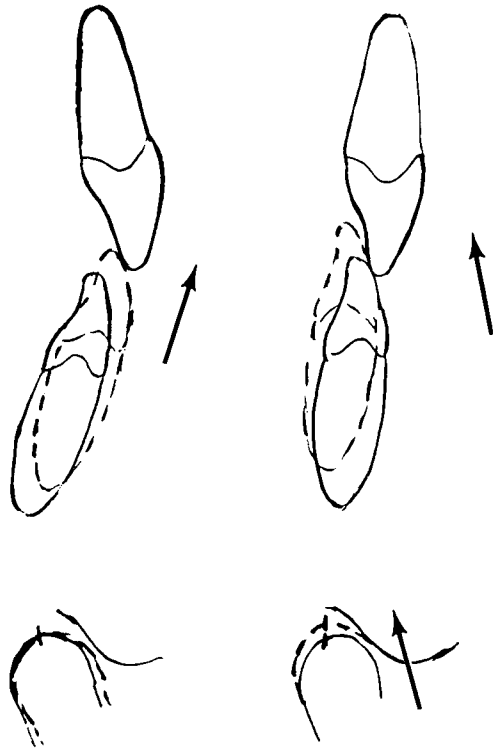
### *Surrounding Structures*

Lateral displacement or posterior displacement of the mandible also involve lateral or posterior displacement of the tongue and hyoid bone.

Specifically, in lateral displacement of the mandible there is imbalance in the extrinsic muscles of the tongue, which can produce spasms in the tongue and hyoid muscles, vague symptoms of teeth pressing on the tongue, inadequate tongue space, tightness in the throat

**Fig. 19**

Normal rest and closed relationships of incisors and condyle are shown on the left. The path of closure is upward and forward, and the condyle rotates with little translation. Incisal interference is shown on the right. The path is upward and *backward*, with the condyle also moving upward and backward. This can force the condyle over the posterior band of the disk, resulting in a *click* as the disk snaps forward.



muscles, and so on. A posterior imbalance can cause bilateral tongue sensations.

#### *Post-orthodontic Problems*

Many orthodontic patients later develop abnormal joint function. This is more often the result of continued mandibular growth after the orthodontic treatment, rather than an effect of treatment.

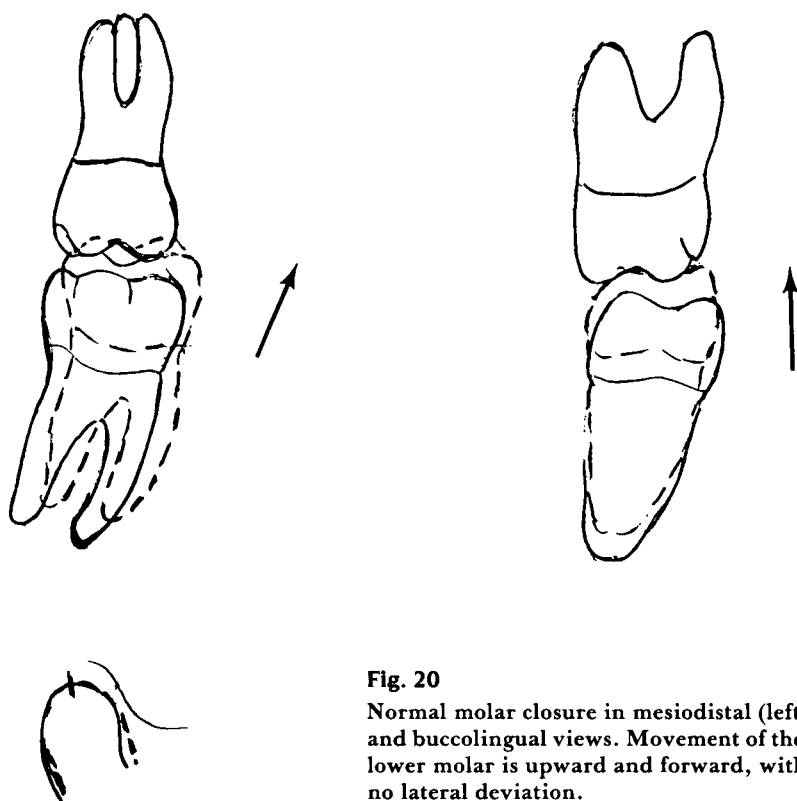
Useful as mandibular growth may be during orthodontic treatment, it can nevertheless produce functional disharmony in later years. Differential growth of mandible and maxilla is a common characteristic of pubertal growth. It is not unusual, especially in straight-type

“good” faces, to see a traumatogenic relation of the incisors in the post-pubertal period in treated or untreated individuals alike.

This can often be anticipated by an increase in the S-N-B angle while the S-N-A angle remains the same.

In time, the premature contact of the incisors may be accompanied by a lengthening of the clinical crowns. In the more pronounced differential growth cases, the continuing superior-posterior condylar growth may produce posterior condyle displacement if compensatory forward movement or positioning of the mandible is inhibited by the the incisor relations.

Such interferences do not impede the anterior shift of the muscular rest posi-



**Fig. 20**

Normal molar closure in mesiodistal (left) and buccolingual views. Movement of the lower molar is upward and forward, with no lateral deviation.

tion of the mandible, so an upward and backward path of closure is exhibited from rest to occlusion. In this condition of posterior mandibular displacement, the condyle is displaced posteriorly and the disk displaced anteroinferiorly on the eminence.

Translatory movements between condyle and disk, not present normally, represent flaccidity of the joint structures with the resultant clinical symptoms of clicking or crepitus, irregular mandibular movement, restriction of mandibular movement, and even pain.

In the normal relation of the condyle, disk and articular eminence described above, the teeth should intercusate passively at the normal structural joint rela-

tion. Should the tooth intercuspation become dominant, an abnormal tooth intercuspation position can follow.

There is no possible way to coordinate the ultimate condyle growth and intercuspation of the teeth in advance of treatment. It is essential, however, to be knowledgeable and alert to disharmonies that may exist prior to, during, and after orthodontic treatment; and to begin the correct therapy, modify existing therapy, or reinstitute therapy as may be required. Such therapy may also include restorative dentistry.

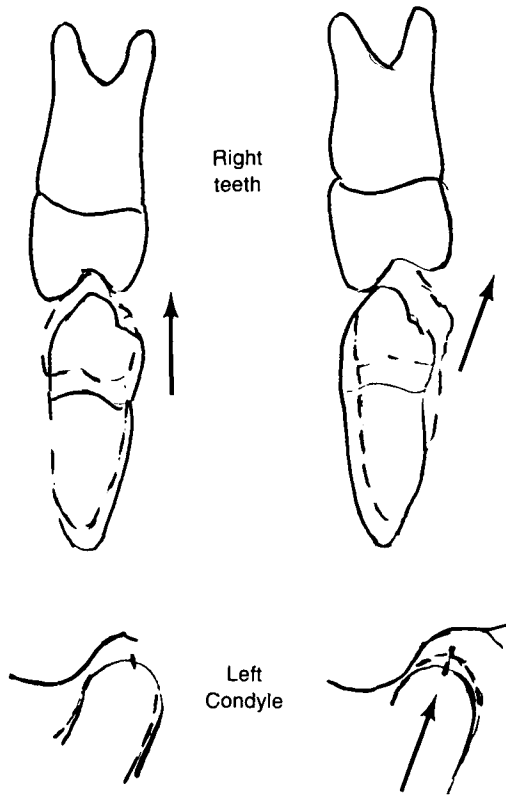
It is important for the orthodontist and restorative dentist to understand that continued mandibular growth, a factor that cannot be controlled by any treat-



**Fig. 21**

*Left, Normal bicuspid closure on the right side as seen in a frontal view; the left condyle is shown directly below.*

*Right, Lateral deviation of the mandible and posterior displacement of the contralateral condyle (lower right) can be caused by an excessively upright or lingually inclined upper bicuspid.*



ment procedure, produces a large percentage of post- pubertal (and post-orthodontic) temporomandibular joint problems. Recognition of this fact will lead to better treatment for these patients.

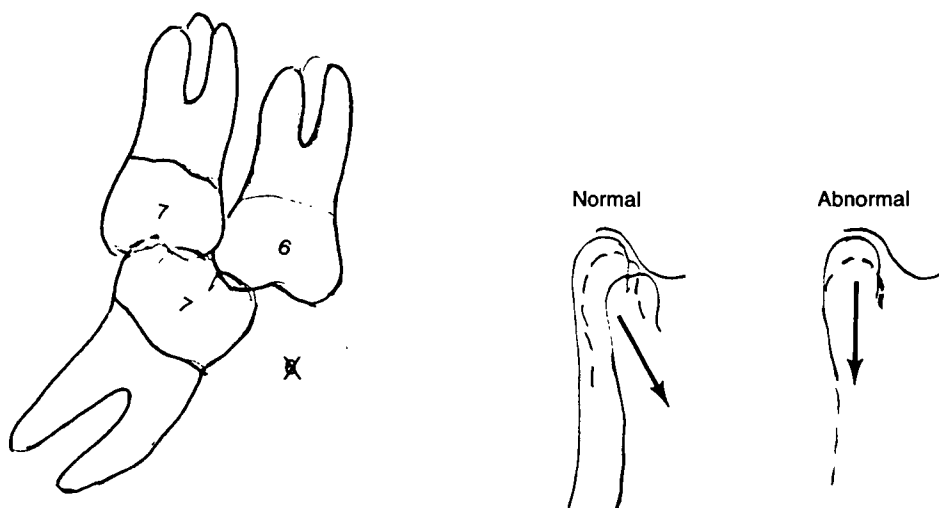
We should not presume that an excellent anatomical occlusion of itself can assure excellent function. This is not intended to demean the occlusal objectives of excellent technical procedures, but enlarges on those goals, with function carrying at least equal priority with morphology.

In the broad perspective, abnormal function occurs when uncontrollable condyle growth continues beyond the

range of normal adaptation. This may call for some consideration beyond the static case records at hand, projecting treatment planning along the line of anticipating mandibular growth based on such factors as the degree of straightness of the face.

When good faces get "better" esthetically, it is usually through increased prominence of the chin. This is dependent on continued condyle growth that can also bring negative functional effects.

Some statement such as the following, describing those possibilities, should be included in the initial consultation letter.



**Fig. 22**

Molar migration following loss of the lower first molar. The maxillary first molar overerupts, and the mandibular second molar inclines mesially. As it tilts, the disto-occlusal surface enters the freeway space. Instead of following the contour of the articular eminence, the condyle must now follow an abnormal tooth-directed path.

*“— should be kept under periodic observation for several years after the orthodontic treatment has been completed, as it is possible for developmental changes such as additional lower jaw growth to introduce abnormal function of the jaw and joints. Should this occur, some additional treatment may be necessary.”*

Such a straight-forward statement of what often occurs in the general population with or without orthodontic treatment provides professional advice that affords protection for both patient and orthodontist.

*References are on pages 162-163 (April, 1986).*

### — Summary —

**T**iming of mandibular growth and orthodontic treatment are coincidental, not cause-and-effect. Comparison of cephalometric radiographic tracings made before, during, and after treatment has shown no evidence that orthodontic forces can either arrest or stimulate growth of the condyle.

Conversely, the growth behavior of the condyles can have a profound effect on the time required to achieve an orthodontic correction and on the anatomic and functional relationships at the end of treatment and later.

Mandibular growth at the moment of orthodontic force application can have important effects on facial growth and function. If there is no growth, the mandible may rotate downward and backward, and condyle displacement and clicking can occur. Future growth rarely leads to recovery of such alterations.

With adequate growth at the moment of orthodontic force application, the freeway space is maintained and horizontal tooth movement does not alter mandibular position.

The position of the maxillary incisors in the face must be based on many considerations going far beyond arbitrary conformity to some "standard" values based on averages. Functional relationships and their effects on the joints are one of those considerations, along with esthetics.

Dynamic thinking requires that maxillary incisors not be over-retracted, anticipating continued growth of the condyle that can reposition the body of the mandible and lower incisors downward and forward. This can occur before, during, or many years after treatment.

If a tight incisor relationship is established, or develops naturally, in the early or midteens, and the condyles later outgrow the maxilla, clicking may well develop. Anterior translation of the mandible with the new growth is impeded by the incisors, so posterior displacement of the condyles occurs instead. This is most likely to occur in straight ("good") faces.

Facial morphology, or pattern, has an impact on function. In the straight facial pattern, these problems usually involve incisor interference. In convex faces, the problems more often involve vertical molar interferences. Each of these presents its own unique problems and treatment requirements.

## Addenda

### — Functional Cephalometric Radiography —

**T**his radiographic procedure records the mandible in the five key functional positions — *rest position, full closure, incision, protrusion, and wide open*. Conventional cephalometric technique is used, with the patient oriented for a lateral view. Five cassettes should be used, so that all exposures can be made without removing the patient from the cephalostat.

Because these exposures involve the mandibular movements that are under diagnostic scrutiny, it is advantageous for the clinician to make them personally, rather than delegate this procedure.

If the joints are painful, it may not be possible to fully seat the ear rods.

Make the rest-position exposure first, engaging the subject in natural conversation. After a pause, ask that they not

move their tongue or lips, and make the exposure.

Make the other exposures in sequence, noting any unusual circumstances such as inability to occlude posterior teeth in protrusion, or midline deviations in protrusion or opening wide.

### *Technic of Tracing Functional Cephalometric Radiographs*

- Attach tracing film over the film made with the mandible *closed*, and trace the cranium, face, one ramus, hyoid bone, and the first three or four cervical vertebrae.
- Begin a mandibular template by making a separate tracing of the mandible from this tracing on a small square of tracing film.
- The condyle may not be clearly discernible on the *closed* or *rest* position films, so the mandibular template can be completed by tracing the condyle from the *protrusion* or *open-mouth* films. The master tracing can then be completed by tracing the condyle from the template.
- Make separate tracings of each film, showing key cranial reference points, mandibular outline, hyoid bone and vertebral column. The mandibular outline is augmented from the template as required.
- Make a composite tracing of the opposite side of the mandible, showing the cranium, face, and mandibular positions.

### *Interpretation*

This series of radiographs will clearly show functional movements of the condyles. Their accurate orientation and exposure at a single sitting eliminates the variables that cloud functional interpretation of other joint radiographs.

- The condyle outline can be clearly seen on the protrusive and open-mouth films with minimal distortion.
- Posterior condylar displacement from rest position to occlusion is clearly outlined on the composite tracing.
- Restricted mandibular movement is clearly evidenced.
- By superimposing the vertebral column tracing with the open mouth on the occlusal film, the amount of backward head rotation can be observed.
- In restricted condyle movement, the hyoid bone will be lower than normal, and it will descend more than normal as the mouth is opened. Such an abnormal opening can be palpated by placing the fingers lightly on the throat and having the subject open and close.
- If the lower incisors continue to move downward and forward from incision to protrusion, molar interference is present.
- If the lower incisor moves in a V path from occlusion to incision to protrusion, incisor interference is present.
- Place the template on the composite and slide it from position to position. One soon develops a sense of any mandibular movement dictated by the dentition.