

Vertical Control in Fully-Banded Orthodontic Treatment

Lloyd Erick Pearson

A review of clinical considerations in the control of vertical dimension, with a statistical evaluation of 79 cases treated with a vertical-pull chincup before and during fixed-appliance therapy.

KEY WORDS: • CHINCUP THERAPY • EXTRAORAL TRACTION •
• GROWTH, MANDIBULAR • VERTICAL DIMENSION •

The importance of controlling maxillary posterior alveolar height to control lower facial height has been stressed many times in recent years. SCHUDY (1963) has suggested that other factors are also involved in vertical control, and merit our attention. He stresses the importance of growth changes in fossa position, nasal septum, maxillary corpus, and mandibular alveolar height.

SCHUDY (1965) points out further that in normal growth in the age range from eight to fourteen years, the maxillary alveolar height increases more than mandibular alveolar height. However, this is often reversed during orthodontic treatment, with the mandibular alveolar height increasing more than maxillary alveolar height.

Three clinical cases demonstrate the difference in lower facial height and in chin position with different amounts of vertical change. Treatment of all of these patients included the extraction of four first bicusps. All three of these patients had similar skeletal patterns, and approximately the same amount of effective condyle growth as measured by the method of CREEKMORE (1967). This measurement is a composite increment which is a summation of condyle growth, glenoid fossa changes, and positional changes of the condyle in the fossa. A pinhole is punched through both tracings in the area of the head of the condyle, with the tracings superimposed along S-N registered at S. (Fig. 1). Then, with the mandibles superimposed along the mandibular plane and registered at the posterior inferior border of the symphysis, the distance between the pinholes is measured (Fig. 2).

Author Address:

Dr. Lloyd Pearson
263 Southdale Medical Building
Minneapolis, MN 55435

Dr. Pearson is in the private practice of orthodontics in Minneapolis, Minnesota. He is a dental graduate (D.D.S.) of the University of Minnesota, and also holds an M.S.D. degree in orthodontics from the same institution. He is a Diplomate of the American Board of Orthodontics.

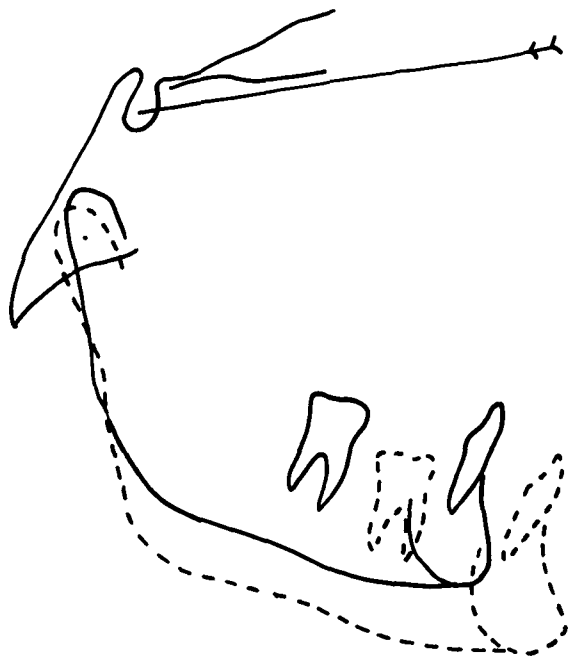


Fig. 1
Tracings are superimposed on S-N at S, and a pinhole then punched through both tracings in the area of the condyle.

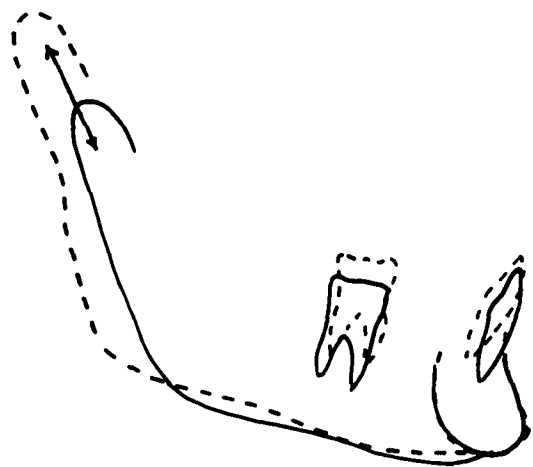


Fig. 2
The mandibles are superimposed and the distance between the pinholes is measured.

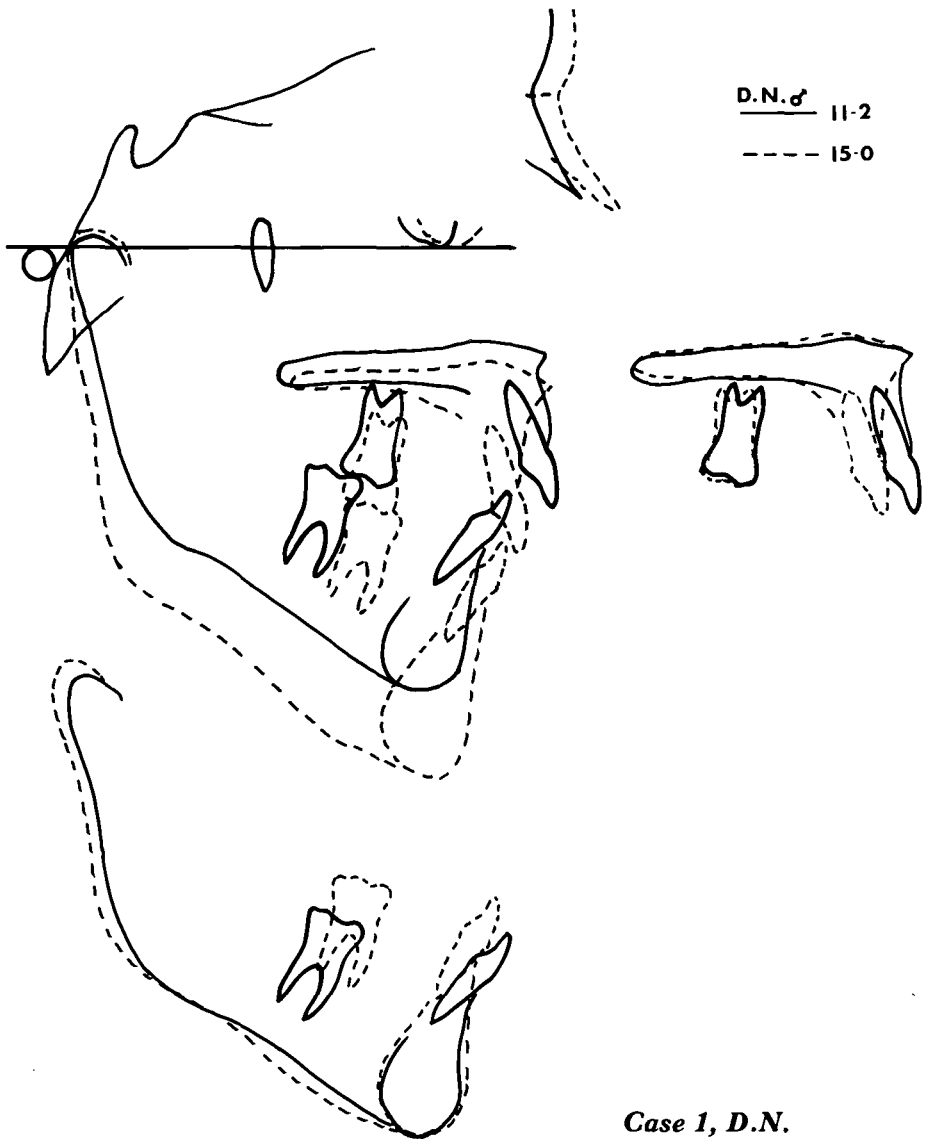


Fig. 3 Case 1, D.N.

Treatment included maxillary control, but there was considerable lower molar extrusion. The lower molar height increased from 31mm to 41mm, and lower facial height increased from 64mm to 74mm.

**Case 1, D.N.
Figure 3**

This patient was a boy with a persistent mouth breathing habit caused by an allergy that was not amenable to treatment. The cephalometric tracings reveal 4mm of effective condyle growth, good vertical control, and significant retraction of the upper anterior teeth.

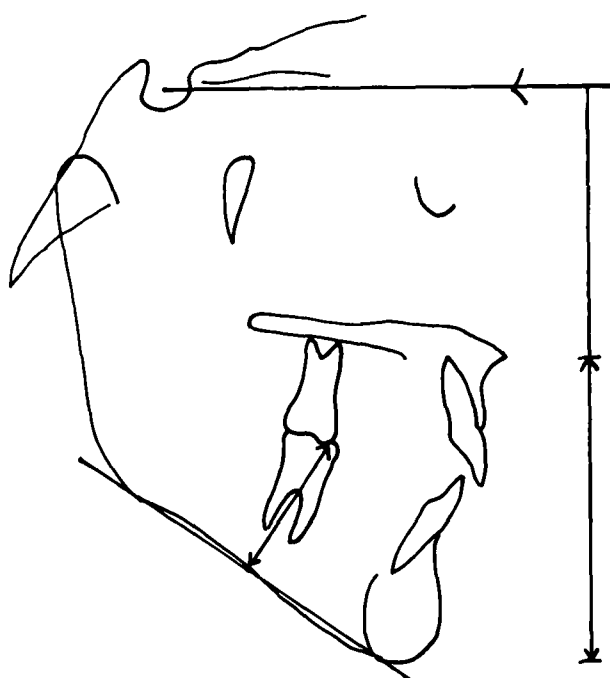


Fig. 4

Lower molar height is measured from the mandibular plane to the mesiobuccal cusp of the lower first molar. The lower facial height is measured from ANS to Menton on a perpendicular drawn from Sella-Nasion.

His treatment included an occipital headgear, with the inner bow fitted to buccal tubes on the upper first molars and the outer bow extended past the upper molars. The extraction spaces were closed with en masse retraction.

There was a 10mm increase in the lower molar height, from 31mm to 41mm, as measured from the mandibular plane to the mesiobuccal cusp of the lower first molar (Fig. 4). Usually, a 1.5mm increase in the lower molar height can be expected in an untreated normal individual during a two-year period (RICKETTS 1960 AND CREEKMORE 1967), indicating that D. N. experienced an increase in lower molar height 8.5mm in excess of what would be anticipated.

The lower facial height increased 10mm, from 64mm to 74mm (Fig. 4). McNAMARA (1981) has reported that the lower facial height would typically increase 1mm per year in an untreated individual, indicating an excess in D. N. commensurate with the molar height increase. The tracings reveal that the chin moved straight down, with no forward component, even though there was 4mm of effective condyle growth.

The conclusion that might be drawn suggests that, if better mandibular alveolar height control had been achieved, the chin would have moved farther forward. The final result would then have been better facial balance and greater stability during the post-retention period.

Case 2, D.B.**Figure 5**

Also showing 4mm effective condyle growth, D. B. is an example of a patient who was treated without any intrusive forces in any of the buccal segments. There was significant molar height increase in both arches, and the resultant lower facial height effect was an 8mm increase.

The chin rotated down and back in a worsening direction. This is an extreme change when compared to the Burlington Centre craniofacial templates (POROVICH 1977). The pattern that began in the average range exhibited severe backward rotation. The conclusion must be drawn that these changes, which were probably induced by treatment, were very deleterious. Such changes should be avoided whenever possible.

Case 3, S.J.**Figure 6**

Effective condyle growth in this patient was 6mm. Treatment included intrusive forces to the buccal segments of both arches. In the maxillary arch, these forces were derived from an occipital headgear attached to the upper first molars. In the mandibular arch, intrusive forces were developed from light (6 oz) cervical traction applied to the lower first molars. These extraoral forces were directed as close to the center of resistance as possible to avoid tipping effects (KUHN 1968).

The lower molar height increased 1mm, which is similar to what one would expect without treatment (RICKETTS 1960 AND CREEKMORE 1967). Comparison of the resulting chin position with those in Figs. 3 and 5 is most revealing. The overall picture shows a small amount of molar extrusion, less facial height, and a better chin position.

Case 4, S.M.**Figure 7**

This patient exhibited an extreme 22mm of effective mandibular growth. With such a large amount of growth at the condyle, a proportionate increase in maxillary and mandibular alveolar height is needed for a harmonious facial growth pattern.

Anticipating such growth potential before initiating treatment can be very beneficial. BJÖRK (1963 AND 1969) has described a structural method for predicting growth rotation from a single cephalograph. This can help in deciding whether extrusive or intrusive posterior forces may be desirable, and whether an effort should be made to change some environmental factors.

If the changes in mandibular alveolar height with different treatment methods are compared with the increases that occur normally in untreated samples, some significant results become evident (Table 1). In untreated groups reported by CREEKMORE (1967) and RICKETTS (1960), the lower molar height typically increased by an average of about 1.5mm over a 30mo period. Looking at nonextraction treatment, one study (CREEKMORE 1967) reports a mean vertical height increase of 2.2mm. In a study of nonextraction anchorage preparation, DOUGHERTY (1968) reports 2.6mm mean lower molar height increase.

Different methods of providing intrusive forces to the lower posteriors show significant differences in the amount of extrusion of the lower molars. Some of the most effective methods approached the low amount of vertical development that would occur normally without orthodontic treatment.

In a series of extraction cases, this Author found a lower molar height increase of 3.2mm (PEARSON 1973). DOUGHERTY (1968) reported a similar value of

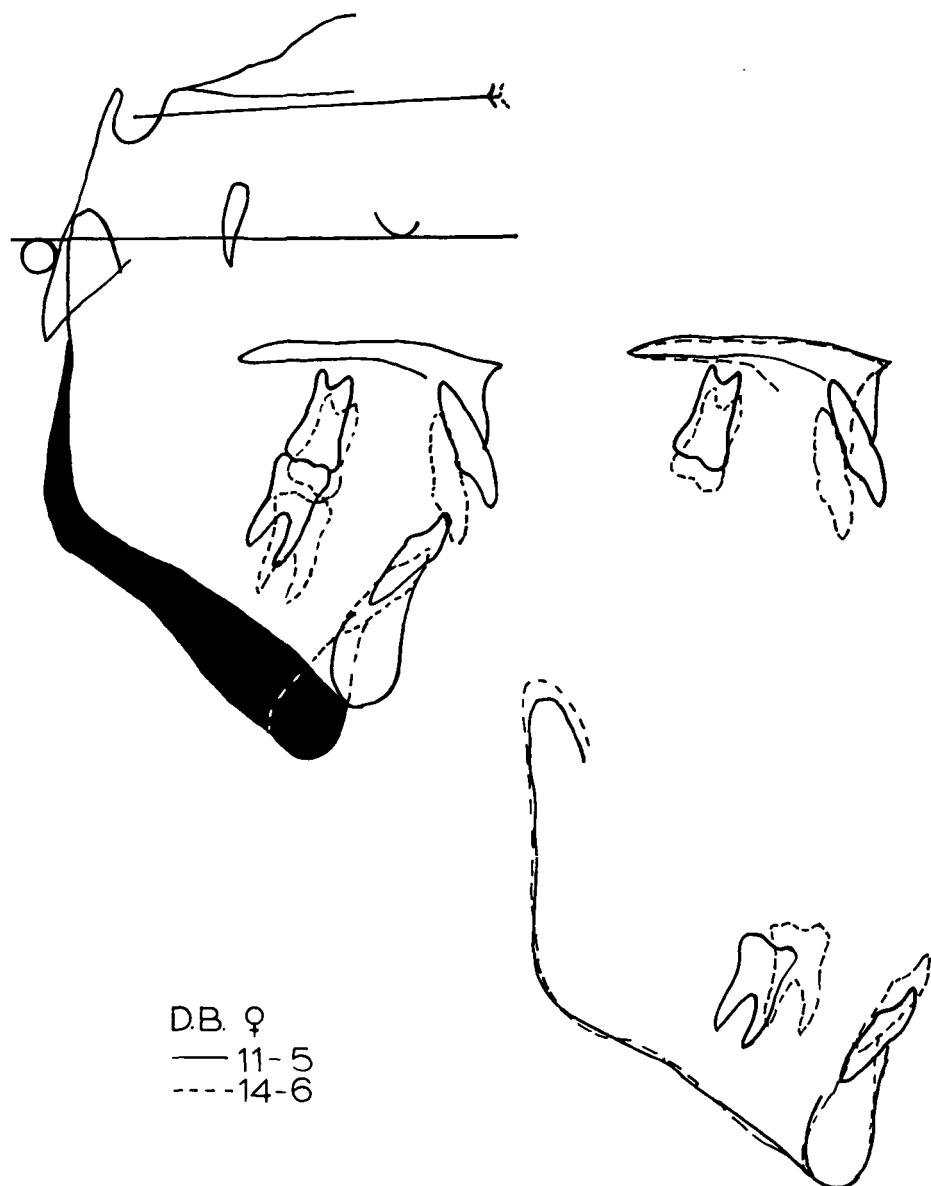


Fig. 5 Case 2, D.B.
Treatment did not include any intrusive forces in the buccal segments. The lower molar height increased from 36mm to 42mm, and lower facial height from 66mm to 74mm.

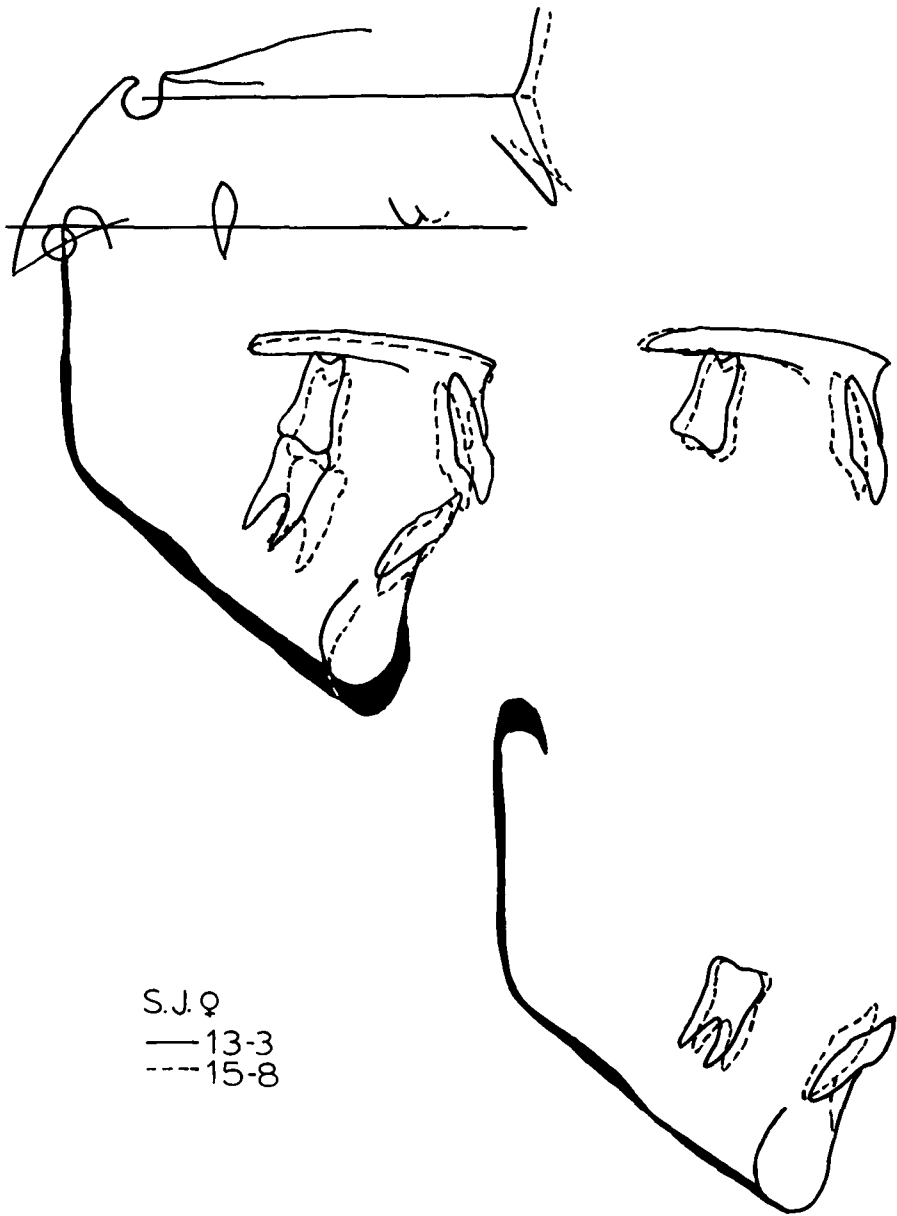


Fig. 6 Case 3, S.J.

Intrusive forces were applied to both buccal segments. The lower molar height increased 1mm during treatment, and the lower facial height increased from 63mm to 67mm.

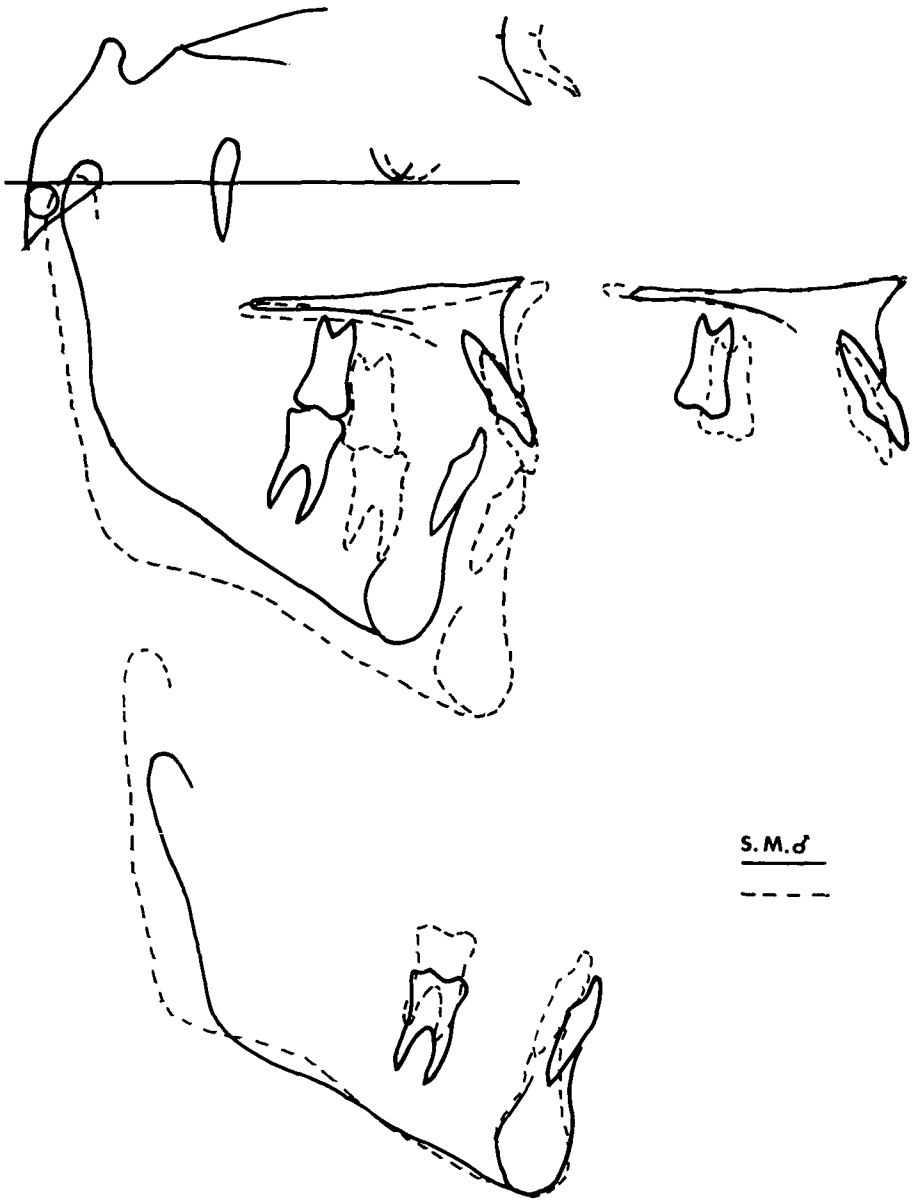


Fig. 7 Case 4, S.M.

This patient experienced an extreme amount of effective mandibular growth (23mm). A proportionate increase in alveolar heights is necessary for a harmonious facial pattern.

Table 1

Average Height Increase Measured from the Mandibular Plane (mm, over a 30mo period)	
Untreated controls ^{1, 2}	1.5
Nonextraction treatment ¹	2.2
Nonextraction, anchorage preparation ³	2.6
Extraction ⁴	3.2
Extraction, anchorage preparation ³	3.5
Extraction, lower headgear ⁴	1.9
Extraction, sliding jigs to lower molars ⁴	1.5
¹ — Creekmore (1967) ² — Ricketts (1960) ³ — Dougherty (1968) ⁴ — Pearson (1973)	

3.5mm of extrusion in those undergoing Tweed anchorage preparation. When extraction cases were treated with intrusive forces derived from a lower headgear to the lower molars, there was only a 1.9mm average increase in the lower molar height (PEARSON 1973). In another group of extraction cases treated with sliding jigs to the lower molars, without anchorage preparation, 1.5mm lower molar height increase was found (PEARSON 1973).

Case 5, D. P.

Figure 8

This patient was treated with four first bicuspid extractions and a vertical-pull chincup while waiting for teeth to erupt. During this period, her mandibular plane closed from 46° to 42°, as measured to S-N.

During the fixed-appliance therapy, her mandibular plane continued to close, from 42° to 40°, and the change in mandibular morphology was evident on the

tracings. This response is typical of what has been seen with extraction cases using a vertical-pull chincup prior to placement of fixed appliances.

The mandibular images were superimposed in two different ways for evaluation —

- 1) along the mandibular border and the symphysis, and
- 2) as suggested by Björk (1969), with the mandibular images superimposed using the mandibular canal, the lower crypt of the developing third molars, and the inner cortical layer of the symphysis.

There is a moderate difference between the two methods because of the remodeling that occurs along the mandibular border.

In a thesis at Case Western Reserve University, DiPALMA (1982) analyzed a number of these factors on a series of patients treated with four first bicuspid extractions and a vertical-pull chincup.

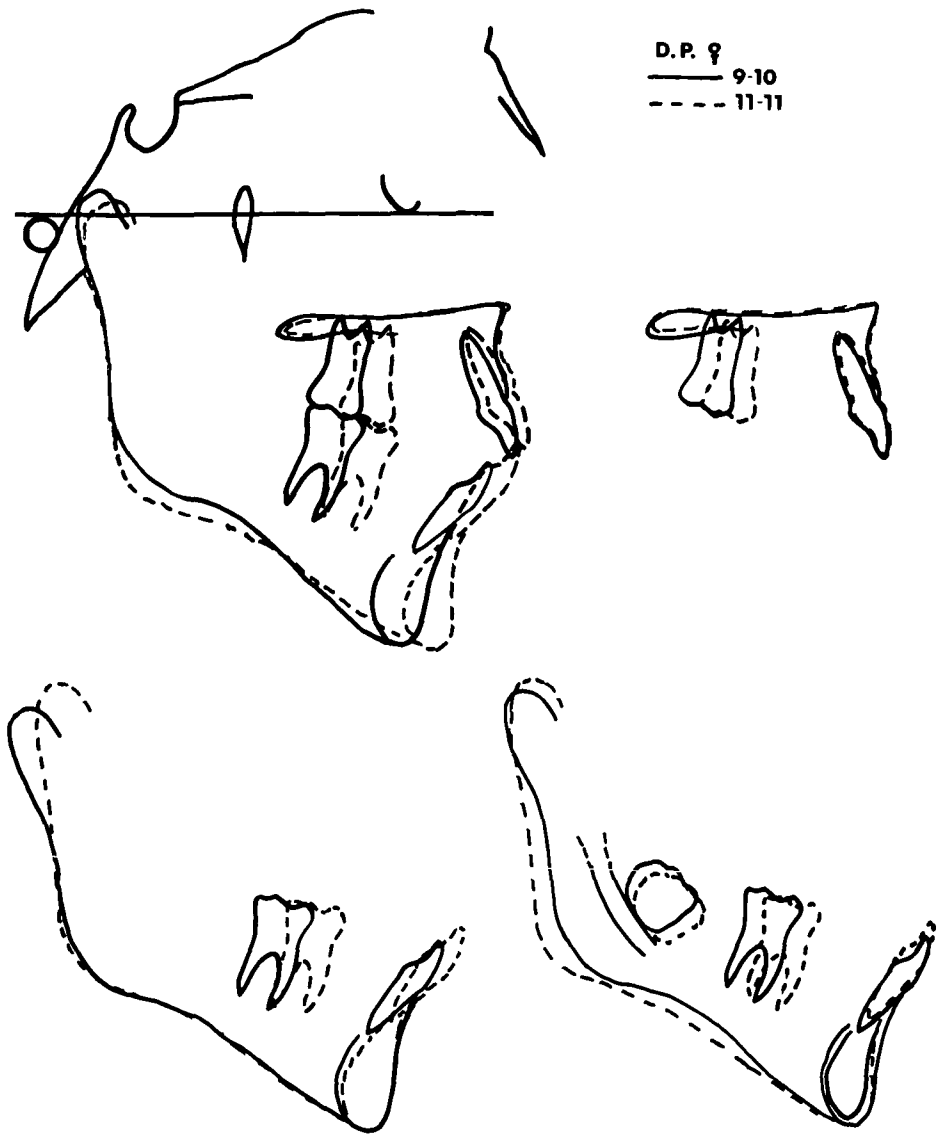


Fig. 8 Case 5, D.P.

Treatment was initiated with the extraction of all four first bicuspid, followed immediately by a vertical-pull chin cup. Fixed appliances were used for the final treatment phase. The mandibular plane angle closed 6° during treatment. Note that the left mandibular tracings are superimposed on the mandibular border and symphysis, and the right mandibular tracings are superimposed on internal mandibular structures.

Table 2

**Effects of Vertical Pull
Chin Cup Therapy
in Four-bicuspid Extraction
Treatment**

Mandible

Posterior ramus rotation
Superior rotation of mandibular corpus
Hypodivergent (closing)
rotation of the occlusal plane
Hypodivergent (closing)
rotation of the mandibular plane
Decrease in the gonial angle

Maxilla

Hypodivergent (closing)
rotation of the palatal plane

Cranial Base

Cranial base angle more acute

Teeth

Increased Curve of Spee
Mandibular first molars moved
anteriorly more than the
maxillary molars

Anterior Facial Height

Decreased

ENLOW's (1971) counterpart analysis was used to evaluate these changes, which are shown in Table 2.

This Author has previously reported on 20 patients who had four bicuspids extracted, followed by a vertical-pull chincup for an average of nine months prior to banding (PEARSON 1978). The mandibular plane closed an average of 3.9° , and the open bites all closed. These were young, growing patients, 11 females and 9 males. All presented steep mandibular planes ranging from 37° to 48° .

There was a statistically significant difference between the mean values prior to the placement of the vertical-pull chin-cup and following that stage of therapy. This study demonstrates an effective way to close the bite and rotate the mandible prior to banding (Table 3).

A question still to be answered is — What changes can be expected after fixed appliances have been placed and treatment completed?

Table 3

**Mandibular Plane Angle Changes
20 patients, 11 females and 9 males**

	Age (years)	Time Worn (months)	Go-Gn/S-N before	Go-Gn/S-N after	Diff.
Mean \pm SD	11.5 \pm 1.2	9.4 \pm 4.1	41.9° \pm 3.4°	38.0° \pm 3.3°	3.9 \pm 1.4°
Range	9.0—13.5	5—18	37°—48°	35°—46°	1°—6°
SE of differences .319					
T value 9.09					

— Design of Project —

Seventy-nine patients with excessive vertical dimension and backward growth rotation patterns were selected for treatment with a vertical-pull chin cup in addition to the necessary fully- banded fixed appliances. The fixed appliance consisted of an .022" Edgewise appliance with all teeth banded, including upper and lower second molars when erupted. A maxillary occipital headgear was also used when indicated.

The patients were evaluated in groups, according to the amount of cooperation shown in wearing the vertical-pull chin cup. This was determined from a questionnaire sent to their home and filled out by either a parent or the patient. Four categories were used:

- E — Excellent Cooperators 10-12hrs/day
- G — Good Cooperators 8-10hrs/day
- P — Poor Cooperators 4-8hrs/day
- VP — Very Poor Cooperators < 4hrs/day

The groups were compared, and the following measurements reported:

- Mandibular plane angle, S-N/Go-Gn
- Lower molar height, as measured from the mesiobuccal cusp of the lower first molar to the mandibular plane (Fig. 4)
- Lower facial height, measured from ANS to Menton on a perpendicular to S-N (Fig. 4)
- Effective condyle growth, after Creekmore
- Height change during treatment

Table 4

Table 4				
Mean Increases in Vertical Height With Vertical Chincup Traction				
Group 1 — Excellent cooperation, 10-12 hrs/day		Group 3 — Poor cooperation, 4-8 hrs/day		
Group 2 — Good cooperation, 8-10 hrs/day		Group 4 — Very poor cooperation, < 4 hrs/day		
<hr/>				
Extraction Treatment (N= 51)				
	Group 1 (13)	Group 2 (21)	Group 3 (13)	Group 4 (4)
Facial Height Increase (mm)	+2.6	+5.1	+3.9	+ 6.5
Lower Molar Extrusion (mm)	+3.5	+4.2	+3.2	+ 5.8
Mandibular Plane Angle Change (°)	-1.7	-0.4	-0.8	- 2.8
Effective Condyle Growth (mm)	+9.8	+7.9	+7.4	+11.3
<hr/>				
Nonextraction Treatment (N= 28)				
	Group 1 (2)	Group 2 (10)	Group 3 (10)	Group 4 (6)
Facial Height Increase (mm)	+6.0	+2.0	+4.9	+6.2
Lower Molar Extrusion (mm)	+2.0	+1.9	+2.3	+3.5
Mandibular Plane Angle Change (°)	-2.0	-2.6	+1.1	+1.2
Effective Condyle Growth (mm)	+8.0	+4.9	+6.2	+7.5

— Results and Discussion —

Results are presented in Table 4.

Excellent cooperators in the extraction treatment group showed significantly less lower molar extrusion than the very poor cooperators, an average of 3.5mm compared to 5.0mm. This is a statistically significant difference at the $P < .004$ level.

Facial height increase averaged 6.5mm in the very poor cooperators.

Generally, the nonextraction cases exhibited less molar extrusion than did the extraction cases (Table 5). Similar comparisons can be made for all four cooperation groups.

If we compare the male sample of 31 patients with the female sample of 48 patients, there are some interesting differences. Generally, everything that was measured in the male sample occurred to a greater degree than in the female sample, including facial height increase (Table 6).

Case 6, B.K. Figures 9 and 10

This patient was treated with extraction of all four first bicusps, followed by a vertical-pull chin cup for the six months prior to the placement of fixed appliances. His mandibular plane closed from

Table 5

Summary Comparisons Extraction vs. Nonextraction Treatment

	Extraction	Nonextraction	P value
Facial Height Increase (mm)	+4.5	+4.3	+.632
Lower Molar Extrusion (mm)	+4.2	+2.4	+.000
Mandibular Plane Angle (°)	-1.4	+0.6	+.011
Effective Condylar Growth (mm)	+9.1	+6.7	

Table 6

Mean Treatment Changes Males and Females

	Males (31)	Females (48)	P value
Facial Height Increase (mm)	+ 6.5	+3.6	+.000
Lower Molar Extrusion (mm)	+ 4.5	+2.8	+.000
Mandibular Plane Angle Change (°)	- 1.8	- .3	+.053
Effective Condylar Growth (mm)	+11.6	+5.6	+.000

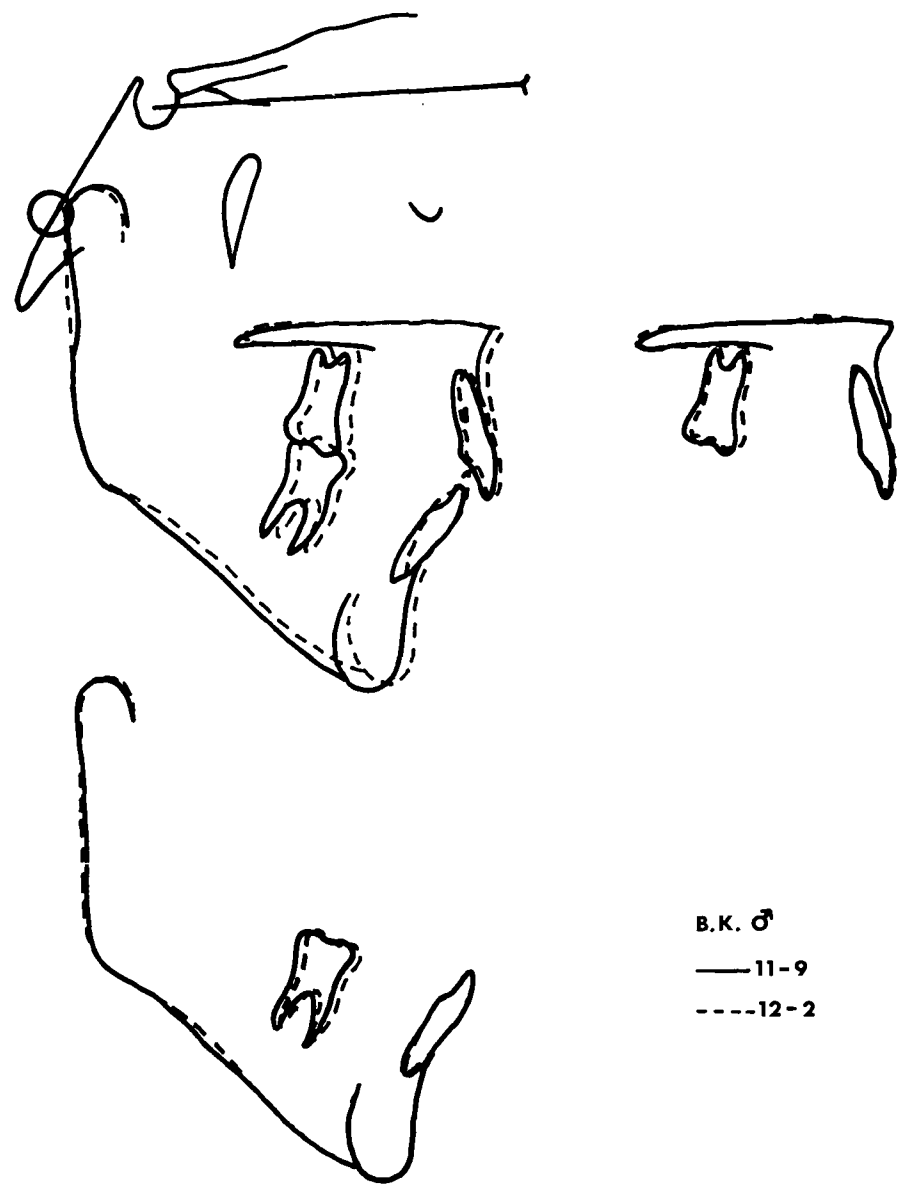


Fig. 9 Case 6, B.K., first phase
A vertical-pull chin cup was used for six months prior to the placement of fixed appliances. The mandibular plane closed 4°, and the lower facial height remained unchanged at 71mm.

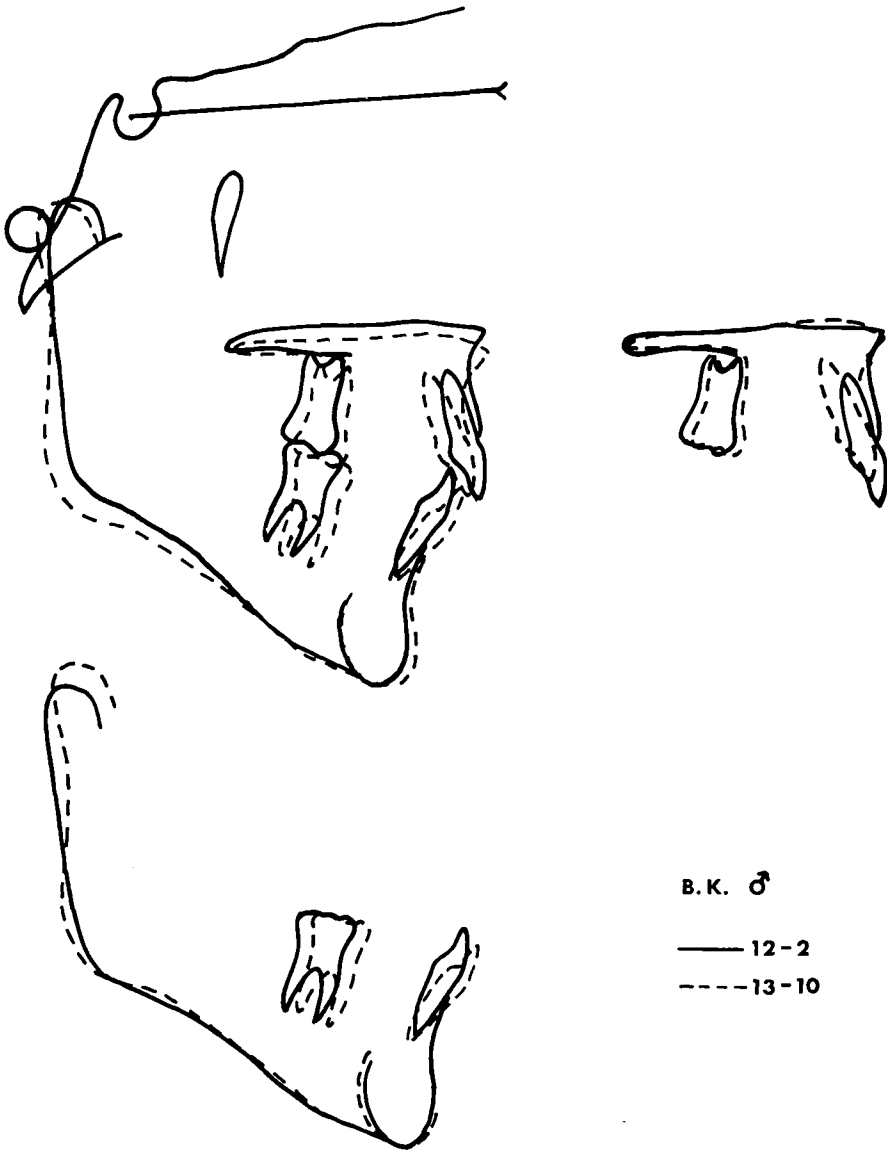


Fig. 10 Case 6, B.K. second phase

The vertical-pull chin cup used prior to fixed appliances was continued throughout this 20-month phase as well. His mandibular plane closed 4° in each phase, for a total closure of 8° (from 42° to 34°). The lower facial height decreased from 71mm to 67mm.

42° to 38° during this preparatory stage. The vertical-pull chincup was continued, along with an occipital headgear, during the 20 months of fixed-appliance therapy.

His mandibular plane continued to close, from 38° to 34° (Fig. 10). Facial height decreased from 71mm to 67mm, as measured on a tangent perpendicular to S-N after the method of ISAACSON (1971). He was an extremely cooperative patient; in the report that his mother filled out following treatment, she indicated that in approximately two years he had only missed two nights with his vertical-pull chincup.

Case 7 A.S. Figures 11-14

This was a Class II, division 1 malocclusion, with an 8.8mm overjet and backward rotation of the mandible. Both upper first bicuspid and both lower second bicuspid were removed.

She wore an occipital headgear and vertical-pull chincup, together with an upper anterior intrusion assembly as advocated by BURSTONE (1966), for five months prior to the placement of fixed appliances. The anterior intrusion assembly consisted of upper molar bands, an upper transpalatal arch, upper incisor brackets with passive edgewise segments in the brackets, and a base arch for intrusion of the incisors.

The first phase of treatment was followed by fixed appliances for 23 months, for a total of 28 months of treatment.

During this period, her mandibular plane closed from 42° to 37°, and her facial height decreased from 65mm to 61mm. Her facial angle (H angle) changed from 12° to 8°. The effective condyle growth was 7mm. Her A-N-B difference dropped from 6° to 3°. She was extremely cooperative in the wearing of her appliances, and the illustrations show the effects that were achieved.

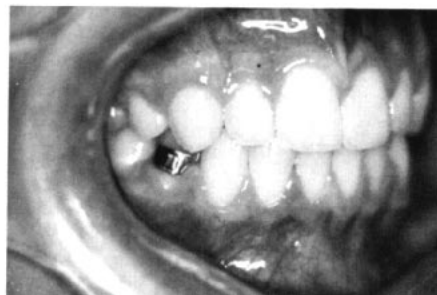
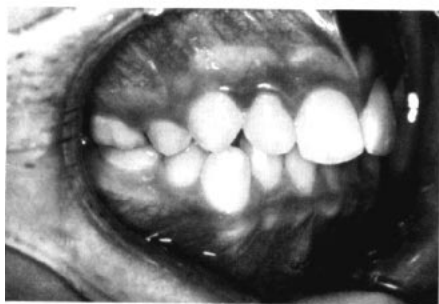
Fig. 11 Case 7, A.S. Dental photographs before and after treatment

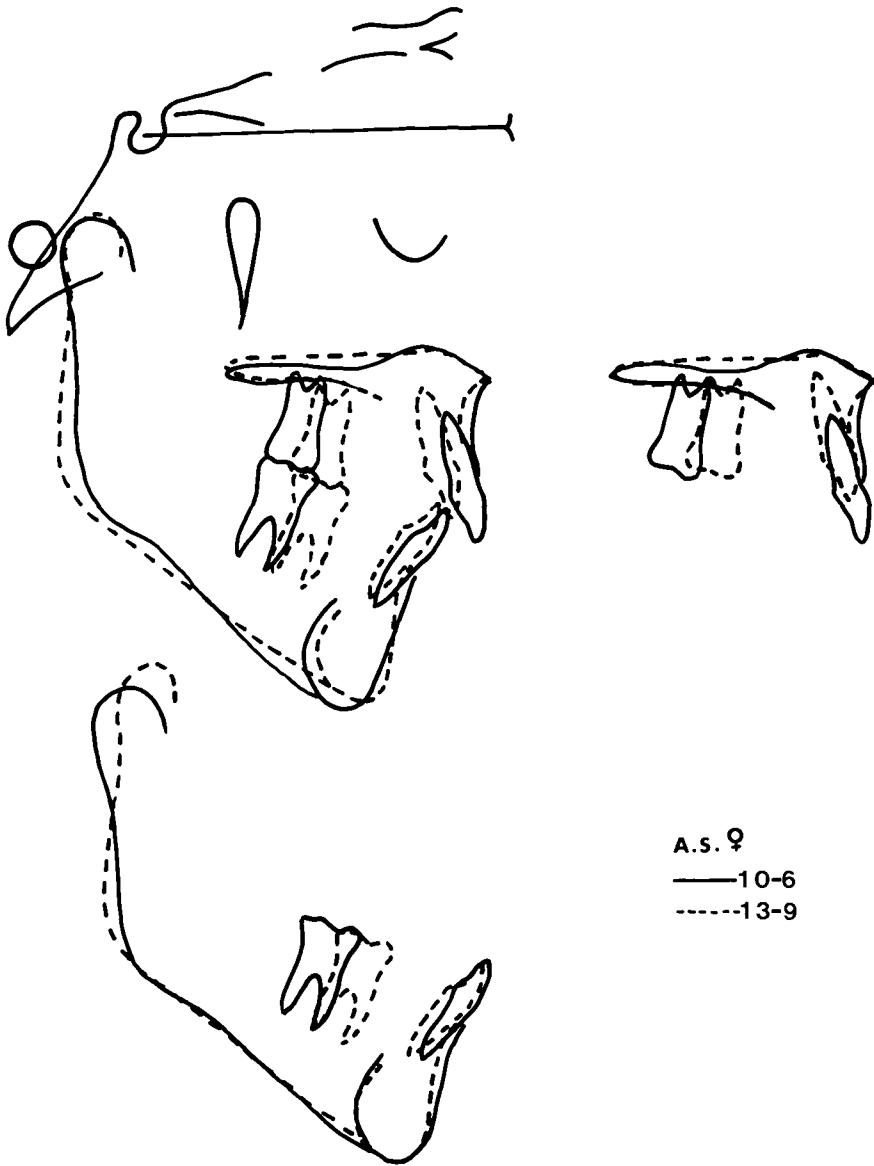


Fig. 12 Case 7, A.S.

An occipital headgear combined with an upper anterior intrusion assembly was used in addition to a vertical-pull chin cup in the first phase of treatment. Her mandibular plane closed from 42° to 37° , and her facial height decreased from 65mm to 61mm.

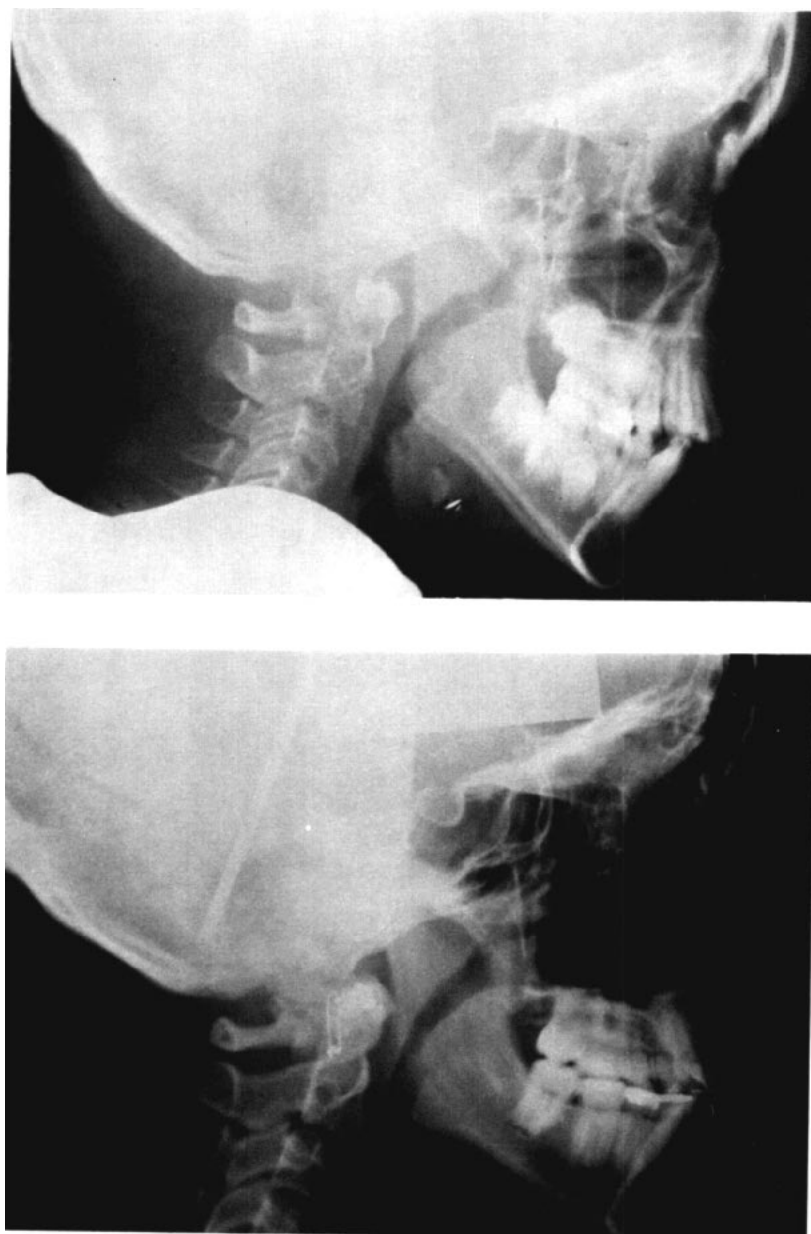


Fig. 13 Case 7, A.S.
Cephalometric Radiographs before and after treatment

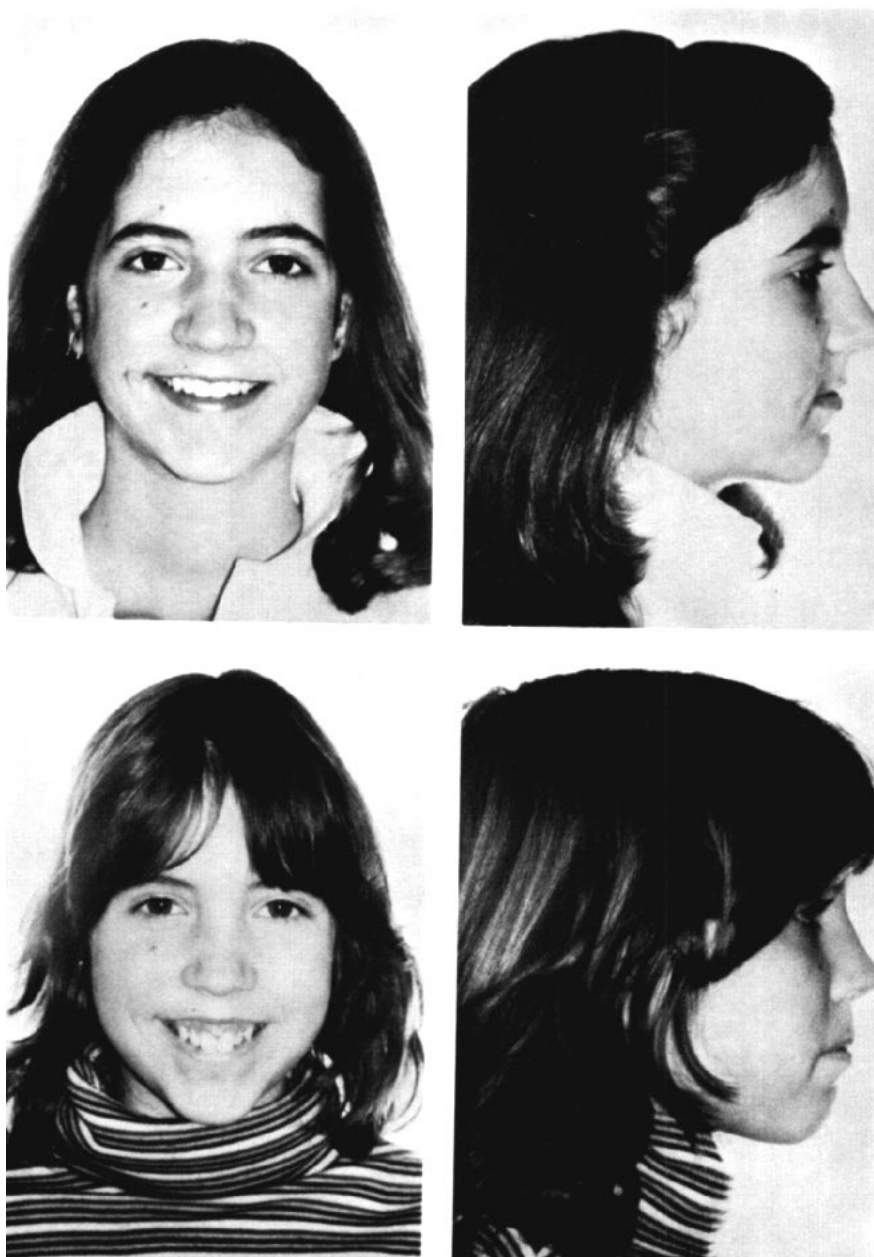

Fig. 14 Case 7, A.S.
Facial photographs before and after treatment

— Summary and Conclusions —

- Extrusion of posterior teeth and an accompanying lower facial height increase are undesirable side-effects in a backward-rotating type of patient. Adjuncts or adjustments to fully-banded appliance therapy should be considered when any increase in the lower face height would be detrimental.
- Vertical-pull chincup therapy can be a useful treatment procedure in certain backward-rotating patients.
- Cooperation is essential, requiring great care in selection and motivation of patients.

There are a number of treatment methods that can be useful in controlling posterior alveolar heights and consequently the lower face height and chin position. These methods may include several not reported here, such as certain functional appliances like the Fränkel, mandibular bite blocks, functional appliances designed to prevent further posterior vertical development, differential extractions, and perhaps lip seal exercises. Surgery may also be indicated in extreme cases. The future is full of exciting possibilities as orthodontists continue to gain additional control in this portion of their therapy. A/O

REFERENCES

- Björk, A. 1963. Variations in the growth pattern in the human mandible: longitudinal radiographic study by the implant method. *J. D. Res.* 42:400-411.
- Björk, A. 1969. Prediction of mandibular growth rotation, *Am. J. Orthod.* 55:585-599.
- Burstone, Charles J. 1966. The mechanics of the segmented arch techniques, *Angle Orthod.* 36:99-120.
- Creekmore, T. D. 1967. Inhibition or stimulation of the vertical growth of the facial complex, its significance to treatment, *Angle Orthod.* 37:285-297.
- DiPalma, Dennis M. 1982. *A morphometric study of orthopedic and functional therapy for the hyperdivergent skeletal pattern.* Masters Thesis, Case Western Reserve University.
- Dougherty, Harry L. 1968. The effect of mechanical forces upon the mandibular buccal segments during orthodontic treatment, *Am. J. Orthod.* 54:29-49, 83-103.
- Enlow, D., Kuroda, T., and Lewis, A. 1971. The morphological and morphogenic basis for craniofacial form and pattern, *Angle Orthod.* 41:161-188.
- Isaacson, John R. et al. 1971. Extreme variation in vertical facial growth and associated variation in skeletal dental relations, *Angle Orthod.* 41:219-229.
- Kuhn, Robert J. 1968. control of anterior vertical dimension and proper selection of extraoral anchorage, *Angle Orthod.* 38:340-349.
- McNamara, James A. Jr. 1981. Components of Class II malocclusion in children 8-10 years of age, *Angle Orthod.* 51:177-202.
- Pearson, Lloyd E. 1973. Vertical control through use of mandibular posterior intrusive forces, *Angle Orthod.* 43:194-200.
- Pearson, Lloyd E. 1978. Vertical control in treatment of patients backward rotational growth tendencies, *Angle Orthod.* 48:132-140.
- Popovich, F. and Thompson, G. 1977. Craniofacial templates for orthodontic case analysis, *Am. J. Orthod.* 71:406-420.
- Ricketts, R. M. 1960. The influence of orthodontic treatment on facial growth and development, *Angle Orthod.* 30:103-131.
- Schudy, F. F. 1963. Control of the occlusal plane and axial inclinations of the teeth, *Angle Orthod.* 33:69-82.
- Schudy, F. F. 1965. The rotation of the mandible resulting from growth, its implications in orthodontic treatment, *Angle Orthod.* 35:36-55.