

Letters

Hemifacial microsomia label questioned

We were very interested in Dr. Ross G. Kaplan's case report in the summer issue of the journal (*Angle Orthod.* 59:85-90, 1989). While the term "hemifacial microsomia"¹ covers a spectrum of conditions, we think the mandibular asymmetry in the 11 year 7 month boy could be due to other causes. The clinical description, the radiographic appearance of the affected side (Kaplan's Figure 11) and subsequent regeneration of the condyle suggest to us that this anomaly is more likely to be due to an undiagnosed condylar fracture than a case of hemifacial microsomia. There are several long-term studies of children with fractured mandibular condyles and the consensus is that the majority of fractured condyles regenerate spontaneously.^{2,3,4} It has also been claimed that these fractures are frequently undiagnosed.⁵

We are continuing to review a girl with an untreated condylar fracture. When first seen at age four, she had a marked mandibular asymmetry. The panoramic radiograph taken at that age shows that the upper left condyle had been fractured and was grossly displaced (Figures 1, 2). No orthodontic treatment was undertaken and when the patient was re-examined three years later the upper left condyle had regenerated (Figures 3, 4). The new condyle was noticeably thicker than the condyle on the unaffected right side. We would like to draw your attention to the similarity of our initial radiograph (Figure 1) to Figure 11 in Dr. Kaplan's report.

Finally, without any form of controls, we con-

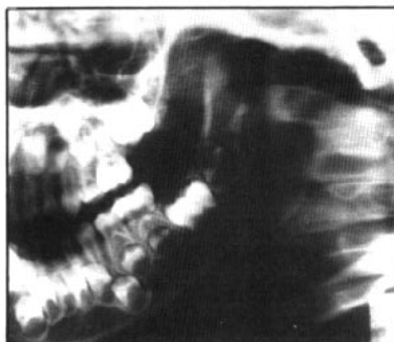

Figure 1

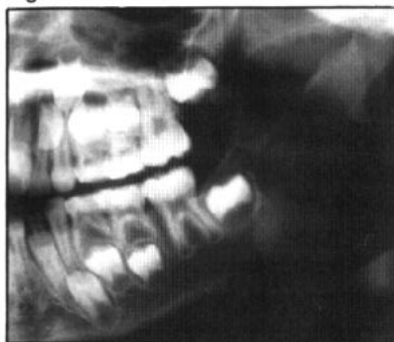

Figure 3

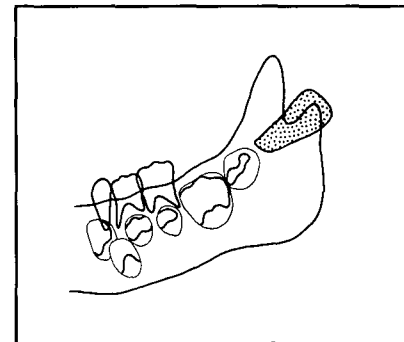


Figure 2

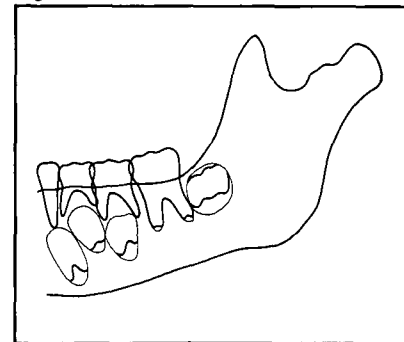


Figure 4

sider Dr. Kaplan's claim that orthodontic treatment "induced" condylar growth in some way cannot be supported.

—E.M. Harkness, BDS, MSc, PhD,
DOrth RCS(Eng), FRACDS
Department of Orthodontics
University of Otago
Dunedin, New Zealand

—D.N. Thorburn, BDS, FDSRCS(Edin)
Harley Chambers
137 Cambridge Terrace
Christchurch, New Zealand

Figure 1
Panoramic view of left side taken at age 4 years 2 months.

Figure 2
Tracing of mandibular outline at age 4 years 2 months. The condylar fragment is outlined and shaded.

Figure 3
Panoramic view of left side taken at age 7 years 1 month.

Figure 4
Tracing of mandibular outline at age 7 years 1 month.

References

1. Gorlin, R.J., Pindborg, J.J. and Cohen, M.M.: Syndromes of the head and neck. 2nd edition, 546-52, McGraw-Hill, 1976.
2. MacGregor, A.B. and Fordyce, G.L.: The treatment of fracture of the neck of the mandibular condyle. *B. Dent. J.*, 102:351-57, 1957.
3. Leake, D., Doykos, J., Habal, M.B. and Murray, J.E.: Long-term follow-up of fractures of the mandibular condyle in children. *Plast. Reconstr. Surg.*, 47:127-31, 1971.
4. Lund, K.: Mandibular growth and remodelling processes after condylar fracture. *Acta Odont. Scand.*, 32, Suppl. 64, 1974.
5. Proffit, W.R., Vig, K.W.L. and Turvey, T.A.: Early fracture of the mandibular condyles: frequently an unsuspected cause of growth disturbances. *Am. J. Orthod.*, 78:1-24, 1980.