

Letters

Orthopedic headgear forces

The Summer 1993 issue of *The Angle Orthodontist* contained a study entitled "Stress distributions in the maxillary complex from orthopedic headgear forces (Tanne K, Matsubara S, Sakuda. *Angle Orthod* 1993;63:111-118) which examined biomechanical responses of the human maxillary complex from headgear forces using three-dimensional finite element analysis.

The authors observed very prominent stress reactions in the human sphenomaxillary suture from headgear forces. It should be noted however that the existence of a sphenomaxillary suture could not be demonstrated in several studies investigating maxillary sutures in man.^{1,3}

Dr. Hendrik-Jan Rimmelink
Almelo, The Netherlands

References

1. Le Diascorn H. Anatomie et physiologie des sutures de la face. Thesis. Julien Prélat, Paris, France, 1972.
2. Rimmelink H-J. The postnatal development of the human maxillary sutural surfaces. Thesis. University of Groningen, The Netherlands, 1985.
3. Rimmelink H-J. Orientation of maxillary sutural surfaces. *Eur J Orthod* 1988;10:223-226.

Author's reply

We consulted *Acta Anatomica* before initiating this study and found the name 'sphenomaxillary suture'. We also examined the suture in the Japanese textbook of anatomy¹ and found it listed there. The suture is similar in structure to other facial sutures, i.e. the interface between the two adjoining bones is smooth, not saw-like; however, the anatomic area between the maxillary tuber and pterygoid process of the sphenoid bone may be defined as a suture. Thus the stresses in the area are evaluated as those induced by headgear forces between the maxillary and sphenoid bone. The stresses in this anatomic area are of great importance for investigating the effects of headgear forces on biomechanical change in the nasomaxillary complex because the maxillary bone exhibits primary displacement by headgear forces. In fact, the stress in this area was confirmed to be an important determinant for mechanical behavior of the entire complex.

Kazuo Tanne
Hiroshima, Japan

References

1. Kamizyo Y. *Oral Anatomy 1. Osteology*, Tokyo. *Anatome*. 1965;139-140.

Limitations of treatment

I certainly agree with Thomas P. Sperry's general approach in "The limitations of orthodontic treatment"¹ that a cautious attitude and ample explanation are needed in evaluating possible treatment for a mixed dentition child who has an obvious skeletal problem. I disagree with him, however, in his discussion of cephalometrics, the question of mandibular retrognathism, and the use of cervical headgear.

Dr. Sperry said, "But to what end? The vast majority of skeletal Class II patients have mandibular problems." What is the basis for this statement? He gives no documentation. I have heard this statement made a number of times over the past few years and almost always without documentation. The only recent study I know of which documents this is McNamara's.² He stated "All four measurements used in the analysis of mandibular position relative to upper face structures indicated frequent mandibular retrusion. For example, the mean facial angle was 84.4°, which is less than the ideal 86° in the balanced face of the 9-year-old child."

The pooled male and female mean value for the facial angle of 9-year-olds in the Bolton Standards of Dentofacial Developmental Growth³ is 85.6° with a standard deviation of 2.28°. The retrusive limit at one standard deviation is thus 83.32°, placing McNamara's mean of 84.4° well within the normal range for that age.

McNamara studied Class II patients, but did not explain the skeletal criteria he used in the selection of subjects. In regard to the vertical component, he noted, "The average value for lower face height indicated excessive vertical development in this sample." McNamara has shown that a more vertical position of the mandible results in more retrognathism.

On the other hand, Amoric,⁴ in a French study of 100 people, was unable to support McNamara's results. He found more maxillary protrusion and less mandibular retrognathism in his subjects. Again, no skeletal criteria were used in selecting

Pretreatment sagittal indicators				
Maxilla	NA-FH	Ba-A%	SNA	A-N perp
	<u>93.3+</u>	<u>103.3</u>	82.6	<u>2.5+</u>
Mandible	NPg-FH	Ba-Pg%	SNB	Pg-N perp
	85.0	90.5	<u>73.7-</u>	<u>-10.0-</u>
+ indication of maxillary protrusion				
- indication of mandibular retrusion				

the subjects.

Since Amoric's subjects had less vertical dysplasia than did McNamara's, the question arises: was the greater degree of vertical dysplasia in McNamara's subjects truly representative of a skeletal Class II sample?

In a study I am presently preparing for publication, I found large differences in the categorization of subjects depending on the skeletal indicators used for the maxilla and mandible. I found Reidel's SNB⁵ and McNamara's linear mandibular indicator (Pogonion to Nasion perpendicular) tend to be much more biased toward mandibular retrognathism than Downs' facial angle⁶ or the Coben proportional mandibular indicator (Ba-N:Ba-Pg).⁷

Figure 1 shows the pretreatment photographs of a mixed dentition skeletal Class II patient. There is an apparent mandibular retrognathism and possible maxillary protrusion. The Down's facial angle shows that the mandible is within one standard deviation of the reference mean for the patient's age using the Bolton standards, but the McNamara indicator and SNB indicate the patient has a retrognathic mandible.

Use of the angle NA-FH (Lande)⁸ shows that the maxilla is protrusive. The Coben and McNamara measurements agree with this assessment, but SNA does not.

The patient was treated with cervical headgear, a bite-plate, conventional edgewise mechanics in the upper arch only, and no permanent teeth were extracted. Headgear compliance was excellent as the patient was the third daughter in the family to use headgear and her older sisters were diligent in assuring her cooperation. Also, cervical headgear treatment was started at the peak of the pubertal growth spurt.

The posttreatment result is shown in Figure 2. Note the greatly improved profile with vastly improved contour of both the upper and lower lips and the chin. The angle of convexity was reduced from 19° to 10° and the ANB angle for 9.1° to 4.7°.

If as Dr. Sperry states, "The use of traditional

Write the Editor

The "letters" page is your opportunity to express your opinion on what you read in this magazine. Send your letter via mail:

Dr. David L. Turpin, Editor
1268 East Main Street
Auburn, WA 98002

or Fax:
206/939-5898

cephalometric analysis is more appropriate for inter- and intraprofessional communication and retrospective analysis and research than it is for prospective analysis and treatment planning", then I ask: other than evaluating treatment changes, what worthwhile information are we communicating if our indicators are not valid for treatment analysis and planning?

The clinical impression and the posture and degree of function of the soft-tissues are important factors in developing the treatment plan, but it is skeletal relationships which the orthodontist can affect. The point of cephalometric radiography is to scrutinize inner relationships making reference to appropriate age standards and the normal variation about the reference mean. We are trying to use our knowledge of the potential growth of the patient to benefit the skeletal pattern directly and the soft-tissue pattern indirectly. To do less is an injustice to the patient and to the potential of dentofacial orthopedics.

Perhaps it is time to re-evaluate our indicators, determine their reliability, discard those which are not valid and devise new ones if indicated, possibly making use of a centroid based analysis.

An academician recently pointed out that proper use of mixed dentition facial orthopedics at an early age, rather than orthognathic surgery later, would reduce our nation's health bill by quite a few million dollars each year.

Robert E. Rosenblum
Canadaiqua, NY

References

1. Sperry TP. The limitation of orthodontic treatment. *Angle Orthod* 1993;63:155-158.
2. McNamara JA Jr. Components of Class II malocclusion in children 8-10 years of age. *Angle Orthod* 1981;51:177-202.
3. Broadbent BH Sr., Broadbent BH Jr, Golden W. Bolton standards of dentofacial developmental growth. St. Louis: CV Mosby, 1975.
4. Amoric M. Etude critique des evaluations cephalometriques composant les classes II d'Angle selon McNamara. *Rev Orthod Dento Fac* 1985;19:563-568.
5. Riedel RA. The relation of maxillary structures to cranium in malocclusion and in normal occlusion. *Angle Orthod* 1952;22:142-145.
6. Downs WB. Variation in facial relationships: their significance in treatment and prognosis. *Am J Orthod* 1948;34:812-840.
7. Coben SE. The integration of facial skeletal variants. *Am J Orthod* 1955;41:407-434.
8. Lande MJ. Growth behavior of the human bony facial profile as revealed by serial cephalometric roentgenology. *Angle Orthod* 1952;22:78-90.

See author's response on following page

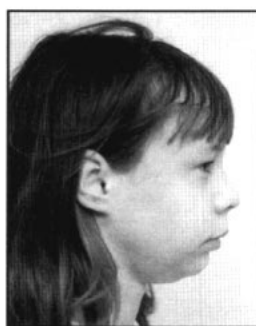

Figure 1A

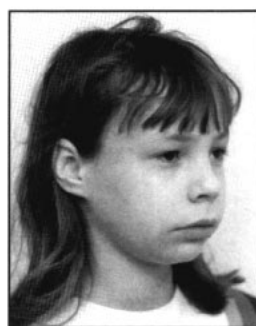

Figure 1B

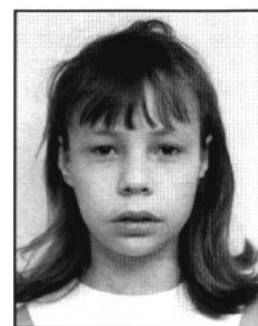

Figure 1C

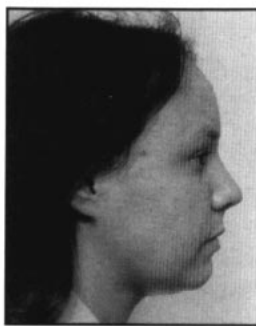

Figure 2A



Figure 2B

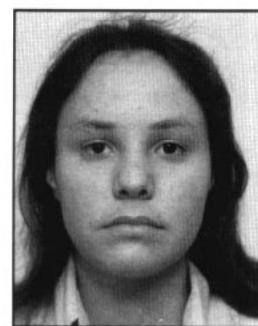

Figure 2C

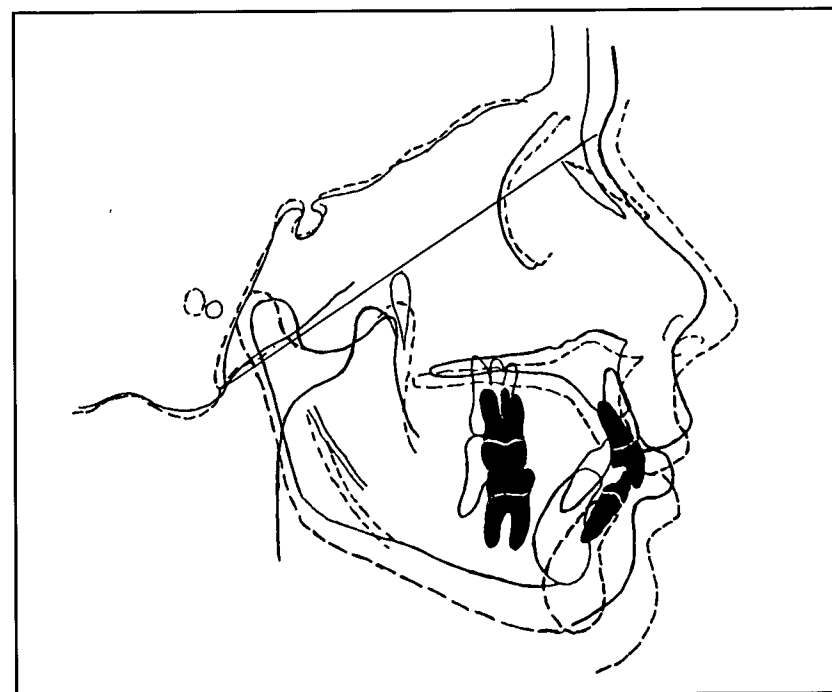


Figure 3

Figure 1-C
Pretreatment photographs of a mixed dentition skeletal Class II patient.

Figure 2-C
Posttreatment result.

Figure 3
Superimposed pretreatment and posttreatment tracings.

Author's reply

Dr. Rosenblum's criticism is based on cephalometric issues, the question of mandibular retrusion, and the application of cervical headgear to Class II malocclusion. Indeed, my statement concerning the preponderance of mandibular retrusion in Class II malocclusion was based on the McNamara study cited by Dr. Rosenblum. McNamara's extensive literature review supported his finding that mandibular skeletal retrusion was the most common single characteristic in the sample. Dr. Rosenblum's discussion of cephalometric "gotcha" illustrates the inherent problems of angular- and linear-driven analyses.¹

I have always favored soft tissue analytical methods when studying skeletal discrepancies. Conventional cephalometrics is an important adjunct, especially in determining the impact of dental compensation; but the role of the soft tissue as the "ultimate compensator" will always be the primary consideration.² Note the successful Class II treatment in the case presented by Dr. Rosenblum. In the absence of serial tracings or tables with cephalometric posttreatment data, allow me to suggest that most orthodontists will recognize the outstanding result to be a consequence of excellent mandibular growth combined with inhibition of maxillary growth secondary to cervical traction. How can that be determined? The nasolabial angle is only slightly increased, and the facial contour angle (representing both lower lip and chin) is greatly improved. The application of Class II mechanics and dentoalveolar orthopedics in this case is a textbook example of clinical success. Cervical traction works... but not all the time

(micrognathia, closing and opening rotational growth patterns, lack of quality or quantity of growth, etc.)

One may ponder, however, how a conventional cephalometric analysis would change the treatment plan proposed and executed for this patient by Dr. Rosenblum.

Clearly, Dr. Rosenblum and I share common ground in establishing treatment goals and stressing informed consent. My theme was based on recognizing limitations of both conventional treatment and dentofacial orthopedics in treating skeletal discrepancies in all dimensions, and, when necessary, redirecting efforts to achieve the original treatment goals and, as a corollary, avoiding unproductive and expensive interim treatment.

Dr. Rosenblum closes with a statement attributed to "an academician" that facial orthopedics can reduce healthcare costs by avoiding surgery. While acknowledging exceptional circumstances, I suggest that the injudicious use of mixed dentition facial orthopedics, rather than inevitable orthognathic surgery at a later age, will increase our nation's health bill by quite a few million dollars. It is important for all clinicians to plan treatment considering favorable cost/benefit ratios, as well as achieving established treatment goals.

Thomas P. Sperry, DDS, MS, MSD
Aurora, Illinois

References

1. Moyers R, Bookstein F. Inappropriateness of conventional cephalometrics. *Am J Orthod* 75:599-617.
2. Worms F, Isaacson R, Speidel M. Surgical orthodontic treatment planning, profile analysis and mandibular surgery. *Angle Orthod* 1966;16:1-25.