

Letters

Extraction decisions

I am writing in reference to Dr. Gary Wolf's article "Case Report BC: Extraction decisions based on treatment responses" (1993;63(4):251).

I would like to commend Dr. Wolf on an excellently treated case from a dental perspective. However, I would like to discuss this article from the facial profile point of view. As Dr. Wolf points out, "the maxillary and mandibular incisors were retracted and thus reduced lip support by approximately 2 mm." The end result was a concave facial profile. The before profile was clearly superior to the 'dished-in' final result. The question arises: Could this have been avoided and could, perhaps, an improved facial profile be achieved if the case had been treated nonextraction? This question should have been discussed in the article.

When one reads the work of Cetlin and Jones

with respect to nonextraction treatment, this concept becomes a viable alternative, if part of the treatment objective is to maintain or improve the facial profile, not to worsen it or prematurely "age the face". Achieving the best balance of optimal facial esthetics was not a part of Dr. Wolf's treatment plan. If it had been, then the matter of deciding whether or not to extract would be a major consideration.

I would like to hear some discussion and opinion on the possible outcome of the case if only the involved lateral were extracted and the rest of the case treated nonextraction. One can conjecture about a different facial profile if this case had been treated with the extraction only of the involved lateral or possibly the third molars.

Marvin Rosenthal, DDS
Fishkill, N.Y.

Author's Response

I wholeheartedly agree that a treatment plan should be selected that satisfies the goals and objectives of both our patients and ourselves, particularly on what would improve the facial profile. In the 10 years since case BC was treated, tools of growth modification and orthognathic surgery have made extractions for anteroposterior correction less common while making facial profile improvements more attainable. Extraction therapies have declined from approximately 60% in 1965 to less than 30% today. Unfortunately, not all patients are referred early enough or are candidates for growth modification and not all nongrowing patients with skeletal disharmonies require or will accept surgery. The range of complexity of malocclusions necessitates that we consider extraction of teeth for reasons other than just arch length deficiency. Consequently, "extraction" or "nonextraction" is not an adequate treatment plan for a complex problem.

Case Report BC is not an argument for or against extraction therapy. The purpose of writing the report was to illustrate a solution to a complex orthodontic problem that most orthodontists face daily. In Case Report BC, I tried to illustrate the importance of having a plan of treatment that anticipates a variety of potential treatment responses and of executing the plan in a timely manner, depending upon the treatment responses. If your treatment plan for Case BC were to extract the supernumerary tooth and the retained deciduous teeth, to correct the excessive arch length deficiencies, and to remove the maxillary left lateral incisor and prosthetically replace it, I agree that would have been a viable alternative. My concern with Case BC, as outlined in the report, was not knowing the prognosis for the central and lateral incisors until they could be evaluated radiographically.

There were two omissions in the publication of

this report. First, the parents and patient were opposed to fixed bridgework. When the patient started treatment in 1985, implants were not as proven as they are today and resin bonded bridges were (and still are) variably successful. Although you didn't comment on how you would have prosthetically restored the patient, the severe dilaceration of the maxillary left central incisor could have made placement of an implant precarious. Second, due to an error when preparing the paper for publication, the photograph of the pretreatment mandibular model (Figure 2E) was not Case BC. The correct model, shown here, had a more severe arch length deficiency than the model published.

Consequently, based on the patient's goals and objectives, the excessive arch length deficiencies and multiple unknowns, I felt extraction of premolars could be justified. But rather than start with the removal of four premolars, extractions were done in a sequential manner so that prosthetic replacement was avoided. It was the external resorption and poor prognosis for the lateral incisor that determined the direction of this treatment plan. Once the decision to extract the lateral incisor was made, great care was taken to position the substituted canine and first premolar to achieve an acceptable esthetic and functional result.

When acceptable treatment options exist, is it always our role to dictate our patient's treatment? Nordquist and McNeill showed that patients with canines substituted for congenitally missing lateral incisors were significantly healthier periodontally than patients whose missing lateral incisors were replaced with fixed bridgework. (Fixed bridgework would probably have been the restorative treatment of choice for Case BC.)

Is profile a more important objective for this patient than avoiding the need for bridgework? You state "when one compares the before and after facial profiles, it is obvious that the before profile is superior to the 'dished in' after profile." It may be debated as to what defines "obvious". Paquette et al. recently published results of pa-

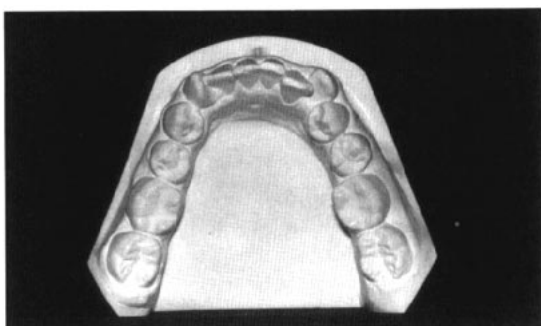


Figure 2E, Corrected

tients' perceptions of their profile 15 years after treatment. They compared patients treated with four premolar extractions to those treated nonextraction. The samples were matched statistically and were nearly identical pretreatment. Although approximately 2 mm of incisor and lip retraction occurred in the extraction cases (the same as in Case BC) both groups responded about the same to their profiles 15 years posttreatment using VAS (visual analog scale) scores. In Case BC, chin and nasal growth contributed to the posttreatment facial profile (see superimposition, Figure 10). This same growth, however, would have occurred with any plan and, therefore, the extraction decision probably did not significantly influence the facial esthetic result, as shown by Paquette et al.

I am not familiar with the literature concerning the esthetics and clinical stability of the techniques of Cetlin and Jones and what results could have been achieved with removal of third molars. Therefore, I cannot comment on this suggestion. Without extractions to gain additional maxillary arch length, I do not believe that I could have detected the resorption radiographically. Given the many treatment alternatives considered in the case, including yours, and evaluating the advantages and disadvantages of each, I feel not only an acceptable dental (and periodontal) result was achieved but that a pleasing smile and a satisfied patient were also attained.

Gary R. Wolf, DDS, MSD
Norwalk, Ohio

References

1. Peck S, Peck H. Frequency of tooth extraction in orthodontic treatment. *Am J Orthod* 1979; 76: 491-496.
2. Weintraub J, Vig PS, Brown C, Kowalski CJ. The prevalence of orthodontic extractions. *Am J Orthod Dentofac Orthop* 1989; 96:462-466.
3. O'Connor BMP. Contemporary trends in orthodontic practice: A national survey. *Am J Orthod Dentofac Orthop* 1993; 103:163-170.
4. Nordquist GG, McNeill RW. Orthodontic vs. restorative treatment of the congenitally absent lateral incisor - Long term periodontal and occlusal evaluation. *J Periodont* 1975; 46:139-143.
5. Paquette DE, Beattie JR, Johnston LE. A long-term comparison of nonextraction and premolar extraction edgewise therapy in "borderline" Class II patients. *Am J Orthod Dentofac Orthop* 1992; 102: 1-14.

Figure 2E, corrected
This model replaces the figure marked 2E on page 252 of Case Report BC in the Winter 1993 edition of *The Angle Orthodontist*. (1994;63:251-256.)

Fluoride applications to control decalcification

The important study by Robert Boyd reported in your Spring issue of 1993 (Comparison of three self-applied topical fluoride preparations for control of decalcification. *Angle Orthod* 1993; 63:25-30) reported the positive effect of fluoride applications in the control of decalcification during orthodontic treatment.

His findings confirm earlier reports by our group.^{1,2,3} However, in the discussion, page 28, Dr. Boyd refers to our earlier studies in support of his conclusion that the greatest amount of decalcification was found most frequently in molar teeth. There appears to be a major difference since we reported on only bonded posterior teeth and in Dr. Boyd's study, "first and second molars were generally banded".

Decalcification from cement breakdown and washout on banded teeth is generally different from the white spots on bonded teeth. The latter may indeed be protected by fluoride and hygiene programs while the decalcification of banded molars can only be limited by rigid inspection and the avoidance of occlusal trauma. Therefore, we feel the study under discussion could have benefited by excluding the banded molars.

Arnold M. Geiger, DDS
Clinical Professor
Division of Periodontics and
Orthodontics
Columbia University School of
Dental and Oral Surgery
New York, New York

References

1. Gorelick L, Geiger AM, Gwinnett AJ. Incidence of white spot formation after bonding and banding. *Am J Orthod* 1982; 81:93-98.
2. Geiger AM, Gorelick L, Gwinnett AJ, Griswald PG. The effect of a fluoride program on white spot formation during orthodontic treatment. *Am J Orthod Dentofac Orthop* 1988; 93:29-37.
3. Geiger AM, Gorelick L, Gwinnett AJ, Benson BJ. Reducing white spot lesions in orthodontic populations with fluoride rinsing. *Am J Orthod Dentofac Orthop* 1992; 101:403-407.

Author's Response

I wish to thank Dr. Geiger for his favorable comments on the importance of this study. I am grateful that Dr. Geiger pointed out that his studies with Drs. Gwinnett and Gorelick generally corroborate the findings of my study, as their work on decalcification has been the benchmark for decalcification studies during the last decade. I would also like to acknowledge Dr. Geiger's

comments on molar teeth in the discussion section of my paper. I appreciate the clarification of his work for the readers of *The Angle Orthodontist*.

Robert L. Boyd, DDS, MED
Professor and Chair
Division of Orthodontics
University of California
San Francisco

Editorial

Continued from page 83

complex are the diagnostic and treatment planning procedures required in the more severe forms of asymmetry. In a review of dental and facial asymmetries in this issue, Dr. Samir Bishara summarizes the findings of many investigators regarding the etiology of these conditions. He goes into great detail in describing the need to examine and identify the specific areas of asymmetry, which is obviously critical to the successful treatment of

these individuals. The case report by Dr. Dan Yaillen that follows this article illustrates the complications created by a developing mandibular asymmetry. In this situation a surgical approach was required to achieve the desired outcome.

I could continue to ask clinically related questions about every other article in this issue...but I'll leave that to you as you conduct your own search for the truth.