

# Case Report MH

*This case report was presented at a regular meeting of the Southern California Component of the Edward H. Angle Society in 1994. It demonstrates the value of two-phase treatment which resulted in effective vertical control.*

**Arthur L. Kobal, DDS**

**S**hyness and apprehension were readily apparent when this 9-year-old patient came in for her first orthodontic examination. A previous finger-sucking habit had given way to tongue-thrusting and lip-biting habits. Her parents recognized a problem and wondered if something should be done at an early age.

## Etiology

The patient's skeletal disharmony was primarily genetic in origin with a strong influence on the father's side toward a Class II relationship with a recessive mandible. The anterior openbite and excessive overjet could be attributed to the habits of finger sucking, tongue thrusting, and lip biting. The mesioincisal corners of the maxillary central incisors had been broken in a swimming pool mishap. Her medical history was noncontributory.

## Diagnosis

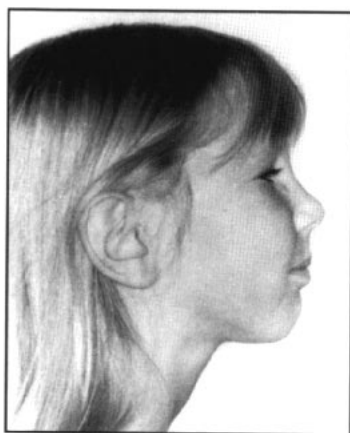
The patient presented in the mixed dentition with a Class II, Division 1 malocclusion with anterior openbite. The mandible was excessively retruded relative to the maxilla which was within normal

limits ( $SNA=80^\circ$ ,  $SNB=70.5^\circ$ ,  $ANB=9.5^\circ$ ). This was in part due to vertical maxillary excess and clockwise rotation of the mandible. The openbite was both skeletal and dental in nature. Habits contributed to the dental portion, whereas a high mandibular plane angle ( $GoGn-Sn=47^\circ$ ) gave evidence of the amount of skeletal divergence.

The patient's lips were normally apart at rest and lip competency was accomplished only with considerable strain. Other oral soft tissues appeared normal.

Calculations indicated insufficient arch length in both arches for eruption of the permanent canines and premolars. The maxillary arch form was tapered while the mandibular arch form was more rounded. Posterior arch

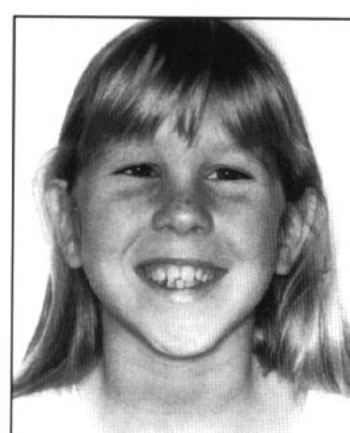**Figure 1A-C**  
Pretreatment facial photos at 9 years 2 months.



**Figure 1A**



**Figure 1B**



**Figure 1C**

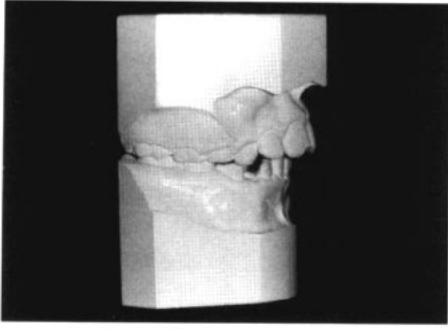


Figure 2A

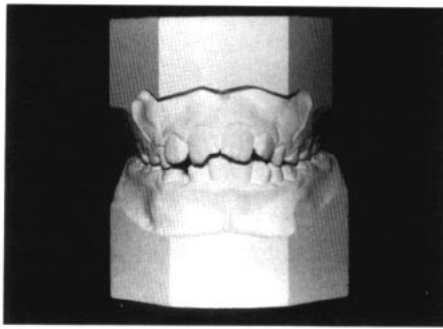


Figure 2B

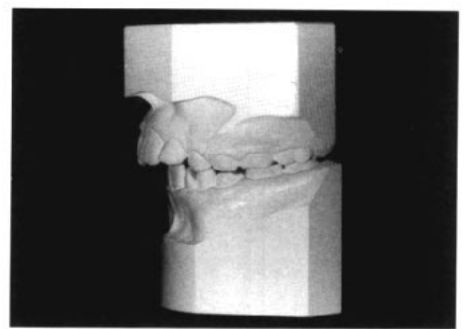


Figure 2C

**Figure 2A-E**  
Pretreatment study casts

**Figure 3**  
Pretreatment cephalometric tracing.  
Note mandibular retrognathia.

**Figure 4**  
Panoramic radiograph at 12 years 1  
month with maxillary crib, palatal arch  
and mandibular lingual arch in place.

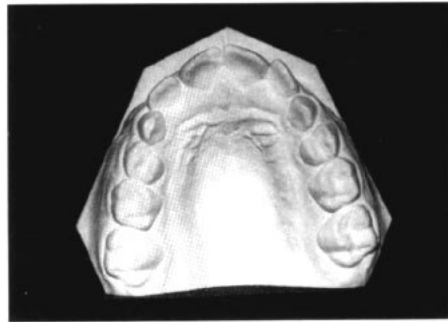


Figure 2D

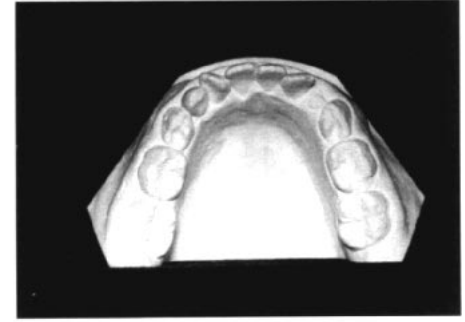


Figure 2E

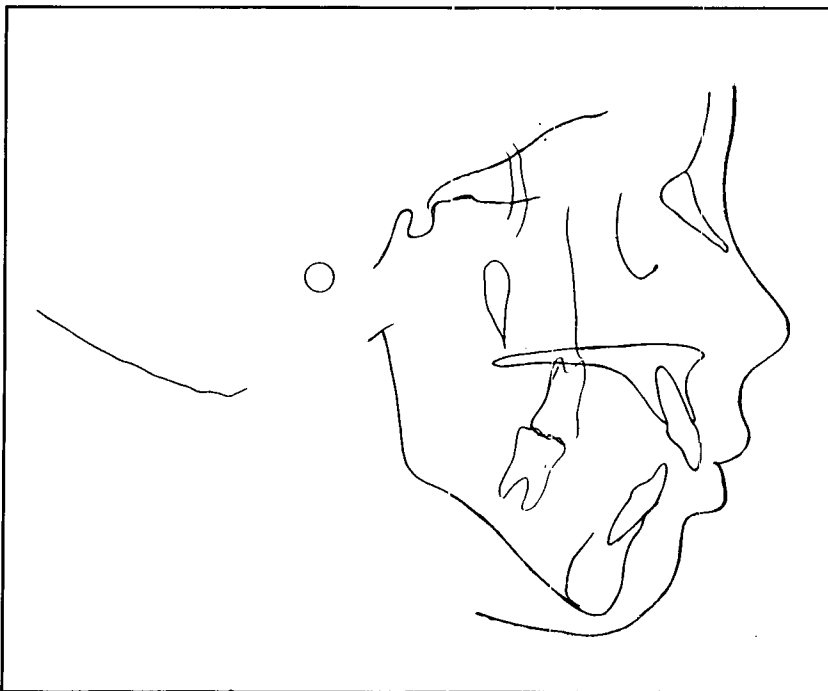

Figure 3

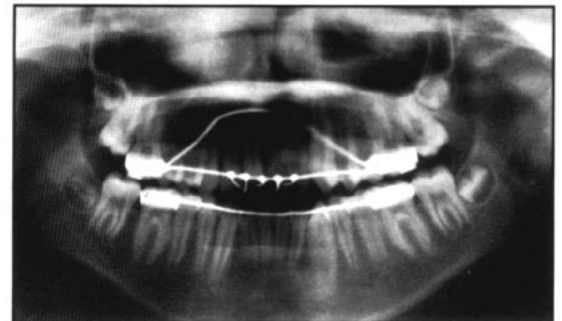


Figure 4

widths were normal and the mandibular midline was off approximately 2 mm to the left.

Pretreatment radiographs revealed a mixed dentition that was developing normally. There was no evidence of third molars. Bone morphology appeared to be normal. The permanent teeth seemed to be developing normal roots, in good relation to root resorption of the deciduous teeth. There was no evidence of caries.

#### Treatment objectives

Treatment objectives for the first phase of treatment were: to inhibit the tongue's influence on the anterior teeth, to redirect maxillary growth, and to control the vertical dimension while awaiting the eruption of permanent teeth. When the mandibular second molars were about to erupt, the growth changes would be evaluated and phase 2 initiated. The second phase of treatment would include fully-

banded, edgewise orthodontic appliances. If the objectives of phase 1 were met, then treatment objectives for phase 2 would be: to alleviate arch length deficiencies, to achieve ideal overbite and overjet, to coordinate widths of maxillary and mandibular arches, and to attain a functional and stable Class I occlusion.

### Treatment plan

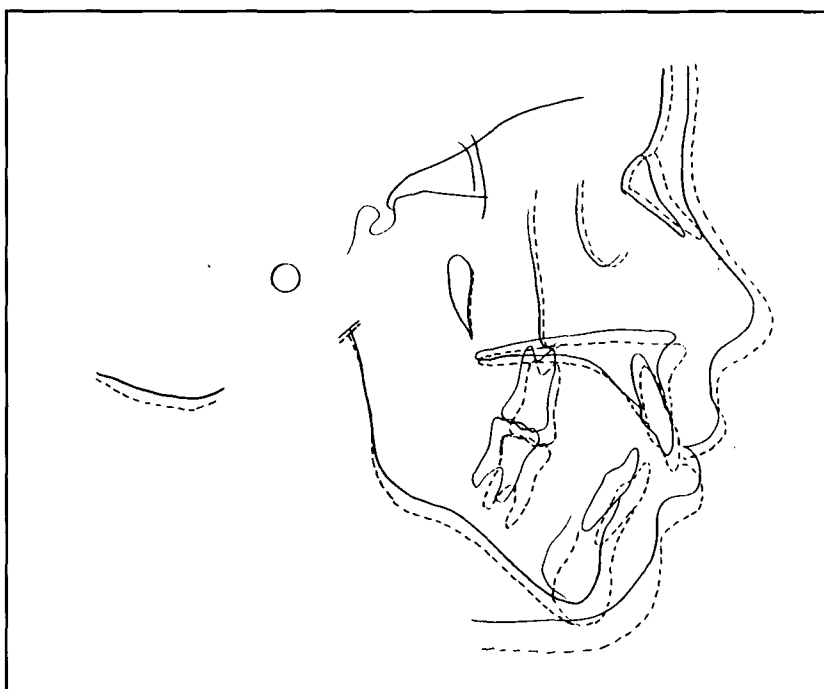
Phase 1 treatment was initiated with the banding of the maxillary and mandibular first molars and the placement of a palatal bar combined with tongue crib (spurs soldered on an upper lingual wire) and a lower lingual arch. A posterior high-pull headgear would inhibit vertical maxillary growth and maxillary molar eruption. The palatal bar would control buccal torque of the maxillary molars during high-pull headgear wear so that the openbite would not be made worse by premature contact of the lingual cusps. Rationale for the tongue crib was to inhibit anterior tongue-thrust and to allow for eruption of the maxillary incisors. The lower lingual arch was to maintain the position of the mandibular incisors and to inhibit eruption of the mandibular molars.

Control, inhibition, or redirection of vertical eruption and development was essential if the Class II skeletal and dental corrections were to be made by orthodontic methods alone. Further, anterior bite closure and profile improvement would be realized by counterclockwise rotation of the mandible. The possibility of surgical correction might need to be considered.

Success of the first phase of treatment would set the stage for phase 2, when the premolars would be extracted prior to placement of the fixed maxillary and mandibular appliances to correct the dental components of the malocclusion. The rationale for extracting the maxillary first and mandibular second premolars included excessive overjet and Class II molar relationship, excessive lip strain upon closure, remaining mandibular arch length discrepancy, and the family's preference for an orthodontic solution to the problem. Mandibular second premolar extraction was elected to allow for mesial shift of the mandibular molars, both to correct the Class II relationship and to allow for decreasing the mandibular plane angle.

### Progress of treatment

Maxillary and mandibular first molar bands were fitted and impressions were taken to



**Figure 5**

make working models for the fabrication of a palatal bar, tongue crib, and lingual arch. The spurs of the tongue crib extended inferiorly approximately 2 mm below the incisal edges of the mandibular incisors. The outer bows of the high-pull headgear were short so that the vector of force would pass through the molars and not cause tipping of the palatal plane. The elastic traction devices provided a force level of approximately 16 ounces per side. The patient wore the headgear 14 hours per day for 11 months and at night only for 6 additional months. The tongue spurs were removed after 6 months of treatment.

During phase 1, the patient was seen at 4-week intervals. Goals of phase 1 were realized in that vertical maxillary development was held to a minimum and the ANB was reduced slightly.

More time elapsed between phases of treatment than was desirable because of the parents' wish to delay the start of the second phase. Interim records were taken at age 12 years and an evaluation was made for the second phase of treatment. A slight openbite remained and the vertical dimension was still considered excessive. The parents did not want the patient to undergo surgical correction of the malocclusion. Therefore, extraction of maxillary first and mandibular second premolars was deemed necessary.

Extractions were performed and the patient

**Figure 5**  
Superimposed tracings at 9 years 2 months and 12 years 1 month.

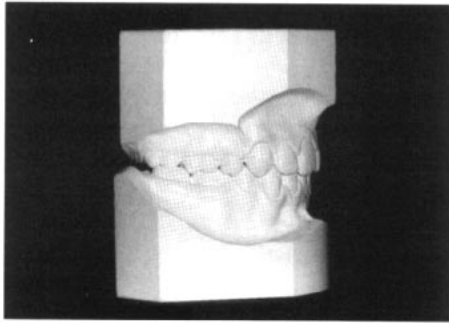


Figure 6A

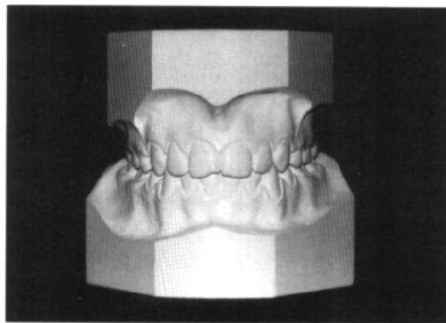


Figure 6B

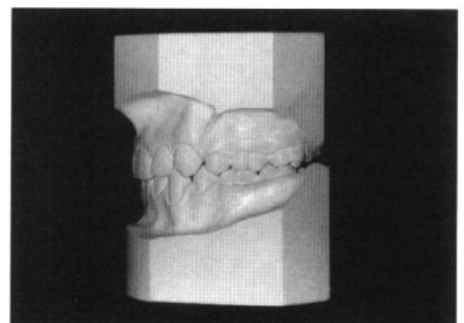


Figure 6C

**Figure 6A-E**  
Posttreatment study casts at 14 years 6 months.

**Figure 7**  
Superimposed tracings at 9 years 2 months and 14 years 6 months.

**Figure 8A-B**  
Posttreatment facial photos.

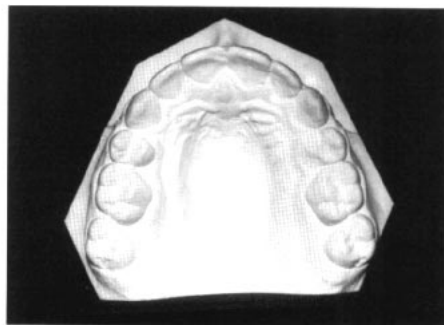


Figure 6D

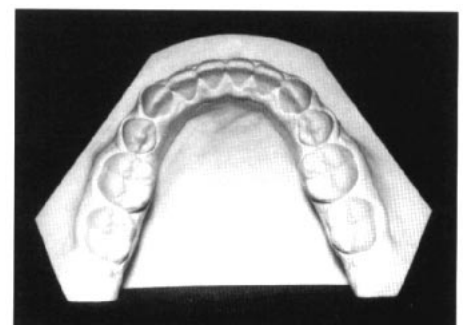


Figure 6E

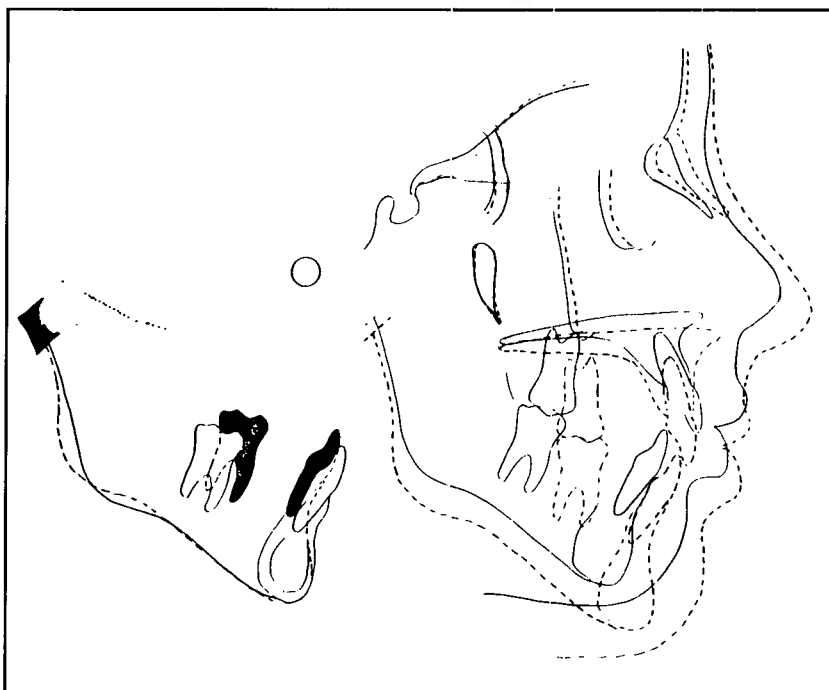


Figure 7

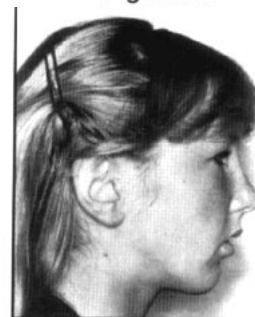

Figure 8A

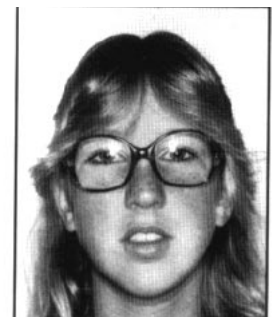


Figure 8B

was fully banded. Spaces were closed and maxillary anteriors were retracted with the assistance of Class II elastics worn daily. The mandibular molars were allowed to come forward to correct the Class II relationship and close the bite. The patient was cooperative and treatment progress was good. All bands were removed after 25 months of treatment.

### Results

The final analysis of the records shows a very acceptable result. An excellent Class I occlusion was achieved. The overbite and overjet were corrected, and good arch forms and dental alignment are seen. There was a reduction of ANB from 9.5° to 6°. The mandible is still relatively retruded, but the profile is less convex and the lips are less protrusive because of the retraction of the maxillary incisors. The effective length of the mandible has increased slightly and contour of the chin has improved

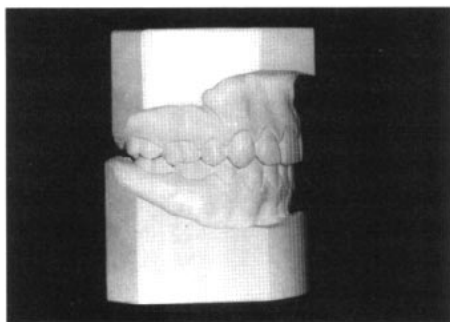


Figure 9A

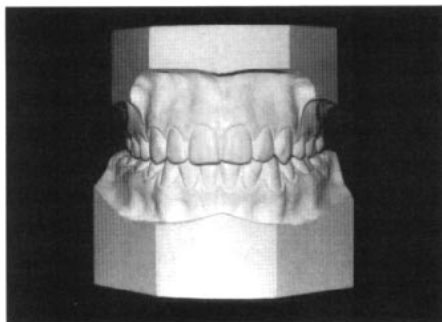


Figure 9B

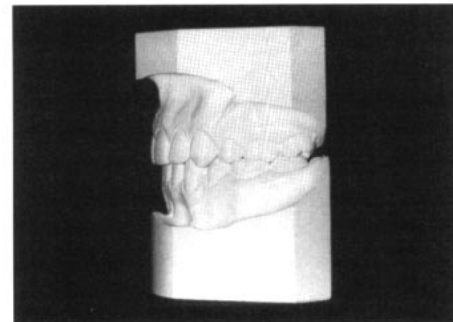


Figure 9C

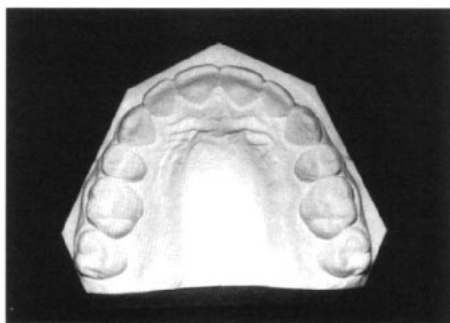


Figure 9D

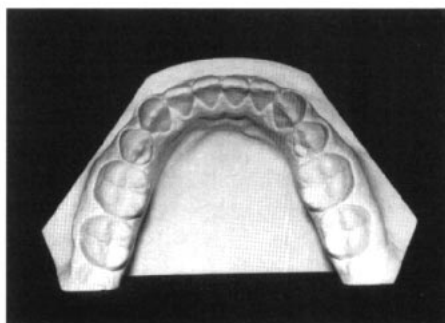


Figure 9E

**Figure 9A-E**  
Postretention study casts at 18 years 8 months

**Figure 10**  
Superimposed tracings at 14 years 6 months and 18 years 8 months, showing late mandibular growth following treatment.

to further enhance the facial profile. The upper lip remains short but the smile is pleasing and the facial proportions and symmetry are good.

Minor interdental spaces remain where bands were removed but these were subsequently closed with retainers.

#### Retention

Immediately after complete band removal, maxillary wraparound and mandibular Hawley retainers were placed. As the occlusion settled, retainers were adjusted and the incisal edge of the maxillary left central incisor was reshaped. The reshaping took place over several appointments due to the patient's apprehension. It was recommended that the patient ask her general dentist to restore the mesioincisal corner of the maxillary right central incisor. The patient and parents were also advised about the possible need for extracting the developing third molars. The patient was cooperative and retention was uneventful until, at 11 months, the upper retainer was chewed up by a dog and had to be replaced. The retention period lasted 38 months.

#### Final evaluation

The 4.5-year records demonstrate the effectiveness of this two-phase treatment. The occlusion remains in a Class I relationship with good overbite, overjet, and arch form. Although esthetics are excellent, there is minor

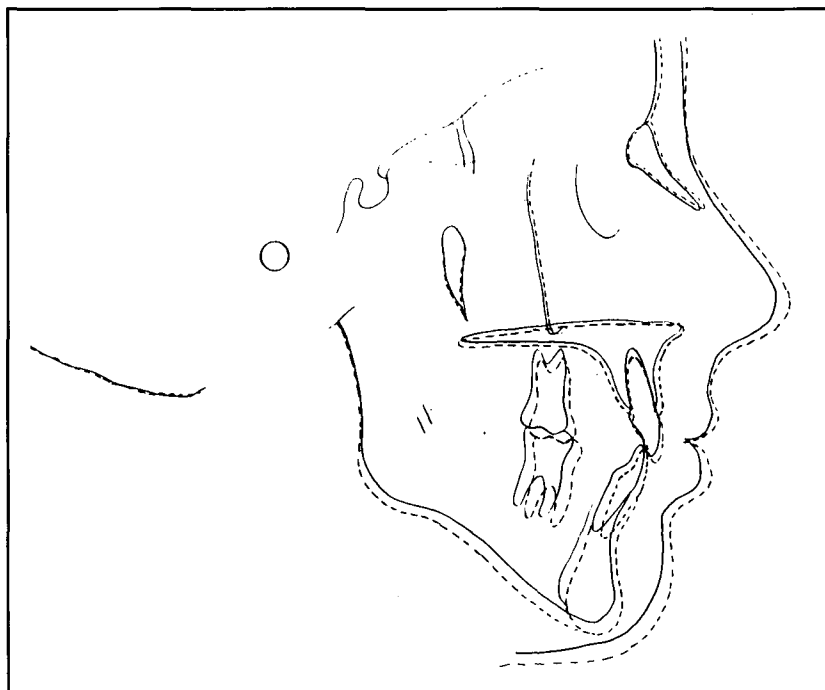


Figure 10

**Figure 11A-C**  
Facial photos at 18  
years 8 months. Note  
restoration of central  
incisor.

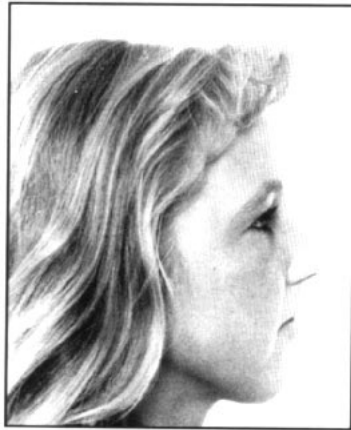

Figure 11A



Figure 11B



Figure 11C

relapse in the mandibular incisor area. The mandibular third molars are beginning to erupt and will continue to be monitored. The mandible has grown a bit more, which has contributed further to improvement of the facial profile and the reduction of ANB to 5°. There was an increase of SL from 32 mm to 33.5 mm. The mandibular plane angle remains stable and unchanged at 46.5°. All hard and soft tissues appear to be normal and healthy. Based

upon original treatment objectives, the treatment is considered a success.

**Author Address**

Arthur L. Kobal, DDS  
228 Lombard Street, Suite A  
Thousand Oaks, CA 91360-5837  
*A.L. Kobal is in private practice in Thousand Oaks, California.*