

# Communication in orthodontic treatment planning: bioethical and informed consent issues

James L. Ackerman, DDS; William R. Proffit, DDS, PhD

**T**reatment planning in orthodontics requires the integration of objective factors derived from the diagnosis (historical, morphological, and functional characteristics of the patient) and subjective factors (primarily esthetic and psychosocial). The orthodontist's view of the subjective issues involved may differ considerably from that of the patient or parents. The clinician's goal should be to bridge the gap between the professional's point of view and the patient's, thereby achieving a mutual understanding and consensus. This can be achieved only through an orthodontist-patient or -parent dialogue, the aim of which is to jointly construct treatment goals that satisfy both the doctor and the patient.

It has not always been this way; indeed, the concept presented above is surprisingly recent. With the introduction of radiographic cephalometrics into clinical orthodontic practice in the 1940s, orthodontists became more aware of the role of underlying jaw disproportion in the etiology of malocclusion, and dental and skeletal components of malocclusion became the universal language of orthodontists.<sup>1</sup> Nonetheless, for nearly 30 more years, these ideas were more effectively applied to diagnosis than they were to treatment planning. It was not until orthognathic surgery came of age in the 1970s, with the inclusion of maxillary as well as mandibular procedures,<sup>2</sup> that orthodontists began to more seriously consider a patient's underlying skeletal

## Abstract

Orthodontic treatment planning is an interactive process in which the patient or parent and the orthodontist serve as co-decision makers. As in most partnerships, there is a natural tension between the orthodontist and the patient because of differences in their frames of reference. The orthodontist generally is influenced more by the objective findings (the problem list), whereas patients are guided more by subjective issues related to their perceived needs, desires, and values. The art of careful probing and listening to the patient as part of the treatment planning process is an essential skill. One of the most difficult situations in contemporary orthodontics is presented by the patient with a jaw discrepancy for which the alternative treatments are orthodontic camouflage through dental compensation or surgical-orthodontic correction. Computer imaging to simulate the probable treatment outcomes can facilitate communication about these alternatives by eliminating misconceptions. Full disclosure and the consideration of all viable treatment alternatives have great benefits from a risk management standpoint, in addition to their bioethical merits.

## Key Words:

Bioethical issues • Informed consent • Computer imaging

**Submitted:** October 1994

**Revised and Accepted:** March 1995

Angle Orthod 1995;65(4):253-262.

## Case 1

### Figure 1

Pretreatment profile with superimposed cephalometric tracing, 13-year-old girl with moderate Class II Division 1 malocclusion (photographed from computer screen).

pattern in orthodontic treatment planning.

Until recently, dental compensation for an underlying skeletal disproportion, "orthodontic camouflage," was a routine and acceptable treatment method. With an improved understanding of the changes that occur in the soft tissue contours of the face, orthodontists have become more aware of the esthetic risks of camouflage treatment. Good communication between the orthodontist and the patient is the key to effective treatment planning, and the patient or parent's input can markedly affect the plan of treatment.

### Autonomy vs. paternalism in orthodontic treatment planning

As orthodontists became more focused on the relationship between the soft tissues of the face and the underlying hard tissue morphology, a change of another kind was taking place. Previously, the doctor was the sole decisionmaker in the treatment planning process. Now, a shift was occurring toward the patient as a co-decisionmaker. Bioethicists across the country and the jurisprudence system in many states have concluded that the doctor as sole decisionmaker is paternalistic and an abuse of professional authority.<sup>3</sup> Thus, it is now the doctor's legal as well as moral responsibility to advise a patient of the risk/benefit considerations of a contemplated treatment and to discuss alternative treatment possibilities. Possible compromise treatment should be included in the list of treatment alternatives, and the doctor is also obliged to explain the risk associated with no treatment at all. This obligation to properly inform patients and gain their consent is known as the doctrine of informed consent.<sup>4</sup>

In discussing treatment alternatives with parents and patients, the orthodontist must deal with three competing values: (1) the wish to be clear, concise and direct; (2) the desire to be kind and to not overly alarm the parents or patient; and (3) the hope that they will accept treatment. The patient and parents are also conflicted, wanting to hear the truth on the one hand, but wanting also to minimize their losses and achieve an acceptable outcome with minimum treatment. The dilemma for the orthodontist is often this: If he or she recommends what is theoretically the best plan, the patient or parent may reject any treatment at all. The problem is magnified if orthognathic surgery is the best plan and the patient is not prepared to accept it.

The orthodontist can use several approaches to make it easier for the patient or parent to accept

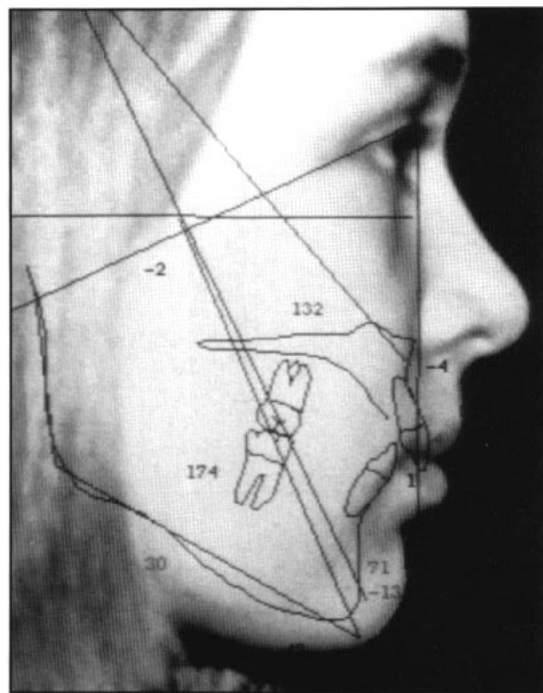


Figure 1

difficult news. The most obvious is to soften the blow by using euphemisms such as dentofacial imbalance (rather than deformity) or a somewhat deficient chin (rather than a weak chin). Not only is this a kinder way of referring to the same issue, it also paves the way for acceptance rather than recoil.

The orthodontist can and should preserve the patient's dignity and the parents' natural admiration for their child through a process of negotiation concerning the diagnosis and treatment needs. In this process of jointly constructing treatment goals, the objective is to bridge the distance between the professional's point of view and that of the patient or parent, thereby achieving a mutual understanding and consensus before a final plan of treatment is established.<sup>5</sup>

Much has been learned in recent years from social science research investigating the doctor/patient discourse.<sup>6</sup> How meaning is constructed between the orthodontist and patient involves not only words and what they stand for, but also how they are interpreted by the two parties involved in the dialogue. Thus, the orthodontist who says that "there will be an improvement in the protrusion of the upper front teeth" may have one picture in mind and the patient quite another. Since the esthetic benefits of orthodontic and orthognathic surgical treatment are largely subjective and difficult to describe to a patient or parent, the degree to which an orthodontist can comply with the concept of full disclosure is influenced by his or her

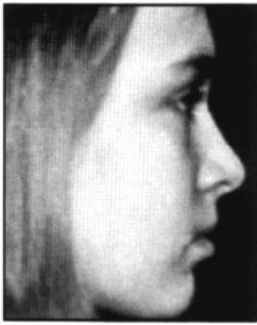

Figure 2A

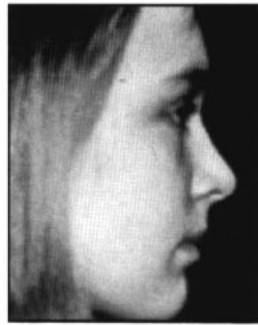

Figure 2C

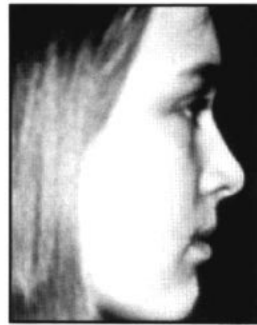

Figure 2E

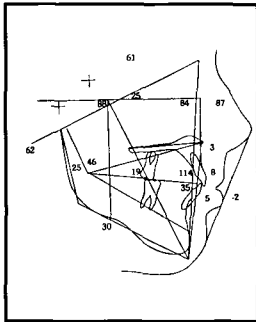


Figure 2B

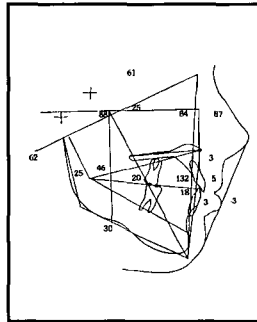


Figure 2D

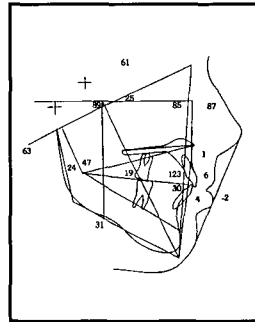


Figure 2F




Figure 3

communication skills.

With the advent of computerized video imaging to predict the outcome of treatment, the orthodontist now has a powerful and reasonably accurate communication tool to compare and contrast for the patient the potential outcomes of various treatment alternatives.<sup>7,8</sup> By substituting actual pictures for words, the orthodontist can eliminate some of the misconceptions related to the construction of mental pictures. Some legal advisors have suggested that care should be taken in offering renderings or representations of facial appearance outcomes.<sup>9</sup> Recent studies, however, suggest that while patients who have been shown video predictions have higher esthetic expectations than those who have not seen predictions,<sup>10</sup> they are equally or more satisfied with the outcome of treatment.<sup>11</sup>

Communication problems are often greatest with patients who have moderately severe rather than extremely severe problems. When a patient has a severe dentofacial deformity, it is generally easier for the parents to accept a treatment plan in which extractions and/or surgical correction play a role. Borderline cases in which a skeletal disproportion underlies a relatively mild to moderate dentofacial imbalance often lend themselves to either surgical or nonsurgical correction. It is not unusual in borderline cases to have the alternatives range from no treatment to surgical correction, with extractions for orthodontic camouflage as something of a middle ground. These cases require the greatest commu-

nication skills on the part of the orthodontist and also require the greatest amount of wisdom on the part of the parents or patient in selecting the alternative that best suits their needs.

#### Treatment dilemmas in borderline cases

Figure 1 shows a patient with reasonably good facial balance, albeit with slight mandibular retrognathism. She has a Class II, Division 1, subdivision malocclusion, with 3 or 4 mm overjet and a pleasing alignment of her teeth. To her and her family, facial esthetics were very important. They did not consider the malocclusion a major problem but were willing to consider treatment if it was really needed. Computer imaging (Figure 2) facilitated a comparison of the potential outcomes of nonextraction orthodontic treatment, extraction treatment, and surgical advancement of the mandible. In both the nonextraction and extraction outcomes, the after-treatment profile is less pleasing than the pre-treatment face. With surgical treatment, one could also make the case that the patient's facial balance is more pleasing before treatment. Dental function presumably would be better if the occlusion were ideal, but facial esthetics were more important than function to this girl and her parents.

In this patient's case, since her smile was already pleasing and there was no assurance that her facial balance could be improved through either orthodontic treatment or orthognathic surgery, her parents opted for no treatment at all.

#### Case 1

**Figure 2A-F**  
Video image predictions.  
A, B: nonextraction.  
C, D: premolar extraction.  
E, F: surgical mandibular advancement.

**Figure 3**  
Follow-up facial view; the patient elected to forego treatment.

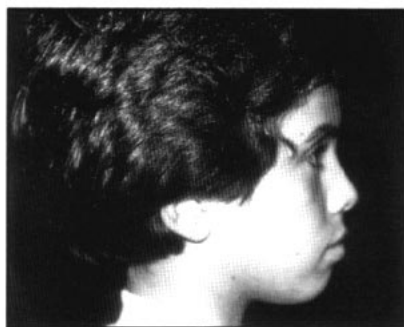

Figure 4A



Figure 4C

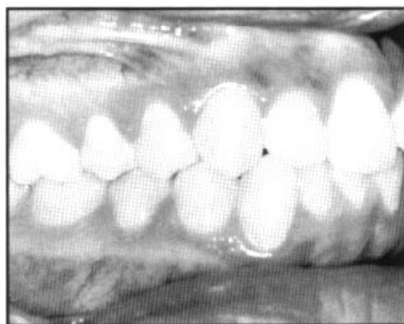

Figure 4B

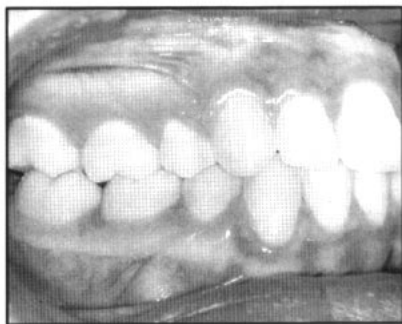

Figure 4D



Figure 6A



Figure 6B

## Case 2

### Figure 4A-D

Profile and lateral occlusal views before (A, B) and after (C, D) premolar extraction treatment.

## Figure 5

Cephalometric superimposition showing incisor retraction during space closure and flattening of the profile. The parents and patient were quite pleased with the treatment outcome.

## Case 3

### Figure 6A-B

Oblique facial views before (A) and after (B) nonextraction treatment. The mother, who considered a concave profile an important family characteristic, was quite unhappy with the result and wanted retreatment with extraction; the daughter refused further treatment.

## Figure 7

Cephalometric superimposition.

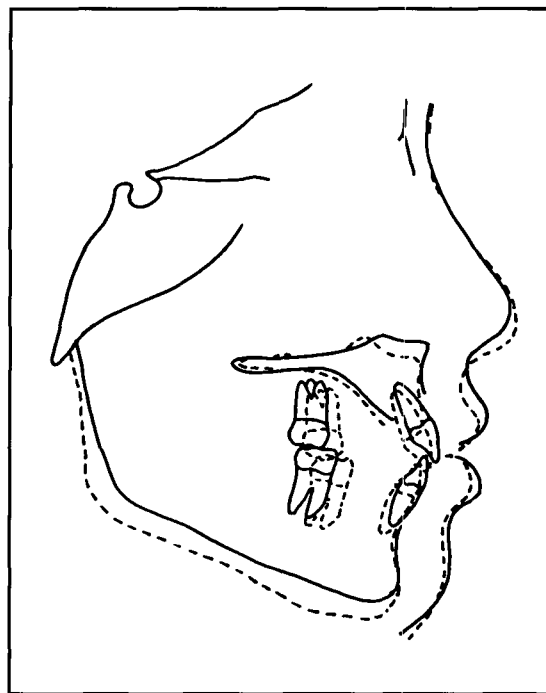


Figure 5

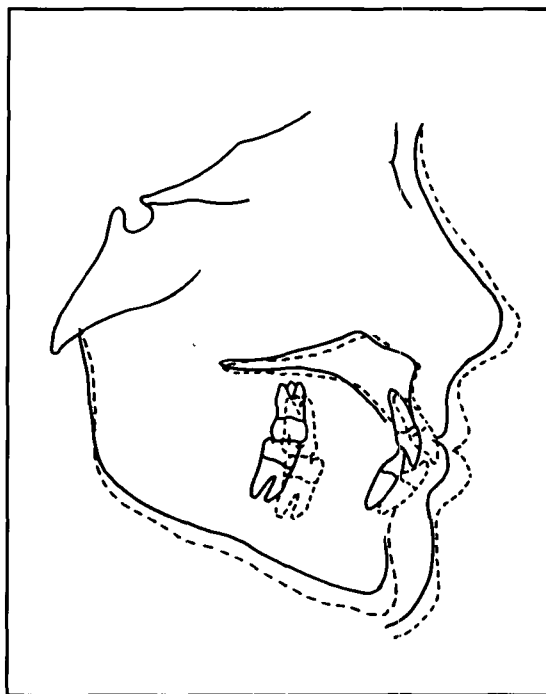


Figure 7

The girl became a photographic model, and her mother, who was very pleased with the decision for no treatment, was kind enough recently to provide a published photograph of her daughter (Figure 3). This case illustrates a patient for whom the potential risks of treatment outweighed the possible benefits, given the relative importance esthetics in her case. Retrospectively, in the absence of functional problems, it is easy to agree with this child's mother that the correct

decision was made. The major issue is who decides which treatment is most appropriate for an individual. In the modern world, the doctor must share that responsibility.

Figures 4 and 5 illustrate the case of another borderline patient. The patient's mother had a rather convex profile and maxillary and mandibular crowding; at age 11, the daughter had a Class I malocclusion with good alignment of her maxillary teeth, slight mandibular anterior crowding, and a convex profile with a tendency toward bimaxillary dental alveolar protrusion. Nonextraction treatment would increase the prominence of the lips; treatment with premolar extraction would reduce it. At age 13, after much discussion, her mother's decision was to have the orthodontic treatment with premolar extraction, to reduce the protrusion and provide greater long-term stability of the incisors. Beauty, of course, is in the eye of the beholder, and both the mother and daughter were extremely satisfied with the outcome of treatment. It remains to be seen how the patient will appear at age 25 or 30 and how she will feel about the decision that was made by her mother.

Figures 6 and 7 illustrate the treatment of a 12-year-old girl with mild mandibular deficiency compensated by retroclined maxillary incisors. Prior to treatment, the patient's profile was concave. From an orthodontist's perspective, it seemed perfectly clear that this malocclusion should be treated without extraction. The patient's lips would probably become somewhat fuller from this treatment. Good facial balance and a pleasing dental outcome were achieved, and although the incisors became considerably proclined, the lower lip at the end of treatment was on the E line. But the patient's mother, who had not been asked before treatment how she felt about her daughter's profile or shown the probable outcome of alternative treatment approaches, was exceedingly disappointed with the facial change. She was proud of her family's characteristic concave profile. After several conferences with the patient's mother, it was decided that four premolars would be extracted and the patient retreated. By that time, the daughter was 14 years of age, and she would not hear of further treatment, which perhaps spared her from treatment that would have benefited the mother more than her.

In this case, the orthodontist operated in a paternalistic fashion, carrying out the treatment he thought best for the patient with minimal consultation. This always carries with it a considerable risk of misunderstanding. Under some

circumstances, these misunderstandings can lead to allegations of negligence. Thus, the consideration of all alternatives and full disclosure, aside from their bioethical merits, also have great benefits from a risk management standpoint. On the other hand, if the parent insists on a course of treatment that the orthodontist feels is not appropriate, he or she is by no means obliged to provide it. The joint construction of treatment goals cuts both ways. Treatment should proceed only when both parties reach a consensus as to the best plan.

### The patient-parent conference

The meeting between the orthodontist and patient/parent to discuss proposed treatment traditionally is called a case presentation conference, but this term does not properly reflect its intent. Case presentation implies that the orthodontist presents information and the patient or parent listens. Although one component is the doctor's presentation of information, the meeting should be a dialogue that will result in consensus. The organization and style of this meeting, which might better be termed the patient-parent conference, is important.

The patient-parent conference should be divided into three components. In the first part, the orthodontist describes the patient's situation and reviews the problem list. It is important to prioritize the problems and to be sure that the patient agrees with that prioritization before proceeding. Then the orthodontist can review the possible treatment strategies. The use of a problem-oriented diagnosis and treatment planning system makes it easy for the orthodontist to delineate the specific problems, describe their severity, and discuss the ways in which each problem can be solved and the attendant risks. If the issues are complex, they should be put into language that the patient can understand.

The second component of the conference is a review of the risk/benefit considerations of treatment and the relative merits of the various treatment alternatives, including the alternative of no treatment. One of the key aspects in obtaining informed consent is delineating for the patient what the risk of forgoing treatment would be. In only a few specific situations are there scientifically valid data to document adverse effects stemming from untreated malocclusion, which means that almost all orthodontic treatment is elective. It is necessary to disclose this to a patient.

The third component of the patient-parent conference is a careful probing of the patient's ex-

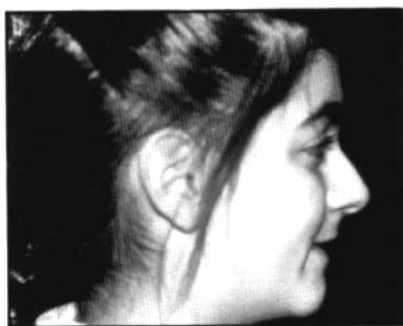

Figure 8A

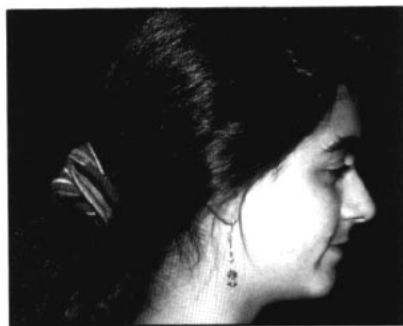

Figure 8C

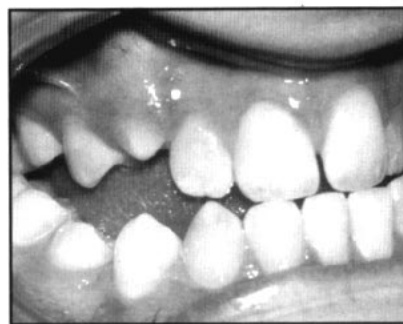

Figure 8B

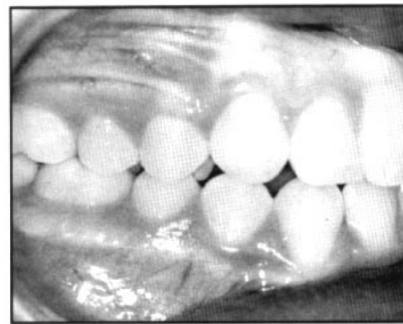


Figure 8D

#### Case 4

**Figure 8A-D**  
Profile and lateral occlusal views before (A, B) and after (C, D) non-extraction orthodontic (nonsurgical) treatment to compensate for skeletal Class III malocclusion.

**Figure 9**  
Cephalometric superimposition. Symptoms of temporomandibular dysfunction developed following treatment, perhaps related to the patient's use of heavier-than-prescribed Class III elastics.

pectations and values. The goal of this conference is a joint decisionmaking effort in which the patient and parent, after reflecting on the various choices, choose the option that best suits their perceived needs. Presenting predictions to patients is not necessary or even desirable in many cases, but when value judgments must be made by the patient in choosing between alternative possibilities, video images can be particularly helpful in facilitating communication.

The problem-oriented format described by Proffit and Ackerman<sup>12</sup> provides a basis for the first two components of the conference. The AAO's informed consent booklet is helpful in reviewing the risks of treatment, but it is important to keep in mind that informed consent requires more than a discussion of risks. To fulfill the third component, the orthodontist must perfect the technique of careful probing and listening so that a true dialogue with the patient develops.

#### Treatment dilemmas in patients with severe problems

Can one always rely on parents to select the best alternative for the treatment of their child? In moderate problems, as the case in Figures 6 and 7 suggests, the answer is not always yes. This is equally true in severe problems. Figures 8 and 9 illustrate the treatment of a 13-year-old girl with a Class III malocclusion and posterior open bite on the right side. The orthodontist's strong suggestion to the father, who was a den-

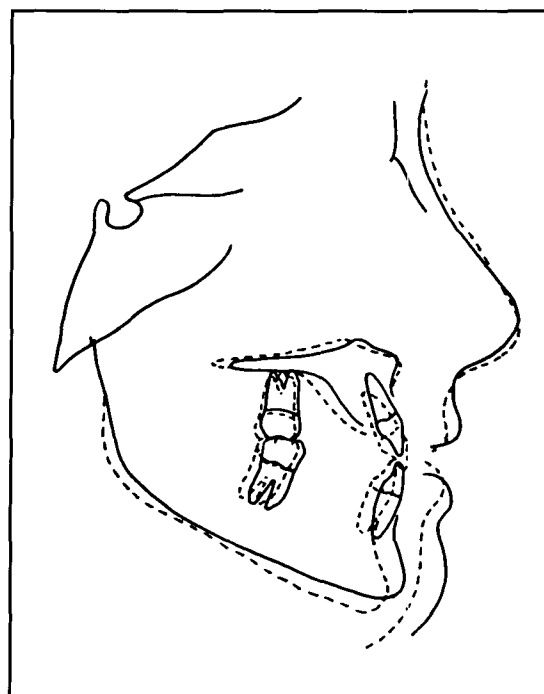


Figure 9

tist, was a combination of orthodontic treatment and orthognathic surgery. The father was concerned about the surgery, and the daughter was strongly opposed. After much discussion, the decision was made to attempt to treat the girl orthodontically without extractions, relying on interarch elastics to correct the occlusion. Should that fail, they would then consider the possibility of surgery.

This patient turned out to be fanatic in her compliance with treatment. She not only wore her elastics full-time, she doubled up on them. An almost miraculous occlusal result was achieved, and her facial balance at the end of treatment was acceptable. Within a year after treatment, however, the patient began to complain of significant pain in her right temporomandibular joint area. After unsuccessful attempts at splint therapy, she was referred for MRI. The MRI revealed a displaced disc and abnormal condyle. There was no history of any trauma, and the TMD may have been exacerbated by the orthodontic treatment. Of course, there can be no assurance that she would not have had TM joint problems after orthognathic surgery. Nonetheless, this illustrates the fact that if one follows a parent's instinct rather than one's own, the potential for an unhappy outcome may increase. If the orthodontist chooses to proceed with less desirable treatment—and there is no obligation to do so—it is important to document that informed consent was obtained and that treatment alternatives were reviewed.

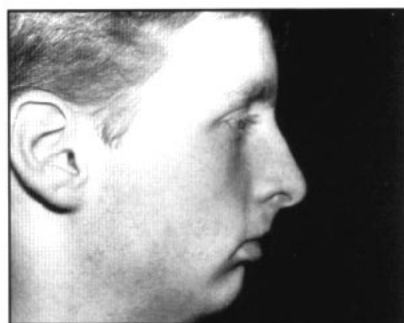

Figure 10A

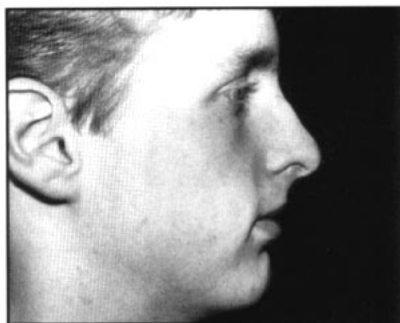

Figure 10C

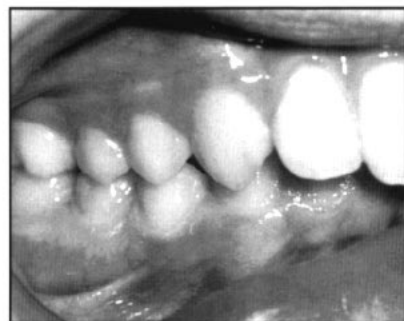

Figure 10B

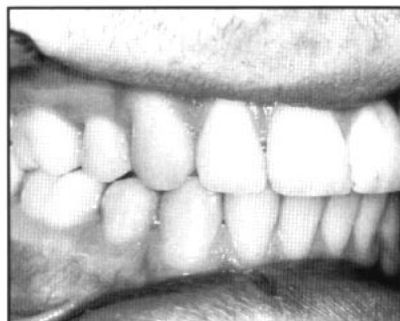


Figure 10C

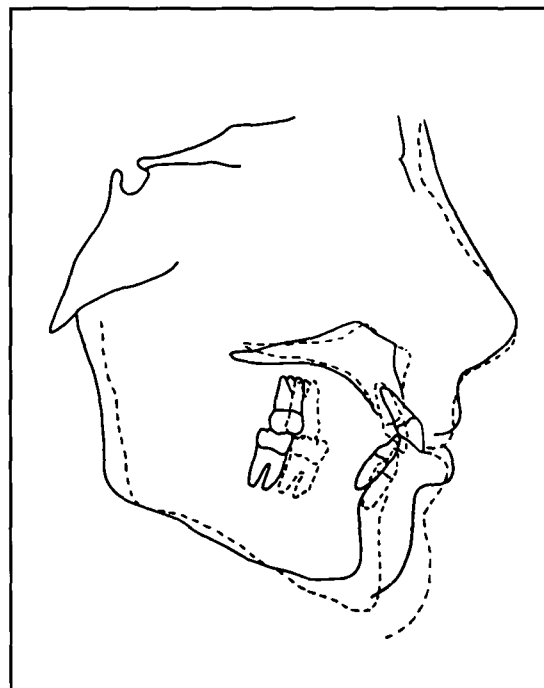


Figure 11

Figures 10-12 illustrate the treatment of a 14-year-old boy with a severe Class II, Division 1, malocclusion due to mandibular deficiency. Note that in this individual, although there was not a major alignment problem, the mandibular incisors were quite procumbent, which would limit the degree to which the mandible could be advanced surgically. Orthodontic treatment alone would produce an unacceptable flattening of the upper lip and might not succeed in totally correcting the malocclusion, but if surgical treatment was planned, extractions would be needed to remove preexisting dental compensation for the skeletal deformity. The video image predictions (Figure 12) were very helpful to the patient and his parents, and they accepted the surgical-orthodontic treatment approach.

Two years later (Figure 11), after the mandibular incisors had been uprighted and the overjet had increased, a LeFort I osteotomy was performed to reposition the maxilla superiorly 3 mm at the incisors, a bilateral sagittal split ramus osteotomy advanced the mandible 9 mm, and a lower border osteotomy in the mandible was used to advance the chin 4 mm. Porous block hydroxyapatite was added to increase the vertical height of the mandible. In this case, the outcome of surgical orthodontic treatment was as good as, if not better than, the computer simulation (compare Figure 12C with Figure 10C). In our experience, as others have also reported,<sup>8</sup> this is generally the case.

It is often easier to achieve consensus in a pa-

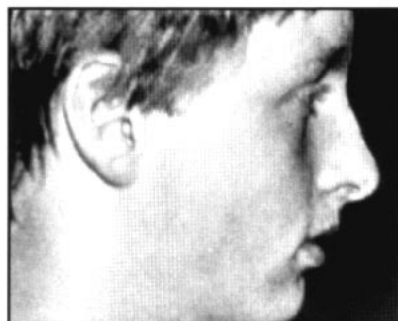

Figure 12A

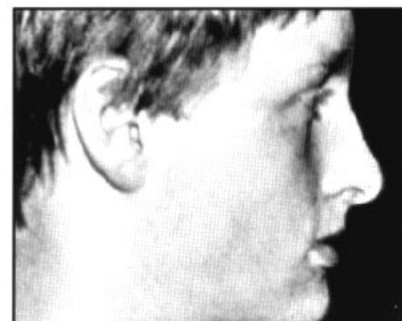

Figure 12C

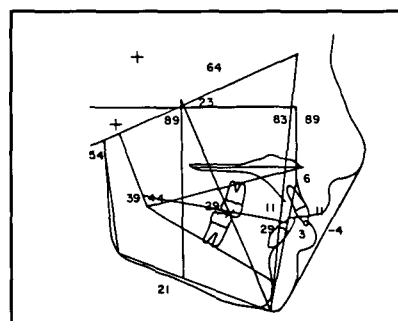


Figure 12B

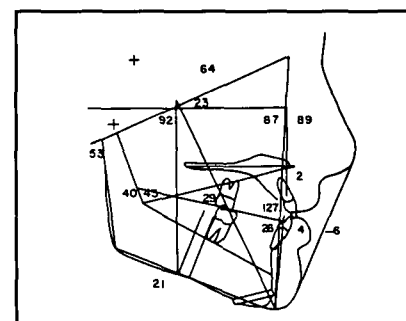


Figure 12D

## Case 5

### Figure 10A-D

Profile and lateral occlusal views before treatment (A,B) and after premolar extraction to correct incisor protrusion, LeFort I osteotomy, bilateral sagittal split osteotomies, and chin augmentation (C,D).

### Figure 11

Cephalometric superimposition pretreatment and finish.

### Figure 12A-D

Video image prediction of the profile outcome of no treatment (A,B), and premolar extraction and two-jaw surgery after orthodontic decompensation (C,D). Compare prediction with Figure 10C.



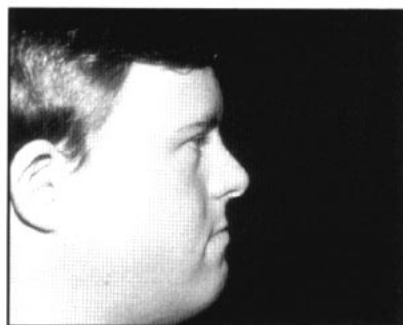

Figure 13A

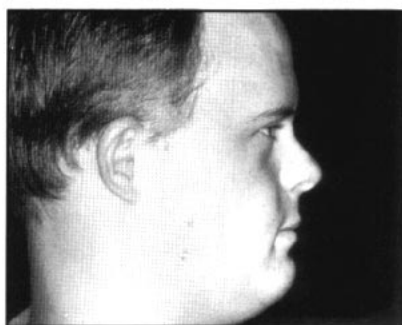


Figure 13C

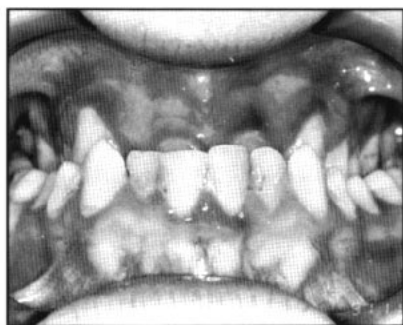

Figure 13B

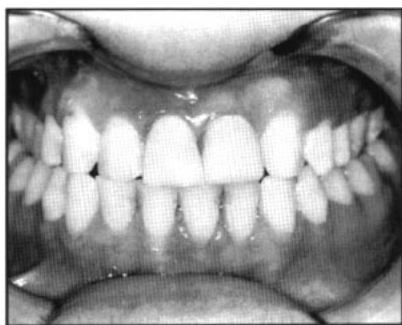


Figure 13D

## Case 6

**Figure 13A-D**  
Profile and intra-oral views of a Down syndrome patient before (A,B) and after (C,D) nonextraction orthodontic treatment and LeFort I osteotomy to advance the maxilla.

**Figure 14**  
Cephalometric superimposition.

tient/parent conference when the patient has severe facial imbalance, but when a patient strongly desires treatment, issues of communication and consent may arise. The competence of the patient to make such a decision is at issue. Figures 13 and 14 illustrate the treatment of an 18-year-old who had Down Syndrome and the typically severe periodontal disease associated with it, as well as idiopathic root resorption of his maxillary incisors. His maxillary left permanent lateral incisor had exfoliated due to root resorption. The patient had a severe Class III malocclusion with maxillary hypoplasia. When this patient was asked facetiously whom he would like to look like after surgery, he said Tom Cruise! In spite of the risks involved, the parents of this patient elected to have combined orthodontic/surgical correction of the problem, which produced significant facial and dental changes. In a letter, the mother commented

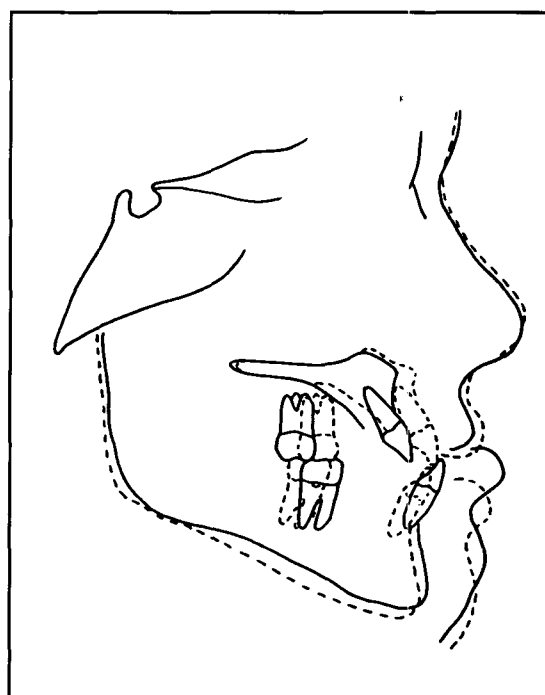


Figure 14

"When we first consulted you, I was concerned only about Chris' dental health. The irregular arrangement of his teeth, thanks to trauma and Down Syndrome, made me wonder how long he would have any teeth. The transformation which began 18 months ago is beautiful. We're not just talking dental health. Chris has gotten so much more! Is it worth putting a child with a disability through this? Yes! These kids have a future. All of Chris' doctors have made his prospects much brighter. My son hasn't stopped smiling!"

Although this letter sounds like a testimonial more appropriate for the *Ladies Home Journal*, it illustrates how a parent's values can impact the orthodontic treatment plan. From the doctors' perspective, the risks of combined orthodontic-surgical treatment in this case were great. What the parent is saying is that from her perspective,



the benefits of treatment far outweighed the risks.

Patients and parents are often surprised to learn that there is more than one "correct" treatment plan. They are sometimes shocked when asked to acknowledge the risks associated with treatment, orthodontic or other, and to weigh the benefits versus the risks. It is the orthodontist's moral and legal responsibility now to advise a patient of the risk/benefit considerations of treatment, the alternative treatment possibilities, including compromises, and the risks of no treatment. If one accepts the bioethical and medicolegal premise that orthodontic treatment goals should be jointly constructed by the doctor and patient, then logically one must agree that to gain consensus, accommodations or compromises are often necessary. The consideration

of all viable alternatives and full disclosure, aside from its bioethical merits, is of great benefit from a risk management standpoint. In the last analysis, the moral, ethical and legal imperative in the orthodontic decisionmaking process is that a patient or parent's consent for treatment must be an informed one.

#### Acknowledgments

Orthognathic surgery for these patients was performed by Harvey M. Rosen, DMD, MD. Video predictions were done using the Quick Ceph Image program.

#### Author Address

James L. Ackerman, DDS  
931 Haverford Road  
Bryn Mawr, PA 19010

#### References

- Downs WB. Variations in facial relationships: their significance in treatment and prognosis. *Am J Orthod* 1948; 34:812-840.
- Bell WH. LeFort I osteotomy for correction of maxillary deformities. *J Oral Surg* 1975; 33:412-426.
- Canterbury v. Spence, 464F 2d 772 (D.C. Cir. 1972).
- Ackerman JL. Autonomy versus paternalism in the decision making process: the doctrine of informed consent. In Ghafari JG, Moorrees CFA (eds), *Orthodontics at the Crossroads*. Boston: Harvard Society for the Advancement of Orthodontics, 1991 (Library of Congress Catalog Card Number: 93-78158).
- Abrams EZ, Goodman JF. Diagnosing developmental problems in children: parents and professionals negotiate the bad news. *J Social Sci Med*, pending.
- Katz J. *The silent world of doctor and patient*. New York, The Free Press (div. MacMillan Inc), 1984.
- Sarver DM. Videoimaging: the pros and cons. *Angle Orthod* 1993; 63:167-172.
- Sinclair PW, Kilipilanen P, Phillips C, White RP Jr, Sarver DM. The accuracy of video imaging in orthognathic surgery. *Am J Orthod Dentofac Orthop* 1995; 107:177-185.
- Machen DE. Orthodontic treatment and facial appearance. *Am J Orthod Dentofac Orthop* 1991; 99:185-186.
- Phillips C, Hill B, Cannac C. The influence of video imaging on patients' perceptions and expectations. *Angle Orthod*, 1995;65(4)263-270.
- Serrano MJ. Prospective observational study of patient expectations and satisfaction with orthognathic surgery. Masters thesis, Univ. of North Carolina, 1994.
- Proffit WR, Ackerman JL. Problem-oriented diagnosis and treatment planning. In Proffit WR, *Contemporary Orthodontics*, 2nd ed. St. Louis: CV Mosby, 1993; chapters 6 and 7.