

Case Report MH:

Treatment of a severe Class II, Division 1 malocclusion in a growing female with Class III skeletal relationship, low mandibular plane angle, and prominent nose and chin

Jon Årtun, DDS, Dr. Odont; Charles D. Alexander, DDS, MSD;
Ronald H. Ellingsen, DDS, MSD

The patient presented as a healthy 12-year-old girl with a history of no significant medical problems. She had been on semi-annual dental recall and had excellent oral hygiene. Her chief complaint was that her maxillary incisors were "sticking out." She mentioned occasional discomfort due to impingement of the mandibular incisors on the palate.

Diagnostic summary

Extraoral evaluation revealed a slightly convex soft tissue profile with the nose and chin prominent. The lips were retrusive relative to Ricketts' E-line, particularly when smiling. Lower anterior facial height was reduced and the mentolabial fold was deep (Figure 1).

Cephalometric evaluation revealed a severely retrognathic maxilla, severely proclined maxillary incisors, mandibular dentoalveolar retrusion, and a Class III skeletal relationship. The mandibular plane angle was low, and there were signs of anterior rotation of the mandible during growth (Figure 3).

Model analysis showed a full Class II molar and canine relationship bilaterally, excessive overjet and overbite, and a deep curve of Spee. Arch length was slightly deficient in both arches.

The patient was 5' 3" tall and 6 months post-menarchal. She had no siblings, but her mother's height of 5'6" suggested that further growth was questionable. She was enthusiastic, bright, and highly motivated to start treatment.

Treatment alternatives

Orthodontic treatment combined with orthognathic surgery

1. Extraction of maxillary first premolars and maximum anchorage control during incisor retraction would correct the malocclusion. If this procedure were to be followed by maxillary advancement and mandibular dentoalveolar advancement, both the dental and skeletal deviations could be corrected. Due to the limited indications for total mandibular subapical osteotomy, information on the outcome of this treatment approach was very scarce.¹ The procedure requires close attention to detail to avoid surgical damage to the neurovascular bundle and root apices. Relapse could also be a problem following removal of the orthodontic appliances.¹ The surgical alternative is bimaxillary advancement. One aim of the

Figure 1 A-C
Pretreatment extraoral photographs show a prominent nose and chin and retrusive lips, particularly when smiling.

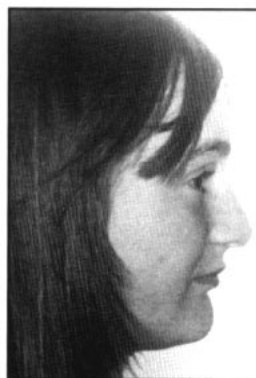

Figure 1A

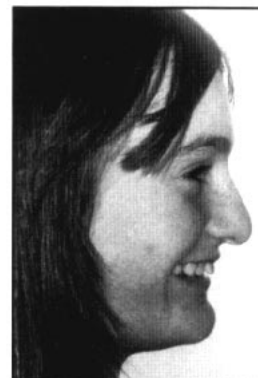

Figure 1B



Figure 1C

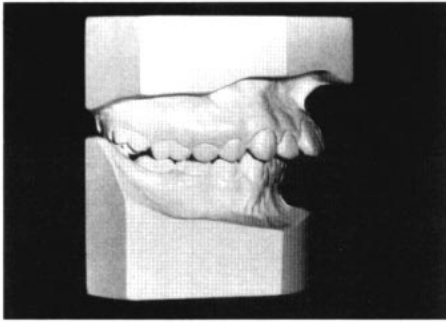


Figure 2A

Figure 2A-E

Pretreatment study models. Note severe Class II, excessive overjet, and moderate arch length deficiency.

Figure 3

Pretreatment cephalometric tracing. Note severely proclined maxillary incisors, mandibular dentoalveolar retrusion, and Class III skeletal relationship.

Figure 4

Pretreatment panoramic radiograph.

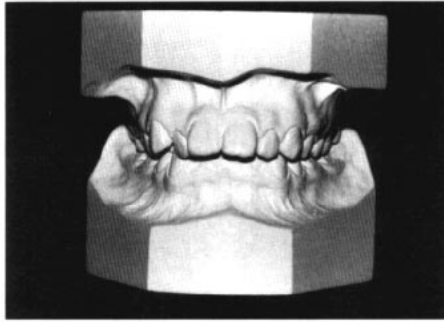


Figure 2B

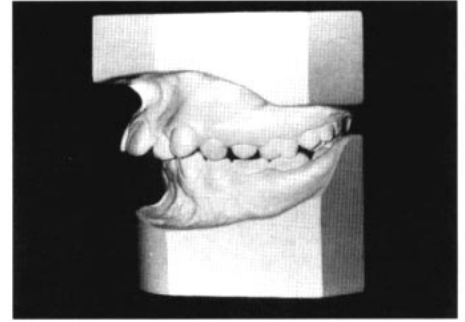


Figure 2C

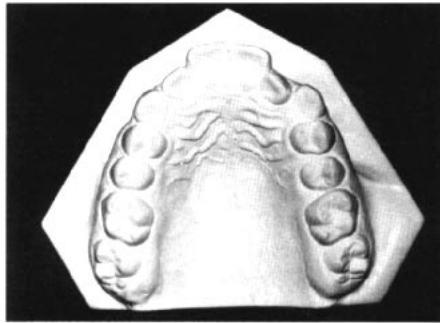


Figure 2D

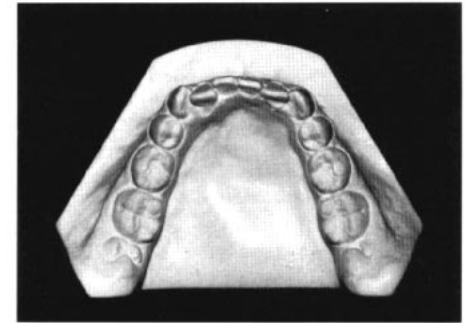


Figure 2E

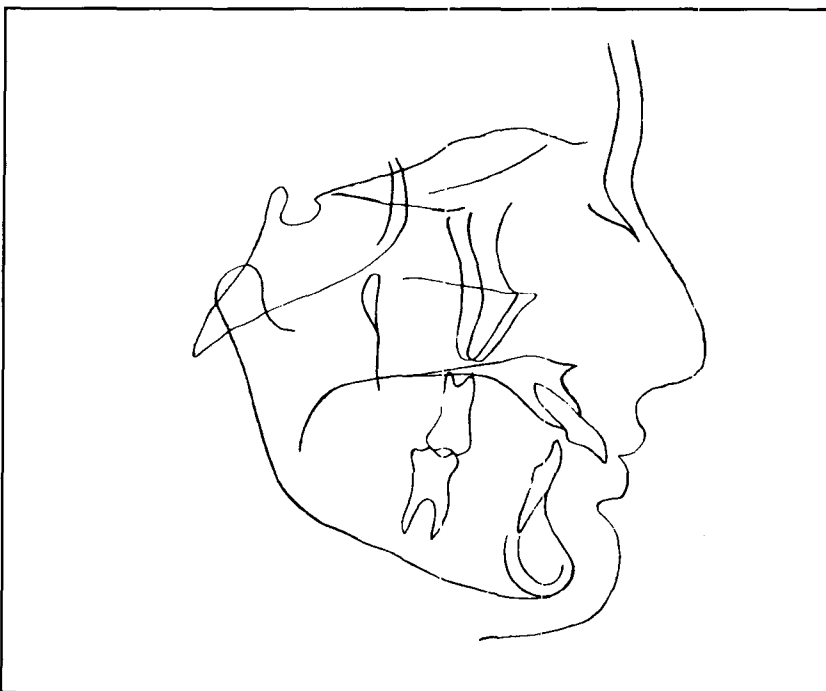


Figure 3

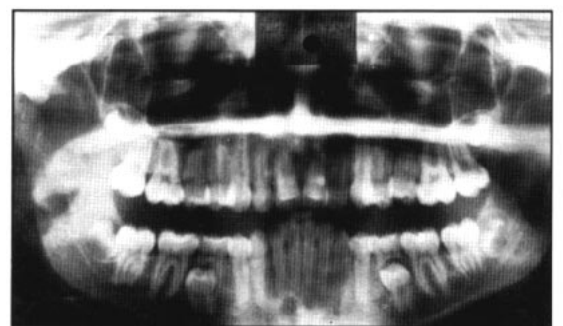


Figure 4

the soft tissue response.³ Follow-up evaluations of bimaxillary advancements are limited. However, inferences from studies on stability of maxillary⁴ and mandibular⁵ advancement using rigid fixation indicate that the success rates may be high.

2. The second option was to combine a nonextraction treatment approach with a mandibular subapical osteotomy or a bilateral sagittal split osteotomy. With these procedures, any correction of the excessive maxillary incisor proclination would be limited to labial root torque during the presurgical orthodontic phase. This may be associated with formation of bone dehiscences and increased risk of gingival recession.^{6,7} The surgical procedures would also aggravate the skeletal discrepancy.

Conventional orthodontic treatment

1. An extraction alternative in the mandible would allow leveling and alignment without proclining the incisors. However, regardless of

presurgical orthodontic treatment would then be to maintain the deep bite. That would allow posterior rotation of the distal fragment during surgery, reducing the potential for excessive chin prominence and increasing the anterior facial height. A recent follow-up study suggests that such increase in facial height is stable.² A reduction genioplasty might further reduce the potential for chin prominence. One problem with this procedure is the unpredictability of

which teeth are extracted and how careful the mechanics, it might be difficult to close the extraction sites without any retraction of the anterior segment, thereby increasing the amount of retraction necessary in the maxillary anterior segment. A nonextraction alternative in the mandible might therefore reduce the potential for a negative impact on the profile and also reduce anchorage requirements in the maxilla. However, leveling the excessive curve of Spee and aligning the mandibular incisors might require considerable proclination of the mandibular incisors, increasing the potential for gingival recession.^{6,7}

2. A nonextraction alternative in the maxilla would require excellent patient compliance and favorable growth. Headgear therapy could cause a reduction in facial convexity through inhibition or redirection of maxillary growth in combination with distal movement of the maxillary dentition.^{8,9} Dentoalveolar change might allow favorable retroclination of the incisors, while the skeletal change could make the skeletal discrepancy worse. Cervical pull headgear could cause maxillary molar extrusion with secondary backward rotation of the mandible.⁸ Any backward mandibular rotation would reduce the negative impact on the skeletal discrepancy, and the concomitant increase in anterior facial height might be considered advantageous.

The maxillary incisors need to be retracted to a position dictated by the mandibular incisors. Accordingly, the posttreatment outline of the anterior portion of the maxilla is likely to be similar regardless of extraction approach in the maxilla, since the apical portion of the alveolar process is likely to follow the root apices during incisor retraction. However, extraction of maxillary premolars would likely lessen the need for headgear wear, reducing the possibility of influencing the vertical dimension.

Treatment

After reviewing all options with the patient and parents, a conventional orthodontic treatment approach was selected. The nonextraction strategy was preferred, with extraction of maxillary first premolars as an alternative if necessary due to unfavorable growth or cooperation.

Initially the maxillary first molars were banded and the patient was asked to wear cervical headgear for 12 hours a day. Cooperation proved to be excellent, with attainment of a Class I molar relationship in 5 months. At that time full appliances were placed in the maxillary arch. The spaces developed through head-

gear wear were closed using power chains buccally and lingually from the first premolars to the first molars. The incisors and canines were retracted in a friction-free manner using closing loops distal to the canines. A round archwire was used initially to facilitate reduction in incisor proclination. The plan was to change to a rectangular wire once correct incisor inclination was achieved. After 10 months of treatment the mandibular second premolars had erupted and appliances were placed on the entire mandibular arch. A rectangular archwire was placed following leveling and alignment. Cervical headgear was used throughout treatment and Class II elastics were used for 5 months. Appliances were removed after 29 months of active treatment.

Treatment results

A favorable occlusal result was achieved, with acceptable interdigitation and incisor contact (Figure 5). The Class II mechanics caused only minimal reduction in maxillary prognathism. One explanation for this may be that the incisor retroclination caused some labial movement of the apical third of the roots, allowing some bony apposition in the area of the cephalometric point A. Despite considerable maxillary molar extrusion, the mandible rotated anteriorly during treatment, probably due to an excessive vertical growth component of the condyles. This resulted in a significant reduction in inclination of the mandibular plane and an increase in mandibular prognathism and Class III skeletal discrepancy (Figure 6). Due to growth of the nose and forward translation of pogonion, a significant retrusion of the upper lip relative to Ricketts' E-line occurred during treatment. This was particularly evident when smiling (Figure 8).

Retention

A maxillary wraparound retainer with an anterior bite plane was used. The patient was instructed to wear the retainer for 24 hours per day the first 6 months, at night only for another 18 months, and thereafter as needed. The bands on the maxillary first molars were not removed until 6 months after treatment, to allow active retention with cervical headgear 3 nights per week. A 0.032" spiral wire was bonded to the mandibular canines to maintain incisor alignment.

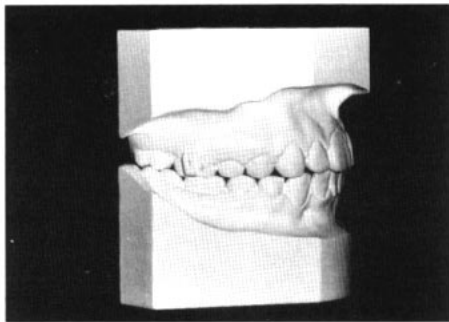


Figure 5A

Figure 5A-E

Posttreatment study models.

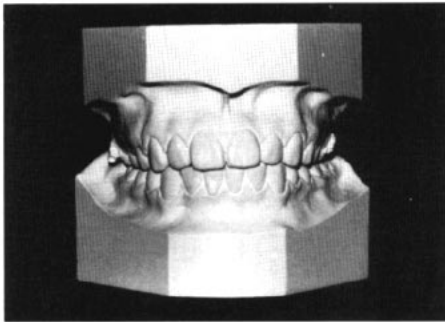


Figure 5B

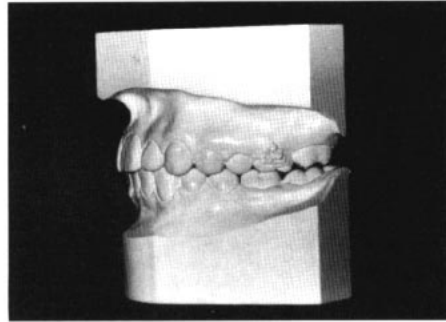


Figure 5C

Figure 6

Pre- and posttreatment cephalometric superimposition. Note anterior mandibular rotation despite considerable maxillary molar extrusion.

Figure 7

Posttreatment panoramic radiograph.

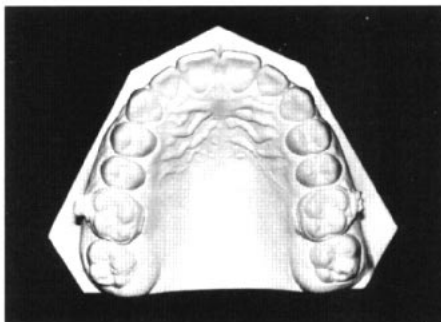


Figure 5D

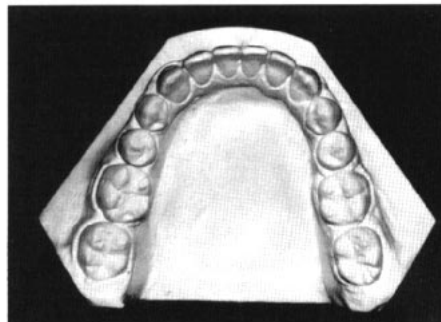


Figure 5E

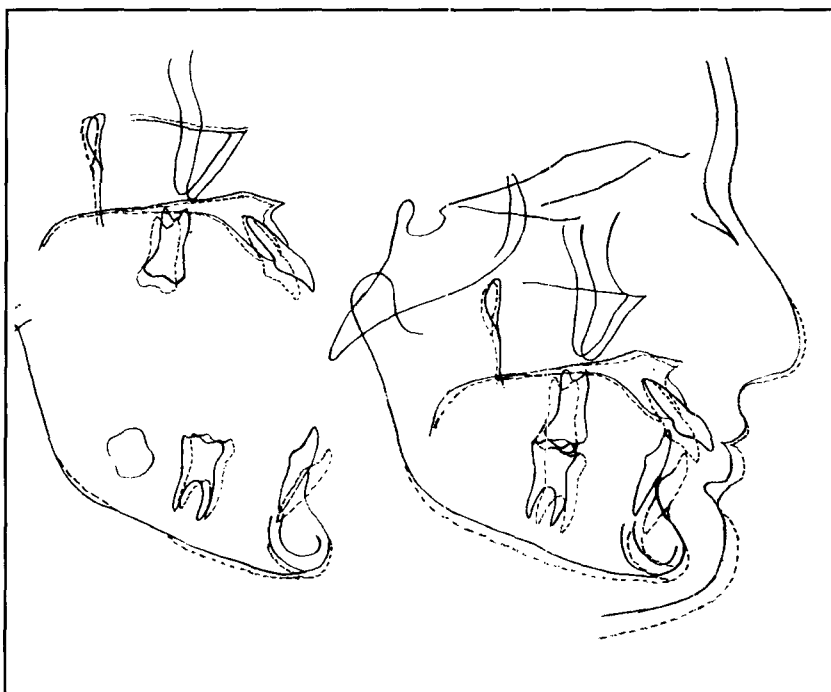


Figure 6

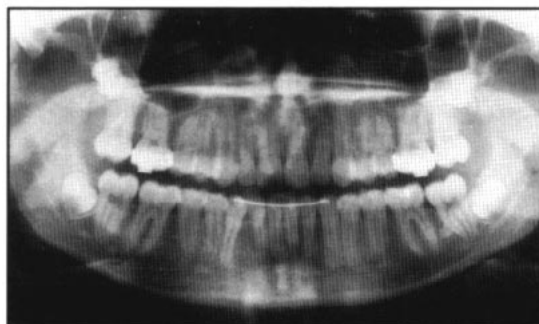


Figure 7

Final evaluation

A follow-up evaluation 2 years posttreatment showed excellent stability of the posterior segments (Figure 9). This is in keeping with a recent study concluding that there is only a minor tendency for relapse of molar, premolar, and canine relationships following successful Class II correction.¹⁰ A slight increase in overjet was observed. Gingival recession on the mandibular right central incisor (Figure 9) appeared shortly after active treatment and is not likely to progress.⁷ The continued anterior rotation of the mandible and concomitant translation of pogonion made the lip retrusion relative to Ricketts' E-line slightly worse (Figure 11). On the other hand, the face is well balanced and characteristic for patients exhibiting excessive forward growth rotation. The lips are curved and nicely related to each other, and the patient has a beautiful smile in frontal view. The lip retrusion is really noticeable only in lateral view

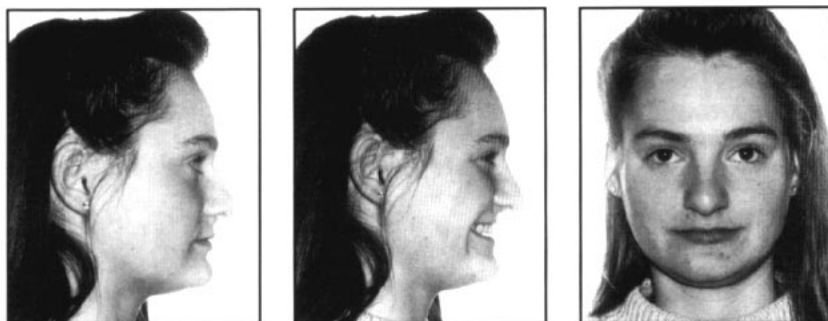


Figure 8A

Figure 8B

Figure 8C

Figure 8A-C
Posttreatment extraoral photographs showing a well balanced face with prominent nose and chin and retrusive lips.

Figure 9A-C
Intraoral photographs at 2-year follow-up. Note intercuspation, a slight increase in overjet, and gingival recession on mandibular right central incisor.

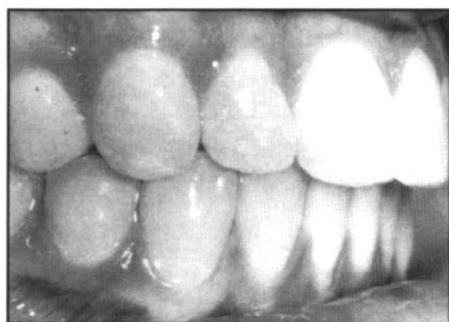

Figure 9A

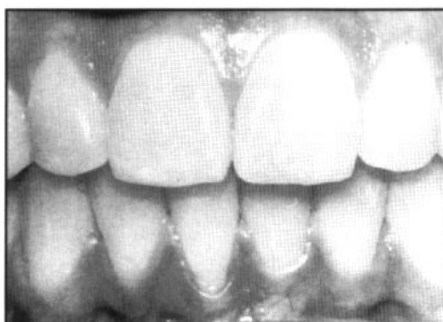

Figure 9B

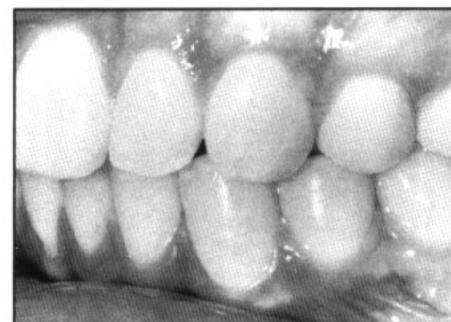

Figure 9C

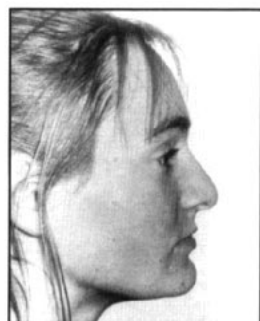

Figure 10A

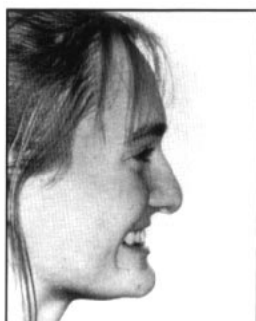

Figure 10B

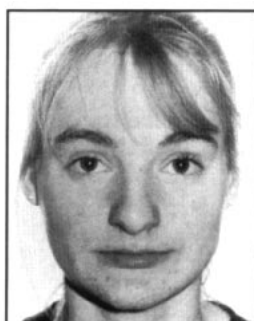

Figure 10C

Figure 10A-C
Extraoral photographs at 2 year follow-up. Note severely retrusive lips when smiling.

Figure 11
Posttreatment and follow-up cephalometric superimposition. Note proclination of maxillary incisors, retroclination of mandibular incisors, and anterior mandibular rotation.

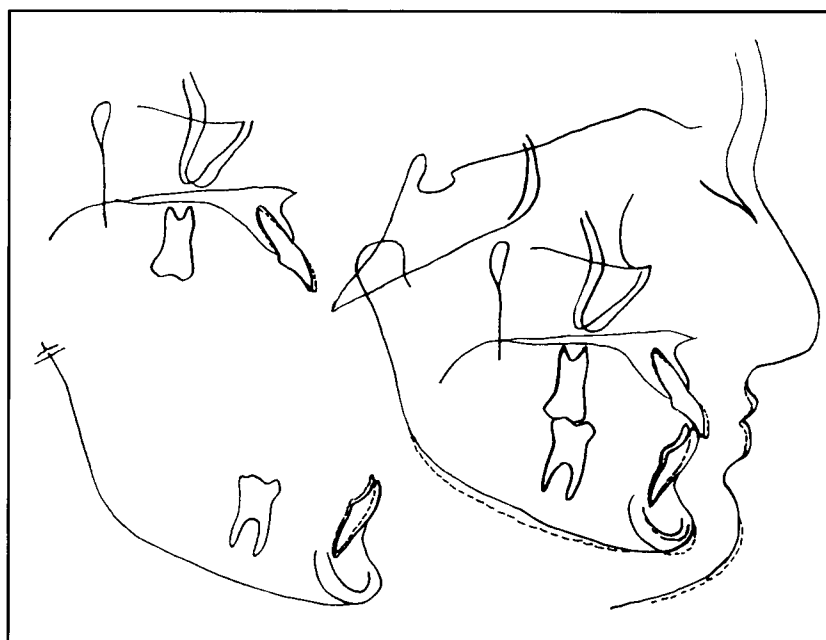


Figure 11

upon smiling (Figure 10). The treatment did not reduce the potential for skeletal correction through orthognathic surgery. However, it is a judgment call whether the efforts and risks associated with orthognathic surgery are warranted in this case.

Author Address

Dr. Jon Årtun
Department of Orthodontics
School of Dentistry
Mail Stop SM 46
University of Washington
Seattle, WA 98195

J. Artun is a professor at the University of Washington, Department of Orthodontics, in Seattle.

C.D. Alexander is in private practice in Arlington, Texas.

R.H. Ellingsen is in private practice in Spokane, Wash.

References

1. Buckley MJ, Turvey TA. Total mandibular sub-apical osteotomy: a report on long-term stability and surgical technique. *Int J Adult Orthod Orthogn Surg* 1987;2:121-130.
2. Witt DW, Kokich VG, Joondeph DR. Long-term stability of increasing lower anterior facial height with mandibular sagittal osteotomies. *Angle Orthod* (in press).
3. Bell WH, Brammer JA, McBride KL, Finn RA. Reduction genioplasty: Surgical techniques and soft-tissue changes. *Oral Surg Oral Med Oral Path* 1981;51:471-477.
4. Proffit WR, Phillips C, Prewitt JW, Turvey TA. Stability after surgical-orthodontic correction of skeletal Class III malocclusion. II. Maxillary advancement. *Int J Adult Orthod Orthogn Surg* 1991;6:71-80.
5. Knaup CA, Wallen TR, Bloomquist DA. Linear and rotational changes in large mandibular advancements using three or four fixation screws. *Int J Adult Orthod Orthogn Surg* 1993;8:245-263.
6. Steiner GG, Pearson JK, Ainamo J. Changes of the marginal periodontium as a result of labial tooth movement in monkeys. *J Period* 1981;52:314-320.
7. Årtun J, Krogstad O. Periodontal status of mandibular incisors following excessive proclination: A study in adults with surgically treated mandibular prognathism. *Am J Orthod Dentofac Orthop*, 1987;91:225-232.
8. Melsen B. Effects of cervical anchorage during and after treatment: An implant study. *Am J Orthod* 1978;73:526-540.
9. Baumrind S, Molthen R, West EE, Miller DM. Distal displacement of the maxilla and the upper first molar. *Am J Orthod* 1979;75:630-640.
10. Fidler BC, Årtun J, Joondeph DR, Little RM. Long-term stability of Angle Class II, division 1 malocclusions with successful occlusal results at end of active treatment. *Am J Orthod Dentofac Orthop* 1995;107:276-285.