

Treatment of Mandibular Asymmetry by Distraction Osteogenesis and Orthodontics: A Report of Four Cases

Azita Tehrani, DMD^a; Hossein Behnia, DMD^b

Abstract: Distraction osteogenesis devices followed by hybrid functional appliance therapy and fixed orthodontic appliance therapy were used to correct a variety of maxillofacial skeletal and dental deformities in 4 patients. The patients underwent procedures to lengthen the mandibular ramus and body. Transcutaneous pins were used to activate the distraction devices. After achieving the desired skeletal position, the distraction devices were maintained for 2 to 3 months to allow ossification. Following distraction, functional orthodontic appliance therapy was initiated during growth to correct the cant of the occlusal plane by extrusion of teeth on the affected side for improved facial symmetry. Fixed orthodontic therapy was used for final occlusal adjustments. All patients achieved lengthening of their jaws and substantial improvement in facial symmetry and occlusion. The follow-up period for this group of 4 patients ranged from 18 to 36 months. (*Angle Orthod* 2000;70:165–174.)

Key Words: Case report; Tehrani; Behnia; Case report: Distraction osteogenesis

INTRODUCTION

Deficiencies in growth of 1 or both condyles of the mandible may result from multiple causes. Condylar fractures at an early age may affect growth centers. Congenital deformities, such as Goldenhar's syndrome, Nager's syndrome, craniofacial scoliosis, and Pierre Robin syndrome, may present mandibular hypoplasia with varying degrees of severity.^{1–3}

Hemifacial microsomia is a relatively common facial malformation, second in frequency only to clefts of the lip and palate.⁴ In this group of hypoplasias the mandibular deficiency may be associated with microtia, facial asym-

metry, deviation of the chin to the affected side, and hypoplasia of the soft tissues. The unilateral deficiency in mandibular growth, including its associated soft tissues and masticatory muscles, alters symmetrical vertical growth of the maxilla and may also alter the position of the orbit.⁴

Patients with branchial arch dysplasias characteristically show hypogenesis or agenesis of the condylar process and mandible.⁵ As a result, the facial deformities often become worse during growth.⁵ In growing patients, orthopedic treatment with functional appliances is often indicated.^{5,6} After pubertal growth, mild deformities can be corrected with orthodontic treatment, genioplasty, or unilateral mandibular augmentation, while more severe cases may require simultaneous mandibular and maxillary surgery.⁷ Early surgical intervention with autogenous costochondral grafting may be indicated for patients with severe deformities.⁵

Gradual traction on living tissues can create stresses that will stimulate and maintain regeneration and active growth of tissue structure.^{5,8} Under the proper conditions, cells associated with the free surfaces of bone can differentiate into osteogenic or chondrogenic cells needed for repair or growth. The process of generating new bone by stretching

^a Azita Tehrani, Assistant Professor, Orthodontic Department, Shahid Beheshti University of Medical Sciences, Tehran, Iran.

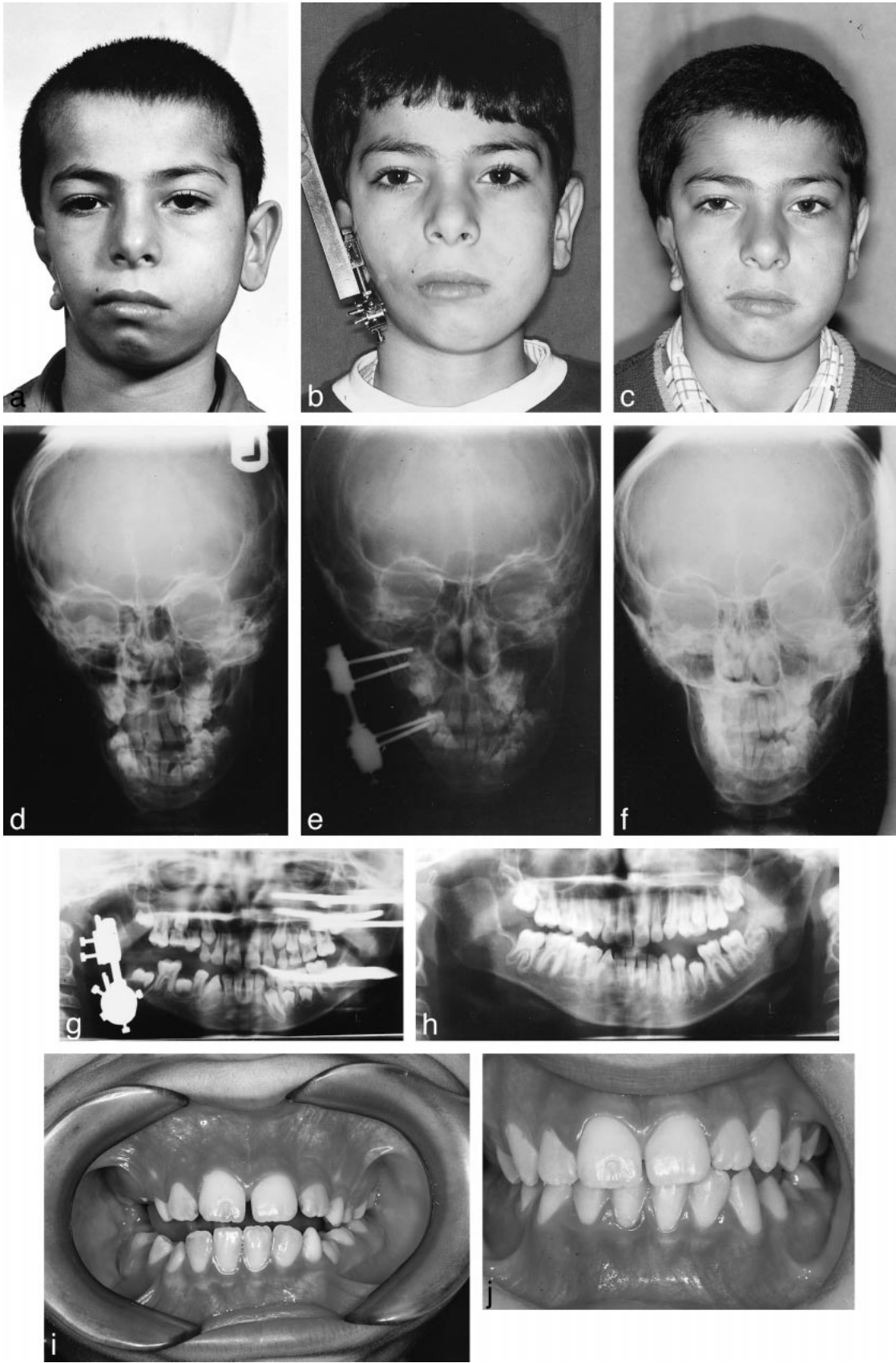
^b Hossein Behnia, Associate Professor, Oral and Maxillofacial Surgery Department, Shahid Beheshti University of Medical Sciences, Tehran, Iran.

Corresponding author: Azita Tehrani, 1317 Vanak Square, 15179 Tehran, Iran
(e-mail: arashkh@yahoo.com).

Accepted: November 1999. Submitted: March 1999.

© 2000 by The EH Angle Education and Research Foundation, Inc.

FIGURE 1. Case 1. (A) Pretreatment Facial photograph (frontal view). (B) Facial photograph after 19 mm mandibular distraction. (C) Facial photograph 2 years following treatment. (D) Pretreatment postero-anterior cephalometric radiograph. (E) Postero-anterior cephalometric radiograph after 19 mm mandibular of distraction. (F) Postero-anterior cephalometric radiograph 2 years following treatment. (G) Panoramic radiograph with distraction device in place. (H) Panoramic radiograph 2 years following treatment. (I) Dental occlusion after mandibular distraction. (J) Dental occlusion after orthodontic treatment



was introduced by Ilizarov^{8,9} and is called distraction osteogenesis. Based on experimental and clinical studies over 35 years, he suggested that distraction osteogenesis could be used to treat 17 types of injuries or orthopedic diseases.⁹

Gradual bone lengthening by distraction has been a standard procedure for treating endochondral bones of the hands and feet. Synder et al¹⁰ described the first use of distraction osteogenesis in the canine mandible. Sawaki¹¹ reported distraction osteogenesis in sheep. Michieli and Miotti¹² were able to lengthen the dog mandible using an intraoral distraction device attached to the mandibular dentition.

Other investigators^{10,13-18} have also reported successful experimental studies of mandibular lengthening by distraction osteogenesis. In 1992, McCarthy et al¹⁹ reported the first clinical cases of mandibular lengthening by gradual distraction. Molina et al⁴ reported mandibular elongation by distraction as a farewell to major osteotomies.

Distraction techniques have been used in the human facial bone area for the past 10 years.²⁰⁻²¹ The biomechanical effects of mandibular lengthening in 32 rabbits have been shown on a cellular and histological level.²² Techniques and equipment are improving and intraoral osteogenic distraction devices have recently been developed and used.²³

CASE REPORTS

A distraction device was fabricated for 4 patients, 2 males and 2 females, ranging in age from 9 to 15 years. The design of each distractor was determined by the desired vector and magnitude of skeletal correction, morphology of the distraction site, access for placement of the device and osteotomy, and access for placement of the activating pin.

Transcutaneous pins were used extraorally to stabilize the distraction devices to the skeletal fragments on both sides of the osteotomy line in the ramus. After allowing 1 week for the healing of the periosteum, the distraction was performed at the rate of 1 mm per day (four turns all at once). The amount of distraction ranged from 19 to 22 mm. None of the patients showed any evidence of dysfunction of the ipsilateral inferior alveolar nerve or other complications.

Dental models, lateral cephalograms, anteroposterior cephalograms, and panoramic radiographs were obtained pre- and post-distraction and at 12-month intervals.

Orthodontic treatment was initiated with hybrid functional appliances after completion of active mandibular lengthening. Distractor devices were maintained in place 2 to 3 months during the retention period. The main goals of the orthodontic therapy were extrusion of teeth on the affected

side for correction of the cant of occlusal plane, creation of facial and dental symmetry, and acceptable occlusion. Due to the asymmetrical nature of the skeletal deformity in craniofacial microsomia and idiopathic unilateral mandibular hypoplasia, attempts were made to obtain symmetry in all patients during growth using hybrid functional appliances. Fixed orthodontic appliances and 0.018 inch edge-wise brackets were used for mechanotherapy.

Case 1, Figure 1A-J

MK, a 9-year-old male with right-side craniofacial (hemifacial) microsomia (Group III Meurman Classification) demonstrated an asymmetric face with canting of the occlusal plane and a 40 mm maximum bite opening. He underwent a corticotomy procedure and a lengthening device was placed on the right side. He tolerated 19 mm of mandibular distraction well and the treatment resulted in a shift of the chin point relative to the craniofacial midline. As the distraction progressed, a dental lateral open bite developed on the right side. The mandible was maintained in fixation for 2 months following distraction.

A hybrid functional appliance was used to overcorrect and maintain facial and dental symmetry. The acrylic on the occlusal surface on the right side of the appliance was trimmed to allow for changing the occlusal plane.

Three years after the distraction osteogenesis and functional orthodontic treatment, the mandible remained corrected and the occlusion and cant of occlusal plane were acceptable.

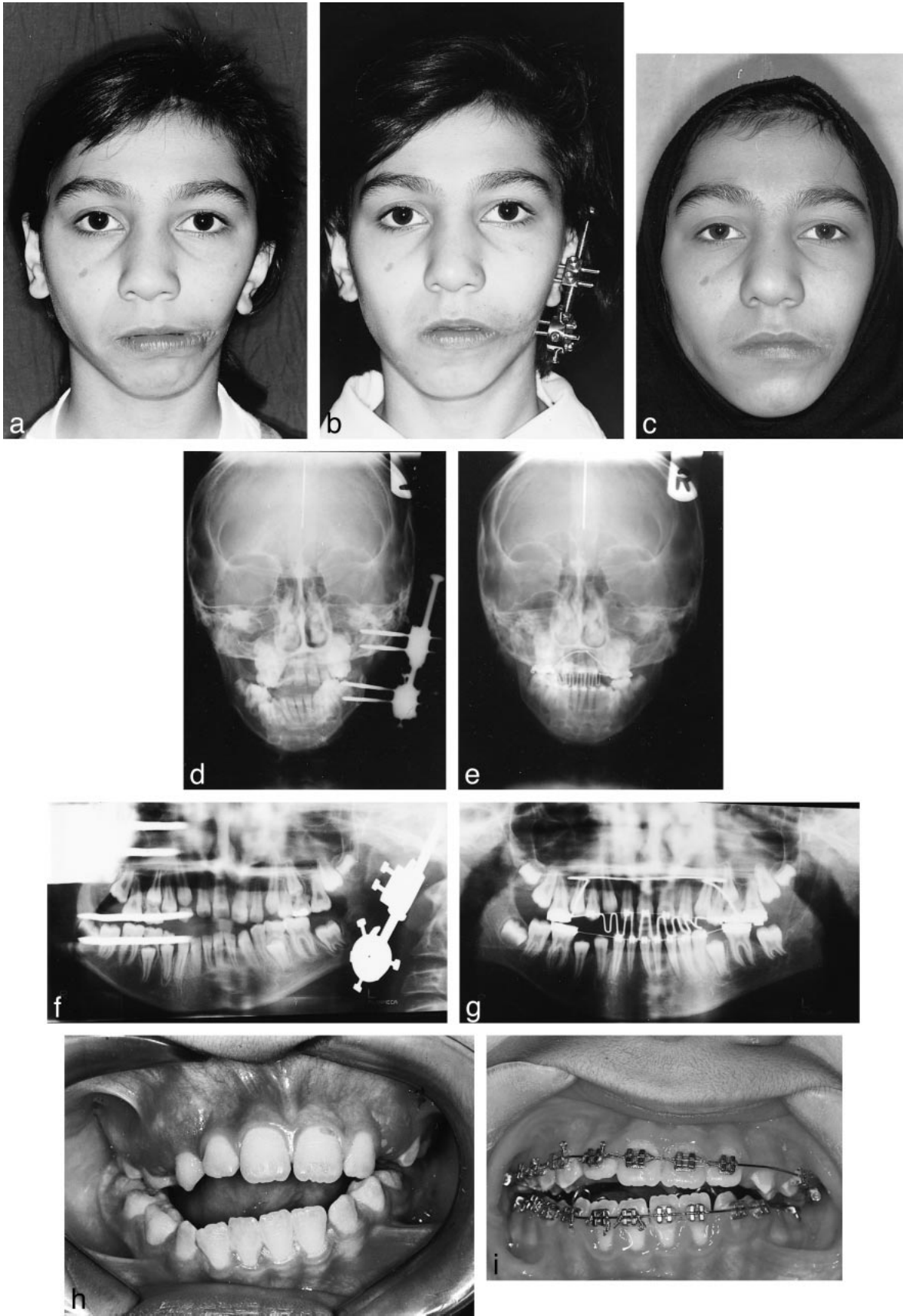
A comparison of pre- and post-treatment radiographs shows a considerable increase in the length of the affected mandibular body. During 3 years of orthodontic therapy, a balance of growth on both sides was achieved. In the years ahead, the patient will undergo soft tissue surgery.

Case 2, Figure 2A-I

SG is a 12-year-old girl with a previous facial cleft on her left side and a 12 mm unilateral anterior open bite on the right. A corticotomy was performed and a distraction device was inserted. The left side of the mandible was lengthened 20 mm. The post-lengthening fixation period was 3 months. An occlusal bite plane was used during this period for correction of the cant of occlusal plane and extrusion of teeth on the affected side.

Soon after removal of the distractor, a fixed tongue guard was placed in the upper arch and fixed orthodontic mechanics were used to obtain acceptable occlusion. Three

FIGURE 2. Case 2. (A) Facial photograph before treatment. (B) Facial photograph with distraction device and 20 mm of distraction. (C) Facial photograph 1 year following treatment. (D) Postero-anterior cephalometric radiograph with 20 mm of mandibular distraction. (E) Postero-anterior cephalometric radiograph 1 year following treatment. (F) Panoramic radiograph with mandibular distraction device in place. (G) Panoramic radiograph 1 year following treatment. (H) Dental occlusion after mandibular distraction. (I) Dental occlusion 1 year after treatment.



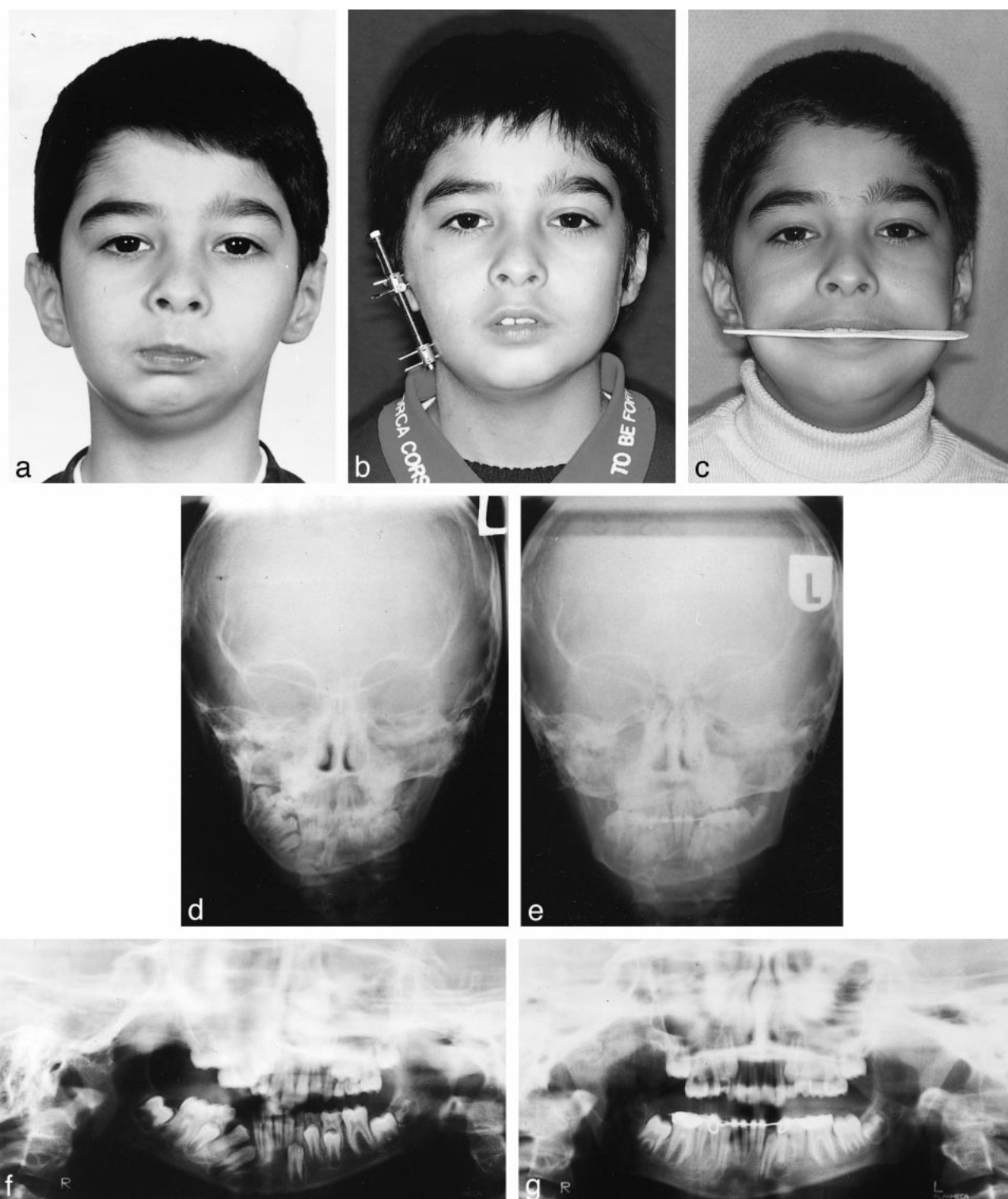


FIGURE 3. Case 3. (A) Initial facial photograph. (B) Frontal view after 22 mm of mandibular distraction. (C) Facial photograph 2 years following treatment. (D) Postero-anterior cephalometric radiograph before treatment. (E) Postero-anterior cephalometric radiograph 1 year after treatment. (F) Panoramic radiograph prior to treatment. (G) Panoramic radiograph 1 year after treatment.

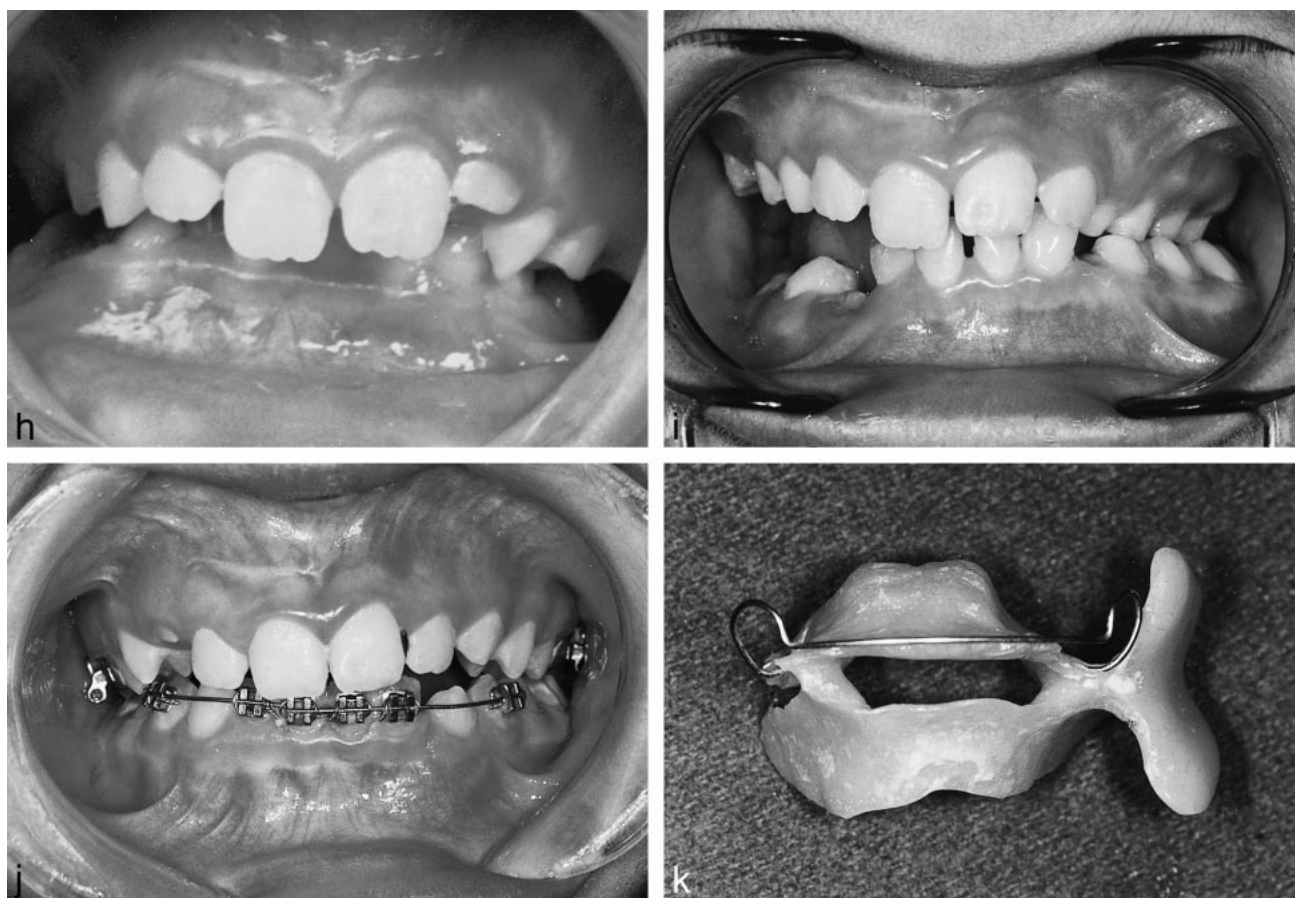


FIGURE 3. Continued. (H) Dental occlusion prior to treatment. (I) Dental occlusion after mandibular distraction. (J) Dental occlusion 2 years after treatment. (K) Functional appliance.

years after distraction osteogenesis and orthodontic treatment, the facial symmetry and dental occlusion were acceptable as shown on the dental casts and radiographs.

Case 3, Figure 3A-K

HA was a 10-year-old boy with idiopathic right side mandibular hypoplasia and a severe class II deep bite. A distractor was inserted for unilateral left side mandibular lengthening and 22 mm of distraction was performed followed by 3 months of retention. During this period, correction of the cant of occlusal plane was done. A hybrid functional appliance was used for correction of the cant of the occlusal plane.

Comparison of pretreatment and recent photographs and radiographs show a considerable increase in length of the affected mandibular body and correction of the occlusal plane cant and class II deep bite malocclusion. After 2.5 years, the face remained symmetric although the child was still growing.

Case 4, Figures 4A-L

FM, a 15-year-old girl, had unilateral ankylosis of the left temporomandibular joint. She underwent a costochon-

dral rib graft on the affected side when she was 10 years old but did not use her hybrid functional appliance during the growth period following her surgery. Her mandible was severely deviated to left. A distraction osteogenesis device was placed and a 21 mm lengthening procedure was performed. An upper Hawley with a screw for palatal expansion and a posterior bite plane were inserted and retained for 2 months. Fixed orthodontic mechanics were used to achieve acceptable occlusion. Her facial symmetry has remained 1.5 years later.

RESULTS

All patients achieved clinical lengthening of their skeletal deformities. In 1 patient with contralateral open bite prior to surgery, a tongue guard and orthodontic extrusive mechanics were used.

In the 15-year-old girl, extrusion of teeth on the affected side was slower. In all patients, radiographic examination showed the distraction sites were well-consolidated and the distraction devices were maintained fixed to the bone.

DISCUSSION

Reconstruction of the severely deficient mandible in younger children has been hampered by the need for cos-

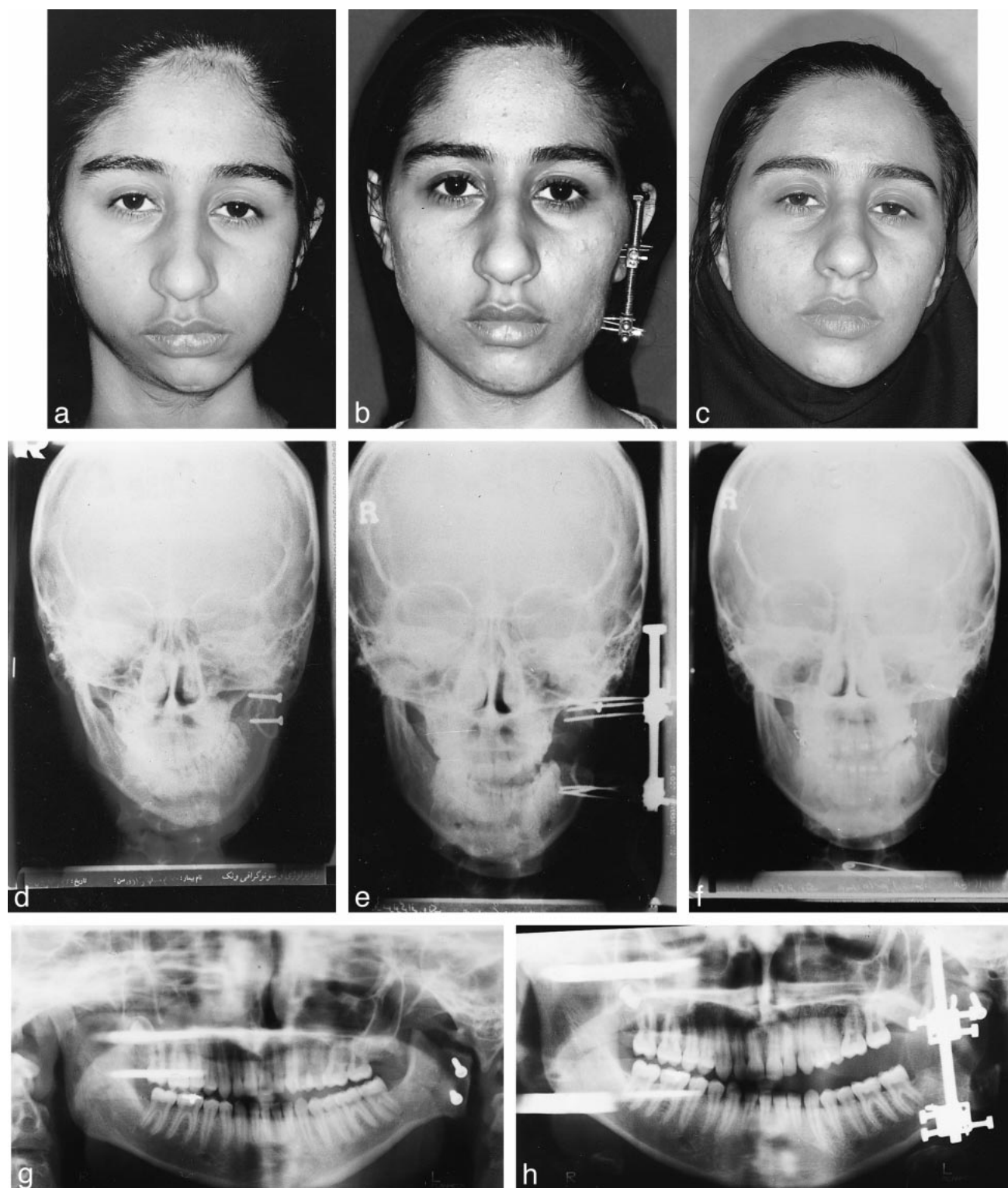


FIGURE 4. Case 4. (A) Facial photograph prior to treatment. (B) Facial photograph after 21 mm of mandibular distraction. (C) Facial photograph 1.5 years after treatment. (D) Postero-Anterior cephalometric radiograph before treatment. (E) Postero-anterior cephalometric radiograph after mandibular distraction. (F) Postero-anterior cephalometric radiograph 6 months after treatment. (G) Initial panoramic radiograph. (H) Panoramic radiograph with distraction in place.

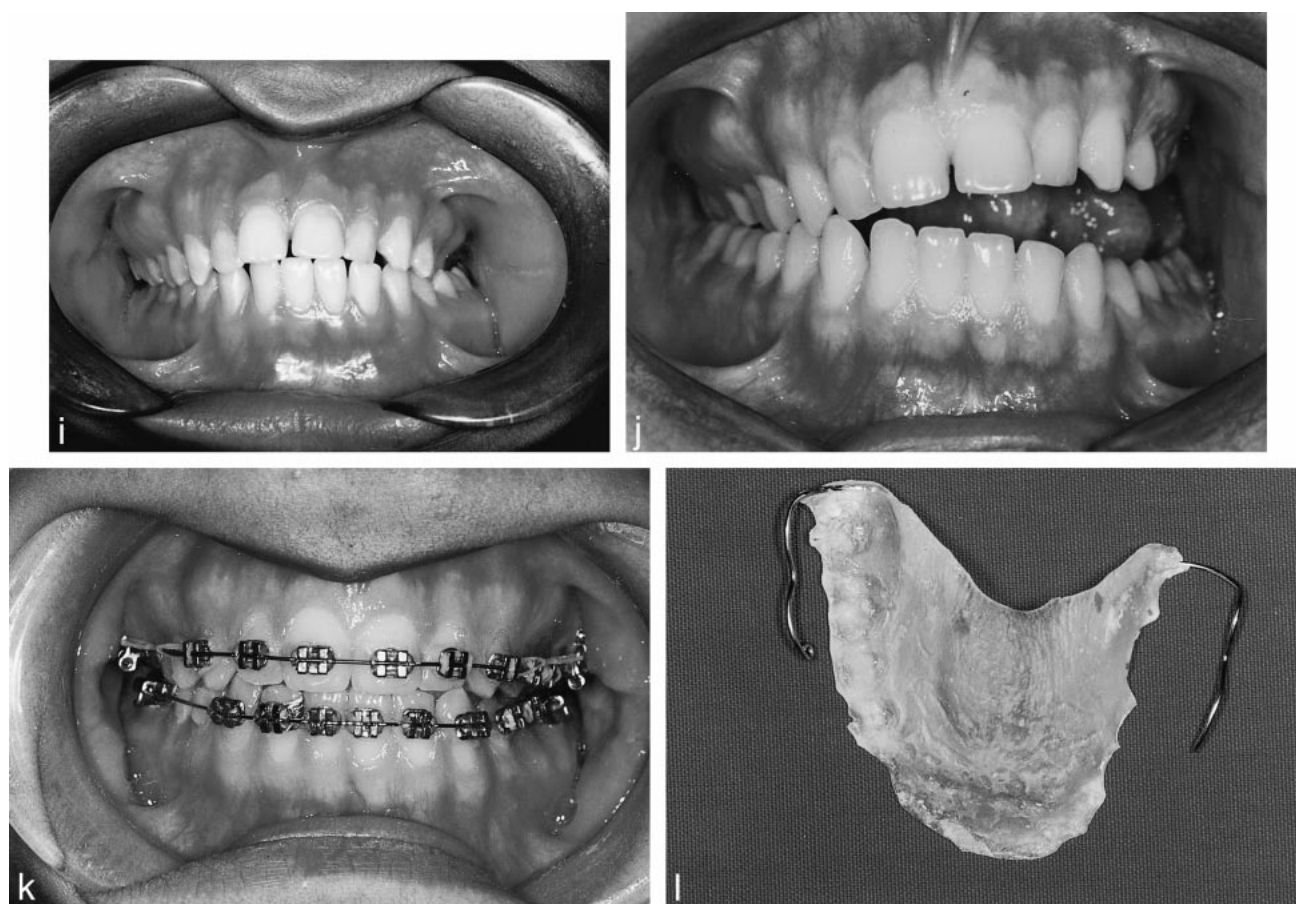


FIGURE 4. Continued. (I) Dental occlusion before treatment. (J) Dental occlusion after distraction osteogenesis. (K) Dental occlusion 1.5 years after treatment. (L) Unilateral postbite plate.

tochondral bone grafts.²⁴ One of the drawbacks of a costochondral bone graft is the unpredictability of its growth, producing excessive mandibular length in some cases, inadequate growth in others, and no growth at all in some.²⁵ Other complications include infection or resorption and the potential for donor site morbidity, scarring, mild chest wall contour defects, and postoperative pain.²⁴

Bone lengthening has become an accepted technique in the management of congenital deficiencies and post-traumatic deformities (nonunion and skeletal defects).

One source of concern at the initiation of the clinical trial was the effect of the corticotomy on the inferior alveolar nerve. All 4 patients presented intact nerve function at the post-surgical clinical examination.

An external distractor requires an incision for insertion, and active distraction leaves a scar. The scars in these 4 patients have resolved satisfactorily and no cosmetic revisions have been necessary.

Another concern was the potential for relapse of the lengthened mandible. Treatment was evaluated by clinical and dental examinations, photographs, dental models, and radiographs. When the desired mandibular length had been obtained, all patients had hybrid functional appliances in-

serted to guide proper occlusion and extrusion of teeth and to oppose any forces of relapse. To date, the longest follow-up period is 3.5 years, and the distraction increment has been maintained.

In the growing child, a question remains as to the potential of the lengthened mandible for further growth and development. It is postulated that craniofacial skeletal development is influenced by the functional matrix, that is, the sum of the functions of the attached neuromuscular envelope and the needs of the associated visceral spaces.¹⁹ Enlow¹⁹ demonstrated that mandibular growth is dependent on the development of the muscles of mastication and the erupting dentition and is characterized by bony apposition on the posterior aspect of the ramus and resorption on the anterior aspect. Ilizarov²⁶ reported associated lengthening of the attached muscles and nerves after gradual distraction of the long bones of the extremities. It can be speculated that gradual lengthening of the mandible, performed at an early age, can result in lengthening not only of the jaw but also of the attached muscles of mastication and soft tissues.

Hybrid functional appliances can be used to continue the process in order to improve neuromuscular function. This treatment protocol (gradual distraction plus functional or-

thodontic therapy) enhances facial symmetry and minimizes relapse. Long-term evaluation of a large number of patients will be necessary to evaluate the efficacy of this treatment protocol.

REFERENCES

1. Lauritzen C, Munro IR, Ross RB. Classification and treatment of hemifacial microsomia. *Scand J Plast Reconstr Surg.* 1985;19:33–39.
2. Murray JE, Mulliken JB, Kaban LB, Belfer M. Twenty-year experience in maxillocraniofacial surgery. An evaluation of early surgery and growth, function and body image. *Ann Surg.* 1979;190:320–331.
3. Pruzansky S. Not all dwarfed mandibles are alike. *Birth Defects.* 1969;1:120.
4. Molina F, Monasterio FO. Mandibular elongation and remodeling by distraction: a farewell to major osteotomies. *Plast Reconstr Surg.* 1995;96:825–840.
5. Proffit WR, White RP. *Surgical Orthodontic Treatment.* St. Louis, Mo: Mosby; 1991:142168,483–502.
6. Vig KWL, Burd AR. *Craniofacial Morphogenesis and Dysmorphogenesis* Ann Arbor, Mich: University of Michigan Center for Human Growth and Development; 1988:149–186.
7. Epker BN, Fish LC. *Dentofacial deformities. Integrated Orthodontic and Surgical Correction.* St. Louis, Mo: Mosby; 1986:949–1041.
8. Ilizarov GA. The tension-stress effect on the genesis and growth of tissues: Part I. part 1. The influence of stability of fixation and soft tissue preservation. *Clin Orthop.* 1989;238:249–281.
9. Ilizarov GA. The tension-stress effect on the genesis and growth of tissues: Part II. The influence of the rate and frequency of distraction. *Clin Orthop.* 1989;239:263–285.
10. Synder CC, Levine GA, Swanson HM, Browne EZ Jr. Mandibular lengthening by gradual distraction. Preliminary report. *Plast Reconstr Surg.* 1973;51:506–508.
11. Sawaki Y, Ohkubo H, Hibi H, Ueda M. Mandibular lengthening by distraction osteogenesis using osseointegrated implants and an intraoral device: a preliminary report. *J Oral Maxillofac Surg.* 1996;54:594–600.
12. Michieli S, Miotti B. Lengthening of mandibular body by gradual surgical-orthodontic distraction. *J Oral Surg.* 1977;35:187–192.
13. Costantino PD, Shybut G, Friedman CD, et al. Segmental mandibular regeneration by distraction osteogenesis. An experimental study. *Arch Otolaryngol Head Neck Surg.* 1990;116:535–545.
14. Karaharju-Suvanto T, Karaharju EO, Ranta R. Mandibular distraction. An experimental study in sheep. *J Craniomaxillofac Surg.* 1990;18:280–283.
15. Karp NS, Thorne CH, McCarthy JG, Sissons HA. Bone lengthening in the craniofacial skeleton. *Ann Plast Surg.* 1990;24:231–237.
16. Block MS, Daire J, Stover J, Matthews M. Changes in the inferior alveolar nerve following mandibular lengthening in the dog using distraction osteogenesis. *J Oral Maxillofac Surg.* 1993;51:652–660.
17. Annino DJ Jr, Goguen LA, Karmody CS. Distraction osteogenesis for reconstruction of mandibular symphyseal defects. *Arch Otolaryngol Head Neck Surg.* 1994;120:911–916.
18. Califano L, Cortese A, Zupi A, Tajana G. Mandibular lengthening by external distraction: an experimental study in the rabbit. *J Oral Maxillofac Surg.* 1994;52:1179–1183.
19. McCarthy JG, Schreiber J, Karp N, Thorne CH, Grayson BH. Lengthening the human mandible by gradual distraction. *Plast Reconstr Surg.* 1992;89:1–8.
20. Drew SJ, Schwartz MH, Sachs SA. Distraction osteogenesis. *N Y State Dent J.* 1999;65:26–29.
21. Carls FR, Sailer HF. Seven years clinical experience with mandibular distraction in children. *J Craniomaxillofac Surg.* 1998;26:197–208.
22. Meyer U, Wiesmann HP, Kruse-Losler B, Handschel J, Stratmann U, Joos U. Strain-related bone remodeling in distraction osteogenesis of the mandible. *Plast Reconstr Surg.* 1999;103:800–807.
23. Diner PA, Kollar EM, Vazquez MP. Mandibular distraction. *Ann Chir Plast Esthet.* 1997;42:547–555.
24. Kaban LB, Moses MH, Mulliken JB. Surgical correction of hemifacial microsomia in the growing child. *Plast Reconstr Surg.* 1998;82:9–19.
25. Behina H, Kalantar Motamedi MH, Tehrani A. Use of activator appliances in pediatric patients treated with costochondral grafts for temporomandibular joint ankylosis: analysis of 13 cases. *J Oral Maxillofac Surg.* 1997;55:1408–1414.
26. Ilizarov GA. Presentation at the Annual Meeting of American Society of Plastic and Reconstructive Surgeons; October 1990; Boston, Mass.