

Orthopedic Cervical Headgear with an Expanded Inner Bow in Class II Correction

Mirja Kirjavainen, DDS^a; Turkka Kirjavainen, MD, DScMed^b; Kirsti Hurmerinta, DDS, PhD^c; Kaarina Haavikko, DDS, PhD^d

Abstract: Forty consecutively referred children, 20 boys and 20 girls, with a Class II division 1 malocclusion and protrusive maxilla were treated with orthopedic cervical headgear with a 10 mm expanded inner bow and a long outer bow bent 15° upwards. The mean age of the children at the beginning of treatment was 9.3 years (SD 1.3, range 6.6 to 12.4 years), and the average treatment time was 1.8 years (SD 0.6, range 0.8 to 3.1 years). In all patients Class II molar relationships were successfully corrected to Class I molar relationships. This was accompanied by a marked widening of both maxillary and mandibular dental arches. The cephalometric analysis suggested that the observed improvement of the occlusion was due to an inhibition of forward growth of the maxilla and anterior downward rotation of the palate. (*Angle Orthod* 2000;70:317–325.)

Key Words: Class II division 1 correction; Orthopedic cervical pull; Cephalometry

INTRODUCTION

Cervical headgear traction is widely used in Finland for the correction of Class II division 1 malocclusion because it is easy to produce, simple to use, and well accepted by the children. The principle of orthopedic headgear treatment is to restrict forward growth of the maxilla by applying forces on the maxillary first molars. Cervical headgear therapy has been extensively studied for the last 50 years; however, treatment results have varied greatly.¹ This may be explained by the use of different modifications of the headgear treatment.^{2–9} The direction and the force of traction has varied greatly, and high-pull, straight-pull, cervical-pull headgears, or combinations with different forces have been used.^{2,3,5,10} Forces from 150 to 200 g may be used to move teeth,^{2,3,11} while forces over 450 g are assumed to surpass the tooth-moving threshold and be used to control dental anchorage.^{2,3,11,12} Strong forces are needed to produce or-

thopedic skeletal effects on the maxilla, which are essential in the treatment of Class II malocclusion.^{12–20}

The structure of the inner and outer bow has varied. The inner bow may be used with or without expansion,^{21,22} and it may or may not bear on the upper incisors. Bayonets have been used along the vertical or horizontal plane. The length of outer bow and its angle against inner bow has also varied.^{2,3} Furthermore, in many studies headgear therapy has not been used alone, but with fixed or functional appliances,^{23,24} with or without tooth extractions.^{4,5,25} The age at the onset of treatment has also been suggested to be a critical factor.²⁶ The headgear has been used either intermittently or continuously.^{20,27} Therefore, it is difficult to compare different results of the headgear therapy, and it is important to recognize what kind of headgear therapy is studied. In addition, the malocclusion itself may result from various maxillary and mandibular skeletal and dental relationships.^{28–32} This heterogeneity of Class II malocclusion probably adds some variability to the results.

Recent findings suggest that Class II malocclusion is related to a narrow maxilla. This narrow maxilla is seen even in children younger than 6 years of age.³³ To achieve a permanent skeletal correction of the malocclusion and prevention of the protrusive growth, the widening of this narrow maxilla seems to be essential.¹⁹ In a previous study,³⁴ this widening was achieved by using headgear alone without any other appliances, when the headgear was used with a widened inner bow as suggested by Ricketts and coworkers.²² The claimed side-effects of the treatment, distal tipping and extrusion of the first molars in excess of normal eruption, may be avoided by using a face bow with a long and rigid outer bow that has been bent upwards.^{21,35–37}

^a Orthodontist, Department of Pedodontics and Orthodontics, University of Helsinki, Finland.

^b Registrar, Departments of Pediatrics, Universities of Helsinki and Turku, Finland.

^c Senior Orthodontist, Department of Pedodontics and Orthodontics, University of Helsinki, Finland.

^d Emeritus professor, Department of Pedodontics and Orthodontics, University of Helsinki, Finland.

Corresponding author: Dr Mirja Kirjavainen, Venhontie 7, FIN-31300 Tammela, Finland
(e-mail: mirja.kirjavainen@lthtt.fi)

Accepted: May 2000. Submitted: January 2000.

© 2000 by The EH Angle Education and Research Foundation, Inc.

The purpose of the present study was: (1) to evaluate the skeletal and dental effects of orthopedic cervical headgear used with an 10 mm expanded inner bow and a long outer bow bent 15° upwards on Class II division 1 malocclusion in growing children; and (2) to study whether the claimed side-effects of the cervical headgear therapy (ie, extrusion of molars and downwards and backwards rotation of the mandible) could be avoided.

MATERIALS AND METHODS

Patients

Forty consecutively treated, otherwise healthy school-children, 20 boys and 20 girls, were included in the present study. They all were referred for treatment of Class II division 1 malocclusions. They fulfilled the following criteria: (1) they had Class II molar relationship with an overjet more than 2 mm, (2) they had an A-point in the front of the N-Pg-Line, (3) they had pre- and post-treatment plaster models and lateral cephalograms, (4) they were between 6–13 years of age at the date of referral, (5) they were otherwise healthy, (6) all essential measuring points for plaster models were identified,³⁴ and (7) their cooperation was likely to be good or at least moderate. Facial height was not included in the selection criteria. Some individuals had crowding of the teeth.

The patients were treated with the orthopedic cervical headgear without any other appliances by one of the authors (M.K.) in the healthcare center at Forssa. The mean age of the boys at the beginning of treatment was 9.8 years (SD 1.2, range 7.2 to 12.4 years) and of the girls 8.9 years (SD 1.2, range 6.6 to 11.2 years). Hence, boys were somewhat older than girls ($P < .05$). All patients, except 1 boy, were in the mixed dentition stage. The average number of control visits for the boys was 8.4 (SD 1.4, range 6.3 to 11.1) per year and for the girls 8.7 (SD 1.5, range 5.0 to 11.1) per year. The difference between genders was not significant. Thirteen boys and 17 girls had good cooperation, and 7 boys and 3 girls moderate cooperation.

In the present study 3 different control populations were used. All measurements were compared to a Finnish cohort³⁸ which consisted of 385 boys and 333 girls between 6 and 15 years of age. The material was collected between the years 1965 to 1968. The children aged 7 to 14 years were the pupils of the Kaisaniemi and Aleksis Kivi elementary schools of Helsinki, Finland. The angle values were also compared to a British cohort study by Bhatia and Leighton.³⁹ The eruption values of the upper and lower first molars were compared to the normal values presented by Riolo and associates.⁴⁰

Methods

A Kloehe-type cervical headgear with a large inner bow and long outer bow was used to treat the Class II division

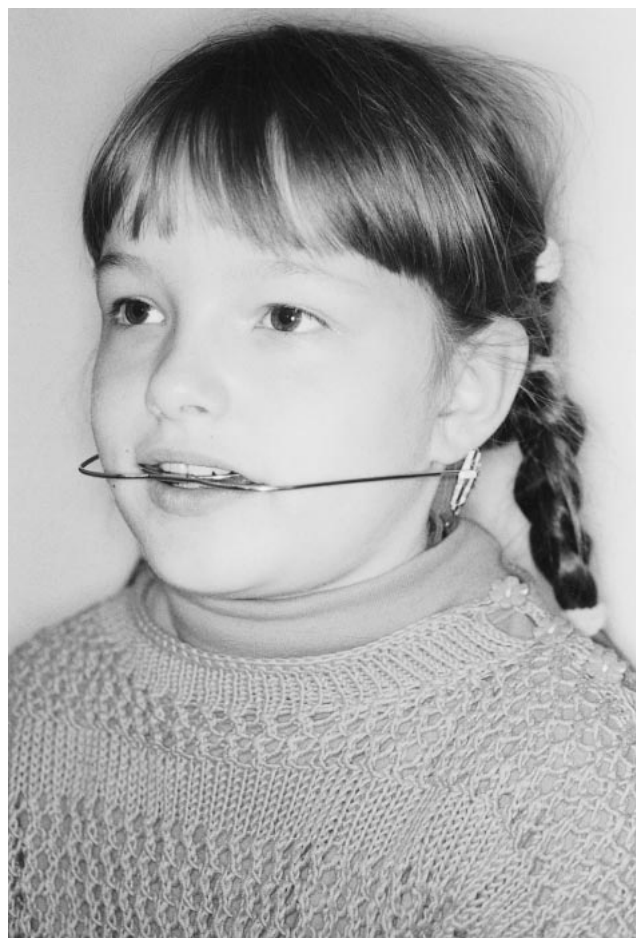

FIGURE 1. Cervical headgear used to treat Class II division 1 malocclusion in this study. The headgear had a long, rigid outer bow bent 15° upwards which reached to the ala of the ear.

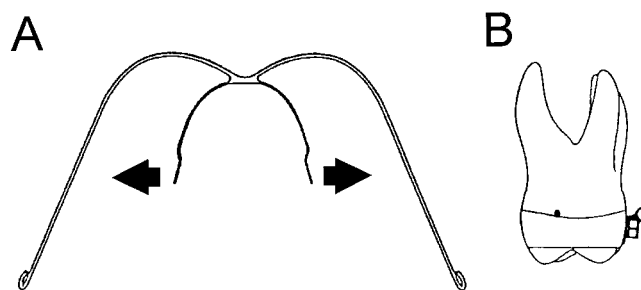


FIGURE 2. Cervical headgear and the placement of the molar tube. The inner bow was expanded 10 mm larger than the distance between the first maxillary molar tubes and was made parallel to the occlusal plane. The arrows indicate the expansion of the inner bow.

1 malocclusions in all patients (Figures 1 and 2). The 4 mm horizontal bayonets were bent to the inner bow to keep teeth out of contact with cheeks or lips. The inner bow was engaged so that the distance between the bow and the anterior teeth was 3 mm. The ends of the inner bow were bent inwards to prevent the rotation of the first molars mesio-palatally or to rotate the first molars into their correct po-

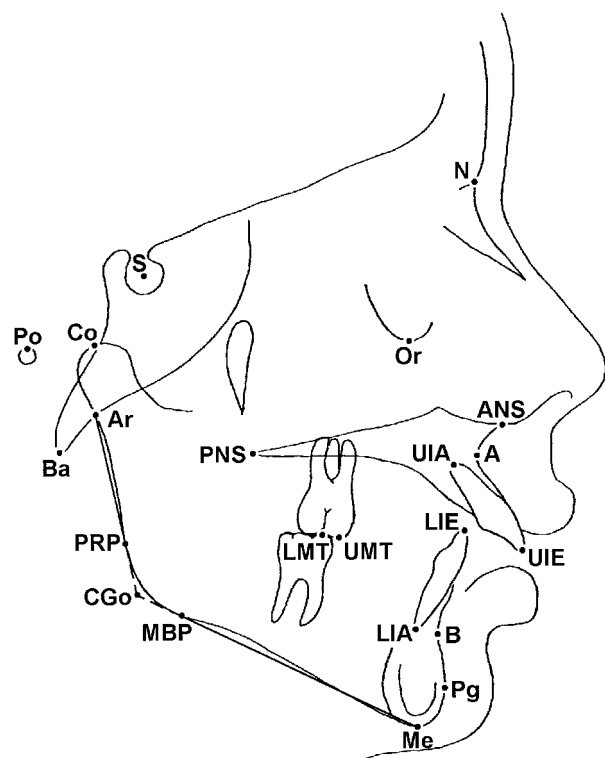


FIGURE 3. The 22 hard tissue cephalometric landmarks used: N (Nasion), S (Sella), Or (Orbitale), Po (Porion), Co (Condylion), Ar (Articulare), Ba (Basion), PRP (Posterior Ramus Point), CGo (Constructed Gonion), MBP (Mandibular Base Point), Me (Menton), Pg (Pogonion), B (B point), A (A point), ANS (Anterior Nasal Spine), PNS (Posterior Nasal Spine), UIE (Upper Incisor Edge), UIA (Upper Incisor Apex), LIE (Lower Incisor Edge), LIA (Lower Incisor Apex), UMT (Upper first Molar mesial cusp Tip), LMT (Lower Molar mesial cusp Tip).

sition. The inner bow of the headgear was expanded 10 mm larger than the distance between the maxillary first molar tubes and made parallel to the occlusal plane. To prevent distal tipping of the first molar crowns and extrusion of the first molars over the amount of the normal eruption, the long rigid outer bow was bent 15° upwards. To prevent buccal and distal tipping of the first molar crowns, the molar tubes were placed as close to the gingival margin and the rotation center of the first molars as possible.⁴¹ In the attachment of the headgear to teeth, triple tubes were used, and the upper and outermost tube was used for the attachment.

A force of 500 g per side was used for cervical traction. The force was measured with a force gauge. The expansion of the inner bow and the amount of force used were controlled at 6–8 week intervals. The patients were asked to wear the headgear 12 to 14 hours a day, in the evenings and at nights, and to keep a daily diary of their headgear wear. Cooperation was estimated according to the diary notes and the signs of use, including the tearing of the elastic band and the neck strap. The treatment was finished when correction of the Class II molar relationship to the

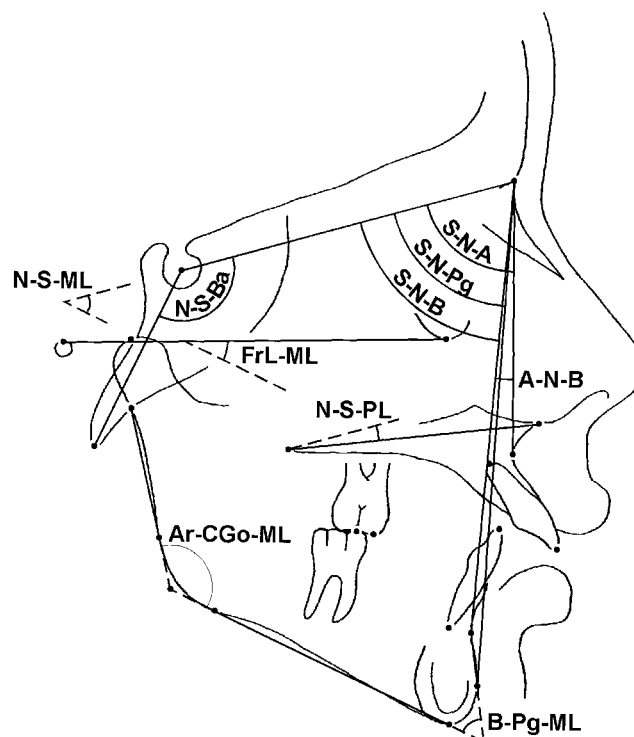


FIGURE 4. The skeletal angles used: N-S-Ba (Nasion-Sella-Basion), S-N-A (Sella-Nasion-point A), N-S-PL (Nasion-Sella-Palatal line), S-N-B (Sella-Nasion-B point), S-N-Pg (Sella-Nasion-Pogonion), N-S-ML (Nasion-Sella-Mandibular line), FrL-ML (Frankfort line-Mandibular line), Ar-CGo-ML (Articulare-Constructed Gonion-Mandibular line), B-Pg-ML (point B-Pogonion-Mandibular line), A-N-B (A point-Nasion-point B).

Class I molar relationship was achieved regardless of the amount of possible horizontal overjet. Standardized lateral cephalometric radiographs were taken in a cephalostat (Cranex dc 2 ceph, Soredex Orion Co LTD, Helsinki, Finland) before and after treatment.

Analysis of lateral radiographs

Landmarks in the cephalometric radiographs were digitized by one of the authors (M.K.). The bilateral structures were bisected. The linear measurements and angles were calculated by computer software designed for the study. The 22 hard tissue landmarks used are presented in Figure 3. These landmarks were identified according to the criteria described by Bhatia and Leighton.³⁹ The skeletal angles are presented in Figure 4, and the dental angles in Figure 5.

Measurement reproducibility

To assess measurement repeatability, serial measurements were taken in 5 randomly selected children. The average difference between the 2 measurements of angles (Table 1) was 0.34° (SD 0.24, range 0.01 – 0.93°), and 0.42 mm (SD 0.28, range 0.01 – 0.93 mm) for linear measurements. The measurements were free of systematic error.

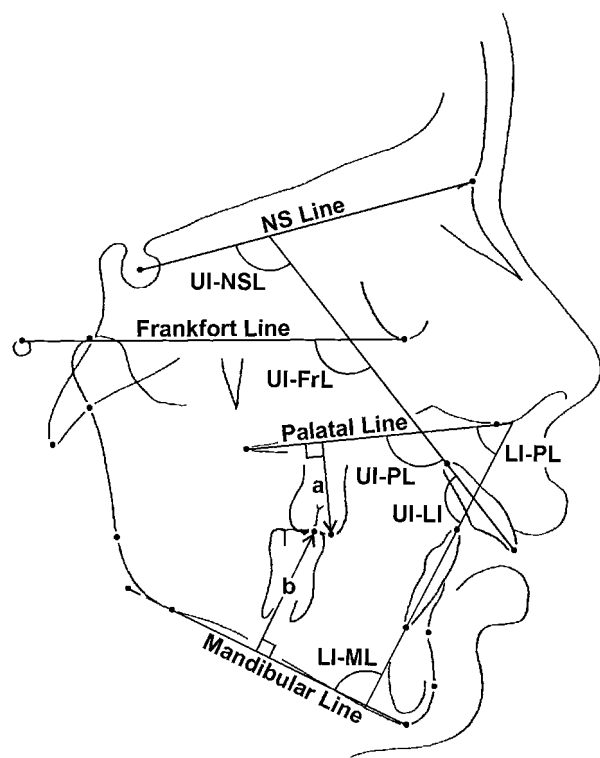


FIGURE 5. The dental angles and linear references used: UI-PL (UIE-UIA-Palatal line), UI-NSL (UIE-UIA-Nasion-Sella-line, NS-line), UI-FrL (UIE-UIA-Frankfort line, Po-Or), LI-ML (LIE-LIA-Mandibular line, MBP-Me), LI-PL (LIA-LIE-Palatal line), UI-LI (UIA-UIE—LIE-LIA), a (perpendicular distance between UMT and Palatal line), b (perpendicular distance between LMT and Mandibular line).

Statistical methods

All the statistical analyzes were performed using SAS statistical software (SAS Institute Inc, Cary, NC, USA). Paired *t*-tests were used to compare pre- and post-treatment angles and linear measurements. The Student's *t*-test was used to compare differences between genders, and to compare values with the normal average values presented by Haavikko³⁸ (Figure 6), and Bhatia and Leighton.³⁹ The eruption values of the upper and lower first molars were compared to the normal values presented by Riolo and associates⁴⁰ using the Student's *t*-test. Correlations between variables were calculated by linear regression analyzes using the least squares method. Multiple linear regression modeling provided by the SAS software was used to further estimate the effects of starting age and treatment time on results, and effects of changes in S-N-A and S-N-B angles on A-N-B angles. *P*-values <.05 were considered statistically significant.

RESULTS

In all patients, the Class II division 1 malocclusions were successfully corrected to a Class I molar relationship. The mean duration of the treatment was 1.9 years (SD 0.7, range

0.9 to 3.1 years) in boys and 1.8 years (SD 0.7, range 0.8 to 3.0 years) in girls. The age at the beginning of treatment did not affect the treatment time ($r^2 = 0.03$ ns). Concurrent with the correction of the Class II malocclusion, the maxillary dental arch was widened with simultaneous spontaneous widening of the mandibular dental arch. Additionally, tooth alignment improved and dental crowding disappeared.³⁴

The treatment did not have significant effect on overbite. Twelve boys and 13 girls had a normal vertical overbite before treatment and this remained unchanged during the treatment. Of the remaining 15 children, 7 boys and 5 girls had deep overbite before the treatment. The bite became normal in 3 of these boys and 4 of these girls after treatment. The deep overbite remained unchanged in 4 boys and 1 girl. Three children had an edge-to-edge overbite before the treatment. In 2 of these children, a normal overbite was achieved with treatment and 1 remained unchanged. Overjet decreased markedly in both genders ($P < .001$) during the treatment, on average from 6.4 mm (SD 2.0, range 4–11 mm) to 4.2 mm (SD 1.4, range 2–8 mm) in boys and from 5.3 mm (SD 2.3, range 3–11 mm) to 3.2 mm (SD 1.3, range 2–7 mm) in girls.

The most important treatment effects are presented in Figures 6 and 7. The results in Figure 6 are presented against the normal values.³⁸ Figure 7 shows the individual changes. All measured pre- and post-treatment angle values are presented in Table 1. There were no significant differences between boys and girls in the effects of treatment on any of the measured variables.

Changes in the maxilla

Before treatment, the maxilla was in a protrusive position in both genders. Girls had 1.7° wider S-N-A angles than Finnish controls ($P < .05$) before the treatment. Boys also had tendency for 1.9° wider S-N-A angles than controls, but this did not reach statistical significance ($P < .1$). However, both boys ($P < .01$) and girls ($P < .001$) had wider S-N-A angles when compared to the British average normal reference values.³⁹ The treatment had its major effects on this prognathism. This was seen as an average decrease in the S-N-A angle during the treatment period of 1.7° (SD 1.4, range 0.8° – 4.9°, $P < .0001$) in boys and by 2.1° (SD 1.6, range 0.7° – 6.2°, $P < .0001$) in girls (Figures 6 and 7). After the treatment, the S-N-A angles were similar to the average normal values.^{38,39}

The palatal plane in our patients was inclined anteriorly and upwards before the treatment (Figure 6). This is indicated by 1.0° smaller N-S-PL angles in girls compared to the Finnish controls. Again, boys had a tendency for 1.0° smaller N-S-PL angles than Finnish controls, but this did not reach statistical significance ($P < .1$). Both boys ($P < .05$) and girls ($P < .01$) had smaller N-S-PL angles than the normal British reference values.³⁹ During treatment, the

TABLE 1. Pre- and Post-Treatment Values and Changes in Skeletal and Dental Angles in Degrees

	Boys						Girls					
	Pre-Treatment		Post-Treatment		Change	SD	Pre-Treatment		Post-Treatment		Change	SD
	Mean	SD	Mean	SD			Mean	SD	Mean	SD		
Cranial base												
N-S-Ba	132.8	3.9	132.3	3.7	−0.5	2.7	133.0	5.1	133.0	5.1	0.0	1.9
Maxilla												
S-N-A	82.4	3.5	80.8	3.8	−1.7 ^c	1.4	82.1 ^{ba}	3.0	80.0	3.2	−2.1 ^c	1.6
N-S-PL	5.3	2.5	6.6	2.7	1.4 ^c	1.5	5.9 ^{la}	2.2	7.8	2.6	1.9 ^c	1.5
Mandible												
S-N-B	77.3	2.9	78.1	3.4	0.8 ^a	1.3	76.6	3.1	77.3	3.3	0.7 ^a	1.2
S-N-Pg	77.8	3.0	78.7	3.5	0.8 ^b	1.2	77.0	3.3	77.7	3.5	0.8 ^b	1.1
N-S-ML	31.7	6.0	31.5	6.7	−0.2	1.5	32.5 ^{la}	4.4	32.1	5.1	−0.4	1.4
FrL-ML	25.3	6.1	24.3	5.6	−1.0 ^a	2.1	24.6	3.9	24.6	4.6	0.0	1.9
Ar-CGo-ML	126.5	7.9	125.7	8.5	−0.8	2.5	124.9 ^{la}	5.5	123.7 ^{lb}	6.0	−1.2 ^a	1.9
B-Pg-ML	65.8	5.5	65.1	5.2	−0.6	3.2	67.1	6.1	66.6	6.0	−0.5	2.9
Maxilla and Mandible												
A-N-B	5.1 ^{bc}	1.7	2.9	1.5	−2.2 ^c	1.4	5.5 ^{bc}	1.8	2.7	1.8	−2.8 ^c	1.3
Dentition												
UI-PL	111.6	6.6	113.5 ^{ba}	7.4	1.9	5.8	110.0	6.6	115 ^{ab}	5.2	5.0 ^b	6.0
UI-NSL	106.3 ^{ba}	7.7	106.8	8.6	0.5	5.5	104.1	6.6	107.2	5.9	3.2 ^a	6.1
UI-FrL	112.8	6.7	114.1	7.0	1.3	6.1	111.9	6.1	114.7	5.6	2.8 ^a	5.8
LI-ML	98.5	7.9	98.9	7.0	0.4	5.2	99.9	6.2	99.9 ^{ab}	5.8	0.0	3.7
LI-PL	55.3	6.6	56.4	5.1	1.2	5.0	53.7 ^{la}	5.8	55.8	7.0	2.1	4.6
UI-LI	124.5	11.9	124.2	12.1	−0.3	8.1	124.6	11.2	121.1 ^{la}	8.9	−3.5	8.8

^a $P < .05$; ^b $P < .01$; ^c $P < .001$

Superscript at the end of a number indicates if the value is larger (^a) or smaller (^b) than the normal mean³⁸ or if the treatment has changed the angle significantly.

N-S-PL angle increased significantly ($P < .001$). Hence the palatal plane was rotated downwards to a more horizontal position, and closer to the normal reference values (Figure 6).^{38,39}

Changes in the mandible

Although the treatment was directed exclusively to the maxilla, significant changes were also observed in the growth of the mandible. The mandible was close to a neutral skeletal position before treatment (Table 1). The S-N-B, S-N-Pg, B-Pg-ML^{38,39} and Fr-ML³⁹ angles were all similar to normal average values both before and after treatment in both genders. The girls had smaller N-S-ML values and Ar-CGo-ML angles than the normal Finnish values³⁸ before treatment ($P < .05$). After treatment, the N-S-ML angles were similar to the normal average reference values in both genders (Figure 6), but Ar-CGo-ML remained smaller in girls than in Finnish controls,³⁸ but values did not differ from the British normal average.³⁹

The mandible grew forward to some extent during the treatment. The S-N-B angle increased by 0.8° (SD 1.3, range −1.2–4.1°, $P < .05$) in boys and by 0.7° (SD 1.2, range −1.1–4.3°, $P < .05$) in girls (Figures 6 and 7). The S-N-Pg angle increased by 0.8° (SD 1.2, range −1.0–3.8°,

$P < .01$) in boys and 0.8° (SD 1.1, range −0.7–3.7°, $P < .01$) in girls during the treatment period.

Skeletal anteroposterior facial relationship

The pretreatment A-N-B angles were larger than normal average values^{38,39} in both genders ($P < .001$), but were significantly decreased toward the normal values during the treatment period, by 2.2° (SD 1.4, range 0.6–6.1°, $P < .0001$) in boys and 2.7° (SD 1.3, range −0.1–5.2°, $P < .0001$) in girls. The post-treatment angles were similar to the average normal values.^{38,39} As expected, the decrease in A-N-B angles correlated to the decrease in S-N-A angles ($r^2 = 0.24$, $P < .01$) and increase in S-N-B angles ($r^2 = 0.14$, $P < .05$). Using multiple regression modeling (model $r^2 = 0.84$, $P < .0001$), both the changes in S-N-A ($P < .0001$) and S-N-B angles ($P < .0001$) were found to explain the changes in the A-N-B angles.

Effect of starting age and treatment time

S-N-A angles decreased somewhat more the earlier the treatment was started ($r^2 = 0.14$, $P < .05$) and the longer the treatment lasted ($r^2 = 0.12$, $P < .05$). However, when the starting age and treatment time were used in multiple regression modeling (model $r^2 = 0.22$, $P = .01$); S-N-A

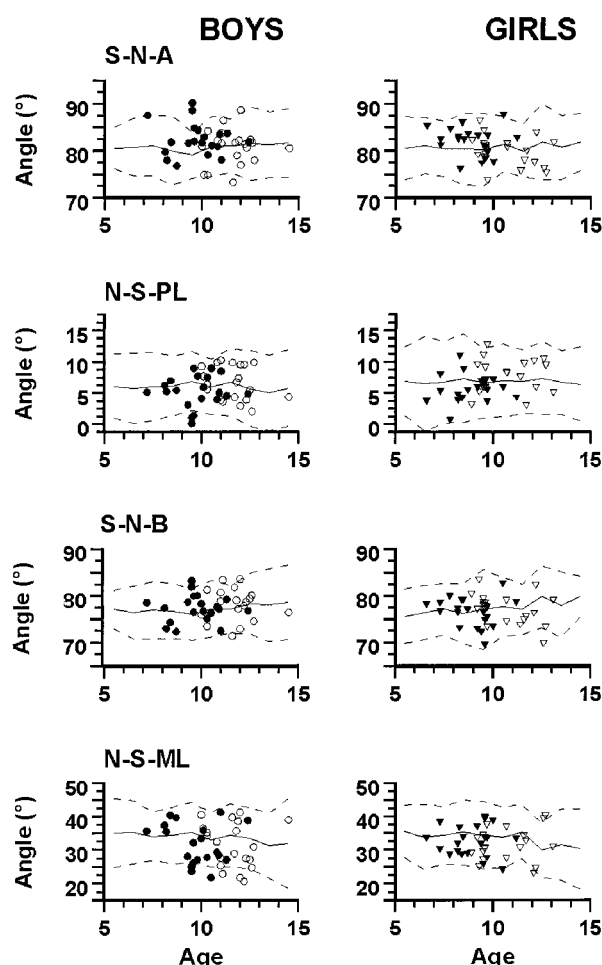


FIGURE 6. Pre- and post-treatment angles in boys (●) and girls (▼) plotted against the normal Finnish average reference values³⁸ and SD values. Pretreatment values are presented as solid points, post-treatment values as open points, normal average as solid lines, and 2SD values as dashed lines. The pretreatment S-N-A angles were larger ($P < .01$) and the N-S-PL angles smaller ($P < .05$) than the normal average. After the treatment, the angles did not differ significantly from the normal average values.

angles were observed to decrease more the earlier the treatment was started ($P = .037$), but the treatment time did not further explain the changes in S-N-A ($P = .053$). Concurrently with the S-N-A angles, N-S-PL angles increased ($r^2 = 0.17$, $P < .01$), and A-N-B angles decreased slightly more ($r^2 = 0.12$, $P < .05$) the earlier the treatment was started. However, treatment time did not correlate to the changes of these angles. Starting age did not correlate with the changes in S-N-B nor N-S-ML angles, but a somewhat smaller amount of increase of S-N-B angles was observed in patients who had longer treatment times ($r^2 = 0.11$, $P < .05$).

Changes in the cranial base measurements

In comparison to Finnish controls, both boys and girls had longer anterior cranial base lengths (N-S) both before

and after the treatment ($P < .01$).³⁸ However, when compared to the British normal average in boys, N-S and cranial base growth rates both before and after treatment were similar to the normal average.³⁹ However, while the girls had longer N-S lengths than the normal average ($P < .01$) before treatment, in spite of a normal growth rate, the post-treatment lengths were similar to the normal average.^{38,39}

The growth and size of the posterior cranial base length (S-Ba) were similar to the normal controls^{38,39} in both genders before and after the treatment, except that girls had longer S-Ba when compared to the Finnish controls ($P < .01$). The N-S-Ba angles were similar to controls both before and after the treatment,^{38,39} but when compared to the British normal values, boys had wider angles than the normal British average both before ($P < .01$) and after ($P < .02$) treatment, without any significant treatment effect.³⁹

Facial heights

The total anterior facial height (N-Me) of these children was similar to the normal British average³⁹ both pre- and post-treatment. However, when compared to the Finnish controls,³⁸ boys had longer N-Me values after the treatment and girls both pre- and post-treatment. The rate of growth was significantly greater than the normal British average in both boys ($P < .01$) and girls ($P < .05$). This increased growth was observed especially in the upper anterior facial height (N-ANS) as the N-ANS/ANS-Me ratio was increased from 0.75 mm (SD 0.06, range 0.66–0.91 mm) to 0.79 mm (SD 0.07, range 0.67–0.94 mm, $P < .01$) in boys, and from 0.77 mm (SD 0.05 mm, range 0.69–0.87 mm) to 0.82 mm (SD 0.06, range 0.75–0.93 mm, $P < .001$) in girls during the treatment period. Compared to the Finnish controls, both boys ($P < .01$) and girls ($P < .001$) had a smaller N-ANS/ANS-Me relationship before the treatment, but the relationship did not differ from control values after the treatment.

Changes in the maxillary and mandibular molars and incisors

The treatment caused only minor extrusion of the upper first molars when compared to the Finnish controls:³⁸ on average 1.3 mm (SD 2.1, range –2.5–4.6 mm) in boys and 1.2 mm (SD 1.4, range –3.4–3.9 mm) in girls. However, the observed eruption was similar to the normal US average.⁴⁰ The distance between the upper molar cusp tip and palatal line increased by 1.1 mm/year (SD 0.6, range –0.1–2.3 mm/year) in boys and 0.9 mm/year (SD 0.4, range 0.1–1.8 mm/year) in girls. The distance between the lower first molar cusp tip to the mandibular plane increased less than the normal British average³⁹ both in boys ($P < .01$) and girls ($P < .001$). The increase in boys was 1.2 mm/year (SD 0.6, range 0.4–2.4 mm/year), and 1.2 mm/year (SD 0.6, range 0.3–2.4 mm/year) in girls.

The incisors may have been somewhat facially inclined

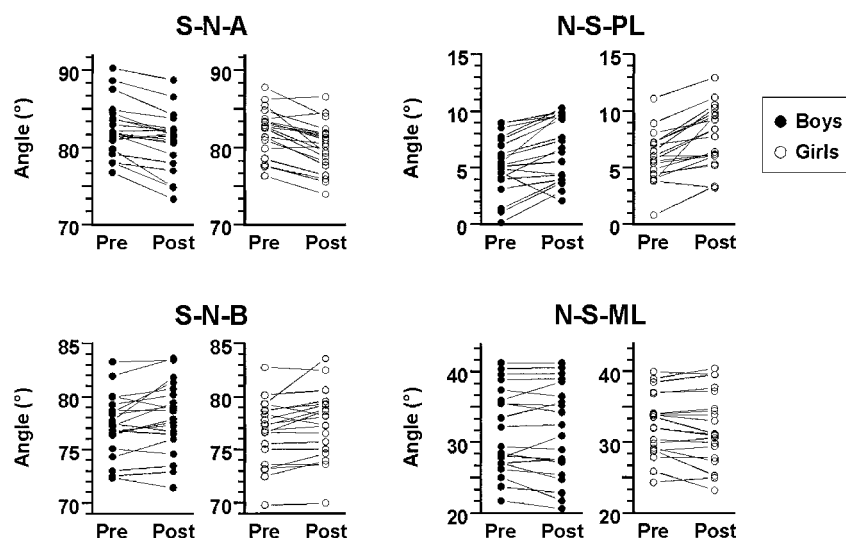


FIGURE 7. Individual pre- and post-treatment values of S-N-A, N-S-PL, S-N-B, and N-S-ML angles. The S-N-A angle was decreased ($P < .0001$), and N-S-PL ($P < .001$) and S-N-B angles ($P < .05$) were increased during the treatment period. There were no significant changes in the N-S-ML angle.

in these children. This was indicated by the smaller UI-LI angles ($P < .05$ in boys, and $P < .01$ in girls), and the wider UI-PL ($P < .01$) and LI-ML ($P < .001$) angles compared to the normal British average³⁹ both pre- and post-treatment. However, the girls had UI-PL angles similar to the normal average³⁹ before treatment. When compared to Finnish controls³⁸ the inclination of the teeth was not as obvious (Table 1). The treatment did not significantly affect these angles, except in girls, who had an increase in the UI-PL angle ($P < .01$).

DISCUSSION

In the present study, it has been shown that Class II malocclusions with a protrusive maxilla may be corrected to Class I molar relationships by using orthopedic cervical headgear as the only appliance, provided that an expanded inner bow and upwards-bent long outer bow are used. Concurrent to the correction of the malocclusion, both the maxillary and mandibular dental arches were significantly widened.³⁴ The cephalometric analyzes suggest that the observed improvement of the occlusion was achieved by inhibiting the forward growth of the maxilla, and by anterior and downwards rotation of the palate. The earlier the treatment was started, the slightly more pronounced effect it had on maxillary growth. The forward growth of the mandible followed the normal growth pattern and was not significantly affected by the treatment.

All patients had a protrusive maxilla at the beginning of the treatment. This was indicated by the large S-N-A and A-N-B angles. Without any treatment intervention, the S-N-A angle is expected to remain unchanged or even increase.^{16,42} However, in this study, the S-N-A angle decreased on average by 1.7° in boys and 2.1° in girls during

the treatment period. There was some tendency for the angle values to cluster toward the normal average (Figure 7). Before treatment, the patients had somewhat anteriorly upwards inclined palates. This was indicated by the small N-S-PL angles. According to Bench and coworkers,²¹ this anteriorly upwards inclined palatal plane may itself lead to maxillary protrusion. During treatment, the palatal plane was rotated anteriorly downwards toward a more horizontal position. This is likely to have an important impact on the improvement of the malocclusion. This result is in accordance with earlier observations.⁴³ The S-N-A and the N-S-PL angles changed together toward a more favorable position ($r^2 = 0.27$, $P < .001$) (ie, the S-N-A angle decreased and the N-S-PL increased). The treatment also significantly decreased the facial skeletal profile convexity. This is suggested by the observed decrease in the A-N-B and S-N-A angles, and increase in the S-N-B and S-N-Pg angles (Table 1).

During treatment, the mandible rotated upwards and forward following the normal growth pattern.^{44,45} This was indicated by the observed decrease in the N-S-ML and Ar-CCgo-ML angles, and increase in the S-N-Pg angles. This result is consistent with the observation by Cook and associates,³⁷ but inconsistent with many other earlier studies.^{13,46-50} However, in contrast to these earlier studies, maxillary widening was induced by using an expanded inner bow, similar to that used by Cook and associates.³⁷ Hence, we suggest that the expansion of the maxillary dental arch enabled normal mandibular growth. Therefore, the expansion of the inner bow of the headgear is an essential part of the method. The binding together of teeth by another orthodontic appliance during headgear therapy may prevent the widening and have an adverse effect on the results.

The treatment did not have a significant effect on the inclination of the incisors. It is therefore suggested that the decreased horizontal overjet and the correction of the Class II division 1 malocclusions to Class I molar relationships are entirely a result of changes in maxillary and mandibular growth rather than changes in dental inclinations.

Only minor extrusion of the maxillary first molars was observed over the normal eruption. The extrusion of molars has been clearly reported in earlier studies.^{13,21,22,46-50} The prevention of the major eruption is probably a result of using a long upwards bent outer bow, which raised the resultant force of the cervical traction above the center of resistance of the upper molars. This important finding is consistent with the study of Cook and associates.³⁷ In the present study, the long outer bow was bent 15° upwards as recommended by Bench and coworkers,²¹ not 20° as used by Cook and associates.³⁷ The bending of the long outer bow of the headgear further upwards increases the risk that the outer bow will go above the rotation center of the upper first molars. This may cause distal tipping of the first molar crowns under the occlusal plane, and hinder the eruption of the upper and lower second molars.

There was a tendency for treatment to be more effective the earlier the treatment started and the longer it lasted. This effect is supposed to be most prominent during the high velocity period of growth in puberty.⁵¹ In the present study, we were not able to estimate the real skeletal maturational age of the children. However, the early onset of the treatment used in this study is supported by the natural course of the malocclusion with increasing age.^{16,42} Therefore, we did not wait for the maximal pubertal growth period.

CONCLUSIONS

Class II division 1 malocclusions with a protrusive maxilla were corrected to Class I molar relationships using orthopedic cervical headgear as the only treatment appliance. The headgear was used with an expanded inner bow and an long outer bow bent upwards. During the treatment period, the mandible grew forward according to the normal growth pattern. This normal mandible growth is likely to be achieved by widening the maxilla with the expanded inner bow.⁵² The results of the present study suggest that orthopedic cervical headgear used with an long upwards bent outer bow and a widened inner bow is a suitable method to treat the Class II division 1 malocclusions. The earlier the treatment was started, the slightly more pronounced effect it had on maxillary growth. This supports the early start of treatment. The treatment caused only minor extrusion of upper molars.

REFERENCES

1. Kloehn SJ. Guiding alveolar growth and eruption of teeth to reduce treatment time and produce a more balanced denture and face. *Am J Orthod.* 1947;17:10-33.

2. Bowden DE. Theoretical considerations of headgear therapy: a literature review. *Br J Orthod.* 1978;5:145-152.
3. Bowden DE. Theoretical considerations of headgear therapy: a literature review, 2. Clinical response and usage. *Br J Orthod.* 1978;5:173-181.
4. Tulloch JF, Medland W, Tuncay OC. Methods used to evaluate growth modification in Class II malocclusion. *Am J Orthod Dentofacial Orthop.* 1990;98:340-347.
5. Tuncay OC, Tulloch JF. Apparatus criticus: methods used to evaluate growth modification in Class II malocclusion. *Am J Orthod Dentofacial Orthop.* 1992;102:531-536.
6. Hubbard GW, Nanda RS, Currier GF. A cephalometric evaluation of nonextraction cervical headgear treatment in Class II malocclusions. *Angle Orthod.* 1994;64:359-370.
7. Tulloch JF, Phillips C, Koch G, Proffit WR. The effect of early intervention on skeletal pattern in Class II malocclusion: a randomized clinical trial. *Am J Orthod Dentofacial Orthop.* 1997;111:391-400.
8. Tulloch JF, Proffit WR, Phillips C. Influences on the outcome of early treatment for Class II malocclusion. *Am J Orthod Dentofacial Orthop.* 1997;111:533-542.
9. Tulloch JF, Phillips C, Proffit WR. Benefit of early Class II treatment: progress report of a two-phase randomized clinical trial. *Am J Orthod Dentofacial Orthop.* 1998;113:62-72.
10. Firouz M, Zernik J, Nanda R. Dental and orthopedic effects of high-pull headgear in treatment of Class II, division 1 malocclusion. *Am J Orthod Dentofacial Orthop.* 1992;102:197-205.
11. Reitan K. Biomechanical principles and reactions. In: Graber TM, Swain BF, eds. *Current Orthodontic Concepts and Techniques. Vol 1.* Philadelphia, Penn: WB Saunders; 1975:111-228.
12. Graber TM. Dentofacial orthopedics. In: Graber TM, ed. *Current Orthodontic Concepts and Techniques. Vol 2.* Philadelphia, Penn: WB Saunders; 1969:919-988.
13. Klein PL. An evaluation of cervical traction on the maxilla and the upper first permanent molar. *Angle Orthod.* 1957;27:61-68.
14. Moore AW. Orthodontic treatment factors in Class II malocclusion. *Am J Orthod.* 1959;45:323-352.
15. Poulton DR. Changes in Class II malocclusions with and without occipital headgear therapy. *Angle Orthod.* 1959;29:234-250.
16. Ricketts RM. The influence of orthodontic treatment on facial growth and development. *Angle Orthod.* 1960;30:103-133.
17. Wieslander L. The effect of orthodontic treatment on the concurrent development of the craniofacial complex. *Am J Orthod.* 1963;49:15-27.
18. Sandusky WC. Cephalometric evaluation of the effects of the Kloehn type of cervical traction used as an auxiliary with the edgewise mechanism following Tweed's principles for correction of Class II, division 1 malocclusion. *Am J Orthod.* 1965;51:262-287.
19. Haas AJ. Palatal expansion: just the beginning of dentofacial orthopedics. *Am J Orthod.* 1970;57:219-255.
20. Armstrong MM. Controlling the magnitude, direction, and duration of extraoral force. *Am J Orthod.* 1971;59:217-243.
21. Bench RW, Gugino CF, Hilgers JJ. Bioprogressive therapy, part V. *J Clin Orthod.* 1978;12:48-69.
22. Ricketts RM, Bench RW, Gugino CF, Hilgers JJ, Schulhof RJ. *Bioprogressive Therapy.* Denver, Col: Rocky Mountain Orthodontics; 1979.
23. Ghafari J, Shofer FS, Jacobsson-Hunt U, Markowitz DL, Laster LL. Headgear versus function regulator in the early treatment of Class II, division 1 malocclusion: a randomized clinical trial. *Am J Orthod Dentofacial Orthop.* 1998;113:51-61.
24. Weiland FJ, Ingervall B, Bantleon H-P, Droschl H. Initial effects of treatment of Class II malocclusion with the Herren activator, activator-headgear combination, and Jasper Jumper. *Am J Orthod Dentofacial Orthop.* 1997;112:19-27.

25. O'Reilly MT, Nanda SK, Close J. Cervical and oblique headgear: a comparison of treatment effects. *Am J Orthod Dentofacial Orthop.* 1993;103:504–509.
26. King GJ, Keeling SD, Hovevar RA, Wheeler TT. The timing of treatment for Class II malocclusions in children: a literature review. *Angle Orthod.* 1990;60:87–97.
27. Brown P. A cephalometric evaluation of high-pull molar headgear and face-bow neck strap therapy. *Am J Orthod.* 1978;74:621–632.
28. Moyers RE, Riolo ML, Guire KE, Wainright RL, Bookstein FL. Differential diagnosis of Class II malocclusions. *Am J Orthod.* 1980;78:477–494.
29. McNamara JAJ. Components of Class II malocclusion in children 8–10 years of age. *Angle Orthod.* 1981;51:177–202.
30. Carter NE. Dentofacial changes in untreated Class II division 1 subjects. *Br J Orthod.* 1987;14:225–234.
31. Rosenblum RE. Class II malocclusion: mandibular retrusion or maxillary protrusion? *Angle Orthod.* 1995;65:49–62.
32. Bishara SE, Jakobsen JR, Vorhies B, Bayati P. Changes in dentofacial structures in untreated Class II division 1 and normal subjects: a longitudinal study. *Angle Orthod.* 1997;67:55–66.
33. Baccetti T, Franchi L, McNamara J, Tollaro I. Early dentofacial features of Class II malocclusion: a longitudinal study from the deciduous through the mixed dentition. *Am J Orthod Dentofacial Orthop.* 1997;111:502–509.
34. Kirjavainen M, Kirjavainen T, Haavikko K. Changes in dental arch dimensions by use of an orthopedic cervical headgear in Class II correction. *Am J Orthod Dentofacial Orthop.* 1997;111:59–66.
35. Kuhn RJ. Control of anterior vertical dimension and proper selection of extraoral anchorage. *Angle Orthod.* 1968;38:340–349.
36. Greenspan RA. Reference charts for controlled extraoral force application to maxillary molars. *Am J Orthod.* 1970;58:486–491.
37. Cook AH, Sellke TA, BeGole EA. Control of the vertical dimension in Class II correction using a cervical headgear and lower utility arch in growing patients: part I. *Am J Orthod Dentofacial Orthop.* 1994;106:376–388.
38. Haavikko K. The formation and the alveolar and clinical eruption of the permanent teeth: an orthopantomographic study. *Proc Finn Dent Soc.* 1970;66:103–170.
39. Bhatia SN, Leighton BC. *A Manual of Facial Growth. A Computer Analysis of Longitudinal Cephalometric Growth Data.* Oxford: Oxford University Press; 1993.
40. Riolo ML, Moyers RE, McNamara JA, Hunter WS. *An Atlas of Craniofacial Growth: Cephalometric Standards From the University School Growth Study.* Ann Arbor, Mich: Center for Human Growth and Development, The University of Michigan; 1974.
41. Worms FW, Isaacson RJ, Speidel TM. A concept and classification of centers of rotation and extraoral force systems. *Angle Orthod.* 1973;43:384–401.
42. Mills CM, Holman RG, Graber TM. Heavy intermittent cervical traction in Class II treatment: a longitudinal cephalometric assessment. *Am J Orthod.* 1978;74:361–379.
43. Schudy FF, Schudy GF. The bimetric system. *Am J Orthod.* 1975;67:57–91.
44. Björk A. Prediction of mandibular growth rotation. *Am J Orthod.* 1969;55:585–599.
45. Skieller V, Björk A, Linde-Hansen T. Prediction of mandibular growth rotation evaluated from longitudinal implant sample. *Am J Orthod.* 1984;86:359–370.
46. Poulton DR. The influence of extraoral traction. *Am J Orthod.* 1967;53:8–18.
47. Baumrind S, Molthen R, West EE, Miller DM. Mandibular plane changes during maxillary retraction. *Am J Orthod.* 1978;74:32–40.
48. Baumrind S, Korn EL, Molthen R, West EE. Changes in facial dimensions associated with the use of forces to retract the maxilla. *Am J Orthod.* 1981;80:17–30.
49. Baumrind S, Korn EL, Isaacson RJ, West EE, Molthen R. Quantitative analysis of the orthodontic and orthopedic effects of maxillary traction. *Am J Orthod.* 1983;84:384–398.
50. Melsen B. Effects of cervical anchorage during and after treatment: an implant study. *Am J Orthod.* 1978;73:526–540.
51. Kopecky GR, Fishman LS. Timing of cervical headgear treatment based on skeletal maturation. *Am J Orthod Dentofacial Orthop.* 1993;104:162–169.
52. Björk A, Skieller V. Growth of the maxilla in three dimensions as revealed radiographically by the implant method. *Br J Orthod.* 1977;4:53–64.