

The Incisor–Lip Relationship in Herbst/Multibracket Appliance Treatment of Class II, Division 2 Malocclusions

Markus Schweitzer, DDS, Dr Med Dent^a; Hans Pancherz, DDS, Odont Dr^b

Abstract: The purpose of this investigation was to examine the effect of Herbst/multibracket appliance treatment on the upper incisor–lower lip relationship in the management of Class II, division 2 malocclusions. The study evaluated 19 successfully treated subjects using lateral head films analyzed at 3 occasions: before (T1) and after (T2) Herbst/multibracket appliance treatment and 1-year posttreatment (T3). The average treatment (T1-T2) changes showed (1) the lower lip overlap on the upper incisors was reduced from 6.0 mm to 4.2 mm ($P < .001$), (2) the upper incisors were proclined 15.3° ($P < .001$) and the lower incisors were proclined 9.6° ($P < .001$), (3) the overbite was reduced from 7.3 mm to 1.7 mm ($P < .001$), and (4) the sagittal jaw base relationship (Wits) improved from +3.5 to +0.5 mm ($P < .001$). The average posttreatment (T2-T3) changes showed (1) the upper incisor–lower lip relationship remained stable, (2) the upper (0.6° ; $P < .001$) and lower (2.3° ; $P < .001$) incisors retroclined, (3) the overbite increased (1.2 mm; $P < .001$), and (4) the sagittal jaw base relationship remained unchanged. In conclusion, it was found that the upper incisor–lower lip relationship was improved by Herbst/multibracket appliance treatment and remained stable during a 1-year posttreatment period in spite of minor relapses of incisor tooth positions and relationships. (*Angle Orthod* 2001;71:358–363.)

Key Words: Class II, division 2 malocclusion; Deep bite; Lower lip position; Herbst appliance; Roentgenographic cephalometry; Stability; Relapse

INTRODUCTION

The Class II, division 2 malocclusion is characterized by retroclined upper front teeth (at least the 2 central incisors), a deep overbite, and a Class II molar relationship.^{1,2} The perioral soft tissue features of the malocclusion such as the hyperactive mentalis muscle and the high lip line (defined as the lower lip covering the upper incisors)^{3–11} are said to be the cause of the steep upper incisor position^{2,3,9,12–19} as well as of the relapse frequently seen after treatment.

A Herbst/multibracket appliance combination has been shown to be most effective in the therapy of Class II, division 2 malocclusions. Class II molar and overjet/overbite corrections are accomplished by both skeletal and dental changes.²⁰ The influence of this treatment on the soft tissues, especially on the vertical position of the lower lip in

relation to the upper incisors, however, to this date has received no attention.

Thus, the aim of the present cephalometric roentgenographic investigation was to assess the effect of Herbst/multibracket appliance treatment on the upper incisor–lower lip relationship in the management of Class II, division 2 malocclusions.

MATERIALS AND METHODS

Subjects

The patient sample consisted of 19 Class II, division 2 malocclusions (8 females, 11 males) treated for an average period of 1 year and 10 months with the banded ($n = 5$) or the cast splint ($n = 14$) Herbst appliance followed by a multibracket appliance. The average pretreatment age of the subjects was 13 years, and each patient had a bilateral Class II molar relationship, retroclined upper incisors, and a deep overbite. After treatment, all subjects exhibited Class I dental arch relationships with a normal overjet and overbite. In 12 subjects, posttreatment retention was performed with a lower cuspid-to-cuspid retainer and an upper Hawley plate. The remaining 7 subjects were retained with an activator or a positioner.

The lateral head films of all subjects were analyzed on 3 occasions: before (T1) and after (T2) Herbst/multibracket

^aAssistant Professor, Department of Orthodontics, University of Giessen, Giessen, Germany.

^bProfessor and Chairman, Department of Orthodontics, University of Giessen, Giessen, Germany.

Corresponding author: Prof Dr Hans Pancherz, Department of Orthodontics, Faculty of Dentistry, Justus-Liebig-Universität of Giessen, Schlangenzahl 14, D-35292 Giessen, Germany.
(e-mail: hans.pancherz@dentist.med.uni-giessen.de).

Accepted: February 2001. Submitted: December 2000.

© 2001 by The EH Angle Education and Research Foundation, Inc.

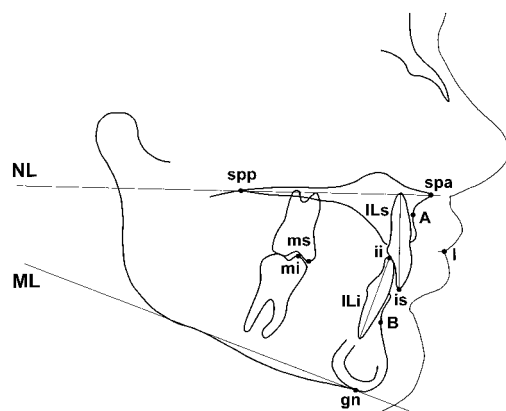


FIGURE 1. Reference points and lines used in the cephalometric analysis. Reference point definitions: I, lip point—the contact point between the upper and lower lips; ms, molar superius—the mesio-buccal cusp tip of the upper first molar; mi, molar inferius—the mesio-buccal cusp tip of the lower first molar; A0, A-point projection—the perpendicular projection of point A on the occlusal line; B0, B-point projection—the perpendicular projection of point B on the occlusal line; spa, spina nasalis anterior—the apex of spina nasalis anterior; spp, spina nasalis posterior—the point of intersection of palatum durum, palatum molle and fossa pterygopalatina.

appliance treatment and 1-year posttreatment (T3). The reference points and lines used are shown in Figure 1. The measured variables are seen in Figure 2a,b.

Measured variables

Variable 1. Lower lip position: the relation of the lower lip to the upper incisors measured by the vertical distance between the lip point (I) and incision superius (is) perpendicular to the occlusal line (OL).

Variable 2. Overbite: the distance between incision superius (is) and incision inferius (ii) perpendicular to the occlusal line (OL).

Variable 3. Upper incisor angulation: the angle ILs/NL.

Variable 4. Lower incisor angulation: the angle ILi/ML.

Variable 5. Interincisal angle: the angle ILs/ILi.

Variable 6. Vertical upper incisor position: the distance from is to NL.

Variable 7. Vertical upper molar position: the distance from ms to NL.

Variable 8. Vertical lower incisor position: the distance from ii to ML.

Variable 9. Vertical lower molar position: the distance from mi to ML.

Variable 10. Vertical jaw relation: the interjaw base angle NL/ML.

Variable 11. Sagittal jaw relation—Wits: the distance between the points A0 and B0. A positive (+) value means that A0 is positioned in front of B0. A negative (−) value implies that A0 is positioned behind B0.

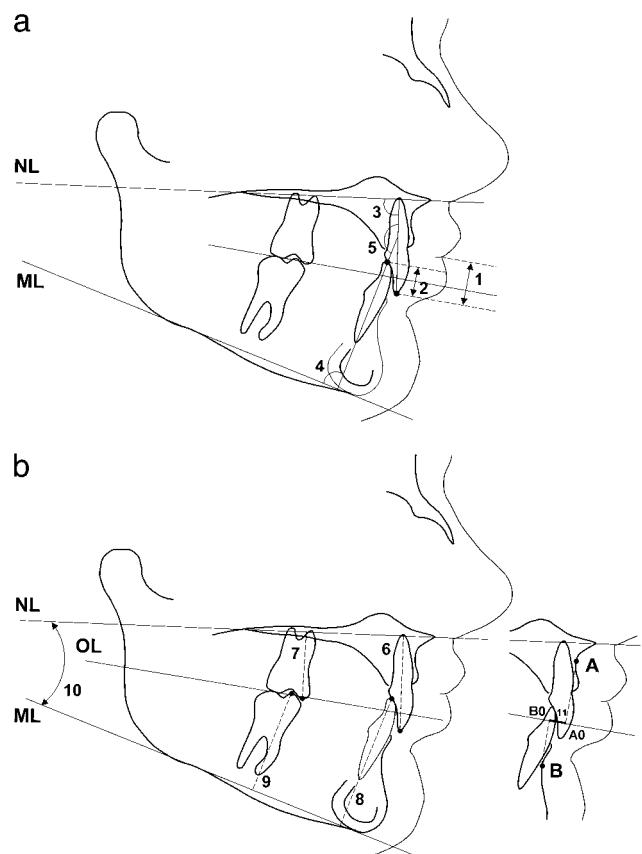


FIGURE 2. a. Measured variables 1–5 used in the cephalometric analysis. b. Measured variables 6–11 used in the cephalometric analysis.

Statistical methods

Statistical calculations were performed with the software Microsoft Excel and SPSS for Windows. The arithmetic mean (mean) and standard deviation (SD) were calculated for each cephalometric variable. The *t*-tests for paired samples were used to assess the differences between registrations performed at different occasions (T1, T2, T3). The levels of significance utilized were $P < .05$ (*), $P < .01$ (**), and $P < .001$ (***); $P \geq .05$ was considered as not significant (ns). All registrations were done twice, and the mean value was used for the evaluations.

Method error

The total method error for double registrations of each variable was calculated. The error comprised the identification of the reference points and lines, the tracing procedure, and the measurements of angles and distances. In the method error (ME) calculations, the following formula of Dahlberg²¹ was used:

$$ME = \sqrt{\frac{\sum d^2}{2n}}$$

TABLE 1. Method Error Evaluation Upon Double Registrations in 19 Class II, Division 2 Subjects Treated With Herbst/Multibracket Appliance (T1, Before Treatment; T2, After Treatment; T3, 1 Year After Treatment)

Variable	T1	T2	T3	T2-T1	T3-T2	T3-T1
1. I-is (mm)	0.46	0.46	0.43	0.75	0.56	0.18
2. ii-is (mm)	0.56	0.32	0.23	0.66	0.34	0.08
3. ILs/NL (degrees)	1.00	1.16	0.95	1.65	1.12	0.23
4. ILi/ML (degrees)	1.15	1.06	1.25	1.18	1.64	0.24
5. ILs/Li (degrees)	1.37	1.25	1.34	1.45	1.65	0.33
6. ms-NL (mm)	0.49	0.52	0.60	0.61	0.79	0.16
7. is-NL (mm)	0.39	0.37	0.67	0.46	0.81	0.32
8. mi-ML (mm)	0.49	0.39	0.40	0.57	0.65	0.11
9. ii-ML (mm)	0.88	0.35	0.41	0.99	0.48	0.26
10. ML/NL (degrees)	0.61	0.60	0.77	0.65	0.88	0.18
11. Wits (mm)	0.82	0.57	0.44	1.09	0.54	0.11

TABLE 2. Cephalometric Records (Mean, SD) in 19 Class II, Division 2 Malocclusions Treated With the Herbst/Multibracket Appliance (T1, Before Treatment; T2, After Treatment; T3, 1 Year After Treatment)

Variable	T1		T2		T3	
	Mean	SD	Mean	SD	Mean	SD
1. I-is (mm)	6.0	0.4	4.2	0.9	4.1	0.5
2. ii-is (mm)	7.3	3.8	1.7	0.5	2.9	1.1
3. ILs/NL (degrees)	95.6	7.3	110.9	0.3	110.3	0.3
4. ILi/ML (degrees)	94.3	7.8	103.9	2.0	101.6	0.9
5. ILs/Li (degrees)	149.9	13.1	124.7	0.3	128.9	0.5
6. ms-NL (mm)	21.1	1.6	22.6	0.1	23.3	0.6
7. is-NL (mm)	28.2	0.9	27.8	1.6	28.4	1.1
8. mi-ML (mm)	31.6	0.5	33.8	1.0	34.2	1.5
9. ii-ML (mm)	40.9	3.3	40.5	3.1	41.4	4.0
10. ML/NL (degrees)	20.9	2.5	20.6	1.9	19.5	1.9
11. Wits (mm)	3.5	3.9	0.5	1.5	0.6	1.1

where d is the difference between 2 registrations of a pair and n is the number of the double registrations ($n = 19$). The results of the calculations are seen in Table 1.

TABLE 3. Change of Cephalometric Records in 19 Class II, Division 2 Malocclusions Treated With the Herbst/Multibracket Appliance (T1, Before Treatment; T2, After Treatment; T3, 1 Year After Treatment)

Variable	T2-T1				T3-T2				T3-T1			
	Mean	SD	t-Value	P ^a	Mean	SD	t-Value	P ^a	Mean	SD	t-Value	P ^a
1. I-is (mm)	-1.8	0.5	-15.60	***	-0.1	0.4	-0.61	ns	-1.9	0.1	-64.24	***
2. ii-is (mm)	-5.6	3.3	-7.52	***	1.2	0.6	8.63	***	-4.4	2.6	-7.25	***
3. ILs/NL (degrees)	15.3	7.5	8.87	***	-0.6	0.5	-4.70	***	14.7	7.0	9.17	***
4. ILi/ML (degrees)	9.6	5.8	7.28	***	-2.3	1.1	-8.82	***	7.3	6.9	4.65	***
5. ILs/Li (degrees)	-25.2	12.9	-8.54	***	4.2	0.8	24.09	***	-21.0	13.6	-6.74	***
6. ms-NL (mm)	1.5	1.6	3.88	**	0.7	0.6	4.96	***	2.2	11.3	0.42	ns
7. is-NL (mm)	-0.4	0.8	-2.29	*	0.6	0.5	4.70	***	0.2	0.3	2.52	*
8. mi-ML (mm)	2.2	0.5	19.04	***	0.4	0.5	3.56	**	2.6	1.0	11.30	***
9. ii-ML (mm)	-0.4	0.1	-13.76	***	0.9	0.9	4.13	***	0.5	0.8	2.52	*
10. ML/NL (degrees)	-0.3	0.6	-1.67	ns	-1.1	0.1	-47.95	***	-1.4	0.6	-9.81	***
11. Wits (mm)	-3.0	2.4	-5.53	***	0.1	0.4	0.61	ns	-2.9	2.8	-4.69	***

^a*, $P < .05$; **, $P < .01$; ***, $P < .001$; ns, not significant.

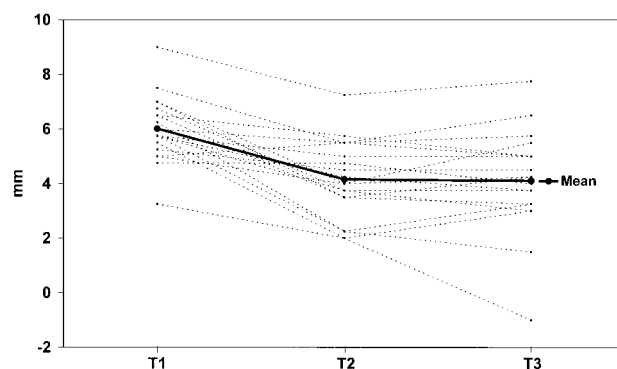


FIGURE 3. Individual changes in lower lip position in 19 Class II, division 2 subjects treated with Herbst/multibracket appliance. T1, before treatment; T2, after treatment; T3, 1 year after treatment.

RESULTS

The cephalometric records from before, after, and 1 year after Herbst treatment are presented in Table 2. The treatment and posttreatment changes are shown in Table 3. The individual changes in lower lip position are given in Figure 3, and the mean changes of selected variables are given in Figures 4 through 8.

Treatment changes (T2-T1)

Variable 1 (lower lip position, I-is). Lower lip overlap on the upper incisors was reduced in 18 of the 19 subjects (mean: 1.8 mm; $P < .001$).

Variable 2 (overbite, ii-is). Overbite was reduced in all subjects (mean: 5.6 mm; $P < .001$).

Variables 3-9 (tooth positions). Upper and lower incisors were proclined in all subjects. The average proclination was 15.3° ($P < .001$) for the upper and 9.6° ($P < .001$) for the lower incisors. The interincisal angle (ILs/ILi) was reduced in all subjects (mean: 25.2° ; $P < .001$). Vertical upper incisor position remained unchanged on average. The vertical distance of is to NL increased in 7 and decreased in 10 of

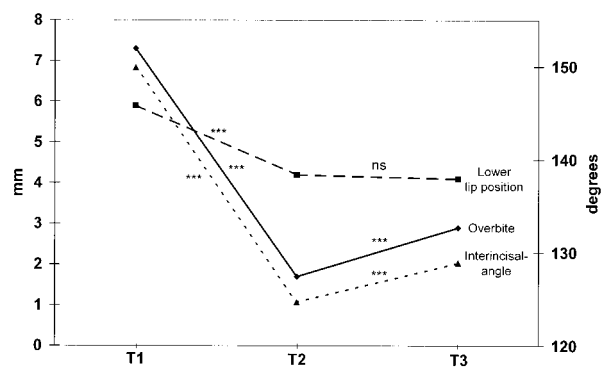


FIGURE 4. Changes of lower lip position (mm), overbite (mm), and interincisal angle (degrees) in 19 Class II, division 2 subjects treated with Herbst/multibracket appliance. T1, before treatment; T2, after treatment; T3, 1 year after treatment.

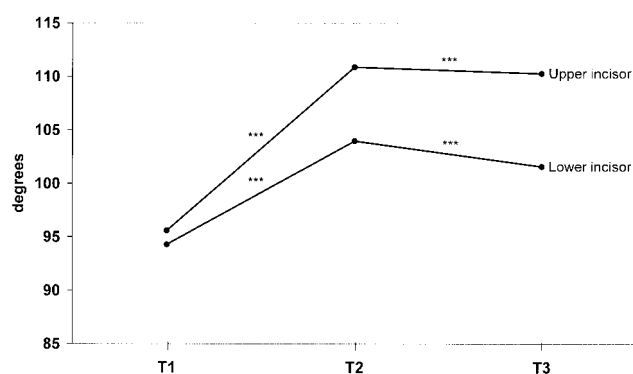


FIGURE 5. Changes of upper and lower incisor angulation in 19 Class II, division 2 subjects treated with Herbst/multibracket appliance. T1, before treatment; T2, after treatment; T3, 1 year after treatment.

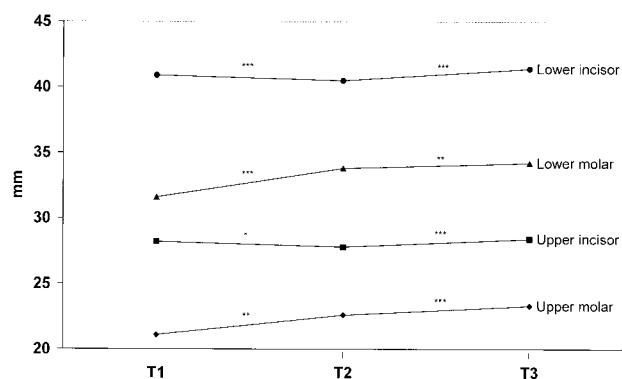


FIGURE 6. Changes of vertical tooth positions in 19 Class II, division 2 subjects treated with Herbst/multibracket appliance. T1, before treatment; T2, after treatment; T3, 1 year after treatment.

the 19 subjects. The vertical upper molar distance ms to NL increased in 16 of the 19 subjects (mean: 1.5 mm; $P < .01$). The vertical lower incisor distance ii to ML decreased in 10 and increased in 6 of the 19 subjects (mean: 0.4 mm; $P < .001$). The vertical lower molar distance mi to ML increased in all subjects (mean: 2.2 mm; $P < .001$).

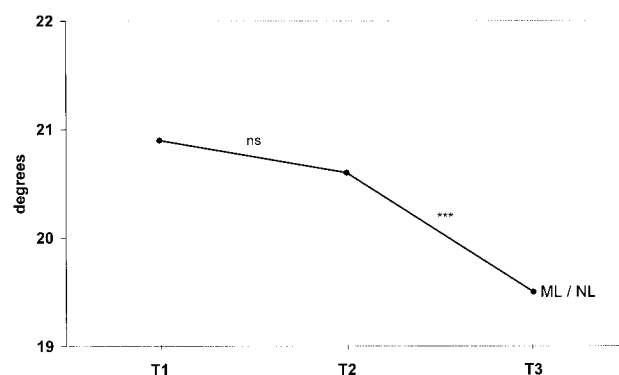


FIGURE 7. Changes of the vertical jaw relation in 19 Class II, division 2 subjects treated with Herbst/multibracket appliance. T1, before treatment; T2, after treatment; T3, 1 year after treatment.

Variable 10 (vertical jaw relation, NL/ML). The angle NL/ML remained unchanged on average. It increased in 9 and decreased in 7 of the 19 subjects.

Variable 11 (sagittal jaw relation—Wits). Sagittal jaw base relationship (Wits) was improved to a Class I relationship in 18 of the 19 subjects (mean: 3.0 mm; $P < .001$).

Posttreatment changes (T3-T2)

Variable 1 (lower lip position, l-is). Lower lip overlap on the upper incisors remained unchanged on average (Figures 3 and 4). It increased in 8 and decreased in 8 of the 19 subjects.

Variable 2 (overbite, ii-is). Overbite increased in 17 of the 19 subjects (mean: 1.2 mm; $P < .001$).

Variables 3–9 (tooth positions). The upper incisors retroclined in 12 of the 19 subjects (mean: 0.6°; $P < .001$) and the lower incisors retroclined in 16 of the 19 subjects (mean: 2.3°; $P < .001$). The interincisal angle (ILs/ILi) increased in 16 of the 19 subjects (mean: 4.2°; $P < .001$).

The vertical upper incisor distance is to NL increased in 11 of the 19 cases (mean: 0.6 mm; $P < .001$). The vertical upper molar distance ms to NL increased in 11 of the 19 subjects (mean: 0.7 mm; $P < .001$). The vertical lower incisor distance ii to ML increased in 13 of the 19 subjects (mean: 0.9 mm; $P < .001$). The vertical lower molar distance mi to ML increased in 10 of the 19 cases (mean: 0.4 mm; $P < .01$).

Variable 10 (vertical jaw relation). The inter jaw base angle (ML/NL) decreased in 15 of the 19 cases (mean: 1.1°; $P < .001$).

Variable 11 (sagittal jaw relation—Wits). The sagittal jaw base relationship (Wits) remained unchanged on average. The Wits value increased in 8 and decreased in 11 of the 19 subjects.

DISCUSSION

Long-term stability of treated Class II, division 2 malocclusions is, among other things, said to be related to a

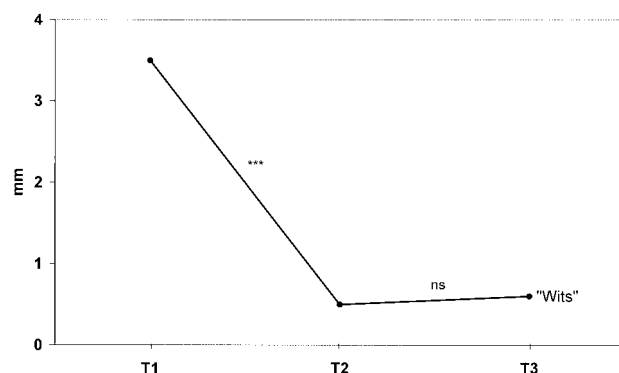


FIGURE 8. Changes of the sagittal jaw relation in 19 Class II, division 2 subjects treated with Herbst/multibracket appliance. T1, before treatment; T2, after treatment; T3, 1 year after treatment.

relative decrease of the lower lip cover on the upper incisors.^{2,4,5,7,13,16–19,22–24} Upon Herbst/multibracket appliance treatment of the present Class II, division 2 subjects, the lower lip overlap on the upper incisors was reduced by 29% (from 5.9 mm to 4.2 mm). During the 1-year posttreatment period, this lip position remained stable. In another Class II, division 2 investigation, using exclusively a multibracket appliance approach, the lower lip overlap was reduced from 4.6 mm to 2.8 mm and then relapsed 1.0 mm during a 1-year posttreatment period.²⁵ The net improvement in the lip position was thus only 17%. The differences in stability found in the two studies may be explained by the various retention regimes performed. In the present study, all subjects had posttreatment retainers, while no retention was performed in Fuhrmann's²⁵ subjects. Furthermore, in regular multibracket appliance treatment, as in Fuhrmann's patients, overbite is reduced by active intrusion of the incisors and extrusion of the molars. The tendency toward overbite relapse is, however, great when incisors are intruded.²⁶

In a long-term cephalometric evaluation of treated Class II, division 2 malocclusions, Binda et al²⁷ found that the lower lip line was lowered during treatment (1.2 mm) and relapsed 0.2 mm during the first 2 years of postretention but did not change afterward. Furthermore, in untreated subjects with normal occlusion, Vig and Cohen²⁸ found that the most marked changes in the relationship of the lower lip to the upper incisors occurred between 9 years and 13 years. After the 13th year, the lower lip overlap on the upper incisors is nearly constant. This would be in agreement with the present findings since the average pretreatment age of the Class II, division 2 cases was 13 years.

Mills¹⁶ as well as van der Linden and Boersma¹⁹ found a significant correlation between the lower lip overlap on the upper incisor position, the interincisal angle, and the overbite. It can, therefore, be assumed that the high positioned lip retroclines the upper and lower incisors. The resulting large interincisal angle then causes the deep overbite due to the missing incisal support allowing the front teeth to erupt freely.

In the present investigation, the overbite was reduced on average from 7.3 mm to 1.7 mm but then relapsed to 2.9 mm. The net overbite reduction was thus 59%, which is relatively high in comparison with other studies.^{25,29,30} The overbite reduction was mainly accomplished by proclination of the maxillary and mandibular incisors,^{21,31,32} extrusion of the lower molars,³² and downward tilt of the mandibular occlusal plane.³² While proclination of the lower incisors usually is undesirable in orthodontics, it is an advantage in the correction of the deep bite in Class II, division 2 malocclusions since the teeth are in a retroclined position to begin with.

In the treatment of the present 19 cases, the upper incisors were, in most cases, proclined with a multibracket appliance before the Herbst appliance was placed. This decompensation of upper incisor position allowed free lower incisor proclination during the mandibular advancement procedure with the Herbst telescope mechanism.

Relapse in overbite has been found to be significantly correlated with relapse of the interincisal angle.^{13,26,29,33,34} Exaggerated proclination of the lower incisors in Class II, division 2 patients would therefore result in a reduction of the interincisal angle, which will contribute to posttreatment overbite stability.^{26,29} Berg³⁰ considered an interincisal angle of less than 140° after treatment to be favorable for long-term stability. In the present sample, the interincisal angle was reduced from 150° to 125° during treatment and increased only 4° after treatment.

Long-term posttreatment stability of the occlusion is certainly also dependent on balanced muscle forces acting on the teeth. A lower lip coverage will challenge this balance.¹⁸ Therefore, in the correction of Class II, division 2 cases, it is necessary to retain the treatment result over a longer period of time to get a soft tissue adaptation.

Selwyn-Barnett²⁴ recommends that the lower arch be retained permanently when any tendency to an increase in the interincisal angle is anticipated. A fixed cuspid-to-cuspid lingual retainer behind the lower front teeth ensures a stable antero-posterior and transverse position of the lower labial segment, which is the foundation of the correct incisor relationship. Crowding of the lower labial segment with concomitant reduction of the intercanine width would lessen the transverse support for the upper arch. This effect is potentially more serious in patients with tight perioral musculature, as seen in Class II, division 2 malocclusions.³⁵ In spite of the lower cuspid-to-cuspid retainer in the present study, the inclination of the lower incisors recovered by an average of 2.3° during the follow-up period. This change in incisor position was certainly the cause of the posttreatment increase in the interincisal angle and in the small overbite relapse seen.³⁶

CONCLUSION

In conclusion, it was found that in Class II, division 2 malocclusions, the upper incisor–lower lip relationship was

improved by Herbst/multibracket appliance treatment and remained stable during a 1-year posttreatment period in spite of minor relapses of incisor tooth position and relationships. Postretention follow-up studies are, however, necessary to assess the long-term effect of the Herbst/multibracket appliance approach on the incisor-lower lip relationship.

REFERENCES

- Mayrhofer B. *Lehrbuch der Zahnheilkunde*. Jena, Germany: Fischer; 1933.
- Ridley DR. Some factors concerned with the reduction of excessive incisor overbite in Angle's Class II division 2 malocclusion. *Trans Brit Soc Study Orthod*. 1960;118-140.
- Angle EH. *Okklusionsanomalien der Zähne*. Philadelphia, Pa: SS White Dental Manufacturing; 1908.
- Nicol WA. The morphology of the lips in relation to the incisor teeth. *Trans Brit Soc Study Orthod*. 1954;25-28.
- Nicol WA. The relationship of the lip line to the incisor teeth. *Trans Brit Soc Study Orthod*. 1955;75-81.
- Ballard CF. The significance of soft tissue morphology in diagnosis, prognosis and treatment planning. *Trans Eur Orthod Soc*. 1953;19:143-175.
- Ballard CF. Morphology and treatment of Class II, division 2 occlusions. *Trans Eur Orthod Soc*. 1956;32:44-54.
- Robertson NRE, Hilton R. Feature of the upper central incisors in the Class division 2. *Angle Orthod*. 1965;35:51-53.
- Fränkel R. *Funktionskieferorthopädie und Mundvorhof als comparative Basis*. Berlin: Volk und Gesundheit; 1967.
- Karlsen AT. Craniofacial characteristics in children with Angle Class division 2 malocclusion combined with extreme deep bite. *Angle Orthod*. 1994;64:123-130.
- Van der Linden F. *Probleme und Vorgänge in der Kieferorthopädie*. Berlin: Quintessenz; 1991.
- Fränkel R. Die Bedeutung der Weichteile für die Induktion und Formorientierung des Kieferwachstums unter Zugrundelegung der Behandlungsergebnisse mit Funktionsreglern. *Fortschr Kieferorthop*. 1964;25:413-432.
- Nicol WA. The lower lip and the upper incisor teeth in Angle's Class II division 2 malocclusion. *Dent Pract*. 1963;14:179-182.
- Nicol WA. The lower lip and the upper teeth in Angle's Class II, division 2 malocclusion. *Dent Pract*. 1964;14:179-182.
- Posen AL. The influence of maximum perioral and tongue force on the incisor teeth. *Angle Orthod*. 1972;42:285-309.
- Mills JR. The problem of overbite in Class II, division 2 malocclusion. *Brit J Orthod*. 1973;1:34-48.
- Fletcher GGT. The retroclined upper incisor. *Brit J Orthod*. 1975;2:207-216.
- Luffingham JK. The lower lip and the maxillary central incisors. *Eur J Orthod*. 1982;4:263-268.
- Van der Linden F, Boersma H. *Diagnose und Behandlungsplanung in der Kieferorthopädie*. Band 3. Berlin: Quintessenz Verlag; 1988.
- Obijou C, Pancherz H. Herbst appliance treatment of Class II, division 2 malocclusions. *Am J Orthod Dentofac Orthop*. 1997;112:287-291.
- Dahlberg G. *Statistical Methods for Medical and Biological Students*. New York: Interscience; 1940.
- Van der Linden F. *Development of the Dentition*. Chicago: Quintessence; 1983.
- Van der Linden F. *Facial Growth and Facial Orthopedics*. Chicago: Quintessence; 1986.
- Selwyn-Barnett BJ. Rationale of treatment for Class II division 2 malocclusion. *Brit J Orthod*. 1991;18:173-181.
- Fuhrmann R. *Kieferorthopädische Behandlung der Klasse II, 2 Malokklusion. Nachuntersuchung von 17 Patienten unter besonderer Berücksichtigung der Unterlippenhöhe und der Bißhebung*. Homburg/Saar, Germany: Med Diss; 1989.
- Simons ME, Joondeph DR. Change in overbite: a ten-year postretention study. *Am J Orthod*. 1973;64:349-367.
- Binda SKR, Kuijpers-Jagtman AM, Maertens JKM, vant Hoff MA. A long-term cephalo-metric evaluation of treated Class II division 2 malocclusions. *Eur J Orthod*. 1994;16:301-308.
- Vig PS, Cohen AM. Vertical growth of the lips: a serial cephalometric study. *Am J Orthod*. 1979;75:405-415.
- Lagerström L. Tiefbißkorrektur in Angle Klasse II, 2 Okklusionsanomalien. *Kieferorthopädie, Konzepte und Perspektiven*. München, Germany: ZMS-Verlag; 1980:129-136.
- Berg R. Stability of deep overbite correction. *Eur J Orthod*. 1983;5:75-83.
- Pancherz H. Treatment of Class II malocclusions by bite jumping with the Herbst appliance. A cephalometric investigation. *Am J Orthod*. 1979;76:423-442.
- Pancherz H. Vertical dentofacial changes during Herbst appliance treatment. *Swed Dent J*. 1982b;15(suppl):189-196.
- Schudy FF. The control of vertical overbite in clinical orthodontics. *Angle Orthod*. 1968;38:19-39.
- Houston WJB. Incisor edge-centroid relationships and overbite depth. *Eur J Orthod*. 1989;11:139-143.
- Selwyn-Barnett BJ. Class II, division 2 malocclusion: a method of planning and treatment. *Brit J Orthod*. 1996;23:29-36.
- Pancherz H. The effect of continuous bite jumping on the dentofacial complex: a follow-up study after Herbst appliance treatment of Class II malocclusions. *Am J Orthod*. 1981;3:49-60.