

# Reduction of the Hypocone of the Maxillary First Molar and Class III Malocclusion

Kazunori Yamaguchi, DDS, PhD<sup>a</sup>; Noriaki Kawanabe, DDS<sup>b</sup>; Eiji Tanaka, DDS, PhD<sup>c</sup>; Kazuo Tanne, DDS, PhD<sup>d</sup>

**Abstract:** This study was conducted to examine the incidence of evolutionary changes of the maxillary molars in orthodontic patients and to investigate the association of this event with craniofacial growth. Among 4,892 Japanese patients treated at the orthodontic clinic of Hiroshima University Dental Hospital, 59 patients presented with a defect of the distolingual cusp of the maxillary first molar. They consisted of 52 female patients and seven male patients with a mean age of 14.7 years. Eruption of the maxillary first and second molars was delayed and the third molar was congenitally missing in all of these patients. Thirty-seven patients exhibited Class III malocclusion (Class III evolution group). The Z scores of cephalometric measurements were compared between the Class III evolution group and the Class III control group. The latter group consisted of 37 Class III subjects with no evolutionary dental anomalies and no orthodontic history. The tooth developmental score (TDS) for each age at the initial record was compared with Nolla's standard tooth developmental score (STDS) for equivalent ages using paired *t*-tests. The Z scores for Ptm'-A and Ar-A were significantly smaller in the Class III evolutionary group than in the Class III control group ( $P < .05$ ). The TDS for the maxillary first and second molars were significantly smaller than the STDS for these molars ( $P < .01$ ). The TDS for the maxillary second molar was significantly larger than the STDS for the maxillary third molar ( $P < .01$ ). This study revealed that an evolution change of the maxillary molar is more common ( $P < .05$ ) in female patients than in male patients, is more frequent ( $P < .05$ ) in subjects with Class III malocclusion, and is related to the anteroposterior undergrowth of the maxilla. (*Angle Orthod* 2001;71:477-485.)

**Key Words:** Hypocone; Maxillary first molar; Craniofacial growth; Cephalometry; Root formation; Class III

## INTRODUCTION

Dental anomalies such as missing and malformed teeth may be signs of heritable developmental disturbances of tooth structures.<sup>1-3</sup> Sexual and racial differences in the incidence of such disturbances have also been described.<sup>4-6</sup>

The third molar is the smallest of the molar teeth with a relatively high incidence of agenesis.<sup>7,8</sup> This is thought to be a general trend toward tooth reduction. To explain the high incidence of third molar agenesis, the concept of morphogenetic fields and the hypotheses of environmental control were proposed by Butler<sup>9</sup> and modified by Dahlberg<sup>10</sup> for human dentition. They believed that the genetic influence diminishes in the more distal tooth within the ontogenetic field. This would account for the reduction and greater variability of the posterior teeth<sup>11,12</sup> Anderson et al<sup>4</sup> reported that the evolutionary reduction of dental dimensions might result from an evolutionary reduction in genetically determined body size. Haruki et al<sup>13</sup> stated that the times of eruption and calcification of the maxillary molars were significantly related to the length of the maxilla. Carlson and van Gerven<sup>14</sup> reported that craniofacial variation was due to changes in the masticatory function and the reduction in dental size was a compensatory response to altered facial size and position.

There is a need to examine clinical cases in order to understand the genetic basis of the evolution of the number

<sup>a</sup> Professor and Chair, Department of Orthodontics, Kyushu Dental College, Kitakyushu, Fukuoka, Japan.

<sup>b</sup> Graduate student, Department of Orthodontics, Kyushu Dental College, Kitakyushu, Fukuoka, Japan.

<sup>c</sup> Associate Professor, Department of Orthodontics, Hiroshima University, Hiroshima, Japan.

<sup>d</sup> Professor and Chair, Department of Orthodontics, Hiroshima University, Hiroshima, Japan.

Corresponding author: Kazunori Yamaguchi, DDS, PhD, Professor and Chair, Department of Orthodontics, Kyushu Dental College, 2-6-1 Manazuru, Kokurakitaku, Kitakyushu, Fukuoka 803-8580 Japan (e-mail: ykazu@kyu-dent.ac.jp).

Presented before a meeting of the North Atlantic Component of the E H Angle Society of Orthodontists, Tyson's Corner, Va, March 2000.

Accepted: June 2001. Submitted: March 2001.

© 2001 by The EH Angle Education and Research Foundation, Inc.

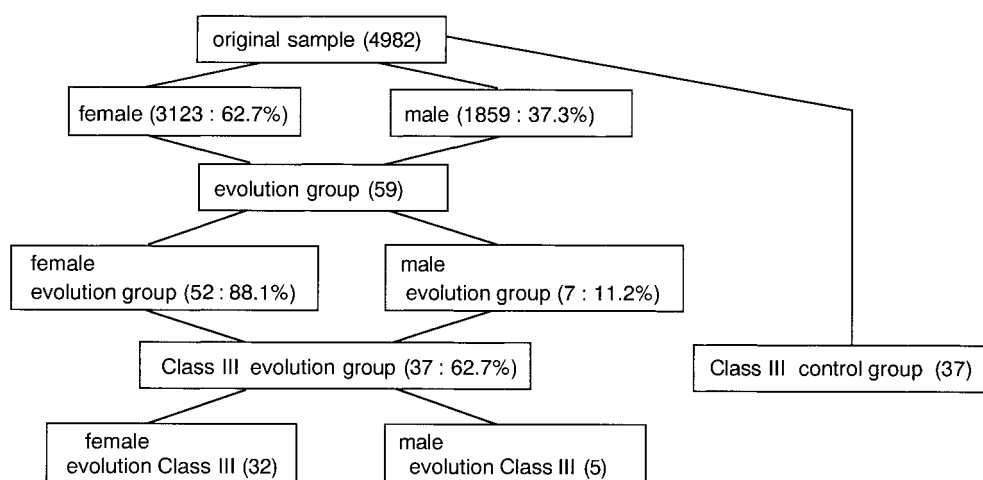


FIGURE 1. Distribution of subjects in original sample.

and shape of teeth and to comprehend the concept of morphogenetic fields and the hypotheses of environmental control. Early diagnosis with a family history and early clinical or radiographic detection is important so that interceptive pediatric and orthodontic interventions are practical in relation to missing, malformed and ectopically erupting teeth.

In the upper molar region, the evolutionary changes of the teeth appear as a defect in the distolingual cusp (hypocone) or as congenital missing teeth and a delay of eruption.<sup>1</sup> This is not only of anthropological interest, but it also has a clinical significance in orthodontic diagnosis and treatment. A posterior discrepancy, which determines any extraction therapy, depends on the size and number of molars.<sup>15-17</sup> The present study was conducted to examine the incidence of the evolution of the maxillary molars in orthodontic patients and to investigate its association with craniofacial growth.

## METHODS AND SUBJECTS

Evolutionary changes of the upper molars were examined in 4,892 Japanese patients (original sample) treated at the orthodontic clinic of Hiroshima University Dental Hospital using dental models and panoramic radiographs taken periodically throughout treatment. The original sample consisted of 62.7% female patients and 37.3% male patients (Figure 1). The age ranged from 6 to 35 years. As expected, Class III malocclusion was the major malocclusion (25%) (Figure 2). Class III malocclusion was defined by the presence of an anterior cross bite and a Class III molar relationship, not by the skeletal relationship. Fifty-nine (1.1%) patients from the original sample were included in our evolution group for the purposes of this study. These patients met the following exclusion criteria:

1. Absence of the distolingual cusp (hypocone) of the maxillary first molar (classified as grade 0 by Turner's<sup>18</sup> stan-

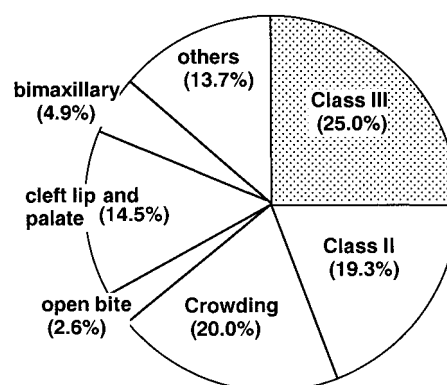


FIGURE 2. Malocclusion in original sample.

dard from the Arizona State University dental Anthropological system.

2. No clinical history of extraction of the maxillary first molar.
3. No numerous missing of teeth.
4. No congenital abnormalities in dentofacial complex including cleft lip and palate.

The evolution group consisted of 52 female patients (88.1%) and seven male patients (11.9%), with a mean age of 14.7 years and a range of 5–35 years (Figure 1). Among the evolution group, 88 molars (0.9% of the original sample) exhibited evolutionary changes. Reduction of a cusp was identified bilaterally in 35 of these patients. Each frequency was statistically compared by a test of proportion.

## Cephalometric measurements

Thirty-seven of the subjects in the Class III evolution group (62.7%) with a mean age of 14.2 years exhibited a Class III malocclusion (Figure 1). In order to define the morphological characteristics of the dentofacial structures relative to the evolutionary changes of the maxillary molars

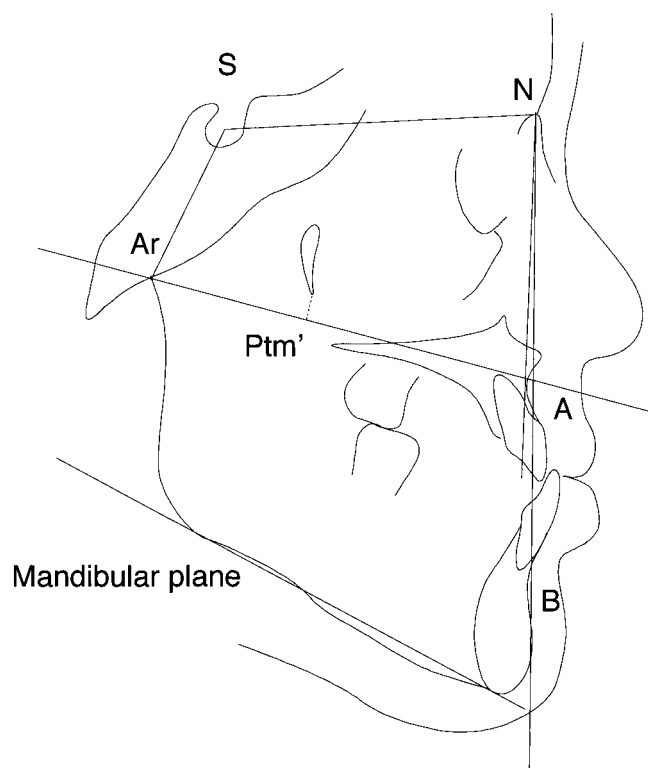


FIGURE 3. Cephalometric measurements.

TABLE 1. Tooth Developmental Score

Developmental Score	Description
0	Absence of crypt
1	Presence of crypt
2	Initial calcification
3	One-third of crown completed
4	Two-thirds of completed
5	Crown almost completed
6	Crown completed
7	One-third of root completed
8	Two-thirds of root completed
9	Root almost completed, open apex
10	Apical end of root completed

in the Class III evolution group, cephalometric measurements of the final records in the Class III evolution group were compared to the initial records of 37 subjects randomly selected from the Class III control group. Class III control subjects had no apparent reduction of the hypocone in the maxillary first molar and no orthodontic history (Figure 1). Since it was difficult to match the age, sex, and type of Class III malocclusion with the Class III evolution group, Z-scores were compared between the evolution Class III and control Class III groups. Z-scores of the 2 groups were calculated by the following formula: (standard value in normal sample—value of each subject in evolution and control Class III groups) / standard deviation in normal sample. Eleven measurements were made for the analysis of lateral cephalograms (Figure 3). The angular skeletal measurements were angle SNA, N-S-Ar, SN/Ar-A, NAB, Ar-A-B, Mp to PP, and the linear skeletal measurements were Ptm'-A, Ar-A, N-A, Ar-A, A-B.

### Estimation of tooth development

Nolla's<sup>19</sup> tooth developmental stage is scored from zero to 10 according to the formation of the root and crown (Table 1). The standard tooth developmental score (STDS) of the molars for each age is shown in Table 2. The entire tooth including the crown was traced on the radiographic films in the initial and last records (Figure 4). The tooth developmental score (TDS) for each chronological age in each subject at the initial record (beginning of treatment) was obtained from Table 2 by referring to the completed root length in the last record. Because the root formation is almost completed at 13 years of age, 29 females less than 13 years of age were selected from the evolution group (Figure 1). The mean TDS for the maxillary and mandibular molars in these subjects was statistically compared with the Nolla's standard tooth developmental score (STDS) for the equivalent age using the paired *t*-test. All data were expressed as mean  $\pm$  standard error of mean (SEM). A *P* value  $< .05$  denoted the presence of a statistically significant difference.

## RESULTS

### Frequency

The reduction of the hypocone in the maxillary first molar (an evolutionary change) was significantly more fre-

TABLE 2. Standard Tooth Developmental Score (STDS) of the Molars by Nolla

Molar	Chronological Age										
	5	6	7	8	9	10	11	12	13	14	15
Maxillary first molar		8.5				9	10				
Maxillary second molar		7			7.5		8	8.5	9	10	
Maxillary third molar				2.1	2.4	3.2	4.3	5.4	6.2	6.8	7.3
Mandibular first molar	7		8.5					9	10		
Mandibular second molar	6		6.5		7	7.5	8			9	10
Mandibular third molar			1.8	2.1	2.3	3.2	3.7	4.7	5.8	6.5	6.9

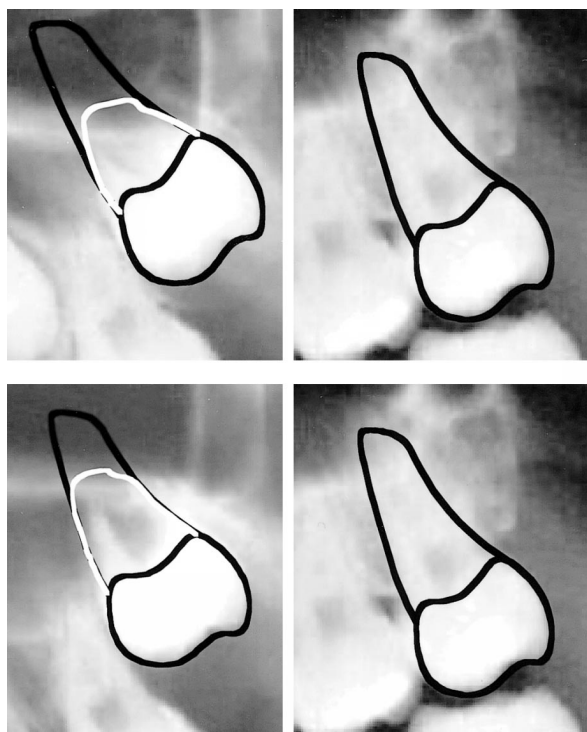


FIGURE 4. Estimation of tooth development.

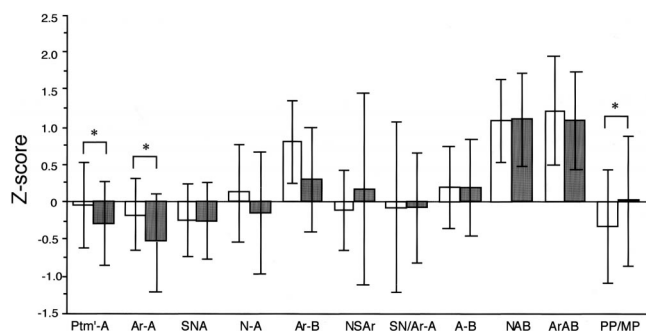


FIGURE 5. Data are mean  $\pm$  SEM for Z scores.

quent in females than in males ( $P < .01$ ) and more frequent in subjects with Class III malocclusion than those with other malocclusions ( $P < .05$ ). In accordance with evolutionary changes, eruption of the maxillary first and second molars was retarded and the third molar was congenitally missing.

### Comparison of craniofacial morphology

The Z scores for the Ptm''-A and Ar-A were significantly smaller in the Class III evolution group than in the Class III control group ( $P < .05$ ), but there were no significant difference in the Z scores for the rest of measurements (Figure 5). The cephalometric analysis revealed that the antero-posterior dimension was significantly less in the Class III evolution group than in Class III control group.

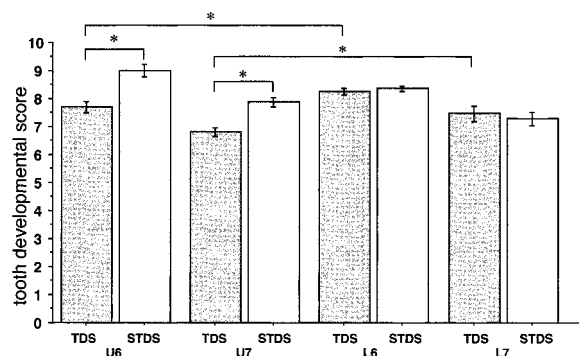


FIGURE 6. Comparison of tooth developmental score. U6: maxillary first molar, U7: maxillary second molar, L6: mandibular first molar, L7: mandibular second molar, U8: maxillary third molar. Data are mean  $\pm$  SEM of TDS (dotted bars) and STDS (open bars).

### Tooth developmental score

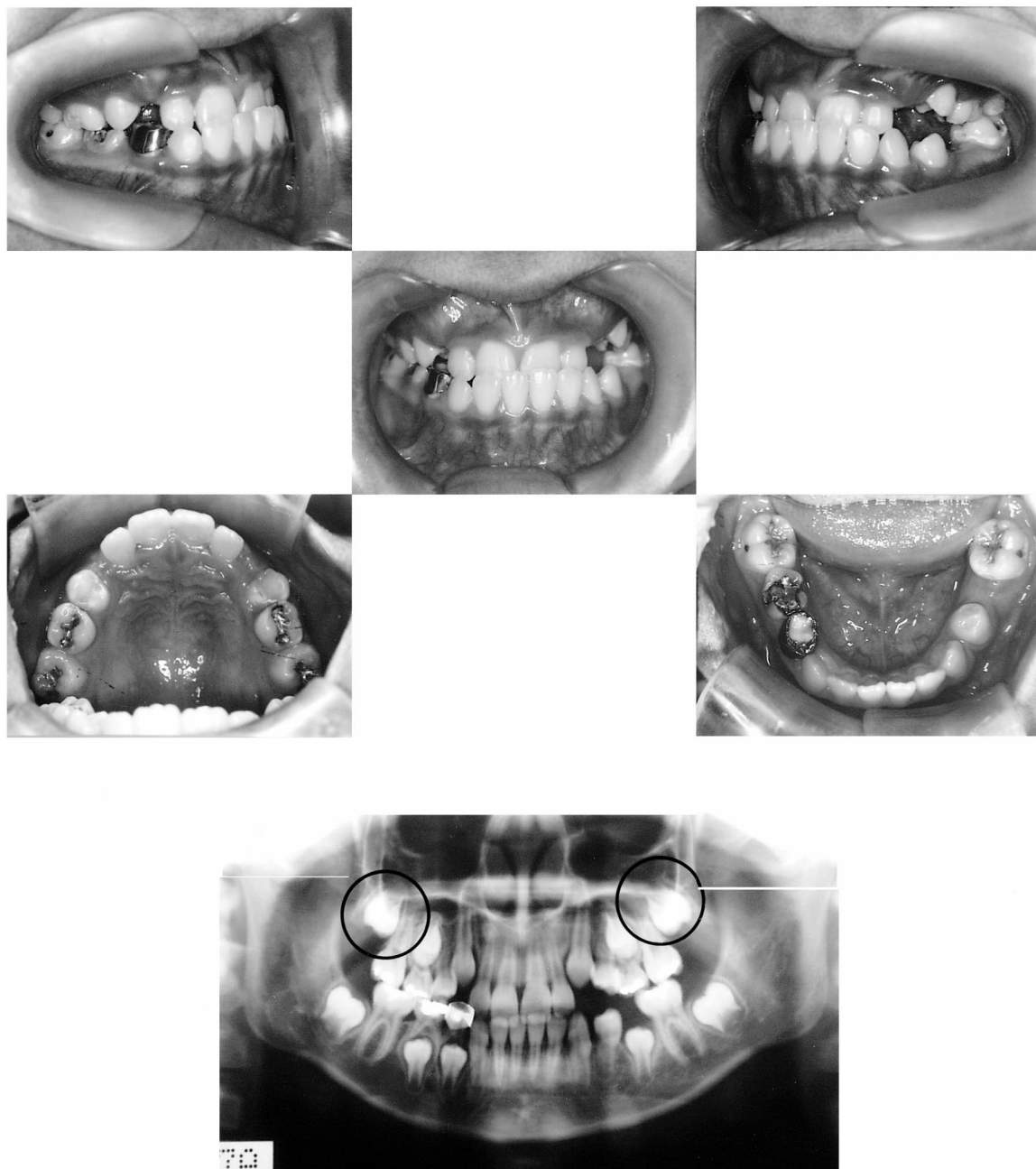
The mean TDS for the maxillary first molar ( $7.7 \pm 0.9$ ) was significantly smaller than the respective STDS ( $9.0 \pm 0.8$ ,  $P < .01$ ). The mean TDS for the maxillary second molar ( $6.8 \pm 0.7$ ) was also significantly smaller than the respective STDS ( $7.9 \pm 0.5$ ,  $P < .01$ ) (Figure 6). There were no significant differences between the 2 scores for the mandibular first and second molars. The STDS for the maxillary second molar was significantly higher than that for the mandibular second molar ( $P < .01$ ), and significantly smaller than that for the mandibular second molar ( $P < .01$ ). In addition, the TDS for the maxillary second molar was significantly higher than that for the maxillary third molar ( $P < .01$ ).

### Case report

A 10-year-old girl presented with Class III malocclusion and a concave type profile (Figure 7). A Class III molar relationship and an anterior cross bite were noticed at the first visit and the insufficient dental arch length was present for the maxillary canines. The distolingual cusp in the maxillary first molars was missing (Figure 7). At the age of 10, the STDS are 9 and 8 for the maxillary first and second molars, respectively. In this case, the TDS was 9 and 7.5 for the maxillary first and second molars. There was no critical delay in tooth development (Figure 7); therefore, we did not pay any attention to the timing of the eruption of the second molars. The anterior cross bite was easily corrected by 6-months of functional appliance therapy. Labial movement of the anterior teeth obtained the dental arch length for the maxillary canines.

At 12 years of age (Figure 8), the facial profile was of the straight type. All permanent teeth except the second molar had erupted and occluded in a Class I relationship. At the age of 12.5 years, the STDS is 9 for the maxillary second molar. In this case, however, root formation of the maxillary second molars had only reached half way and the TDS was 7.5. Delay of root formation and eruption are





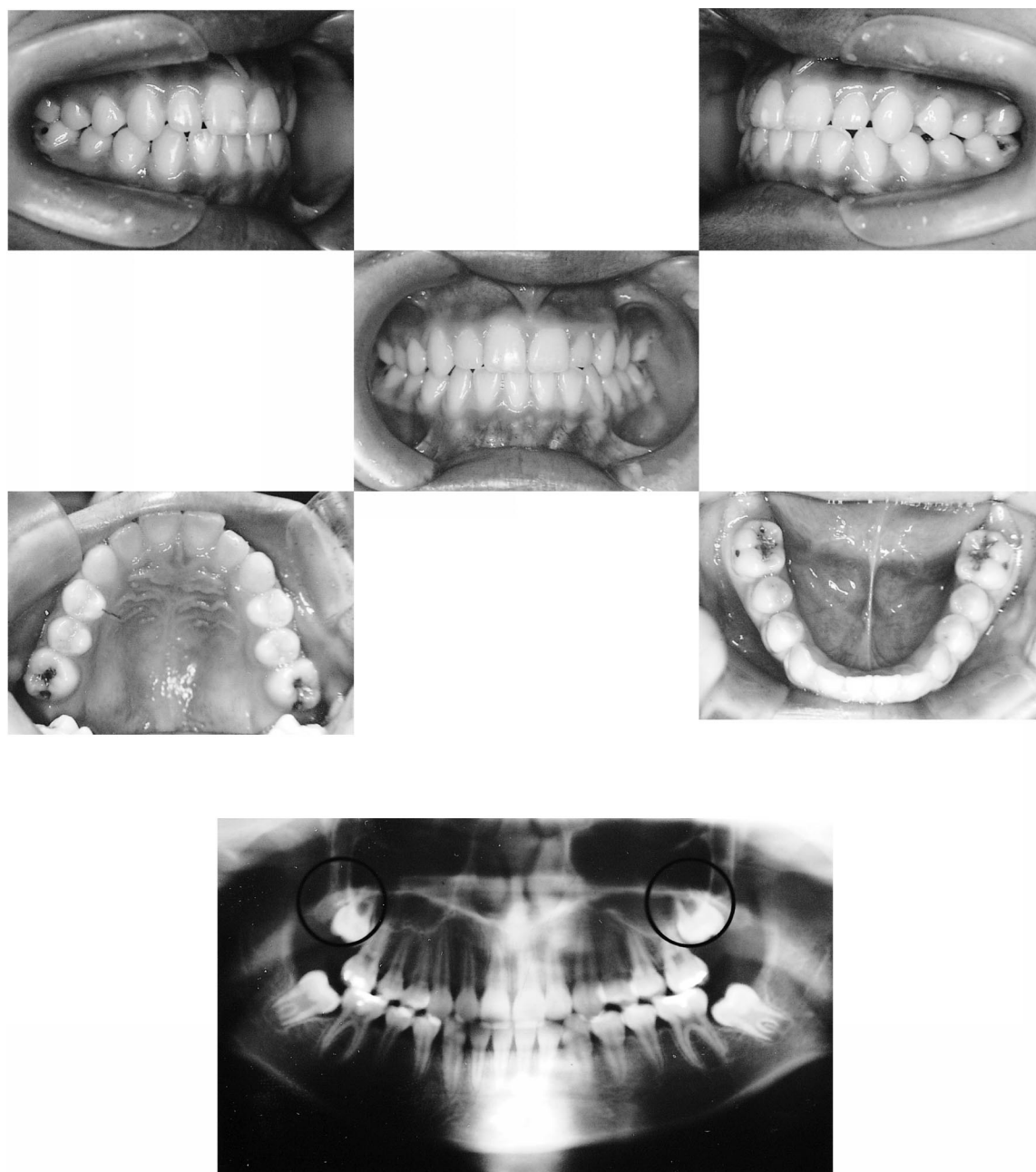
**FIGURE 7.** A preventative example of a 10-year-old girl with Class III malocclusion.

meaningful to treatment (Figure 8). We decided to wait for the eruption of the second molar and, accordingly, we postponed active treatment with multiple bracket appliances until 15 years of age when the maxillary second molars had erupted and mandibular growth had ceased. At this time, an appliance was on all teeth including the second molars. All active appliances were removed at 17 years of age and fixed lingual retainers were placed (Figure 9). The maxillary third molars were missing. Superimposition of traced cephalograms showed downward growth of the total face, which represented improvement of Class III malocclusion (Figure 10).

## DISCUSSION

The morphological evolution in the posterior teeth is of biochemical and anthropological interest and has clinical significance in orthodontic diagnosis and treatment. The dominant role of genes in the etiology of dental anomalies such as missing and malformed teeth is explained by sexual and racial differences in these frequencies. The reduction of the cusp of the maxillary first molar is one form of dental anomaly.<sup>1,2</sup>

Many studies have reported the presence of sexual differences in the size and shape of the molar and agenesis of

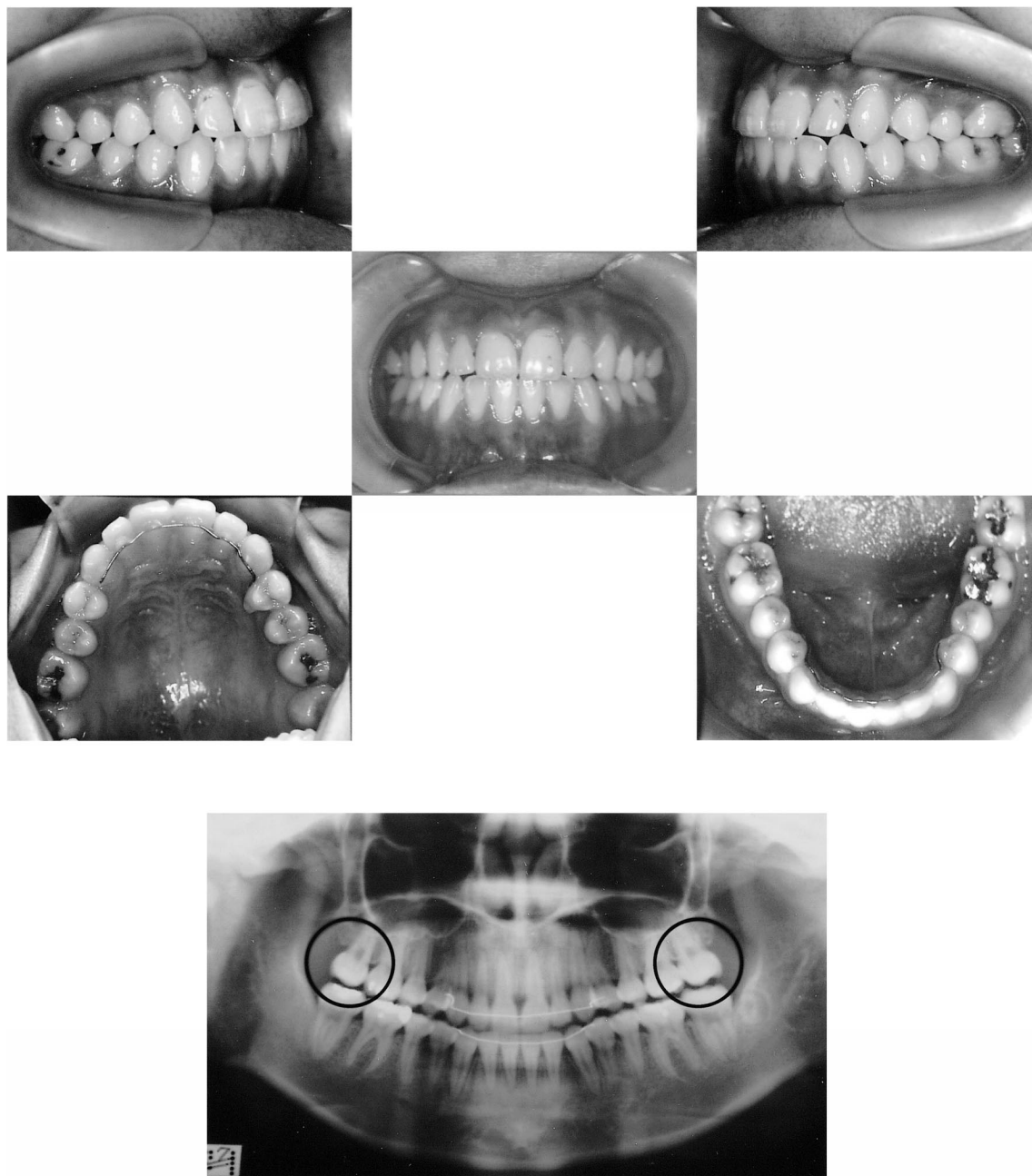


**FIGURE 8.** Photographs and panoramic X-ray film of the same case shown in Figure 7 taken at 12 years and 5 months of age.

the third molars.<sup>4-6</sup> Our results showed that the reduction of the hypocone of the maxillary first molar was more frequent in female patients than in male patients. In accordance with the morphological change of the tooth crown, the third molar was congenitally missing. This is evidence of the heritable incidence of dental anomalies and is supported by the hypothesis that the genetic influence diminishes with increasing distance from the more mesial molar within the ontogenetic field and the impact of the environmental factor increases in the first molar.<sup>9,10</sup> Macho and Moggi-Cecchi<sup>20</sup> analyzed molar size and shape from the first to the third molar. They reported that their findings

were in agreement with the field theory and the environmental hypotheses, although the theory and hypotheses could not explain all of the results. On the other hand, tooth development and initiation have become less dependent on environmental factors and teeth in different positions have differentiated from each other.<sup>21,22</sup>

In the present study, root formation of the maxillary and mandibular molars was estimated using Nolla's standard tooth developmental score in subjects less than 13 years of age. The mean TDS at the initial stage was significantly smaller for the maxillary first and second molars than that of the STDS for the equivalent age ( $P < .05$ ). In addition,



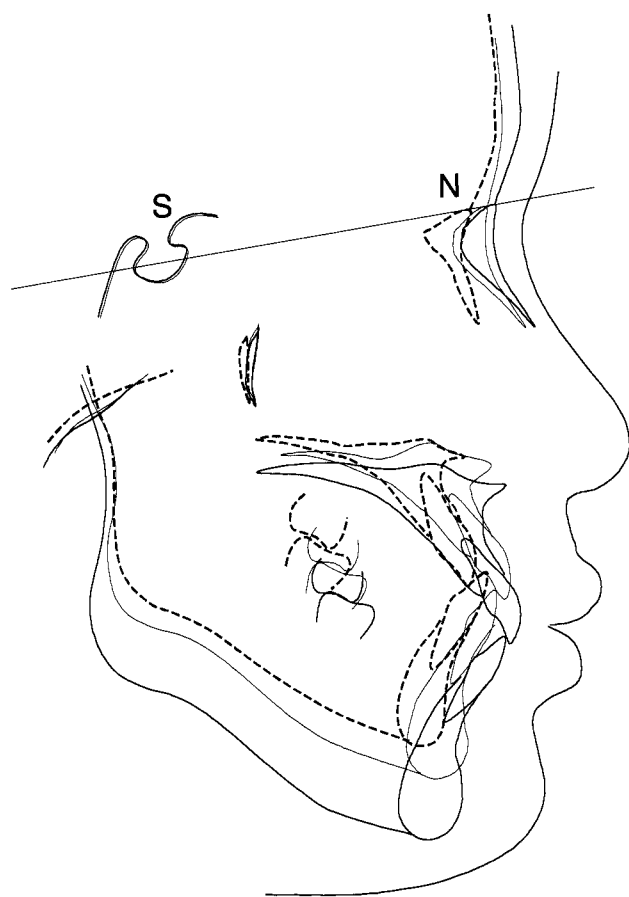
**FIGURE 9.** Photographs and panoramic X-ray film of the same case shown in Figure 7 taken at 17 years of age.

there were no significant differences between the mean TDS of the mandibular molars and their STDS. These findings indicate that the delay of eruption of the molars is ascribed to the delay of their root formation. Nakano et al<sup>23</sup> also found a reduction of the distolingual cusp in delayed development and eruption of the first permanent molar in Japanese children. They concluded that the affected teeth were likely to have been second permanent molars in association with the congenital absence of the first molar. However, if the maxillary first molar is congenitally missing as they argued, the accelerated development of the pre-

sumed maxillary third molar in this study cannot be explained.

There is sufficient evidence for an evolutionary trend toward a reduction of the bony structure of the face. Haruki et al<sup>13</sup> stated that the times of eruption and calcification of the maxillary molars were significantly related to the length of the maxilla. Anderson et al<sup>4</sup> reported that the number of mandibular first molar cusps and the presence of third molars were significantly related to jaw length and prognathism. In our study, the cusp reduction of the maxillary first molar was more frequent in subjects with Class III mal-





**FIGURE 10.** Superimposition of traced cephalograms. Dotted line: before treatment (10 years), solid line: 12 years 5 months, thick solid line: 17 years.

occlusion than those with other malocclusions. In addition, cephalometric analysis revealed that the antero-posterior dimension was significantly less in the Class III evolution group than in the Class III control group. However, we cannot explain the relationship between evolutionary changes of the maxillary molars and the maxilla.

The mechanisms responsible for the initiation of tooth formation, determination of tooth region and tooth identity, and development of cusp number<sup>24</sup> have been examined by molecular signals at various stages of tooth development. Nevertheless, it is not clear whether the factors that affect tooth formation can induce changes in the bony structures or the factors that induce maxillary growth can restrict the development of cusp number. While our study did not investigate these factors, it is important for dental practitioners to keep this evolution evidence in mind.

## CONCLUSION

Since these dental anomalies can be inherited and their functional aspects cannot be ignored, one should take into consideration the family history and early clinical or radiographic detection of such anomalies. A posterior discrep-

ancy, which preserves the facial height, depends on the size and number of molars. Distal movement of the molar usually provides a posterior discrepancy if there is sufficient space for housing the second and third molars. When we found delayed eruption and a reduction in the number of cusps of the maxillary first molar, we could foresee the delayed eruption of the maxillary second molar and missing third molar. This also makes it possible to decide whether to distalize the molar or extract premolars to reduce the tooth jaw discrepancy at a fairly early dentition stage. Early diagnosis of missing, malformed and ectopically erupting teeth is important for effective pediatric and orthodontic treatment.

## REFERENCES

1. Kotsomitis N, Freer TJ. Inherited dental anomalies and abnormalities. *ASDC J Dent Child*. 1997;64:405–408.
2. Harris EF, Bailit HL. The metacone: a morphologic and familial analysis of a molar cusp in humans. *Am J Phys Anthropol*. 1980; 53:349–358.
3. Alvesalo L, Nuutila M, Portin P. The cusp of Cerebella. Occurrence in first upper molars and evaluation of its heritability. *Acta Odontol Scand*. 1975;33:191–197.
4. Anderson BL, Thompson GW, Popovich F. Evolutionary dental changes. *Am J Phys Anthropol*. 1975;43:95–102.
5. Mayhall JT, Alvesalo L. Dental morphology of 45,XO human females: molar cusp area, volume, shape and linear measurements. *Arch Oral Biol*. 1992;37:1039–1043.
6. Kanazawa E, Sekikawa M, Ozaki T. A quantitative investigation of irregular cusps in human maxillary permanent molars. *Am J Phys Anthropol*. 1990;83:173–178.
7. Garn S, Lewis AB, Vicinus JH. Third molar polymorphism and its significance to dental genetics. *J Dent Res*. 1963;42:1344–1363.
8. Bermudezde Castro J. Third molar agenesis in human prehistoric populations of the Canary Islands. *Am J Phys Anthropol*. 1989; 79:207–215.
9. Butler PM. Studies of the mammalian dentition. Differentiation of the post-canine dentition. *London: Proc Zool Soc*; 1939;109B: 1–36.
10. Dahlberg AA. The changing dentition of man. *J Am Dent Assoc*. 1945;32:676–690.
11. Yamada H and Brown T. Contours of maxillary molars studied in Australian aboriginals. *Am J Phys Anthropol*. 1988;76:399–407.
12. Yamada H. and Brown T. Shape components of the maxillary molars in Australian aboriginals. *Am J Phys Anthropol*. 1990;82: 275–282.
13. Haruki T, Kanomi R, Shimono T. The differences in the chronology and calcification of second molars between angle Class III and Class II occlusions in Japanese children. *ASDC J Dent Child*. 1997;64:400–404.
14. Carlson DS and van Gerven DP. Masticatory function and post-pleistocene evolution in Nubia. *Am J Phys Anthropol*. 1977;46: 495–506.
15. Moffitt AH. Eruption and function of maxillary third molars after extraction of second molars. *Angle Orthod*. 1998;68:147–152.
16. Sato S. Case report: developmental characterization of skeletal Class III malocclusion. *Angle Orthod*. 1994;64:105–111.
17. Sato S, Sasaguri K, Kamoi S, Goto M, Suzuki Y. Importance of posterior tooth-to-denture base discrepancy in the development of



- skeletal open-bite malocclusion. *Jap J Ortho Soc.* 1990;49:322–330.
18. Turner CG II, Nichol RC, Scott RG. Scoring procedures for key morphological traits of the permanent dentition: the Arizona State University dental anthropology system. In: Kelley M, Larsen CS. *Advances in Dental Anthropology*. New York, NY: Wiley Liss Inc; 1991:13–31.
  19. Nolla C. Development of the permanent teeth. *J Dent Child.* 1960;27:254–266.
  20. Macho GA, Moggi-Cecchi J. Reduction of maxillary molars in Homosapiens: a different perspective. *Am J Phys Anthropol.* 1992;87:151–159.
  21. Butler PM. Ontogenetic aspects of dental evolution. *Int J Dev Biol.* 1995;39:25–34.
  22. Huysseune A, Sire JY. Evolution of patterns and processes in teeth and tooth-related tissues in non-mammalian vertebrates. *Eur J Oral Sci.* 1998;106Suppl 1:437–481.
  23. Nakano K, Matsuoka T, Takahashi A, Matsumura M, Sobue S, Ooshima T. Delayed development or congenital absence of a single first permanent molar in Japanese child patients. *Int J Paediatr Dent.* 1999;9:271–276.
  24. Jernvall J, Thesleff I. Reiterative signaling and patterning during mammalian tooth morphogenesis. *Mech Dev.* 2000;92:19–29.