

# The Effect of Chronic Renal Insufficiency on Orthodontic Tooth Movement in Rats

Mohsen Shirazi, DMD; Mahin Khosrowshahi, DMD; Ahmad-Reza Dehpour, PhD

**Abstract:** The purpose of this study was to determine the effects of impaired renal function on the amount of orthodontic tooth movement (OTM) in a rat model of renal insufficiency (RI). The animals were divided into three groups: a control unoperated group in which only OTM was done, a sham-operated group, and an RI group. OTM was done two weeks after performance of the sham operation or the surgery to induce RI. Renal failure was induced by electrocoagulation of one kidney cortex followed by contralateral nephrectomy. A fixed orthodontic appliance consisting of a 5 mm length of nickel-titanium closed-coil spring was ligated between the maxillary right incisor and first molar to deliver an initial mesial force of 60 g. Four weeks after RI induction, the amount of tooth movement was estimated by measuring the space created between the first and second molars on a stone cast. Bone density was measured by optical densitometry on radiographs and serum parathyroid hormone (PTH) was measured with a radioimmunoassay method. The results showed that induction of RI significantly increased both OTM ( $P < .05$ ) and PTH levels ( $P < .01$ ), although there was no significant difference in bone density by optical densitometry between the unoperated, sham-operated, and RI groups four weeks after RI induction. The results suggest that an increase of bone-remodeling activities, as evident from a significantly higher level of PTH, may be responsible for increase in tooth movement. (*Angle Orthod* 2001;71:494–498.)

**Key Words:** Orthodontic tooth movement; Renal insufficiency; Rat

## INTRODUCTION

Orthodontic tooth movement (OTM) causes a gradual remodeling of the supporting alveolar bone.<sup>1</sup> When an orthodontic force is applied to a tooth, the alveolar bone on the pressure side undergoes successive cycles of bone resorption and formation, while bone on the tension side predominantly undergoes continuous bone formation. A complex process induces bone resorption.<sup>2</sup> The bone resorption process can be stimulated by various local hormonal factors including prostaglandins,<sup>3</sup> parathyroid hormone (PTH),<sup>4</sup> 1,25-dihydroxy vitamin D<sub>3</sub>,<sup>5</sup> interleukin-1,<sup>6</sup> and interleukin-6.<sup>7</sup> Effects of systemic administration of L-thyroxine<sup>8</sup> and local administration of prostaglandins,<sup>9–11</sup> vitamin D<sub>3</sub>,<sup>12,13</sup> and osteocalcin<sup>2</sup> on experimental tooth movement have been studied. In addition to these local factors, tooth

movement also seems to depend on calcium metabolism of alveolar bone, and systemic alteration of bone metabolism may also play an important role in its remodeling activities.<sup>15,16</sup>

The role of bone metabolism in controlling tooth movement has not been considered seriously however. This is largely because of the difficulty in altering bone metabolism systemically.<sup>14</sup> One of the systemic situations that alters calcium metabolism in bone tissue is chronic renal failure.<sup>16</sup> Renal insufficiency (RI), as a bone metabolic disease, is expected to influence bone manipulative procedures such as orthodontics. However, experimental studies that show the effect of RI on OTM have not been reported. The purposes of this study were to determine the effect of RI on the rate of OTM and bone density in a rat model of chronic RI.

## MATERIALS AND METHODS

### Animals

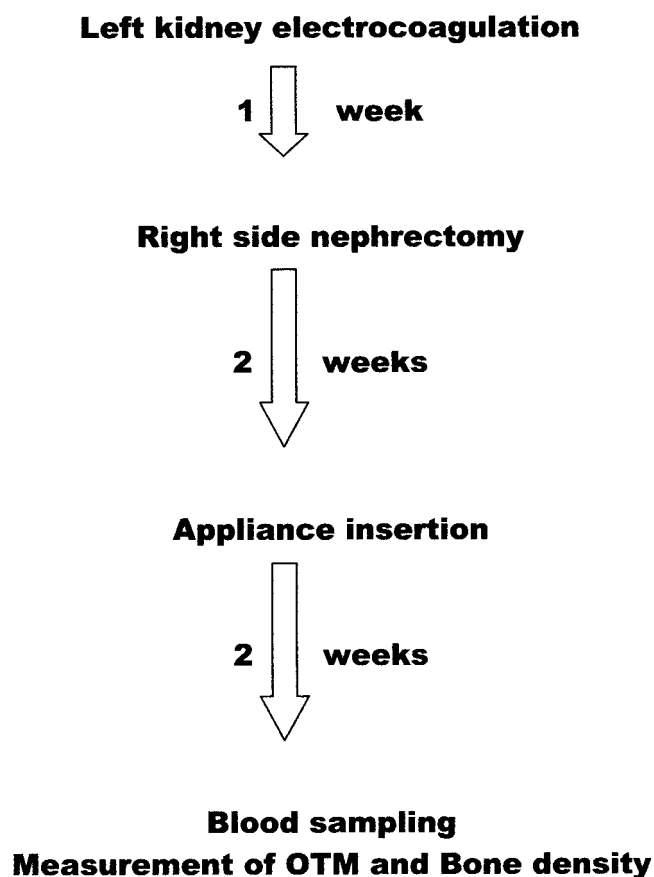
Forty male Sprague-Dawley rats weighing 250–300 g were randomly divided into three groups: (1) control unoperated group ( $n = 10$ ), in which only OTM was done; (2) sham-operated group ( $n = 10$ ); and (3) RI group ( $n = 20$ ). OTM was done after sham surgery and a RI induction surgery in the last two groups, respectively. The animals were exposed to a natural light cycle and had free access to water

From the Department of Orthodontics, School of Dentistry (Dr Shirazi) and Department of Pharmacology, School of Medicine (Dr Dehpour), Tehran University of Medical Sciences, Tehran, Iran, and the Department of Orthodontics, School of Dentistry, Gilan University of Medical Sciences, Gilan, Iran (Dr Khosrowshahi).

Corresponding author: A. R. Dehpour, PhD, Department of Pharmacology, School of Medicine, Tehran University of Medical Sciences, PO Box: 13145-784, Tehran, Iran (e-mail: Dehpour@medscape.com).

Accepted: March 2001. Submitted: September 1999.

© 2001 by The EH Angle Education and Research Foundation, Inc.



**FIGURE 1.** Sequence of operations carried out on rats in the renal insufficiency group. OTM indicates orthodontic tooth movement.

and standard rat food. The protocol of the interventions performed in the RI group is shown in Figure 1.

### Surgery

RI was surgically induced by electrocoagulation of one kidney cortex followed by contralateral nephrectomy as previously described by Boudet et al.<sup>17</sup> After intraperitoneal administration of 50 mg/kg ketamine hydrochloride and 10 mg/kg xylazine anesthesia, a long incision was made in the costovertebral angle and the left kidney was exposed. The adipose capsule was removed carefully, avoiding injury of the adrenal gland. The entire cortex of the kidney, except 2 mm around the hilum, was electrocoagulated to a depth of 1–2 mm with avoidance of tissue carbonization. One week later, a right nephrectomy was done. In the sham-operated group, both kidneys were only decapsulated without electrocoagulation or nephrectomy.

### Placement of orthodontic appliances

Two weeks after the induction of RI, orthodontic appliances were placed in test and control animals. The appliance design was similar to that described by Leiker et al,<sup>11</sup> consisting of a 5 mm length of nickel-titanium closed-coil

spring (NiTi, 3M Unitek, Monrovia, Calif, Hitek, 0.006 × 0.022 inch) ligated and activated between the maxillary right first molar and incisor to deliver an initial measured force of about 60 g.<sup>8,11</sup> Because of the flat load-deflection curve of these springs, they were not reactivated during the 2-week period of the experiment. In order to minimize the distal movement of the right incisor and reinforce the anterior anchorage, the right and left incisors were joined with composite resin and acted as a unit.

### Measurement of tooth movement

Two weeks after appliance insertion, the rats were anesthetized with ether. Skull radiography and blood sampling were performed before decapitation. A plaster replica of the maxillae, including the molars, was made for each rat.<sup>2,18</sup> A polysiloxane impression was taken immediately after removal of the appliance and poured with Vel-Mix (KerrLab, Orange, Calif). The mesiodistal space between the distal surface of the first and the mesial surface of the second molar was measured on the cast with a standard millimeter interproximal gauge. All of the rats had tight contacts between the molars initially.

### Creatinine, urea, and PTH assays

At the time of sacrifice, blood was obtained by intracardiac puncture. Serum creatinine and urea levels were measured with an autoanalyzer (Technicon 500, Technicon Corporation, Emeryville, Calif). Levels of serum immunoreactive PTH were determined with a specific kit (Intact PTH DSL-8000, Nichols Institute Diagnostics, San Juan Capistrano, Calif) by a radioimmunoassay method.

### Bone densitometry

At the end of the experiment, lateral skull radiographs were obtained using a specially made cephalostat and occlusal fast films. The radiographic features and films were the same for all animals (50 kV; 10 mA; 0.3 seconds; film-tube distance, 50 cm). Bone density was determined by optical densitometry at predetermined points.<sup>19</sup> The first point was on the superior posterior part of the skull, the second behind the maxillary molars, and the third on the lower border of mandible beneath the first molar.

### Statistical analysis

The method used for assessing OTM was evaluated for reliability using a double determination and a calculation of a correlation coefficient (*r*). Data obtained from OTM, biochemical factors, and optical bone densitometry are expressed as mean ± SEM. Statistical differences between the means of the groups were evaluated using 1-way analysis of variance (ANOVA) followed by the Student Newman-Keuls test for multiple comparisons. A *P* value less than 0.05 was considered significant.

**TABLE 1.** Comparison of Weight Changes (g) for the Experimental Groups\*

Group	Duration After Intervention			
	Day 1	Week 1	Week 3	Week 5
RI (n = 13)	270 ± 5	273 ± 4	260 ± 5	275 ± 6
Sham operated (n = 8)	273 ± 5	275 ± 5	280 ± 4	279 ± 6
Unoperated (n = 9)	268 ± 4	271 ± 5	275 ± 6	280 ± 5

\* Data are expressed as mean ± SEM. RI indicates renal insufficiency.

**TABLE 2.** Comparison of Urea, Creatinine, and Parathyroid Hormone Levels for the Experimental Groups 4 Weeks After Induction of Renal Insufficiency\*

Groups	Urea, mg/dL	Creatinine, mg/dL	PTH, pg/mL
RI (n = 13)	123 ± 5	1.20 ± 0.08	152 ± 20
Sham operated (n = 8)	39 ± 1 <sup>†</sup>	0.82 ± 0.08 <sup>‡</sup>	46 ± 12 <sup>§</sup>
Unoperated (n = 9)	53 ± 3 <sup>†</sup>	0.80 ± 0.07 <sup>‡</sup>	52 ± 14 <sup>§</sup>

\* Data are expressed as mean ± SEM. PTH indicates parathyroid hormone; RI, renal insufficiency.

<sup>†</sup>  $P < .001$  compared with RI group.

<sup>‡</sup>  $P < .05$  compared with RI group.

<sup>§</sup>  $P < .01$  compared with RI group.

## RESULTS

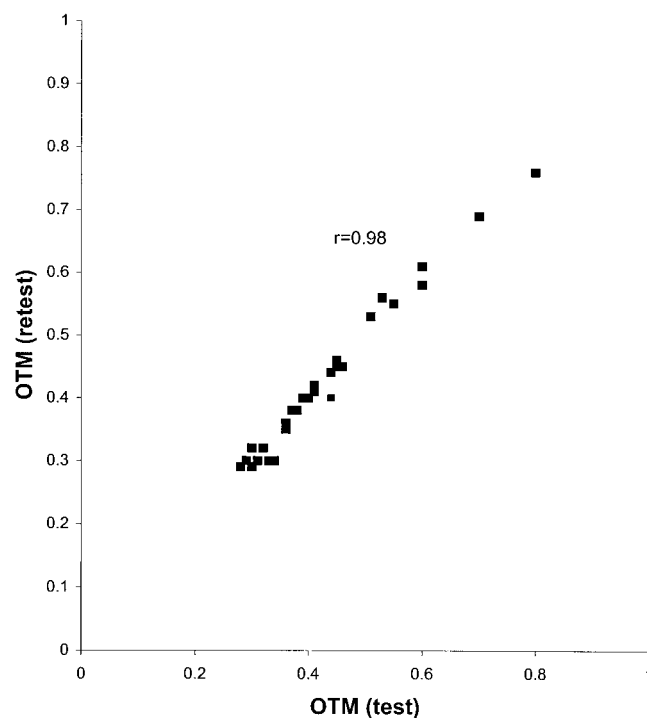
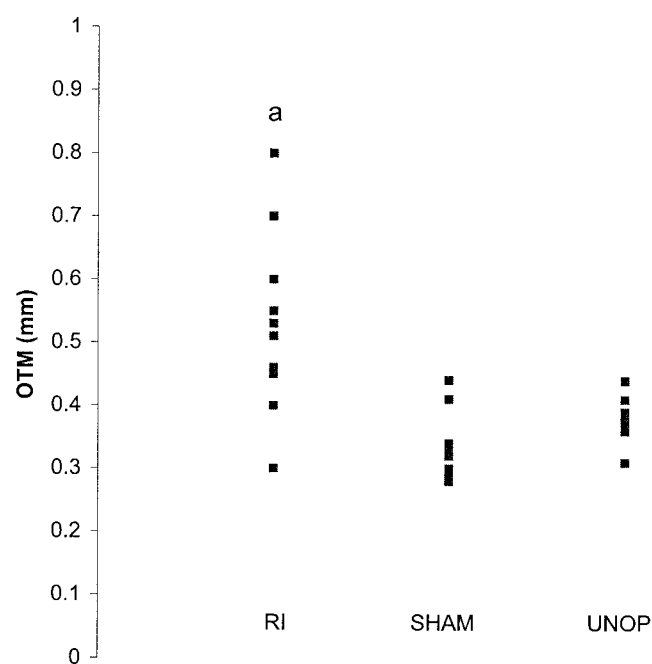
By the end of the experiment, six rats had died in the RI group (one rat after electrocoagulation, four rats after nephrectomy due to hemorrhage during surgery, and one rat during the tooth-movement period). Appliance failure was noticed in four rats (one in the RI group, two in the sham-operated group, and one in the control group). The final size of the RI, sham-operated, and control groups was 13, 8, and 9 rats, respectively. As shown in Table 1, the rats in the RI group lost weight for one week after nephrectomy, but they subsequently began to regain weight.

### Biochemical results

The results obtained from the measurement of creatinine, urea, and PTH in the control and test groups at the end of experimental period are shown in Table 2. In the RI group, there were statistically significant increases in levels of serum creatinine ( $P < .05$ ), urea ( $P < .001$ ), and PTH ( $P < .01$ ) when compared with levels in the control and sham-operated groups. The difference in these parameters between control and sham-operated groups was not significant.

### Tooth movement

As shown in Figure 2, the method of assessing OTM was evaluated using correlation analysis for reliability, which showed a highly significant degree of reproducibility ( $r = 0.98$ ,  $P < .001$ ). Figure 3 shows the rate of tooth movement in the RI, sham-operated, and control groups.

**FIGURE 2.** Scatter diagram for evaluation of reliability of orthodontic tooth movement (OTM) measurement using double determinations of OTM in a double-blind manner and calculation of the correlation coefficient,  $r$  ( $r = 0.98$ ,  $P < .001$ ).**FIGURE 3.** Comparison of amounts of tooth movement between renal insufficient (RI), sham-operated (SHAM), and unoperated (UNOP) rats (a indicates  $P < .05$ ).

**TABLE 3.** Comparison of Optical Density for the Experimental Groups in 3 Predetermined Points on Superior Posterior Parts of Skull, Behind the Maxillary Molars, and on the Lower Border of Mandible\*

Group	Point of Measurement		
	Skull	Maxilla	Mandible
RI (n = 13)	1.54 ± 0.01	1.63 ± 0.03	1.49 ± 0.01
Sham operated (n = 8)	1.54 ± 0.03	1.72 ± 0.03	1.55 ± 0.02
Unoperated (n = 9)	1.55 ± 0.02	1.70 ± 0.02	1.52 ± 0.01

\* Data are expressed as mean ± SEM.

The increased amount of tooth movement observed in the RI group was statistically significant ( $P < .05$ ) in comparison with that in the control and sham-operated groups, but there was no significant difference in OTM between the sham-operated and unoperated groups.

### Optical bone densitometry

The results of bone optical densitometry are shown in Table 3. There were no significant differences in the optical density of the skull, maxillary, and mandibular points between the groups.

### DISCUSSION

As shown in Table 2, significant increases of creatinine ( $P < .05$ ) and urea ( $P < .001$ ) as determinants of kidney function confirmed that induction of RI with this method had been successful. According to Boudet et al,<sup>17</sup> rats with 4 weeks of RI do not require special supportive treatment, such as renal dialysis. This is because this model induces long-lasting changes in patterns of renal function evolution, which need several months to reach to end-stage renal disease requiring special diet and supportive care.

Activation of the orthodontic appliance produced a remodeling response in periodontal tissues and alveolar bone that allowed for tooth movement. The biologic response was altered enough in RI rats to produce a statistically significant increase in tooth movement at the end of the experiment as compared with other groups ( $P < .05$ ). The amount of tooth movement between sham-operated and control groups did not differ significantly and indicated that the RI group differed from the others because of the induced impairment in renal function and not because of the surgical procedures.

Since the appliance force was similar for all groups, the increased rate of tooth movement in RI rats can be attributed to alteration of bone metabolism. Multiple factors are operative in renal disease that initiate and perpetuate the derangements in bone metabolism. These biochemical events include calcium malabsorption, parathyroid hyperfunction, defective renal synthesis of biologically active vitamin D3 metabolites, and chronic metabolic acidosis.<sup>16,20,21</sup> Hyperphosphatemia (as a main factor) and hypocalcemia

(as a second major stimulator) develop in chronic RI and stimulate secretion of PTH, leading to a state that is called secondary hyperparathyroidism. Secondary hyperparathyroidism is initiated in early RI and leads to an increase in number and activity of both osteoblasts and osteoclasts, resulting in an increased bone turnover.<sup>21</sup>

Therefore, as shown in Table 2, parathyroid hyperfunction may be responsible for the increased bone remodeling activities and thus the increase of OTM in the RI group. This finding supports the findings of earlier studies in which increased tooth movement was observed in dogs fed a high-phosphorus, low-calcium diet<sup>14</sup> and in calcium-deficient lactating rats.<sup>15</sup>

Metabolic acidosis also can contribute to changes of bone metabolism. Metabolic acidosis causes an increase in calcium and phosphate excretion, resulting in a negative balance for these minerals and a net acid retention. The source of calcium is almost certainly bone. Persisting metabolic acidosis leads to the consumption of bone buffers, mainly bicarbonate, and calcium dissolution by physicochemical and cell-mediated mechanisms in advanced chronic renal failure.<sup>20,21</sup> Although chronic metabolic acidosis induces bone resorption, its action on bone in early stages of chronic RI has not been clearly understood.

In spite of an alteration in bone metabolism, the results of optical densitometry did not show a significant difference in bone density between the test and control rats (Table 3). Because we used a different technique to measure bone density, we cannot compare our results with others. However, we can say that four weeks after induction of RI, bone density did not decrease enough to be reflected on radiographic films, but this could have been due to a relative insensitivity of the method.

Russell and Avioli<sup>16</sup> showed maturational defects both in collagen and in mineral as early as two weeks after induction of uremia while total bone calcium, inorganic phosphate, and hydroxyproline content were unchanged. This is in agreement with our result, since the total amount of bone mineral and organic matrix remained unchanged, and the optical densitometry showed no difference between the groups. Therefore, it seems that an increase of OTM in the early stages of RI is not because of bone mineral loss. Of course, there is no doubt that if RI lasts more time, bone mineral loss will be enough to be revealed on radiographic films.

In addition to the possible role of PTH in increased tooth movement in experimental RI, other factors may be implicated in generation of this phenomenon. It is established that a decrease of functional renal mass in uremic rats leads to a decrease in 1,25 dihydroxy vitamin D3 synthesis, and this active metabolite of vitamin D3 is important in maintaining the integrity of bone collagen.<sup>16</sup> It has also been shown that the rate of synthesis of soft tissue mature collagen decreases with calcium and vitamin D3 deficiency.<sup>16</sup> Therefore, a decreased synthesis of 1,25 vitamin D3 may

partly be responsible for the increase of OTM. Interestingly, it has been shown that the active metabolite of vitamin D3 could not be a causative factor for bone metabolic derangements in RI, since administration of vitamin D3 active metabolites fails to completely eliminate bone defects in subjects with RI.<sup>16</sup> Thus other factors such as some toxic products or defects in enzymatic activity related to collagen maturation or osteoblastic activity may be present that induce bone defects in RI.

It has also suggested that circulating and locally produced cytokines and growth factors such as insulin-like growth factors have a potential role in the pathogenesis of the skeletal complications of RI.<sup>21</sup> The role of these factors in increasing tooth movement by altering bone remodeling must be taken into consideration in experimental studies.

We suggest that further experiments are needed to investigate bone maturation and its remodeling activities as well as the causative factors for bone defects in RI. This research might find processes or factors that could accelerate the rate of tooth movement without significant bone mineral loss.

## CONCLUSION

Four weeks after impairment in kidney function, the amount of tooth movement and PTH significantly increased, whereas radiograph-based optical densitometry did not show significant difference between bone density in RI and control rats.

## REFERENCES

1. Norevall LI, Forsgren S, Matson L. Expression of neuropeptides during and after orthodontic tooth movement in rat. *Eur J Orthod*. 1995;17:311–325.
2. Kobayashi Y, Sakai H, Matak S, Kato Y. Effects of local administration of osteocalcin on experimental tooth movement. *Angle Orthod*. 1998;68:259–265.
3. Klein DC, Raisz LG. Prostaglandins: stimulation of bone resorption in tissue culture. *Endocrinology*. 1970;86:1436–1440.
4. Raisz LG, Trummel CL, Simmons H. Induction of bone resorption in tissue culture: prolonged response after brief exposure to parathyroid hormone or 25-hydroxycholecalciferol. *Endocrinology*. 1972;90:744–751.
5. Raisz LG, Trummel CL, Holick MF, Deluca HF. 1,25 Dihydroxy cholecalciferol: a potent stimulator of bone resorption in tissue culture. *Science*. 1972;175:768–769.
6. Heath JK, Saklatvala J, Meikle MC, Atkinson SJ, Reynolds JJ. Pig interleukin-1 (catabolin) is a potent stimulator of bone resorption in vitro. *Calcif Tissue Int*. 1985;37:95–97.
7. Ishimi Y, Miyaura C, Jin CH, Akatsu T, Abe T, Nakamura Y. IL-6 is produced by osteoblast and induces bone resorption. *J Immunol*. 1990;145:3297–3303.
8. Shirazi M, Dehpour AR, Jafari F. The effect of thyroid hormone on orthodontic tooth movement in rats. *Clin Pediatr Dent*. 1999;23:259–264.
9. Yamasaki K, Shibata Y, Fukahara T. The effects of prostaglandins on experimental tooth movement in monkeys. *J Dent Res*. 1982;62:1444–1460.
10. Lee W. Experimental study of the effect of prostaglandin administration on tooth movement with particular emphasis on the relationship to the method of PGE<sub>1</sub> administration. *Am J Orthod Dentofac Orthop*. 1990;98:231–241.
11. Leiker BJ, Currier GF, Sinha PK. The effect of exogenous prostaglandins on orthodontic tooth movement in rats. *Am J Orthod Dentofac Orthop*. 1995;108:380–388.
12. Collins MK, Sinclair PM. The local use of vitamin D to increase the rate of orthodontic tooth movement. *Am J Orthod Dentofac Orthop*. 1988;94:278–284.
13. Takano-Yamamoto T, Kawakami M, Kobayashi Y, Yamashiro T, Sakuda M. The effect of 1,25 dihydroxy cholecalciferol on osteoclast numbers in orthodontically treated rats. *J Dent Res*. 1992;71:53–59.
14. Midgett RJ, Shaye R, Fruge JF. The effect of altered bone metabolism on orthodontic tooth movement. *Am J Orthod*. 1981;80:256–262.
15. Goldie RS, King GJ. Root resorption and tooth movement in orthodontically treated, calcium-deficient and lactating rats. *Am J Orthod*. 1984;85:424–430.
16. Russell JE, Avioli LV. Effect of experimental chronic renal insufficiency on bone mineral and collagen maturation. *J Clin Invest*. 1972;51:3072–3078.
17. Boudet J, Man NK, Pils P, Sausse A, Funck-Brentano JL. Experimental chronic renal failure in the rat by electrocoagulation of the renal cortex. *Kidney Int*. 1978;14:82–86.
18. Igarashi K, Mitani H, Adachi H, Shinoda H. Anchorage and retentive effects of a bisphosphonate on tooth movement in rats. *Am J Orthod Dentofac Orthop*. 1994;106:279–289.
19. Hildebolt CF, Bartlett TQ, Brunson BS, Hente NL, Gravier MJ, Walkup RK, Shout MK. Bitewing-based alveolar bone densitometry: digital imaging resolution requirements based alveolar bone densitometry. *Dentomaxillofac Radiol*. 1994;23:129–134.
20. Caldas A, Richard MJ, Maniar S, Laouari D, Dechaux M, Favier A, Kleinknechte Z. Bone loss in chronic renal failure and chronic metabolic acidosis. *Biol Trace Elem Res*. 1992;32:339–348.
21. Hoyland JA, Picton ML. Cellular mechanisms of renal osteodys trophy. *Kidney Int Suppl*. 1999;73:S8–S13.