

Effects of Maxillary Protraction on Craniofacial Structures and Upper-Airway Dimension

Shigetoshi Hiyama, DDS, PhD^a; Naoto Suda, DDS, PhD^b; Masako Ishii-Suzuki, DDS, PhD^c;
Satoru Tsuiki, DDS, PhD^a; Mitsunobu Ogawa, DDS^d; Shoichi Suzuki, DDS, PhD^e;
Takayuki Kuroda, DDS, PhD^f

Abstract: This study was conducted to examine the effect of treatment with a maxillary protraction appliance on the development of the craniofacial structures and upper-airway dimensions. A total of 25 patients (mean age: 9.8 years) with Class III malocclusions were evaluated by the use of lateral cephalograms. A significant increase in maxillary forward growth, inhibition of mandibular forward growth, and clockwise rotation of the mandible were observed. The maxillary incisors were significantly proclined and the mandibular incisors significantly retroclined. A multiple-regression analysis revealed that maxillary growth had a significant positive effect on the superior upper-airway dimension. These findings indicate that the superior upper-airway dimension can be altered during maxillary protraction. (*Angle Orthod* 2002; 72:43–47.)

Key Words: Maxillary protraction, Growth, Craniofacial morphology, Upper airway, Lateral cephalogram

INTRODUCTION

A maxillary protraction appliance (MPA) is used to treat skeletal Class III growing patients with maxillary hypoplasia. Previous studies have demonstrated that this appliance can facilitate maxillary growth.^{1–3} In addition, other various effects of the appliance on craniofacial growth, such as counter-clockwise rotation of the palatal plane, inhibition of anterior mandibular growth, clockwise rotation of the mandible, labial tipping of maxillary incisors, lingual tipping of mandibular incisors and mesial movement and elongation of maxillary molars, have been reported.^{4–14} The combination of these changes improves the maxillo-man-

dibular jaw relation and the occlusal balance of the upper and lower dentition. Although many studies have reported the skeletal and dental changes associated with treatment using an MPA, the relationship between maxillary growth and the change in the upper-airway dimension during MPA treatment has not been well discussed.

Mandibular growth has a favorable influence on the upper-airway dimension.^{15,16} Recently, Özbek et al¹⁷ reported that the sagittal dimension of the upper airway was significantly increased as a consequence of treatment with a functional appliance for growing patients with Class II malocclusion. They also suggested that the mandibular growth induced by such treatment had a beneficial effect on the constricted upper airway. In addition, in Apert's syndrome or Crouzon's disease, which are characterized by severe maxillary hypoplasia, it has been suggested that constriction of the upper airway, including the nasal cavity and velopharynx, may be the source of upper-airway obstruction commonly observed in these patients.^{18,19} Considering that mandibular growth has a definite influence on the upper-airway dimension, we can speculate that maxillary growth could also have beneficial effects on the upper airway. In fact, it was recently reported that rapid maxillary expansion could induce a change in the respiratory function and it could be a useful treatment modality for patients with obstructive sleep apnea.²⁰

The purpose of this study was to examine the effect of changes in craniofacial structures on the upper-airway dimension. As an aid in modifying maxillary growth, an MPA was used in the present study.

^a Postdoctoral Fellow, Maxillofacial Orthognathics, Graduate School, Tokyo Medical and Dental University.

^b Assistant Professor, Maxillofacial Orthognathics, Graduate School, Tokyo Medical and Dental University.

^c Part-time lecturer, Maxillofacial Orthognathics, Graduate School, Tokyo Medical and Dental University.

^d Clinical Fellow, Maxillofacial Orthognathics, Graduate School, Tokyo Medical and Dental University.

^e Lecturer, Maxillofacial Orthognathics, Graduate School, Tokyo Medical and Dental University.

^f Professor and Chair, Maxillofacial Orthognathics, Graduate School, Tokyo Medical and Dental University.

Corresponding author: Shigetoshi Hiyama, DDS, PhD, Maxillofacial Orthognathics, Graduate School, Tokyo Medical and Dental University, 5-45 Yushima 1-chome, Bunkyo-ku, Tokyo, 113-8549 Japan. (e-mail: t_ono.ort2@dent.tmd.ac.jp).

Accepted: August 2001. Submitted: January 2001.

© 2002 by The EH Angle Education and Research Foundation, Inc.

MATERIALS AND METHODS

The sample consisted of 25 patients (7 males and 18 females, mean age: 9.8 years) who visited our orthodontic clinic at Tokyo Medical and Dental University. Several orthodontic specialists belonging to our orthodontic clinic treated them under the same orthodontic concept. The sample was collected based on the following criteria: (1) Pre-treatment (T1) and posttreatment (T2: 12 months after T1) lateral cephalograms of good quality; (2) the presence of a skeletal Class III malocclusion, defined as an ANB angle more than one standard deviation smaller than the Japanese average ($ANB = -1.9 \pm 2.0^\circ$);²¹ (3) the subjects were treated with the MPA alone; and (4) no other congenital anomalies or endocrine problems were present. The MPA employed in this study was a combination of chin cap and the Petit type appliance. The bilateral forces were set at 180–250 gm for maxillary protraction and 600–800 gm for mandibular retraction. Patients were instructed to wear the appliance for 12 hours per day.

One experienced orthodontist traced the lateral cephalograms of each patient. Values at T1 and T2 and the differences between the 2 values were evaluated for each variable. Reference points and cephalometric variables in this study are shown in Figure 1. In addition to the conventional cephalometric variables, some specific variables to evaluate the sagittal upper-airway dimension and head posture were defined as:

- **SPPS:** The anteroposterior width of the pharynx measured between the posterior pharyngeal wall and the dorsum of the soft palate on a line parallel to the FH plane (the line through Po and Or) that runs through the middle of the line from PNS to P.
- **MPS:** The anteroposterior width of the pharynx measured between the posterior pharyngeal wall and the dorsum of the tongue on a line parallel to the FH plane that runs through P.
- **IPS:** The anteroposterior width of the pharynx measured between the posterior pharyngeal wall and the dorsum of the tongue on a line parallel to the FH plane that runs through C2i.
- **SN-CVT:** The angle formed by the SN plane and CVT (the line through C2 and C4).

A paired *t*-test was used to compare values at T1 and T2. To evaluate the relation between changes in the upper-airway dimension and craniofacial morphology, a multiple-regression analysis was performed.

RESULTS

Changes in the craniofacial morphology and upper-airway dimension

Table 1 shows the means and standard deviations of each cephalometric variable at T1 and T2, and the differences

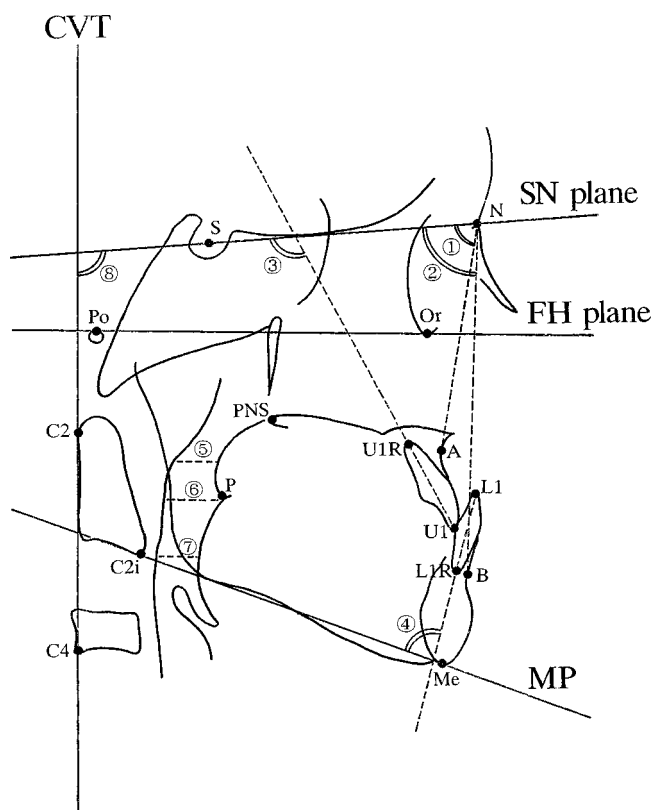


FIGURE 1. Diagrammatic representation of anatomic points and lines used to identify cephalometric variables. U1 indicates the tip of the crown of the maxillary central incisor; U1R, the tip of the root of the maxillary central incisor; L1, the tip of the crown of the mandibular central incisor; L1R, the tip of the root of the mandibular central incisor; P, the tip of the soft palate; C2, the most posterosuperior point on the odontoid process of the axis; C2i, the most anteroinferior point on the body of the second cervical vertebra; and C4, the most posterioroinferior point on the body of the fourth cervical vertebra. ①SNA, ②SNB, ③U1 to SN, ④L1 to MP, ⑤SPPS, ⑥MPS, ⑦IPS, and ⑧SN-CVT.

between them. The mean value of SNA significantly increased from 77.7° to 79.0° ($P < .01$), and that of SNB significantly decreased from 79.7° to 79.0° ($P < .05$). As a consequence of these changes, the mean value of ANB significantly increased from -1.9° to -0.1° ($P < .01$). The mean value of SN-MP at T1 was 39.8° and it increased to 40.3° at T2 ($P = .0644$). The mean value of U1 to SN significantly increased from 104.1° to 110.3° ($P < .01$), which indicated labial tipping of the maxillary incisors. On the other hand, the mean value of L1 to MP significantly decreased from 82.7° to 78.9° ($P < .01$), which indicated lingual tipping of the mandibular incisors. Figure 2 shows changes in the upper-airway dimension and head posture. Both SPPS and MPS width increased in 14 patients and decreased in 11 patients. The IPS width increased in 13 patients and decreased in 12 patients. As a result, no significant changes were demonstrated in the upper-airway dimension. The SN-CVT angle increased in 13 patients and decreased in 12, and again there was no significant change.

TABLE 1. Measurement Values at T1 and T2 in Each Variable and the Differences Between Them

	Mean at T1	SD	Mean at T2	SD	Difference (T2 – T1)	SD	P
SNA	77.7	2.6	79.0	2.6	1.3	0.9	**
SNB	79.7	2.7	79.0	2.9	−0.7	1.1	*
ANB	−1.9	2.0	−0.1	2.4	1.8	1.6	**
SN-MP	39.8	5.5	40.3	5.7	0.5	1.4	NS (<i>P</i> = .0644)
U1 to SN	104.1	6.5	110.3	7.6	6.2	6.6	**
L1 to MP	82.7	8.7	78.9	9.5	−3.8	3.6	**
SPPS	11.3	3.0	11.8	2.1	0.5	3.2	NS
MPS	15.0	4.0	14.7	3.7	−0.3	4.5	NS
IPS	12.6	3.6	12.4	2.5	−0.2	3.9	NS
SN-CVT	99.7	6.1	99.6	8.2	−0.1	8.8	NS

NS indicates not significant.
* *P* < .05, ** *P* < .01.

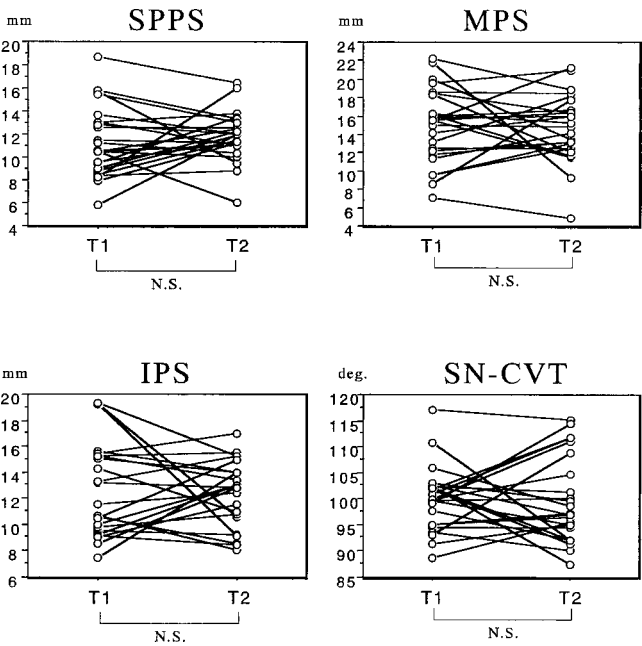


FIGURE 2. Changes in the upper-airway dimension and head posture. T1: Value measured before treatment, T2: Value measured 12 months after T1. N.S.: not significant

Relationship between changes in the craniofacial morphology and upper-airway dimensions

In the multiple-regression analysis, the change in the upper-airway dimension was considered a dependent variable, whereas changes in SNA, SNB, SN-MP, and SN-CVT were selected as independent variables. Then the following regression model can be determined.

$$Y = a + b_1X_1 + b_2X_2 + b_3X_3 + b_4X_4$$

Y: Change in the upper-airway dimension (Δ SPPS or Δ MPS or Δ IPS)
a: Intercept
 b_1, b_2, b_3, b_4 : Regression coefficient
 X_1 : Change in SNA (Δ SNA)

TABLE 2. Results of Multiple-Regression Analysis

	Δ SPPS	Δ MPS	Δ IPS
b_1	.891 (.263*)	.271 (.057)	.807 (.193)
b_2	.657 (.234)	1.326 (.337)	.918 (.251)
b_3	.023 (.010)	.141 (.045)	.071 (.027)
b_4	.276 (.767**)	.400 (.793**)	.334 (.763**)
R	.80	.74	.78
R ²	.64	.55	.61

$b_1 \sim b_4$ indicate regression coefficients; numbers in parentheses represent standardized regression coefficients; R, multiple correlation coefficients; and R², coefficients of determination.
* *P* < .05, ** *P* < .01.

X_2 : Change in SNB (Δ SNB)
 X_3 : Change in SN-MP (Δ SN-MP)
 X_4 : Change in SN-CVT (Δ SN-CVT)

In all 3 cephalometric variables of upper-airway dimension (SPPS, MPS, IPS), statistically useful regression equations could be established (Table 2). The standardized regression coefficient indicates the magnitude and direction of the influence of an independent variable on a dependent variable excluding the effect of other independent variables. The change in SN-CVT had a significantly positive effect on changes in all variables regarding the upper-airway dimension (*P* < .01). Furthermore, the change in SNA was judged to be a contributing factor that had a significantly positive influence on the change in SPPS (*P* < .05). On the other hand, changes in SNB and SN-MP were not significantly related to the change in the upper-airway dimension.

DISCUSSION

Changes in craniofacial morphology during treatment with the MPA

The orthopedic force of the MPA stimulates cellular activity in circummaxillary sutures and maxillary tubercula,^{1,3} and this facilitates maxillary forward displacement. Several studies have reported the effect of treatment with this appli-

TABLE 3. Correlation Coefficients Between the Change in the SN-CVT and the Change in the Upper-Airway Dimension

	Δ SPPS	Δ MPS	Δ IPS
Δ SN-CVT	.727	.678	.740

Δ indicates the amount of change during treatment.

ance on craniofacial growth. Kim et al¹⁴ studied previous reports regarding the effect of treatment with the MPA and demonstrated that the mean increase in SNA was 1.7° in 14 selected articles, which was slightly larger than that in the present study (1.3°). However, based on the fact that the average change in SNA was very slight when no orthopedic force was applied,²²⁻²⁴ the effect of treatment on maxillary growth may have been observed. On the other hand, the mean decrease in SNB and the mean increase in SN-MP were 0.7° and 0.5°, respectively. These changes were apparently smaller than those in previous reports.^{4,6-8,10,12} Consequently, about 67% of the improvement in the intermaxillary relationship during treatment was due to maxillary forward growth and the remainder was due to the inhibition of mandibular forward growth related to mandibular backward rotation. Silva et al⁷ suggested that the ratio of maxillary anterior displacement to mandibular retroposition was almost 1:1, which was similar to the results of Ishii et al.²⁵ However, this ratio varied considerably in other studies,¹⁴ and there seems to be no common interpretation regarding this issue.

In contrast to the use of a skeletal anchorage such as with implants,²⁶ the concomitant effects of the MPA on the dental arches cannot be avoided because the teeth provide the support for the appliance. Since the MPA was used through a lingual arch appliance set on the maxillary dentition in this study, the maxillary incisors tipped 6.2° labially. Kim et al¹⁴ reported that labial tipping of the maxillary incisors ranged from 0.6° to 5.8° (mean: 2.8°)—less than the mean value in our study. On the other hand, mandibular incisors tipped lingually an average of 3.8° as a result of pressure exerted by the chin cap and soft tissue.

Relationship between changes in the craniofacial morphology and upper-airway dimension

Although no significant changes were demonstrated in the upper-airway dimension during treatment (Figure 2), the upper-airway dimension was likely influenced by changes in head posture.²⁷⁻²⁹ In fact, there was a strong correlation between the changes in head posture and those in the upper-airway dimension (Table 3). Accordingly, it is necessary to control the influence of confounding factors including SN-CVT when we evaluate the actual relationship between changes in the craniofacial morphology and upper-airway dimension.

When we select dependent variables for multiple-regression analysis, we must follow the principle that the sample size should be at least more than 5 times the number of

independent variables to predict the dependent variable accurately.³⁰ Based on this principle, it would be reasonable to restrict the number of independent variables to within 4 in the present study instead of including all cephalometric variables regarding the craniofacial structure. Therefore, in addition to the variable regarding head posture (SN-CVT), skeletal variables such as SNA, SNB, and SN-MP were used as independent variables in this study. Cephalometric variables regarding the denture pattern (ie, U1 to SN and L1 to MP) were not included because the main purpose of MPA treatment is not to change the denture pattern, but rather to control the growth of craniofacial skeletal structures.

The multiple-regression analysis demonstrated that the change in SN-CVT had a significantly positive influence on changes in SPPS, MPS, and IPS. Thus, a greater change in SN-CVT was associated with a greater change in the upper-airway dimension. Moreover, the change in SNA also had a significantly positive effect on the change in SPPS. Thus, a greater forward maxillary growth was associated with a greater increase in the superior upper-airway dimension. Based on the findings in this study, facilitation of maxillary growth in growing patients during MPA treatment could contribute to increase the upper-airway dimension and improve the respiratory function of patients with maxillary hypoplasia.

The present study had no untreated control to compare to the patients who were treated by the MPA because it was extremely difficult to obtain such untreated patients. However, the change in the upper-airway dimension during natural growth should be elucidated to determine whether the increase in the upper-airway dimension is actually related to maxillary growth induced by maxillary protraction. In a previous report, Özbek¹⁷ et al demonstrated that 15 untreated subjects (7 boys and 8 girls, mean age: 11.3 years) showed only negligible changes in the upper-airway dimension during a 1.8-year observation period (mean reduction: 0.44 ~ 0.87 mm). Therefore, the increase in the upper-airway dimension could be related to the increased maxillary growth induced by MPA treatment, whereas we should not anticipate the upper-airway dimension to increase unless the patients were treated with an MPA.

Although the underlying mechanism of the increase in the superior upper-airway dimension by maxillary protraction is unclear, possible explanations include the increase in the volume of the oral cavity possibly induced by increased maxillary forward growth could bring the tongue to a more anterior position. This change in tongue posture could induce the soft palate to a more anterior position, which might result in an increase in the superior upper-airway dimension.¹⁷ Clockwise rotation of the mandible might also influence the tongue posture. The orthopedic force applied by the MPA might induce an anterior displacement of PNS, which could result in a forward move-

ment of the soft palate and an increase in the superior upper-airway dimension.

On the other hand, no significant relationship was found between changes in upper-airway dimensions and those in SNB or SN-MP. It is generally thought that a change in the mandibular position could influence the upper-airway morphology. However, the result of the multiple-regression analysis did not indicate that this change had any significant effect on the upper airway. Although we do not have a conclusive explanation, the finding that the inhibition of mandibular forward growth during MPA treatment does not have a negative effect on the upper-airway dimension should be favorable for orthodontists who use an MPA to control maxillary growth in growing skeletal Class III patients.

One of the most critical limitations of this study might be that the upper-airway dimension was evaluated based on a 2-dimensional cephalometric measurement.³¹ Therefore, it is still unknown whether changes in respiratory function could be induced following the increased maxillary growth during MPA treatment. In future studies, the clinical effect of an MPA on respiratory function should be carefully examined by monitoring respiratory function during wakefulness and sleep.

REFERENCES

- Kambara T. Dentofacial changes produced by extraoral forward force in the Macaca irus. *Am J Orthod*. 1971;71:249-277.
- Nanda R. Protraction of maxilla in rhesus monkeys by controlled extraoral forces. *Am J Orthod*. 1974;74:121-131.
- Jackson GW, Kokich VG, Shapiro PA. Experimental response to anteriorly directed extraoral force in young Macaca nemestrina. *Am J Orthod*. 1979;76:318-333.
- Ngan P, Hagg U, Yiu C, Merwin D, Wei SHY. Soft tissue and dentoskeletal profile changes associated with maxillary expansion and protraction headgear treatment. *Am J Orthod Dentofacial Orthop*. 1996;109:38-49.
- Shanker S, Ngan P, Wade D, Beck M, Yiu C, Hagg U, Wei SHY. Cephalometric A point changes during and after maxillary protraction and expansion. *Am J Orthod Dentofacial Orthop*. 1996;110:423-430.
- Nartallo-Turley PE, Turley PK. Cephalometric effects of combined palatal expansion and facemask therapy on Class III malocclusion. *Angle Orthod*. 1998;68:217-224.
- Silva Filho OG, Magro AC, Capelozza Filho L. Early treatment of the Class III malocclusion with rapid maxillary expansion and maxillary protraction. *Am J Orthod Dentofacial Orthop*. 1998;113:196-203.
- Kapust AJ, Sinclair PM, Turley PK. Cephalometric effects of facemask/expansion therapy in Class III children: a comparison of three age groups. *Am J Orthod Dentofacial Orthop*. 1998;113:204-212.
- Baccetti T, McGill JS, Franchi L, McNamara JA Jr, Tollaro I. Skeletal effects of early treatment of Class III malocclusion with maxillary expansion and face-mask therapy. *Am J Orthod Dentofacial Orthop*. 1998;113:333-343.
- Kilicoglu H, Kirlic Y. Profile changes in patients with class III malocclusions after Delaire mask therapy. *Am J Orthod Dentofacial Orthop*. 1998;113:453-462.
- Franchi L, Baccetti T, McNamara JA Jr. Shape-coordinate analysis of skeletal changes induced by rapid maxillary expansion and facial mask therapy. *Am J Orthod Dentofacial Orthop*. 1998;114:418-426.
- Sung SJ, Baik HS. Assessment of skeletal and dental changes by maxillary protraction. *Am J Orthod Dentofacial Orthop*. 1998;114:492-502.
- Deguchi T, Kanomi R, Ashizawa Y, Rosenstein SW. Very early face mask therapy in Class III children. *Angle Orthod*. 1999;69:349-355.
- Kim JH, Viana MAG, Graber TM, Omerza FF, BeGole EA. The effectiveness of protraction face mask therapy: A meta-analysis. *Am J Orthod Dentofacial Orthop*. 1999;115:675-685.
- Pruzansky S, Richmond JB. Growth of mandible in infants with micrognathia. *Am J Dis Child*. 1954;88:29-42.
- Kiely JL, Deegan PC, McNicholas WT. Resolution of obstructive sleep apnea with growth in the Robin sequence. *Eur Respir J*. 1998;12:499-501.
- Özbek MM, Memikoglu TUT, Gogen H, Lowe AA, Caspian E. Oropharyngeal airway dimensions and functional-orthopedic treatment in skeletal Class II cases. *Angle Orthod*. 1998;68:327-336.
- Handler SD. Upper airway obstruction in craniofacial anomalies: diagnosis and management. *Birth Defects*. 1985;21:15-31.
- Hui S, Wing YK, Kew J, Chan YL, Abdullah V, Fok TF. Obstructive sleep apnea syndrome in a family with Crouzon's syndrome. *Sleep*. 1998;21:298-303.
- Cistulli PA, Palmisano RG, Poole MD. Treatment of obstructive sleep apnea syndrome by rapid maxillary expansion. *Sleep*. 1998;21:831-835.
- Iizuka T. A study on facial growth in Japanese children by lateral cephalograms [In Japanese]. *J Stomatol Soc Jpn*. 1958;25:260-272.
- Kerr WJS. A longitudinal cephalometric study of dento-facial growth from 5 to 15 years. *Br J Orthod*. 1979;6:115-121.
- Bishara SE, Jakobsen JR. Longitudinal changes in three normal facial types. *Am J Orthod*. 1985;88:466-502.
- Iseri H, Solow B. Growth displacement of the maxilla in girls studied by the implant method. *Eur J Orthod*. 1990;12:389-398.
- Ishii H, Morita S, Takeuchi Y, Nakamura S. Treatment effect of combined maxillary protraction and chin cap appliance in severe Class III cases. *Am J Orthod Dentofacial Orthop*. 1987;92:304-312.
- Smalley WM, Shapiro PA, Hohl TH, Kokich VG, Branemark PI. Osseointegrated titanium implants for maxillofacial protraction in monkeys. *Am J Orthod Dentofacial Orthop*. 1988;94:285-295.
- Spann RW, Hyatt RE. Factors affecting upper airway resistance in conscious man. *J Appl Physiol*. 1971;31:708-712.
- Thach BT, Stark AR. Spontaneous neck flexion and airway obstruction during apneic spells in preterm infants. *J Pediatr*. 1979;94:275-281.
- Nagai M, Kudo A, Matsuno I, Yokoyama M, Manabe J, Hasegawa S, Nakamura S. Hyoid bone position and airway accompanied with influence of head posture [in Japanese]. *Nippon Kyosei Shika Gakkai Zasshi*. 1989;48:214-225.
- Sato T, Konishi H. *Macintosh for Expert StatView 4.0 [in Japanese]*. Tokyo: Bug News Network; 1995.
- Kawamata A, Fujishita M, Arijii Y, Arijii E. Three-dimensional computed tomographic evaluation of morphologic airway changes after mandibular setback osteotomy for prognathism. *Oral Surg Oral Med Oral Pathol*. 2000;89:278-287.