

Does the Canine Dental Follicle Cause Resorption of Permanent Incisor Roots?

A Computed Tomographic Study of Erupting Maxillary Canines

Sune Ericson, DDS, PhD; Krister Bjerklin, DDS, PhD; Babak Falahat, DDS

Abstract: We performed computed tomography (CT) on 107 children and adolescents aged 9–15 years with 176 unerupted maxillary canines (152 erupting ectopically and 24 erupting normally) to determine whether there is an association between widened dental follicles of the maxillary canines and resorption of the adjacent incisors during eruption. Contiguous axial (transverse) CT scans were obtained through the maxilla in the region of the canines. The width and shape of the dental follicles were recorded, as were any contacts between the follicles and the crowns of the maxillary canines and neighboring incisors. Fifty-eight lateral incisors (38%) and 14 central incisors (9%) had some type of root resorption. The position of the maxillary canine in relation to the root of the lateral incisor varied greatly, as did the width and shape of the canine dental follicle. Follicle width ranged from 0.5 mm to 7.0 mm. The mean \pm SD width of dental follicles was, on average, larger for the ectopically positioned canines (2.9 ± 0.8 mm) than for the normally erupting canines (2.5 ± 0.8 mm) ($P \leq .01$). We found that during eruption, the follicle of the erupting maxillary canine frequently resorbed the periodontal contours of adjacent permanent teeth but not the hard tissues of the roots. We concluded that the dental follicle did not cause root resorption of permanent teeth. Resorption of neighboring permanent teeth during maxillary canine eruption was most probably an effect of the physical contacts between the erupting canine and the adjacent tooth, active pressure during eruption, and cellular activities in the tissues at the contact points, all of which are part of the eruptive mechanism. The findings also confirm an association between root resorption of deciduous canines and the dental follicles of erupting permanent canines. (*Angle Orthod* 2002;72:95–104.)

Key Words: Dental follicle; Eruption; Tooth root resorption; Computed tomography (CT); Maxillary canine; Cuspid; Incisor; Deciduous root

INTRODUCTION

The process of permanent tooth eruption and movement into final functional position in the oral cavity comprises a series of events, and numerous theories have been proposed to explain this process.¹ The process involves the resorption and formation of bone within the alveolar process, the destruction and rebuilding of periodontal tissues, and the resorption of primary teeth.^{1–6} The resorptive mechanism seems to be confined to the dental follicle and related to

metabolic activation in the follicle or in the adjacent hard and soft tissues.^{1,3,4,7–10} Extensive microvascular and cellular activity occur along the coronal part of the follicle and, during eruption, the dental follicle is invaded by granules and mononuclear cells that fuse and form preosteoclasts, osteoclasts, and odontoclasts in the frontal, external layers of the follicle of the erupting tooth.^{4,7–9,11–13} Modification of the extracellular matrix surrounding the developing tooth occurs simultaneously.^{1,3,7, 8,13} These processes begin early in active tooth eruption and form the eruption pathway.^{1,4,7,11–13}

In experimental studies in dogs, Cahill and Marks^{8,14,15} concluded that bone resorption and formation of an eruption pathway involved a dental follicle and occurred independent of pressure from the erupting tooth. Surgical manipulations in dogs demonstrated that the dental follicle, but not the crown of the erupting permanent tooth, was a prerequisite for the formation of the eruption pathway.^{9,14–18} This finding implies that processes within and around the

From the Departments of Oral and Maxillofacial Radiology (Drs Ericson and Falahat) and Orthodontics (Dr Bjerklin), Institute for Postgraduate Dental Education, Jönköping, Sweden.

Corresponding author: Sune Ericson, DDS, PhD, Department of Oral and Maxillofacial Radiology, Institute for Postgraduate Dental Education, PO Box 1030, SE 551 11 Jönköping, Sweden (e-mail: sune.ericson@telia.com).

Accepted: August 2001. Submitted: May 2001.

© 2002 by The EH Angle Education and Research Foundation, Inc.

TABLE 1. Distribution of Maxillary Canines and Incisors in a Sample of 107 Children and Adolescents With 156 Ectopically and 58 Normally Erupting Maxillary Canines

Canine Position	No. of Canines		No. (%) of Central Incisors		No. (%) of Lateral Incisors		
	Total	Erupted (%)	Total	Resorbed (%)	Total	Aplasia	Resorbed (%)
Ectopic	156	4 (2.6)	156	14 (9)	152	4	58 (38.1)*
Normal	58	34 (58.6)‡	58	—	55	3	3 (5.5)†
Total	214	38 (17.8)	214	14 (6.5)	207	7	61 (29.5)

* One resorbed lateral incisor was adjacent to a partially erupted ectopic canine.

† Resorbed lateral incisors were adjacent to normally erupting incisors, 1 adjacent to a partially erupted canine.

‡ Aplasia of 2 lateral incisors.

TABLE 2. Degree of Resorption of the Roots of Lateral and Central Maxillary Incisors as Seen on Transverse CT Scans*

Incisor	Degree of Resorption				Total
	None	Slight	Moderate	Severe	
Lateral, n (%)†	94 (62)	18 (12)	5 (3)	35 (23)	152 (100)†
Central, n (%)	142 (91)	5 (3)	3 (2)	6 (4)	156 (100)

* CT indicates computed tomography.

† Aplasia of 4 lateral incisors.

dental follicle have a major influence on tooth eruption and that the intraosseous stage of eruption involves bone resorption and, in certain regions, primary tooth resorption.

The maxillary canines develop late and emerge into the oral cavity after the neighboring incisors have erupted. In 3-year-old children, the germ of the canine is situated high up in the maxilla, and the crown is directed mesially and somewhat lingually. As the canine moves toward the occlusal plane, it gradually becomes more upright until it reaches the distal aspect of the root of the lateral incisor.¹⁹ Morphologic and histologic studies in man have shown that the dental follicle of the canine will often expose the root of the adjacent incisor during eruption without resorbing any of the hard tissues of the root, besides the cementum, provided that eruption proceeds normally.^{6,20–23}

Root resorption of the maxillary permanent incisors caused by ectopic eruption of the permanent canine does occur and is reported to have an overall prevalence of 12%, with a prevalence that is 4 times as high in girls as in boys.²¹ Resorption sometimes also occurs when the canine erupts normally.²² The biological mechanisms behind the resorption of the roots of permanent teeth and the factors involved in that process have been debated and are not clear.⁵ It has been shown that the size and shape of the dental follicle of the erupting maxillary canine vary considerably between individuals, and it has been proposed that an enlarged or active dental follicle, as well as the pressure caused by an erupting tooth, may be responsible for the resorption,^{1,5,22–26} but so far there has been no final proof for or against these theories. The variation in size and shape of the dental follicle may reflect the properties of the follicle that trigger incisor root resorption.

The aim of this study was to elucidate the role of the

permanent canine follicle in the resorption of the roots of both the maxillary permanent incisors and the deciduous canines during ectopic eruption of the maxillary canines.

SUBJECTS AND METHODS

The subjects consisted of 107 children and adolescents, 39 boys (36%) and 68 girls (64%), with 156 maxillary canines that were erupting ectopically and 58 maxillary canines that were erupting normally. The subjects had been referred to the orthodontic clinic for consultation because they were at risk for resorption of the incisors because of the eruption of the maxillary canines. The ages of the children and adolescents ranged between 9 and 15 years, with a mean age of 12.5 years for both sexes. Seven lateral maxillary incisors were missing because of aplasia, 4 bilaterally and 3 unilaterally; 3 were adjacent to a normally erupting canine, and 4 were adjacent to an ectopically erupting canine. Four of the ectopically positioned canines and 34 of the normally erupting canines had penetrated the gingiva. Table 1 shows the distribution of ectopically and normally erupting canines and aplasia and resorption of the adjacent incisors in the study sample.

Fifty-eight of the 152 maxillary lateral incisors (38%) and 14 of the 156 maxillary central incisors (9%) adjacent to ectopically erupting canines had some type of resorption. In 7 jaw sides, both the lateral and central incisors were resorbed. The degree of resorption of the incisors is shown in Table 2. For a more detailed presentation of the subject material, see Ericson and Kurol²² and Ericson and Bjerklín.²³

Radiographic examination

A Siemens Somatome Plus computed tomography (CT) scanner (Siemens AG, Germany) was used to obtain CT scans of the teeth and alveolar bone in the maxilla.²⁷ A bone algorithm for the middle ear was applied, and the window setting was approximately 2800 Hounfield units (HU), with a center value of 750–800 HU. Filtration was performed according to the standard of the algorithm. The images of the objects on screen and on films were reconstructed from raw data sets.

Contiguous transverse CT scans with a slice thickness of

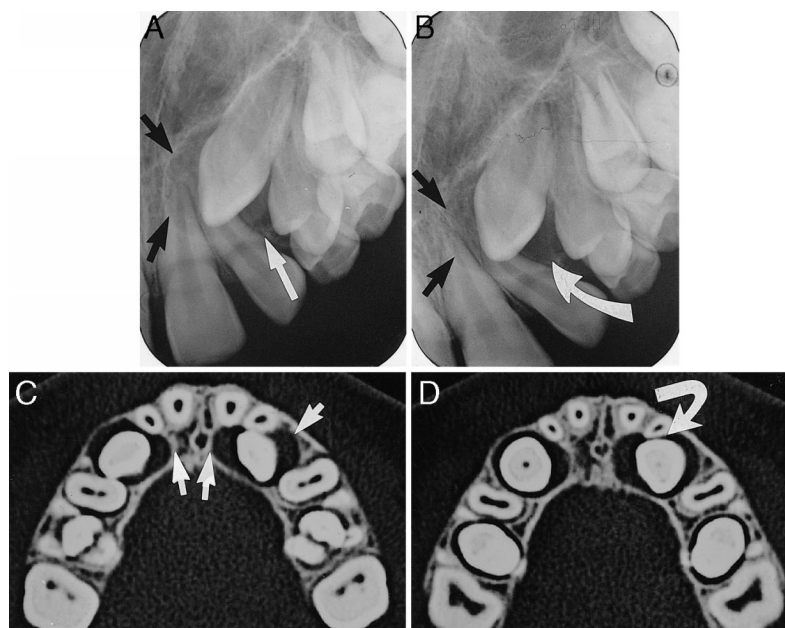


FIGURE 1. Findings in a 13-year-old boy. (A, B) Intraoral periapical films. No. 23 is erupting ectopically. The dental follicle of No. 23 is enlarged (arrows). There is no visible resorption of No. 22. (C, D) Axial computed tomography (CT) scans through the alveolar process at the level of the crowns of the erupting maxillary canines. No. 13 is erupting normally, and No. 23 is erupting lingually to No. 22. The dental follicles of the canines are enlarged (arrows). The follicle of No. 23 has an irregular form and expands into the surrounding medullar bone with no deviations of adjacent structures. The surfaces of the roots of No. 22 and No. 21 facing the follicle are exposed, and the periodontal contours in the contact zones are missing. The follicle tissue is missing at the contact point between No. 22 and No. 23, and the root of No. 22 has been slightly resorbed (curved arrow). The dental follicle of No. 13 has exposed the root of No. 12, and the periodontal contour of No. 12 has been resorbed (arrow). The space between the crown of No. 13 and the root of No. 12 is filled with follicular tissues. No root resorption of No. 12 can be seen.

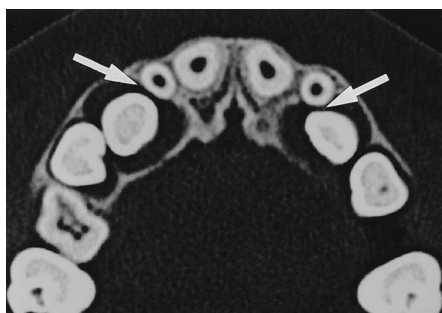

FIGURE 2. Findings in a 12-year-old boy on an axial computed tomography (CT) scan through the crowns of No. 13 and No. 23. The maxillary canines are erupting in slightly lingual positions within the dental arch. The dental follicles are symmetrically enlarged and have exposed the roots of No. 12 and No. 22. A gap exists between the canines and the laterals incisor (arrows). No resorption of the roots of the incisors can be seen. The follicles have expanded the alveolar bone lingually.

2 mm were exposed through the alveolar bone of the maxilla perpendicular to the long axis of the lateral maxillary incisors (Figures 1 through 7). In most subjects, 6 scans were obtained. The scans were documented on film with a Siemens laser camera (Siemens AG). The enlargement (zooming factor) on the film was $\times 1.5$, and the image resolution was about 0.3 mm. For a more detailed description of the performance and accuracy of the CT method in imaging the maxillary canines, see Ericson and Kurol.⁶

Variables studied

The eruption of the maxillary canines, the resorption of adjacent permanent incisors and deciduous canines, and the size and shape of the canine dental follicles were analyzed on screen and on film. The following variables were recorded.

Permanent maxillary canine. Three parameters were assessed for the permanent maxillary canines:

- Location within the bone: follicle was present (Figure 1)
- Eruption through the gingiva: no follicle was present, or the follicle was not assessable
- Position of the crown in relation to the adjacent teeth²²

Width of the dental follicle. The width of each maxillary canine follicle was measured:

- The width was defined as the largest distance from the crown of the maxillary canine to the periphery of the follicle
- The distance was measured in the transverse plane on axial CT scans to the nearest 0.5 mm²³

Shape of the dental follicle. The shape of the dental follicle was assigned to 1 of 2 categories based on the follicle's extension:

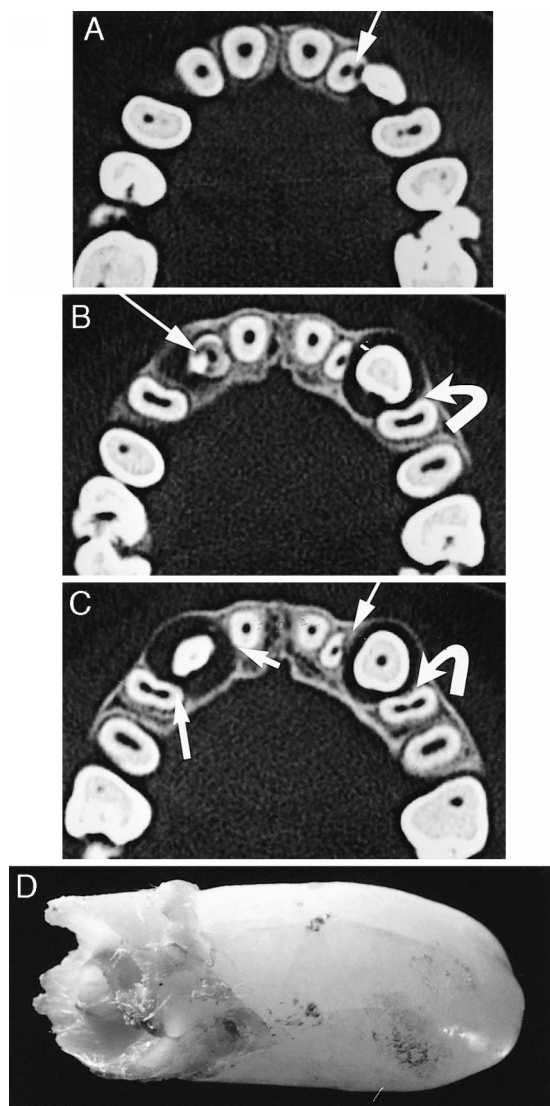


FIGURE 3. Findings in a 12-year-old boy. (A–C) Axial computed tomography (CT) scans obtained on the same occasion. No. 13 is erupting apically to No. 12. The dental follicle is symmetrically enlarged (C, arrows). The buccal cusp of No. 13 hits the root of No. 12 (B, arrow). There is extensive resorption of No. 12 close to the buccal cusp of No. 13. The periodontal contours of No. 14 and No. 11 have been resorbed near the dental follicle of No. 13 (C, arrows). No resorption of No. 14 and No. 11 can be seen. No. 23 is erupting distally to No. 22. The mesial corner of the buccal cusp of No. 23 is in contact with No. 22. Severe resorption of the root of No. 22 in the contact zone (A, arrow). In (C), the prominent part of the crown of No. 23 has passed. The resorbed area and the periodontal contour of No. 22 are being rebuilt (C, arrow). The dental follicle of No. 23 has exposed the root of No. 24 mesially (B, C curved arrows). There is no contact between the crown of No. 23 and the root of No. 24, and no resorption of No. 24 can be seen. (D) Extracted No. 12 showing extensive root resorption.

- Symmetric extension: rounded or spherical shape with the crown of the canine in the center (Figure 2)
- Asymmetric extension: irregular shape (Figure 1)

Root resorption of the maxillary permanent incisors. The

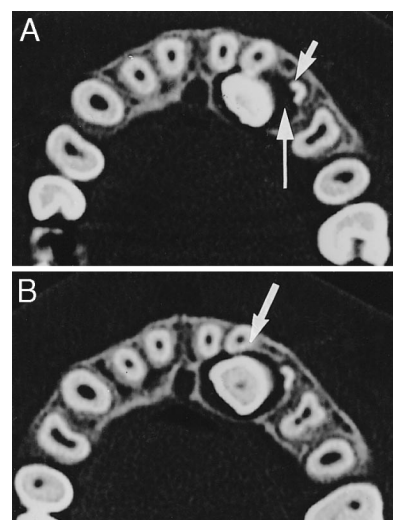


FIGURE 4. Findings in a 14-year-old boy on axial computed tomography (CT) scans. No. 23 is erupting lingually to No. 21 and No. 22. The periodontal contours of No. 21 and No. 22 facing the dental follicle of No. 23 are missing. No. 23 is in contact with the lingual aspect of No. 22, and the root has been slightly resorbed at the contact point (B, arrow). The follicle of No. 23 extends toward No. 63, and the root of No. 63 has been resorbed adjacent to the widened follicle but is intact buccally. There is a gap between No. 23 and No. 63 (A, arrow). No. 13 is erupting normally and at a distance from No. 12 and No. 14. The periodontal contours of No. 14 and No. 12 are unbroken.

resorption status of each incisor root was assigned to 1 of 4 categories:

- No resorption: intact root surfaces, the cementum layer may have been lost (Figures 1 and 5)
- Slight resorption: resorption extended up to half the distance of the dentine thickness to the pulp (Figure 1)
- Moderate resorption: resorption extended half the distance to the pulp or more, the pulp lining is unbroken (Figure 3)
- Severe resorption: resorption reached the pulp (Figure 3)

Periodontal contours of the permanent maxillary incisors. The periodontal contours of the incisors were assigned to 1 of 3 categories:

- Unbroken contours: the lamina dura of the alveolus and periodontal space were intact
- Broken contours: the lamina dura of the alveolus was destroyed, but there was no root resorption of the permanent teeth (Figure 2)
- Broken periodontal contours and resorption of the root(s) adjacent to the erupting maxillary permanent canine (Figures 1, 3 through 5, and 7)

Deciduous maxillary canines. The status of the deciduous maxillary canines was assigned to 1 of 4 categories:

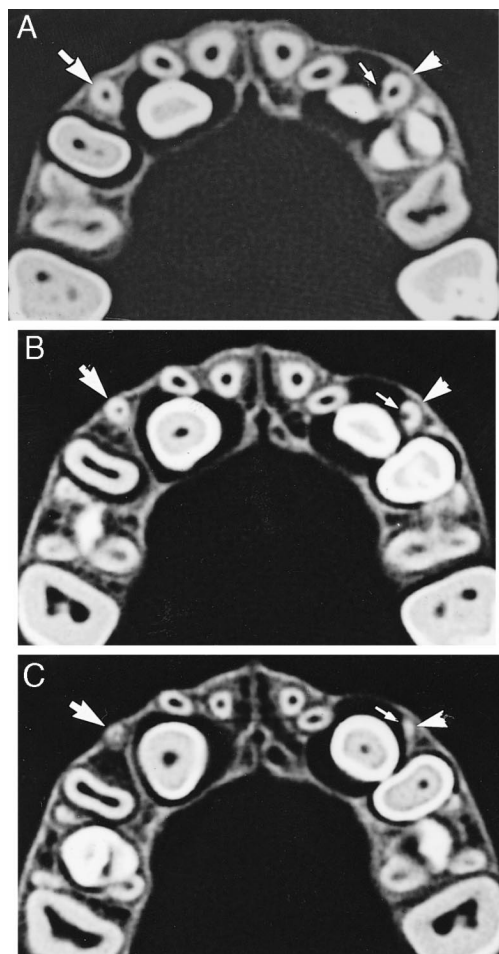


FIGURE 5. Findings in a 12-years-old girl on axial computed tomography (CT) scans. No. 13 is erupting with mesial inclination and lingually to No. 12. The dental follicle of No. 13 is enlarged and has exposed the roots of No. 12 and No. 11 (A–C) and No. 53 in a small area (A). The periodontal contours facing the follicle are missing. No. 53 (arrows) is unresorbed. The buccal surface of the crown of No. 13 touches the root of No. 12 (A, B). There is no root resorption of No. 12 in the contact area. The root of No. 12 is buccally displaced. No. 23 is erupting distally to No. 22 in an upright position and somewhat lingually within the dental arch (A–C). The dental follicle of No. 23 is enlarged and has exposed the roots of No. 22, No. 24, and No. 63. The periodontal contours facing the follicle are missing. The crown of No. 23 is touching No. 22 and No. 24 but not No. 63. No. 22 and No. 24 are intact. The root of No. 63 has been resorbed in the areas facing the dental follicle of No. 23 but is intact buccally.

- Missing tooth (Figures 1 through 3)
- No resorption of the deciduous canine root (Figures 5 and 6)
- Resorbed root, no contact between the follicle of the permanent canine and the deciduous canine
- Resorbed root, contact between the follicle of the permanent canine and the deciduous canine (Figures 4, 5 and 7)

Contact relationships. The contact relationships between

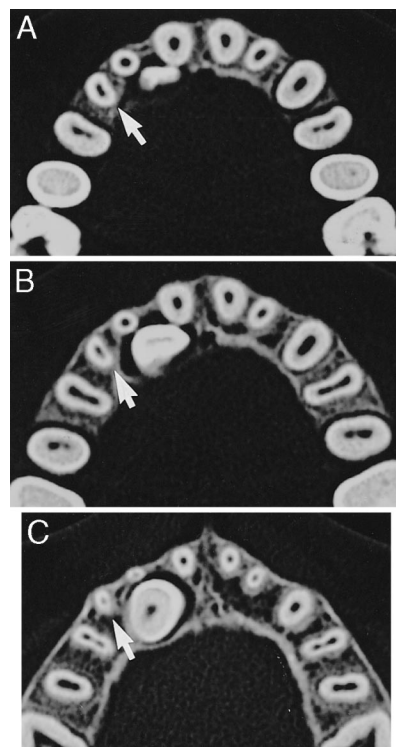


FIGURE 6. Findings in a 12-year-old girl on axial computed tomography (CT) scans. No. 13 is erupting with mesial inclination and lingually to No. 12 and No. 11. The crown of No. 13 is touching No. 11 (A, B). The dental follicle of No. 13 is slightly enlarged and has resorbed the periodontal contours of the roots of No. 11 and No. 12 on the side facing the follicle. No root resorption is seen. The root of No. 53 is separated from the dental follicle of No. 13 by bone (arrows), and the root of No. 53 is intact.

the permanent maxillary canine and the incisor and deciduous canine were assigned to 1 of 2 categories:

- Contact: the distance between the crown of the permanent maxillary canine and the adjacent incisor or the deciduous canine was less than 1 mm (Figures 1 and 5)
- No contact: the distance between the crown of the permanent canine and the adjacent incisor or the deciduous canine was more than 1 mm

Statistical analyses

The SPSS computer program was used for the statistical analyses.²⁸ Descriptive values were expressed as the mean \pm SD. The relationships of categorical data were studied using the chi-squared test (Fisher's exact test); the differences in means between 2 groups were studied using Student's *t*-test.

RESULTS

Permanent canine

The width of the dental follicle of the maxillary canine was calculated to be 2.9 ± 1.0 mm with a range of 0.5–

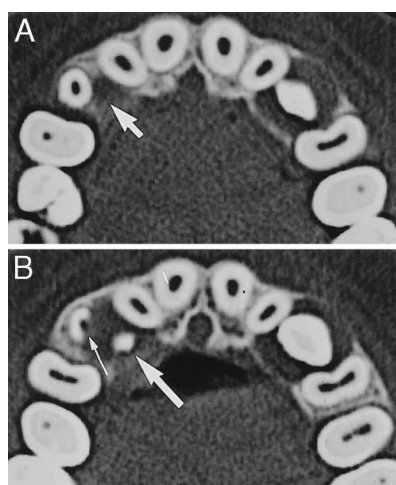


FIGURE 7. Findings in a 10-year-old boy on axial computed tomography (CT) scans. No. 13 is erupting lingually to No. 53 and distally to No. 12. The dental follicle of No. 13 is enlarged, and the roots of No. 53 and No. 12 are exposed on the sides facing the follicle (arrows). No. 53 has been resorbed close to the follicle (thin arrow), but the root of No. 12 is intact. There is a gap between No. 53 and the crown of No. 13. No. 23 is erupting within the dental arch and in contact with No. 22. The dental follicle is enlarged, and the periodontal contours of No. 22 and No. 24 facing the follicle have been resorbed. No root resorption of No. 22 or No. 24 can be seen.

TABLE 3. Association Between the Dental Follicle of the Permanent Maxillary Canine and Root Resorptions of Adjacent Permanent Incisors

Incisor	Periodontal Contour, Contact With the Dental Follicle of the Canine, and Root Resorption Status			Total
	No Contact Intact Root	Broken Contour, No Resorption of Adjacent Root(s)	Broken Contour, Resorption of Adjacent Root(s)	
Lateral, n	2	112	57	171*
Central, n	86	76	14	176

* Aplasia of 4 lateral incisors.

† One excluded, adjacent canine partly erupted.

7.0 mm for the entire sample of 176 unerupted canines. No age- or sex-related differences were found.²³ For the following analyses, the values of the dental follicles in boys and girls were pooled. The follicles of the ectopically erupting canines were, on average, significantly wider (2.9 ± 1.0 mm) than those of normally erupting canines (2.5 ± 0.8 mm) ($P \leq .01$).²³

Periodontal contours of adjacent incisors

The relationship between the dental follicles of the erupting maxillary canines and resorption of the periodontal contours and roots of the adjacent incisors was analyzed and is presented in Table 3. The crown and the dental follicle of the canine as well as the roots of the incisors were studied scan by scan along the roots. Only 2 (1%) of the 171

TABLE 4. Width of the Dental Follicle of the Permanent Maxillary Canines Measured on CT Scans in Relation to Root Resorption of the Adjacent Incisors*

Resorption Status of Incisor Root	No.	Follicle Width, Mean \pm SD, mm	Level of Significance
Lateral			
No resorption†	114	2.9 ± 1.0	NS
Resorption (all)‡	57	3.0 ± 1.0	NS
Severe resorption	35	3.1 ± 1.0	NS
Central			
No resorption	162	3.0 ± 1.0	$P \leq .01$
Resorption (all)	14	2.1 ± 0.6	

* CT indicates computed tomography; NS, nonsignificant.

† Aplasia of 4 lateral incisors.

‡ One partially erupted canine excluded.

canine dental follicles had no contact with the roots of the adjacent lateral incisors. The periodontal contours of those 2 lateral incisors were intact, whereas the contours of the remaining 169 (99%) were broken at the site of the follicle (Figures 1 through 7). Eighty-six (49%) of the central incisors had intact contours, and 90 (51%) had broken contours. The relationship between the broken periodontal contour of an incisor and the proximity of the canine dental follicle was significant ($P \leq .001$).

Proximity of dental follicle and root resorption

Of the 169 lateral incisors that were exposed by the dental follicle of the erupting canine, the root surfaces of 112 (66%) were intact, whereas the root surfaces of 57 (34%) had been resorbed (Table 3). For the central incisors the corresponding values were 76 (85%) and 14 (15%) of 90, respectively. One lateral incisor that was close to the maxillary canine and had partly erupted into the oral cavity had also been resorbed (Tables 1 and 3). The association between root resorption of the adjacent central or lateral incisors and the proximity of the dental follicle of the erupting canine to the roots of the incisors was studied using the chi-square test. No significant relationship was found between root resorption of the incisors and the proximity of the dental follicle of the erupting maxillary canine.

Width of the dental follicle and root resorption

The widths of the maxillary canine dental follicles adjacent to incisors that had undergone some type of resorption and incisors that had not undergone any resorption were compared (Table 4). No significant differences in the widths of the follicles were found for the lateral incisors. For central incisors, the maximum width of the maxillary canine dental follicles was smaller when the root of the central incisor was resorbed (2.1 ± 0.6 mm) than when the root was not resorbed (3.0 ± 1.0 mm) ($P \leq .01$). However, the number of resorbed central incisors was small, which may have biased the results.

TABLE 5. Shape and Width of the Dental Follicle of the Ectopically Positioned, Unerupted Maxillary Canines in a Sample of 57 Resorbed Lateral Incisors and 14 Resorbed Central Incisors

Follicle Shape	No.*	Follicle Width, Mean \pm SD, mm	Level of Significance
Rounded	29	2.6 \pm 0.9	$P \leq .01$
Irregular	35	3.3 \pm 1.0	

* Seven jaw sides had root resorptions of both the lateral and central incisors.

TABLE 6. Relationship Between the Shape of the Maxillary Canine Dental Follicle and Root Resorption of the Adjacent Incisors

Resorption Status of Incisor Root	No. of Follicles*			Level of Significance
	Rounded	Irregular	Total	
No resorption	55	57	112	NS
Resorption	29	35	64	
Total*	84	92	176	

* Both the lateral and central incisors in 7 jaw sides had undergone root resorption. One ectopically and 3 normally erupting canines had erupted through the gingiva.

TABLE 7. Relationship Between Root Resorption of the Maxillary Lateral Incisor and Contact With the Crown of the Adjacent Canine

Resorption Status of Incisor Root	Contact Relationship*		
	No Contact	Contact	Probability
No resorption	37	109	$P < .001$
Resorption	2	59	

* Aplasia of 7 lateral incisors.

TABLE 8. Relationship Between Root Resorption of the Maxillary Central Incisor and Contact With the Crown of the Adjacent Canine

Resorption Status of Incisor Root	Contact Relationship		
	No Contact	Contact	Probability
No resorption	180	20	$P < .001$
Resorption	2	12	

Shape of the dental follicle and root resorption

The shape of the dental follicles of the maxillary canines varied. Among the ectopically positioned, unerupted maxillary canines, 42% were rounded, with the crown of the canine in the center, and 58% had an irregular shape with asymmetric extensions ($P \leq .01$). The relationship between

resorption of adjacent permanent incisors and the shape of the maxillary canine follicle is shown in Table 5. Twenty-nine (45%) of the follicles in contact with resorbed roots were rounded, and 35 (55%) were irregularly shaped. These figures coincide with the distribution of the shapes of the follicles for the whole sample.²³ Among follicles adjacent to resorbed incisors, irregularly shaped follicles were significantly larger than rounded follicles ($P \leq .01$), which is also in agreement with the pattern noted for the total sample of unerupted canines. For the 176 unerupted canines, there was no significant difference in the distribution of rounded or irregular canine dental follicles between resorbed and unerupted lateral incisors (Table 6).

Crown position and root resorption

The association between root resorption of the permanent incisor and contact with the crown of the erupting maxillary canine was also studied. Incisor roots with some type of resorption were more frequently seen when the canine crown was in contact with the incisor root than when there was no contact between the canine and the incisor (Tables 7 and 8) ($P \leq .001$ each for lateral and central incisors).

Deciduous canines

A total of 59 persistent deciduous maxillary canines were found, of which 53 occurred in the sample with the ectopically positioned, unerupted permanent maxillary canines, and 6 occurred in the sample with the normally positioned, erupting canines (Table 9). Twelve (20%) of the 59 deciduous canines were in direct contact with the crown of the permanent canine. In the study of the relationship between resorption of the deciduous canine and the dental follicle of the permanent canine at eruption, those 12 canines were excluded. Thirty-six (77%) of the remaining deciduous canines were in contact with the dental follicles of the adjacent permanent canines, whereas 11 (23%) had no contact (Table 9). A significant relationship was found between resorbed deciduous canines and the proximity of the dental follicle of the erupting permanent canines ($P \leq .01$). However, some resorbed deciduous canines had no follicular contact, and some deciduous canines that were in contact with the dental follicle were intact (Table 9, Figure 5).

The association between resorption of the roots of the deciduous maxillary canines and the width of the dental

TABLE 9. Numbers of Deciduous Maxillary Canines and the Contact Relationships Between the Deciduous and Permanent Maxillary Canines

Permanent Canine Position	Total No.	Deciduous Canine Contact Relationship							
		No. Contact With the Follicle of the Permanent Canine				Contact With the Follicle		Contact With the Crown	
		Missing	Present	Intact	Resorbed	Intact	Resorbed	Intact	Resorbed
Ectopic, n	156	103	53	7	4	9	24	—	9
Normal, n	58	52	6	—	—	—	3	—	3
Total, n	214	155	59	7	4	9	27		12

TABLE 10. Width of the Permanent Maxillary Canine Dental Follicle in Relation to Root Resorption of 47 of the Adjacent Deciduous Canines

Relationship of the Deciduous Canine Root to the Permanent Canine Follicle	No.	Follicle Width, Mean \pm SD, mm	Probability*
Intact, no follicle contact	7	2.6 \pm 1.4	NS
Intact, follicle contact	9	2.5 \pm 0.6	$P \leq .01$
Resorbed, follicle contact	27	3.3 \pm 1.0	$P \leq .05$
Resorbed, no follicle contact	4	2.4 \pm 0.7	

* NS indicates nonsignificant.

follicles of the permanent canines was analyzed (Table 10). The widths of the dental follicles were, on average, larger for deciduous canines that had resorbed roots than for those that had unresorbed roots ($P \leq .05$ to $.01$).

DISCUSSION

Computed tomography is superior to conventional x-ray methods for the assessment of incisor root resorption associated with ectopically positioned maxillary canines.^{6,22} When conventional radiography poorly depicts the relationship between an ectopically erupting tooth and the root(s) of adjacent permanent teeth, the use of CT may be justified despite the additional radiation and cost, so that diagnostic and therapeutic problems may be solved for the benefit of the patient. The children in this study were evaluated on that indication. The effective dose of radiation used was still acceptable in our approach because of the low total risk for stochastic effects, and any drawbacks of CT imaging were balanced by its provision of a better foundation and prognosis for orthodontic treatment.

Besides the accuracy in imaging the morphology of the roots within the jaws, the periodontal contour of the roots and the appearance and extension of the dental follicles of the erupting canines can be imaged in detail with CT (Figures 1 through 7). Limitations due to overlapping and distortion, common problems in conventional radiography, are insignificant with CT imaging.

We found that the dental follicle of the erupting maxillary canine varied in shape and width, but there were no associations of shape and width either with sex and age or with erupting canine position (normal or ectopic).²³ Other factors such as the qualities of the bone, the space within the bone available for follicle expansion, and the changes in and around the follicle activated by hormones or other growth-related factors are most likely of greater importance for the variations in the follicle dimensions.^{4,5,10-13,23} In adults, it has been observed that the dental follicles of impacted teeth often decrease in width if pathologic changes do not occur.^{5,30} Evidence that growth factors might play a role in tooth eruption and its regulation has been found in mice.^{10,12,29,31} The fact that the dental follicles of impacted

teeth often decrease in size in adults may support that presumption.

During normal eruption, the maxillary canine descends along the distal aspect of the root of the lateral incisor. In the present study, the periodontal contour of the lateral incisor facing the follicle of the erupting canine was frequently missing, and the follicle exposed the incisor root. These findings confirm previous observations^{1,20} and underscore the resorptive power of the dental follicle. The age range of the individuals in this study (9–15 years) and their diversity made it possible to follow the eruption of the maxillary canine in different situations. By analyzing the follicle, crown, and roots of the adjacent incisors by CT imaging, we were able to obtain detailed information about the processes of resorption and repair in this population.

We found that resorption of the periodontal contour occurred when the follicle approached the lamina dura, and the contour was rebuilt when the follicle of the canine had passed (Figure 3). Normally and ectopically erupting canines behaved similarly, and the association between resorption and repair of the periodontal contour and the proximity of the dental follicle was confirmed. Our findings in man concerning the resorption and repair of the periodontal contours during permanent tooth eruption are in agreement with the histologic observations of Cahill,^{14,15} Marks and Cahill,¹⁶ Cahill et al,¹⁸ and Marks et al.³²

There was a high frequency of resorbed maxillary incisors in the study group. The cavities on the roots of the permanent incisors that were caused by resorption occurred close to the follicles and crowns of the erupting canines. At the resorption site, the canine dental follicle was thin or missing but otherwise enlarged. When a gap occurred in the follicle between the naked root of the incisor and the crown of the canine, the root of the incisor was not resorbed. The size and shape of the follicle outside the contact zone did not differ between cases with resorbed and cases with unresorbed roots. This finding suggests that other factors involved in the eruption process and not the dental follicle per se caused incisor root resorption. The strong relationship between physical contact between the crown of the erupting canine and resorption of the roots of adjacent incisors indicates that the crown is responsible for the eruption. From orthodontic treatment, it is well known that physical pressure on hard tissues induces cellular activity in the periodontal membrane and the formation of dentinoclasts and osteoclasts.³³ These observations indirectly verify the theory that active pressure during permanent tooth eruption, as a part of the eruptive mechanism, is the factor that triggers incisor root resorption. The strong association between incisor root resorption and contact with the adjacent erupting canine found in this study support that theory.

We also investigated deciduous maxillary canine resorption during permanent maxillary canine eruption. Unlike the roots of the permanent incisors, the roots of the deciduous canines were frequently resorbed when the follicle of

the permanent canine made contact with the deciduous root. The association between resorption and follicle contact was confirmed, but we also noted partially resorbed deciduous canines that were not in contact with the follicle, as well as intact deciduous roots that were in contact with the follicle. The latter finding was present in the younger children in the sample, in whom the contact relationships may have been only recently established.

CONCLUSIONS

The study's results support the following conclusions:

- The dental follicles of the erupting permanent maxillary canine do not per se cause resorption of the adjacent permanent incisor.
- No relationship exists between the width or shape of the maxillary canine dental follicle and resorption of the adjacent permanent incisors at eruption.
- The dental follicle of the erupting maxillary canine normally causes resorption of the periodontal contour of the lateral incisor during eruption.
- Root resorption of the permanent maxillary incisors after eruption of the maxillary canines is probably caused by physical contact between the incisor and the canine and by pressure from the canine as a part of the eruption process.
- The dental follicle of the erupting permanent canine frequently causes resorption of the root of the adjacent deciduous canine.

ACKNOWLEDGMENT

We are grateful to statistician Birgit Ljunqvist, PhD, for statistical advice.

REFERENCES

1. Marks SC Jr, Schroeder HE, Andreasen JO. Theories and mechanisms of tooth eruption. In: Andreasen JO, Kölsen-Pedersen J, Laskin DM, eds. *Textbook and Color Atlas of Tooth Impactions*. Copenhagen, Denmark: Munksgaard; 1997:19–64.
2. Sasaki T, Watanabe C, Shimizu T, Kazuhiro D, Segawa K. Possible role of cementoblasts in the resorbant organ of human deciduous teeth during root resorption. *J Periodont Res*. 90;25:143–151.
3. Marks SG, Gorski JP, Wise GF. The mechanism and mediators of tooth eruption—models for developmental biologist. *Int J Dev Biol*. 1995;39:223–230.
4. Marks SC Jr, Schroeder HE. Tooth eruption: theories and facts. *Anat Rec*. 1996;245:374–393.
5. Kuroi J, Ericson S, Andreasen JO. The impacted maxillary canine. In: Andreasen JO, Kölsen-Pedersen J, Laskin DM, eds. *Textbook and Color Atlas of Tooth Impactions*. Copenhagen, Denmark: Munksgaard; 1997:125–175.
6. Ericson S, Kuroi J. Incisor root resorptions due to ectopic maxillary canines imaged by computerized tomography. A comparative study in extracted teeth. *Angle Orthod*. 2000;70:276–283.
7. Wise GE, Marks SC Jr, Cahill DR. Ultrastructural features of the dental follicle associated with formation of the tooth eruption pathway in the dog. *J Oral Pathol*. 1985;14:15–26.
8. Marks SC Jr, Cahill DR. Regional control by the dental follicle of alterations in alveolar bone metabolism during tooth eruption. *J Oral Pathol*. 1987;16:164–169.
9. Sasaki T, Motegi N, Suzuki H, Watanabe C, Tadokoro K, Yanagisawa T, Higashi S. Dentin resorption mediated by odontoclasts in physiological root resorption of human deciduous teeth. *Am J Anat*. 1988;183:303–315.
10. Kardos TB. The mechanism of tooth eruption. *Br Dent J*. 1996;181:91–95.
11. Marks SC Jr. The origin of osteoclasts: evidence, clinical implications and investigative challenges of an extra-skeletal source. *J Oral Pathol Med*. 1983;12:226–256.
12. Shroff B, Rothman JR, Norris K, et al. Follicular apoptosis during tooth eruption. In: Davidovitch Z, Mah J, eds. *Biological Mechanisms of Tooth Eruption, Resorption and Replacement by Implants*. Birmingham, Ala: EBSCO Media; 1998:71–77.
13. Shroff B, Siegel SM. Molecular basis for tooth eruption and its clinical implications in orthodontic tooth movement. *Semin Orthod*. 2000;6:155–172.
14. Cahill DR. Eruption pathway formation in the presence of experimental tooth impaction in puppies. *Anat Rec*. 1969;164:67–78.
15. Cahill DR. Histological changes in the bony crypt and gubernacular canal of erupting permanent premolars during deciduous premolar exfoliation in beagles. *J Dent Res*. 1974;53:786–791.
16. Marks SC Jr, Cahill DR. Experimental study in the dog of the non-active role of the tooth in the eruptive process. *Arch Oral Biol*. 1984;29:311–322.
17. Wise G, Marks SC Jr, Cahill DR. Ultrastructural features of the dental follicle associated with formation of the tooth eruption pathway in the dog. *J Oral Pathol*. 1985;14:15–26.
18. Cahill DR, Marks SC Jr, Wise GE, Gorski JP. A review and comparison of tooth eruption systems used in experimentation—a new proposal on tooth eruption. In: Davidovitch Z, ed. *The Biological Mechanism of Tooth Eruption and Root Resorption*. Birmingham Ala: EBSCO Media; 1988:1–7.
19. Burdi AE, Moyers RE. Development of the dentition and the occlusion. In: Moyers RE, ed. *Handbook of Orthodontics*. 4th ed. Chicago, Ill: Year Book Medical Publishers Inc; 1988:140.
20. Ericson S, Kuroi J. Radiographic examination of ectopically erupting maxillary canines. *Am J Orthod Dentofac Orthop*. 1987;91:483–492.
21. Ericson S, Kuroi J. Incisor resorption caused by maxillary cuspids. A radiographic study. *Angle Orthod*. 1987;57:332–346.
22. Ericson S, Kuroi J. Resorption of incisors after ectopic eruption of maxillary canines. A CT study. *Angle Orthod*. 2000;70:415–423.
23. Ericson S, Bjerklin K. The dental follicle in normally and ectopically erupting maxillary canines. A computerized tomography study. *Angle Orthod*. 2001;71:332–342.
24. Ericson S, Kuroi J. Resorption of maxillary lateral incisors caused by ectopic of canines: a clinical and radiographic analysis of predisposing factors. *Am J Orthod Dentofac Orthop*. 1988;94:503–513.
25. Sasakura H, Yoshida T, Murayama S, Hauda K, Nakajima T. Root resorption of upper permanent incisor caused by impacted canine. *J Oral Surg*. 1984;13:299–306.
26. Bidwell JP, Fey EG, Marks SC Jr. Nuclear matrix-intermediate

- filament proteins of the dental follicle/enamel epithelium and their changes during tooth eruption in dogs. *Arch Oral Biol.* 1995;40:1047–1051.
27. *Operating Manual: Somatome Plus/Plus-S. Image Quality Guide.* Erlangen, Germany: Siemens AG; 1995:7–50.
 28. Nie N, Hull CH, Jenkins JG, Steinbrenner K, Bent DH. *Statistical Package for the Social Sciences.* 2nd ed. New York; NY: McGraw-Hill; 1975.
 29. Thesleff I. Does epidermal growth factor control tooth eruption? *ASDC J Dent Child.* 1987;54:321–329.
 30. Olow-Nordenram M, Anneroth G. Eruption of maxillary canines. *Scand J Dent Res.* 1982;90:1–8.
 31. Wise GE. The biology of tooth eruption. *J Dent Res.* 1998;77:1576–1579.
 32. Marks SC Jr, Gorski JP, Wise GE. The mechanisms and mediators of tooth eruption—models for developmental biologists. *Int J Dev Biol.* 1995;39:223–230.
 33. Thilander B, Rygh P, Reitan K. Tissue reactions in orthodontics. In: Graber TM, Vanarsdall RL, eds: *Orthodontics: Current Principles and Techniques.* 3rd ed. St Louis, Mo: Mosby; 2000:125–139.