

Correction of Severe Vertical Maxillary Excess with Anterior Open Bite and Transverse Maxillary Deficiency

R. S. Conley, DMD^a; H. L. Legan, DDS^b

Abstract: Patients requiring correction of large anterior open bites have historically been among the most challenging treatments for orthodontists. Adding to that fundamental challenge for the adult patient in this case was vertical maxillary excess, a severe transverse maxillary deficiency as well as an arch length inadequacy, even though the patient had prior orthodontic treatment. The prior orthodontist had included arch expansion and extracted four first bicusps, which limited current treatment options. Various treatment modalities that have traditionally been used to correct transverse maxillary deficiency and the accompanying arch length inadequacy include extractions, labial and buccal dental tipping, segmental maxillary osteotomies, and rapid maxillary expansion with or without surgical assistance. Transverse maxillary distraction osteogenesis is a modification (ie, using a latency period and specific rate and rhythm of distraction) of the surgically assisted rapid maxillary expansion technique developed 25 years ago. This case demonstrates the relationship of transverse maxillary deficiency as well as vertical maxillary excess to apertognathia. Considerations regarding the use of segmental maxillary osteotomy vs transverse distraction osteogenesis are discussed. This case report illustrates the benefit of a team approach using transverse maxillary distraction osteogenesis, effective orthodontic mechanics, and orthognathic surgery to correct a severe dentofacial deformity. (*Angle Orthod* 2002;72:265–274.)

Key Words: Vertical maxillary excess; Transverse maxillary deficiency; Apertognathia; Transverse maxillary distraction osteogenesis

INTRODUCTION

Skeletal open-bite cases have long been considered among the most difficult to treat. Treatment modalities cover a broad spectrum, including bite blocks (with or without magnets),^{1,2} vertical pull chin cup,³ extraction therapy,⁴ multiple loop edgewise archwire (MEAW) therapy,⁵ and surgery.⁶ Unfortunately, many of these techniques are of limited use in adult nongrowing patients and in patients with significant vertical skeletal dysplasia. Many of the proposed treatments, such as extraction of first molars to bring the second molars out of the wedge, have been reported to have beneficial effects on the vertical dimension.⁷ Unfortunately, when investigated more closely, the proposed benefits to the vertical dimension cannot be verified.⁸

Treatment stability is always a concern when open bites

are corrected with guided eruption. Patients who have excellent results upon appliance removal will often show a gradual decrease in overbite. Successful treatment with functional appliances, MEAW therapy, extraction therapy, and other treatment methods often requires both extrusion of anterior teeth and patient compliance. Stability studies of each of these treatment methods have shown that over time there can be significant reduction of the overbite.⁹ Much research has also been conducted on the stability of orthognathic surgery for the correction of skeletal open bite.¹⁰ Depending on the magnitude of the open bite and the relative anterior-posterior positions of the jaws, surgery can vary from relatively routine single jaw surgery to complex three-dimensional double jaw surgery.

History

An 18-year, 6-month-old woman (Figure 1) presented to the office with a chief complaint of “I need braces and jaw realigning.” She reported having previously sought orthodontic care elsewhere at the age of 14. An expansion appliance was placed, but she was unable to complete orthodontic care at that time. She further reported that four teeth were extracted in an attempt to correct the excessive crowding. She had a medical history significant for penicillin, erythromycin, and sulfa drug allergies. She reported having

^a Assistant Professor, Vanderbilt Medical Center, Division of Orthodontics, Nashville, Tenn.

^b Professor and Director, Vanderbilt Medical Center, Division of Orthodontics, Nashville, Tenn.

Corresponding author: R. S. Conley, DMD, Assistant Professor, Vanderbilt Medical Center, Division of Orthodontics, 1500 21st Ave South, Suite 3400, Nashville, TN 37212.
(e-mail: richard.conley@mcmail.vanderbilt.edu).

Accepted: January 2002. Submitted: December 2001.

© 2002 by The EH Angle Education and Research Foundation, Inc.

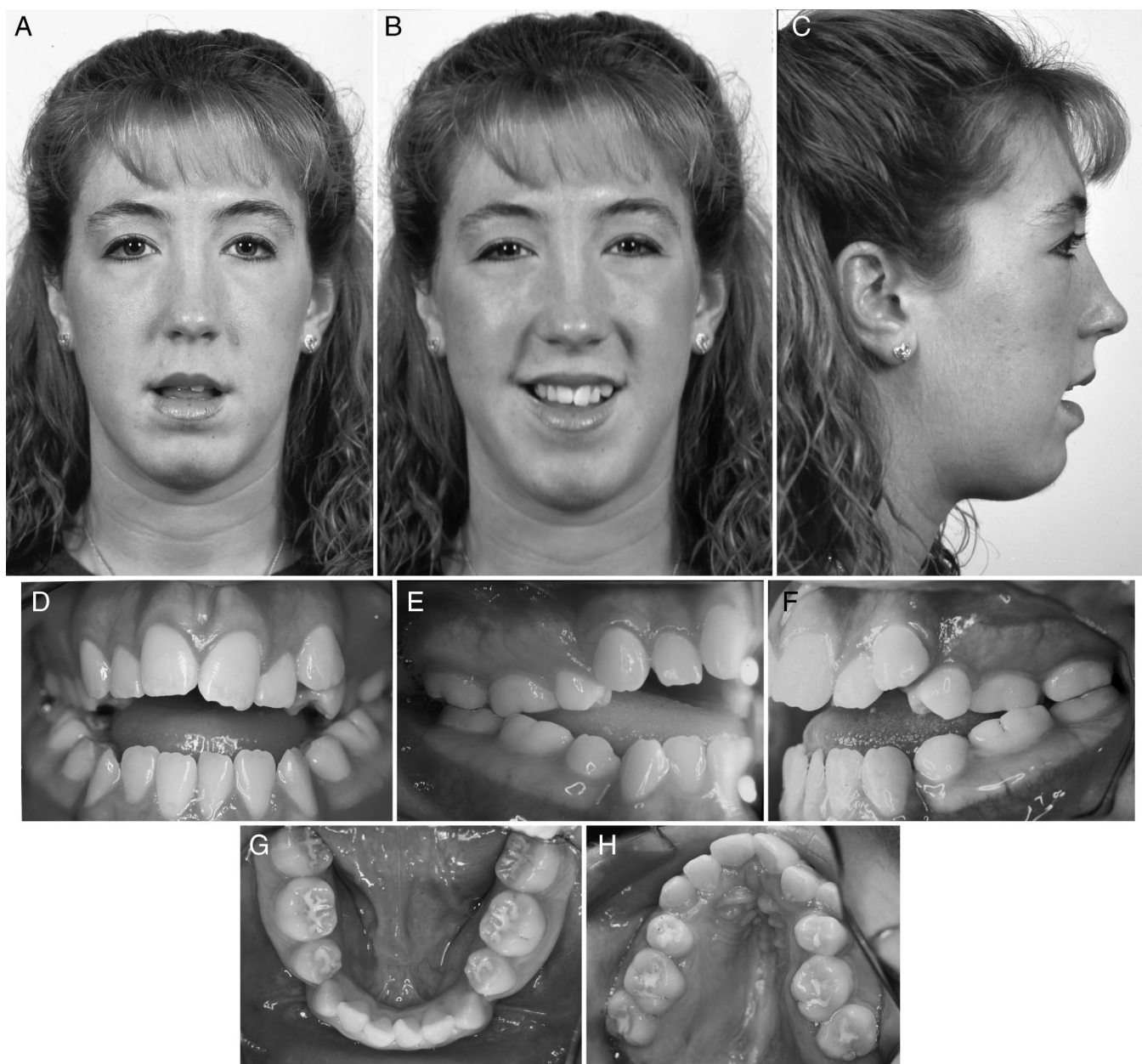


FIGURE 1. (A–H) Pretreatment photographs. Note the severe maxillary transverse and arch length deficiency present. This is especially significant because of the previously extracted four first premolars.

had Rocky Mountain Spotted Fever for which she underwent steroid therapy. Both the mother and the patient reported that the patient had experienced mitral valve prolapse with regurgitation, requiring antibiotic prophylaxis. Finally, she had seasonal sinusitis and took over-the-counter medication as symptoms warranted.

Clinical examination

Examination revealed that the patient was missing four permanent first premolars. Even without the missing teeth, a significant tooth mass and arch length discrepancy existed. She had a bilateral posterior crossbite with lingually

inclined mandibular molars and an eight mm anterior open bite. The only teeth in occlusion were the maxillary and mandibular second molars. An anterior tooth mass discrepancy existed with slightly smaller maxillary lateral incisors. In addition, bilateral temporomandibular clicks were noticeable but nontender and nonpainful. She was able to move through a full range of jaw motion.

Occlusal examination revealed a Class II subdivision left malocclusion with an anterior open bite. The maxillary arch form was constricted with a slight saddle shape. In addition, two distinct occlusal planes were within the maxilla. One plane extended from the second molars to approximately

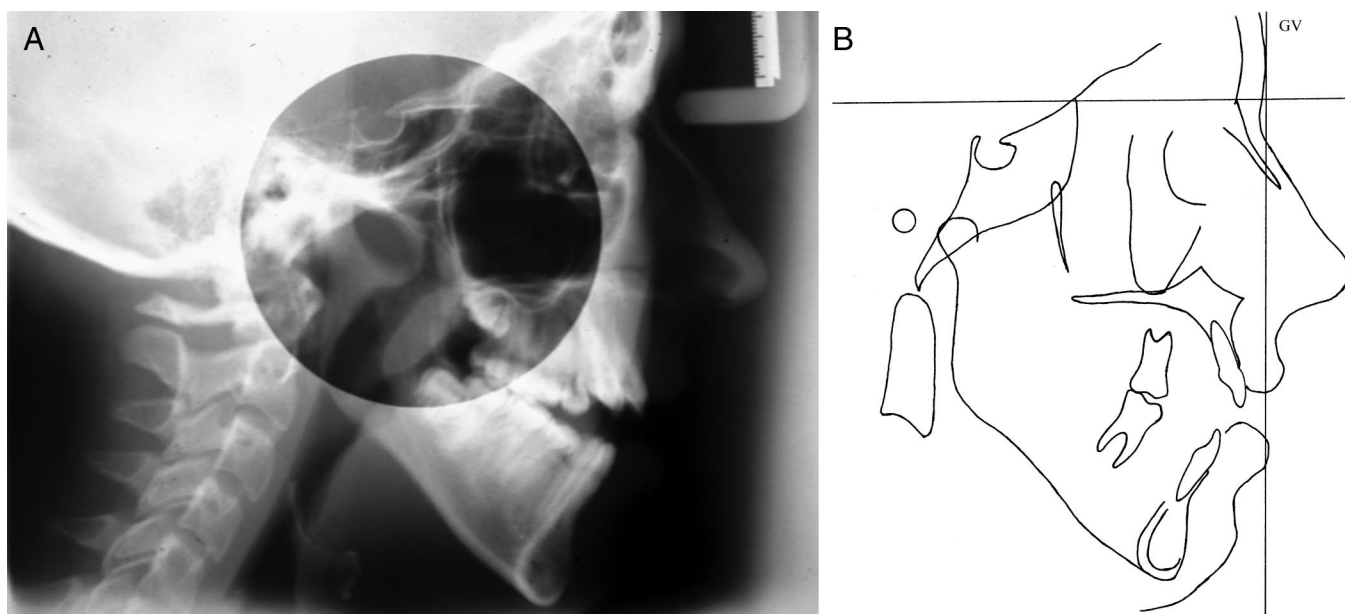
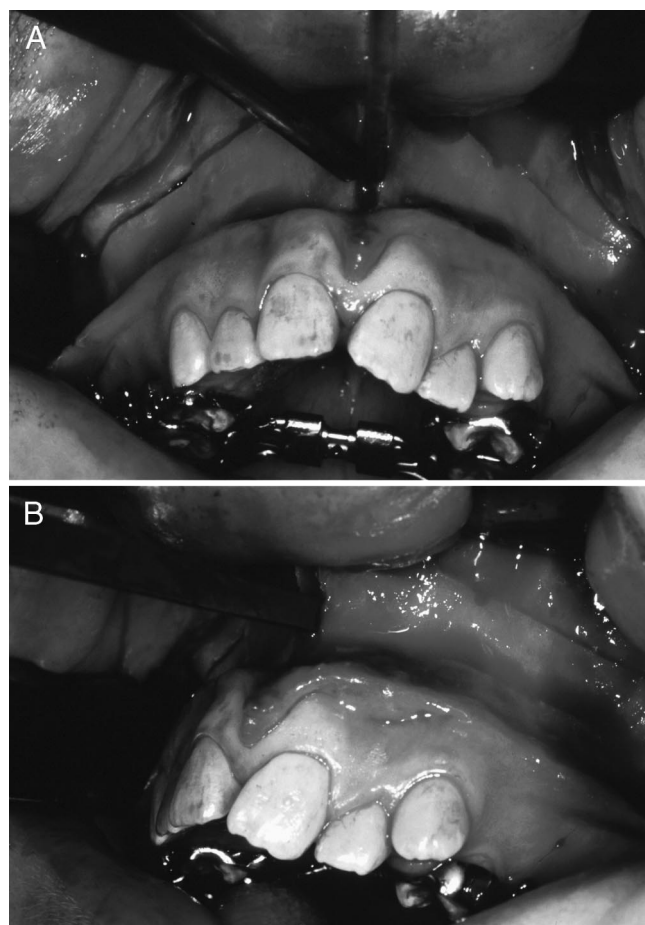


FIGURE 2. (A) Pretreatment cephalograph and (B) tracing. Note the significant anterior open bite, large interlabial gap, steep mandibular plane angle, and vertical maxillary excess.



the maxillary canines. The anterior dentition, from canine to canine, had a second plane of occlusion. The mandibular arch form was essentially normal, although the posterior teeth were mesially tipped. The mandibular midline deviated approximately one mm to the right of the middle sag-

←

FIGURE 3. (A, B) SARME progress photograph. Immediately after completion of the osteotomies, the surgeon checks to assure complete mobilization of the maxilla by activating the appliance approximately 2–3 mm and observing the lateral displacement of the maxilla for symmetry as well as formation of a midline diastema. The appliance was then returned to the starting position to allow formation of a well-organized callus.

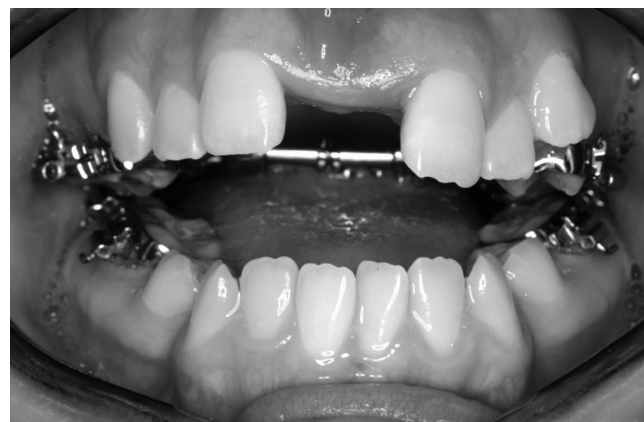

FIGURE 4. Frontal occlusal photograph after completion of SARME. The maxillary left side appears to have repositioned inferiorly as the expansion was performed. A maxillary intrusion arch was applied to correct the frontal occlusal plane discrepancy.

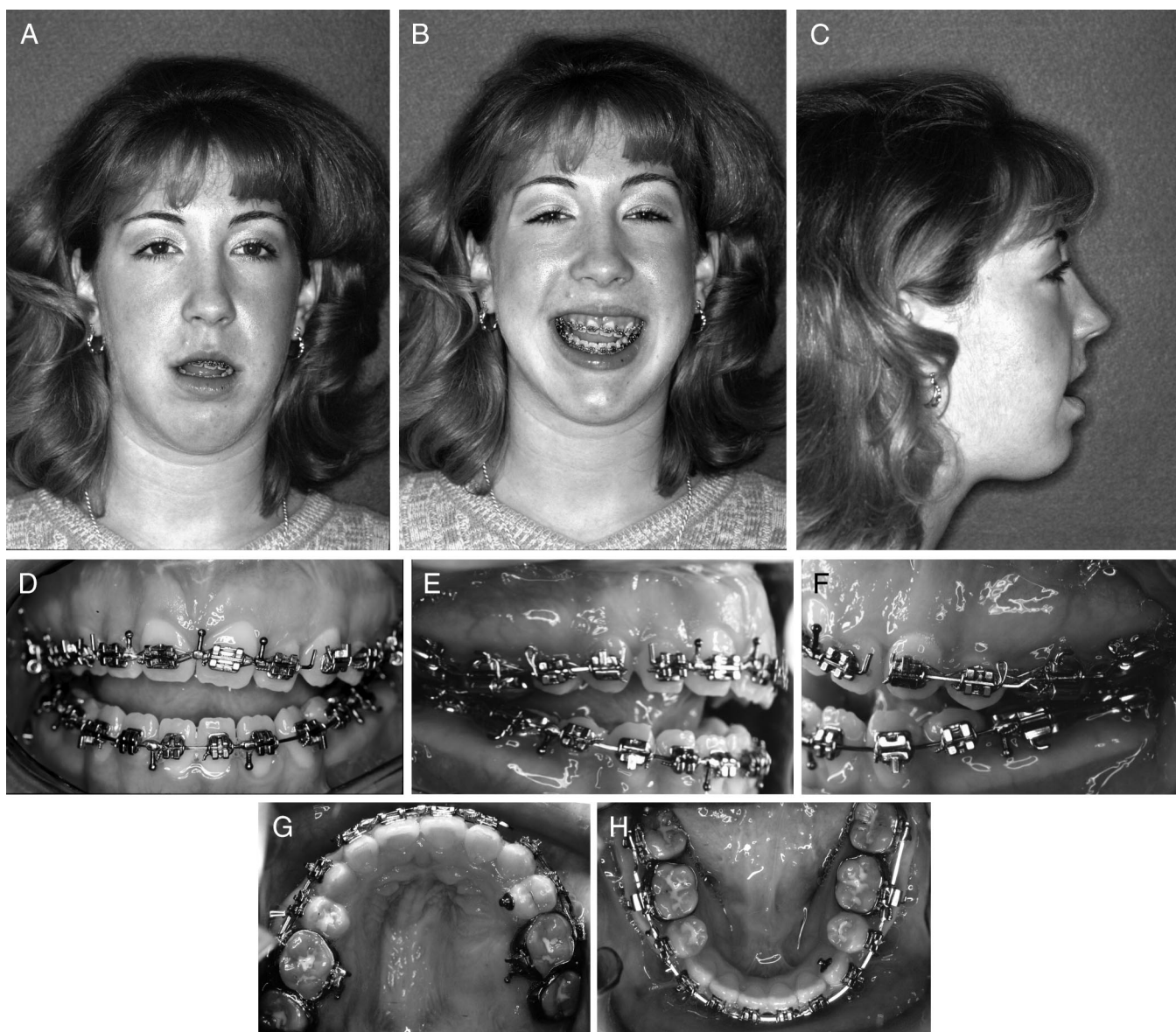

FIGURE 5. (A–H) Presurgical photographs. The maxilla was not completely leveled orthodontically and was separated into three segments to allow for surgical rather than orthodontic correction of the anterior open bite. Placement of a continuous maxillary arch wire may have led to unwanted anterior extrusion and built relapse into the case.

ittal plane, and a moderate mandibular arch length deficiency was also present.

Facial and cephalometric examination^{11,12} (Figure 2) revealed an excessively long lower facial height, large interlabial gap, excessive incisal display at rest, and an excessive incisal and gingival display upon smiling. The patient had a steep mandibular plane of 42° relative to the horizontal plane. She had a convex facial profile with a relative mandibular deficiency secondary to the vertical maxillary excess. There not only was vertical skeletal dysplasia but also excessive vertical alveolar development with the posterior teeth super-erupted. Upon smiling, the patient showed prominent buccal corridors caused by the maxillary transverse deficiency. She was diagnosed with vertical maxillary

excess, transverse maxillary deficiency, apertognathia, and a Class II subdivision left malocclusion.

Treatment objectives

The goals of treatment were:

1. Establish ideal overbite and overjet and with a good functional Class I occlusion bilaterally;
2. Correction of maxillary transverse deficiency with surgically-assisted rapid maxillary expansion (SARME), also referred to more recently as maxillary transverse distraction osteogenesis;¹³
3. Correction of vertical maxillary excess with a superiorly repositioned LeFort I osteotomy;

TABLE 1. Pretreatment and Posttreatment Cephalometric Measurements^a

	Mean	SD	Pretreatment	Posttreatment	Change
Horizontal skeletal					
N-A-Pg angle	2.6	5.1	11	2	9
N-A (//HP)	-2	3.7	-1.5	0	1.5
N-B (//HP)	-6.9	4.3	-14	-9	5
N-PG (//HP)	-6.5	5.1	-15	-7	8
Vertical skeletal					
N-ANS (⊥ HP)	50	2.4	59	63	4
ANS-Gn (⊥ HP)	61.3	3.3	84	67	-17
N-PNS (⊥ HP)	50.6	2.2	59	55	-4
MP - HP angle	24.2	5	42	34	-8
Ar-Go-Gn angle	122	6.9	138	132	-6
Soft tissue facial form					
Facial convexity angle G-Sn-Pg'	12	4	18	14	-4
Maxillary projection G-Sn (//HP)	6	3	6	7	1
Mandibular projection G-Pg' (//HP)	0	4	-9	-1	8

^a SD indicates standard deviation;

- 4. Correction of mandibular deficiency with a LeFort I osteotomy to raise the occlusal plane and allow for mandibular autorotation and mandibular advancement by means of a bilateral sagittal split ramus osteotomy;
- 5. Correction of chin deficiency with an advancement genioplasty (and vertical reduction).

There were few nonsurgical alternatives to the proposed treatment. The magnitude of the open bite did not allow for correction by orthodontic eruption of the dentition. In addition, with four permanent teeth already missing, it was deemed unacceptable to extract four additional permanent teeth (either bicuspid or second molars) to attempt to correct the open bite or crowding. Even if extractions had been performed, an esthetic, stable, and predictable treatment outcome would not likely have been feasible.

Treatment progress

The patient and her mother were presented with the treatment outlined above. Both agreed to pursue a two-stage surgical correction for the malocclusion. Spacers were placed, and the patient returned one week later for banding. Appropriately sized bands were selected and placed on the maxillary second premolars, maxillary first molars, and maxillary second molars. A custom Hyrax expansion appliance was fabricated and cemented along with bands on the mandibular first molars and mandibular second molars. The posterior teeth were all banded at one appointment because of the mitral valve prolapse and a desire to keep the number of American Heart Association antibiotic prophylaxis doses to a minimum. The patient was sent to surgery for completion of a SARME (Figure 3). The osteotomy was carried out using standard techniques with osteotomies of the lateral maxilla, lateral nasal wall, pterygoid plates, and a single osteotomy of the palate slightly to one side of the middle sagittal plane. The expansion appliance was activated approximately two–three mm intraoperatively to as-

sure complete mobilization of the maxilla. After checking for complete mobilization, the appliance was returned to its starting point. A one-week healing and latency period was observed after which the appliance was activated four turns daily, twice in the morning and twice in the evening, for a total of one mm per day. The patient was observed twice weekly until complete correction of the maxillary transverse deficiency was observed. The day the expansion appliance was tied off, a midline diastema of 10 mm was present. Brackets were placed and a 0.016-inch stainless steel archwire with passive coil spring was placed between the central incisors. This wire was placed to prevent initial diastema closure caused by the pull of the transseptal fibers, which may cause excessive tipping of the teeth into an area of immature bone.

During the course of the expansion, the initial cant of the frontal occlusal plane increased. The left half of the anterior maxilla appeared to be positioned more inferiorly (Figure 4). A unilateral intrusive base arch was placed to intrude the maxillary left lateral and maxillary left central incisor to the pretreatment level. Full correction of the frontal occlusal plane was not achieved until the second stage of surgery. The surgical expansion created enough room within the maxillary arch to align all teeth without the need for further extraction. In addition, root divergence was achieved between the maxillary lateral incisors and canines for adequate interdental osteotomy sites. Concurrent with the maxillary expansion and alignment, the mandibular arch was bonded and aligned. The mandibular arch was used as the template arch for arch coordination purposes.

Preorthognathic surgical models, radiographs, and photographs (Figure 5) were obtained approximately 10 months after the SARME. The second stage of surgery (Figure 6) involved a segmental LeFort 1 procedure with approximately five mm of posterior impaction to allow mandibular autorotation. The autorotation serves to correct the anterior open bite, decrease lower face height, and steepen the max-

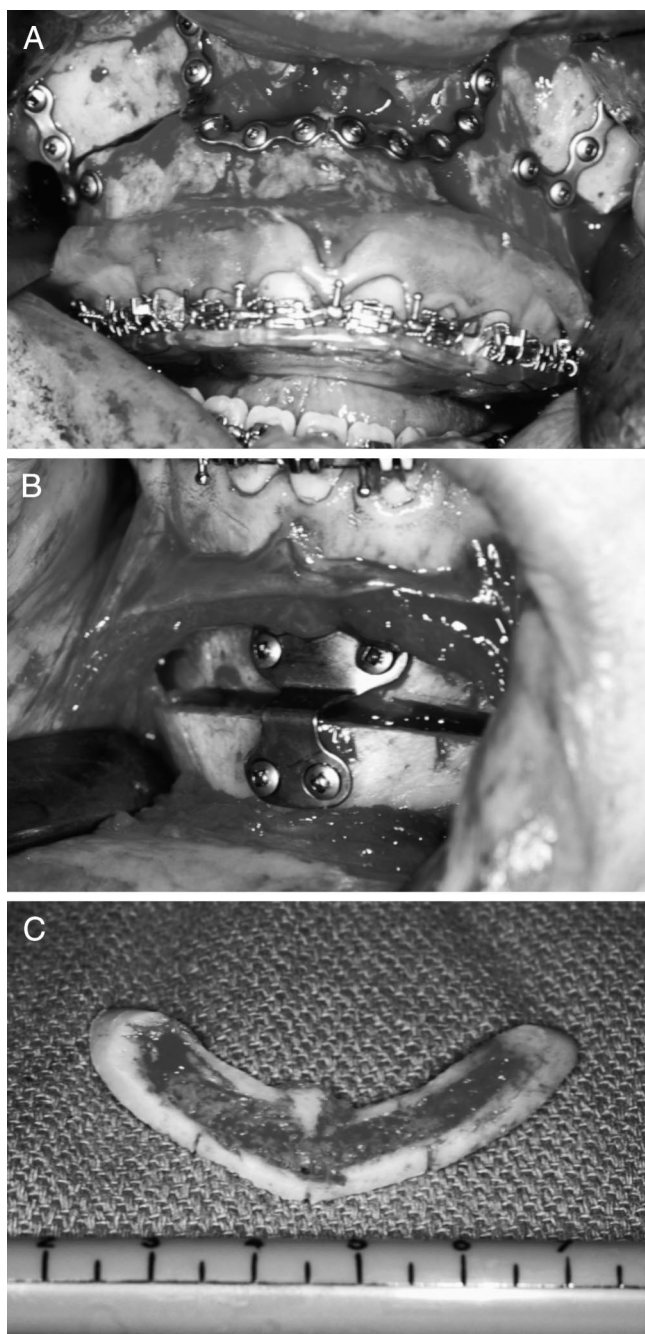


FIGURE 6. (A–C) Operative photos of the segmental LeFort I osteotomy, the vertical reduction genioplasty, and the wedge of bone that was removed. In addition, a bilateral sagittal split ramus osteotomy was performed to advance and rotate the mandible to a Class I molar and canine position with ideal overbite and overjet.

illary occlusal plane. As an adjunct, an advancement genioplasty with vertical reduction was performed to enhance the anterior projection of the lower third of the face and reduce the lower face height. The maxilla was segmented between the lateral incisors and the canines to facilitate differential movement between the anterior and posterior maxilla. Although the SARME provided enough room to align

the dentition, no attempt was made to level the maxillary arch orthodontically. The frontal occlusal plane was canted slightly (the left side being more occlusal than the right) and was differentially impacted to produce a level frontal occlusal plane. On the basis of the hand and computer prediction tracings, the mandible was going to autorotate into an appropriate anterior-posterior position, but an intraoral vertical ramus osteotomy (IVRO) was performed to close the gonial angle and accommodate the occlusal plane change.

The patient was placed in intermaxillary fixation for two weeks, and the surgical splint was wired to the maxillary arch for a total of six weeks. The day that the splint was removed, a continuous maxillary archwire was placed in addition to a passive 0.036-inch stainless steel heat-treated transpalatal arch to aid in maintaining the transverse dimension.

RESULTS

A dramatic improvement in facial height and occlusal function was realized with the completion of treatment (Figure 7). The lip competency, tooth-to-lip at rest, and at smile and facial contour was significantly improved. The patient was very satisfied with the results of treatment. The excessive vertical dysplasia was dramatically reduced, and most of the cephalometric values were brought into the normal range (Table 1). The mandibular plane angle was significantly reduced, mandibular anterior-posterior position was improved, and an ideal overjet and overbite were established (Figure 8). Because of a maxillary Bolton tooth mass deficiency, a slight space was left distal to the maxillary lateral incisors for cosmetic bonding or veneers.

DISCUSSION

The classical technique of closing a skeletal open bite in a patient with a long face involves a LeFort I osteotomy, impaction of the maxillary posterior dentition to allow mandibular autorotation, an increased steepness of the maxillary occlusal plane, and then performing a mandibular ramus procedure to accommodate the occlusal plane change as well as the anterior-posterior change. The mandibular procedure may be a sagittal split ramus osteotomy if any advancement is required, or it may be an IVRO if there is to be either a mandibular setback or accommodation for any change in occlusal plane. Orthognathic surgery for correction of open bite malocclusion in this manner appears to have achieved much greater stability and esthetics than orthodontic anterior dental extrusion.¹⁴ In the hierarchy of surgical stability, maxillary impaction is among the most stable of all orthognathic surgical procedures.¹⁵

One possible variation to the proposed treatment plan would have been a segmental LeFort I osteotomy to differentially affect the posterior dentition and anterior dentition, widen the maxillary transverse dimension, and per-

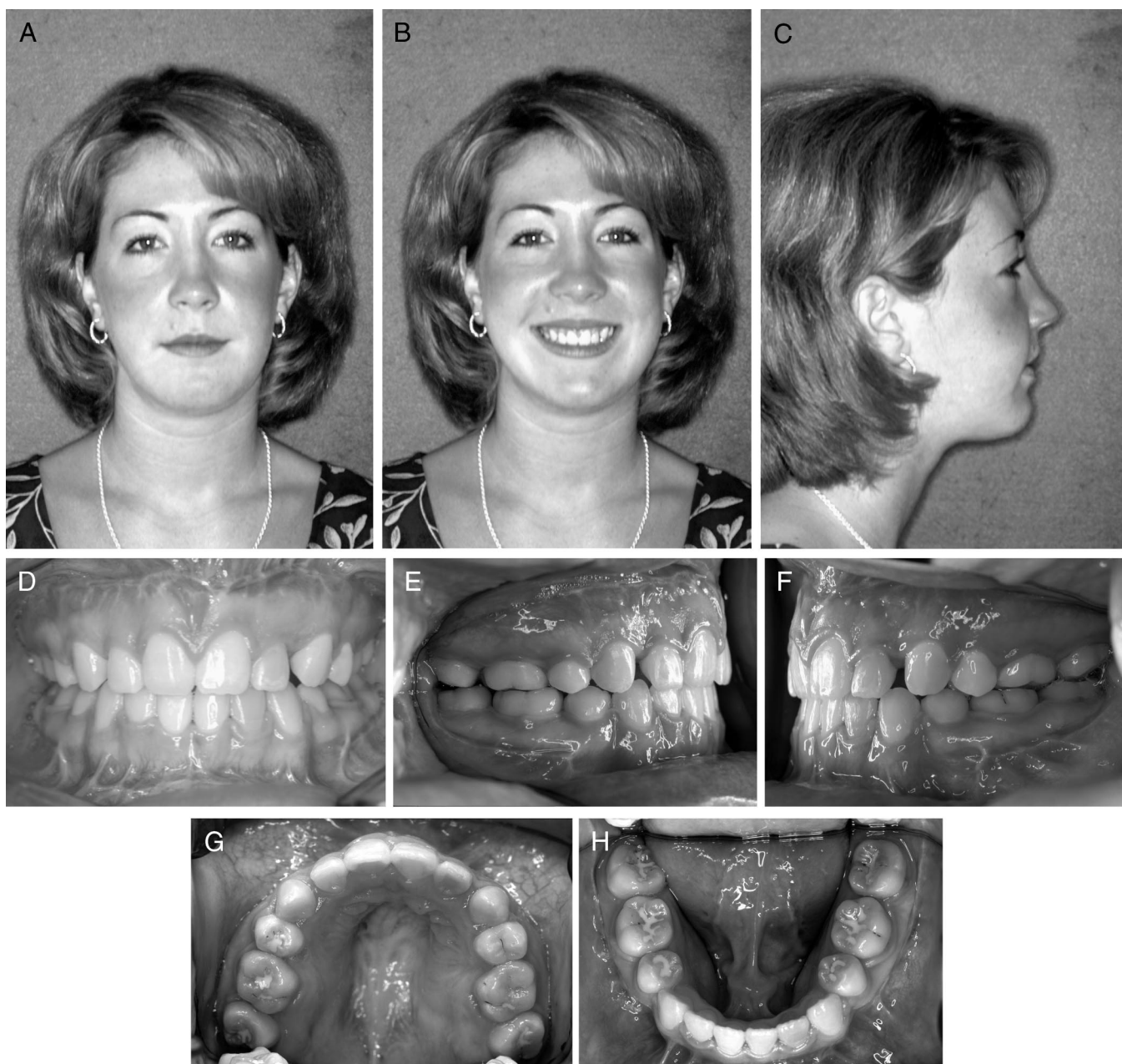


FIGURE 7. (A–H) Posttreatment photographs. Note the dramatic change in facial height as well as the relative maxillary and mandibular projection.

form a mandibular sagittal split osteotomy with advancement genioplasty to correct the mandibular deficiency. The advantage to widening with the segmental LeFort would be a single-stage rather than a two-stage surgery. Patients requiring two-stage surgery will occasionally undergo the first procedure only to decline any subsequent surgical procedures that will produce the necessary vertical and anterior-posterior changes. Typically, the maximum amount of transverse expansion that is practical with a segmental LeFort is 5–7 mm.¹⁶ After closely examining the transverse dimension of this patient with an occlusogram,^{17–19} the mag-

nitude of the maxillary transverse deficiency was determined to be too great to obtain both the transverse and vertical correction at the same time with a segmental LeFort (Figure 9). The occlusogram allows all the intended orthodontic movements in the anterior-posterior and transverse dimensions to be performed on an acetate tracing before treatment begins.

As a result, specific treatment goals and guidelines can be planned to determine whether the proposed treatment is practical before it is even initiated. In the occlusogram, the lingually inclined mandibular teeth were uprighted. The

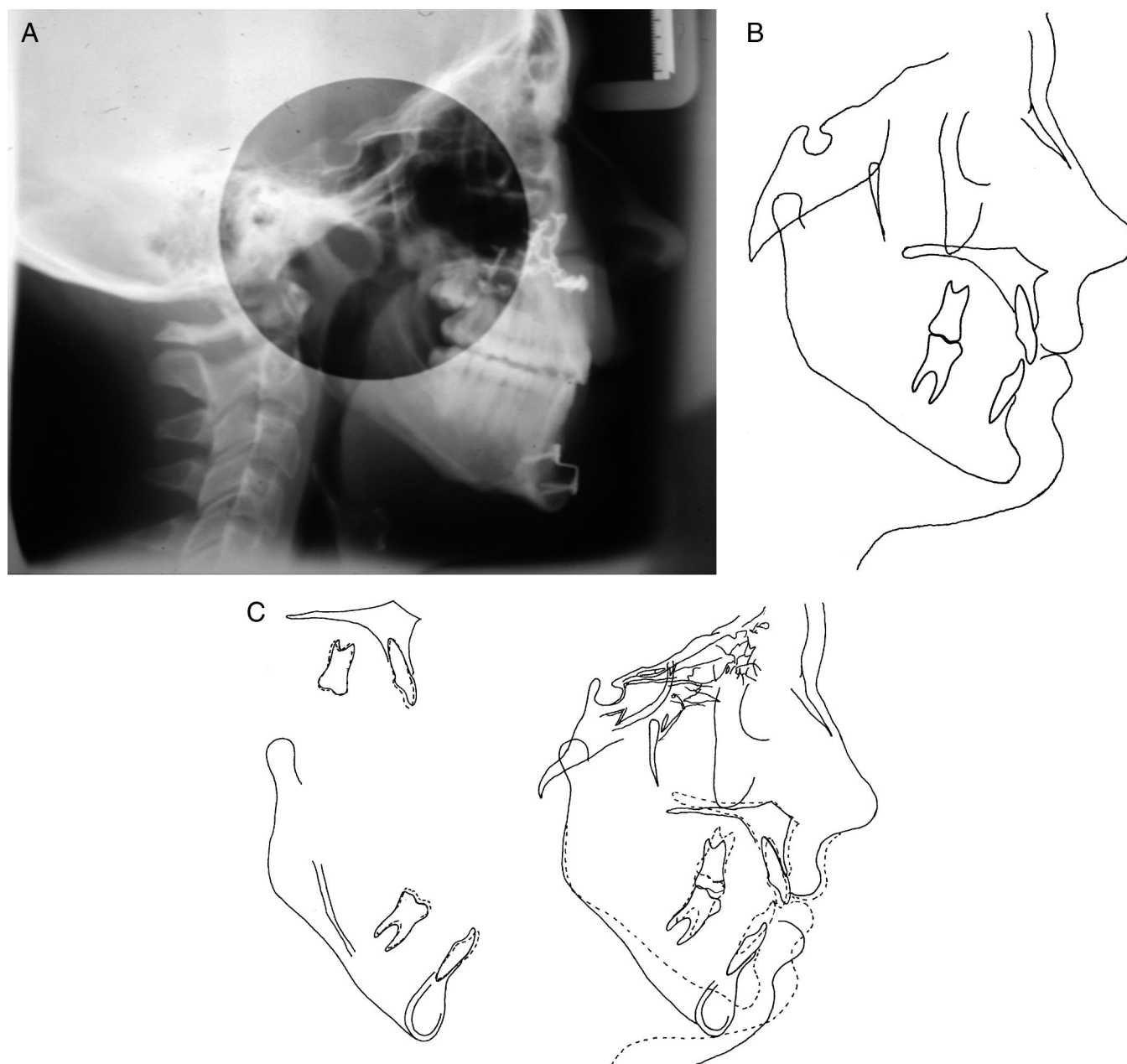


FIGURE 8. (A) Posttreatment cephalograph, (B) tracing, and (C) superimposition. The combined orthodontic and orthognathic surgical treatment was able to produce ideal overbite and lip competence, decrease the mandibular plane angle, and correct the facial heights. Research has shown that the patient should be able to expect a stable long-term result. As a result of minimal anterior extrusion, the stability of the treatment should be higher than an orthodontic-only approach to treatment. In addition, the extrusion of anterior teeth would have led to an even greater increase in the incisal display and produced a less esthetic result.

ideal buccal overjet was drawn to establish the required maxillary transverse dimension necessary to accommodate the mandibular arch. At this point, the difference between the current maxillary width and the required maxillary width was easily measured and found to be approximately 11 mm. The team believed that this transverse discrepancy was too great to correct in a stable and predictable manner with only a segmental osteotomy. The required stretch of the soft tissue pedicle would result in a constrictive force,

and the resulting relapse potential was determined to be too great.

The optimal surgical plan would have involved closure of the open bite solely with the maxillary procedure, for the stability of gonial angle changes is less than the stability of the maxillary impaction.²⁰ To close the open bite strictly with a maxillary procedure, a nine mm posterior impaction would have been necessary. The team believed that nine mm would be an impractical amount on the basis of the

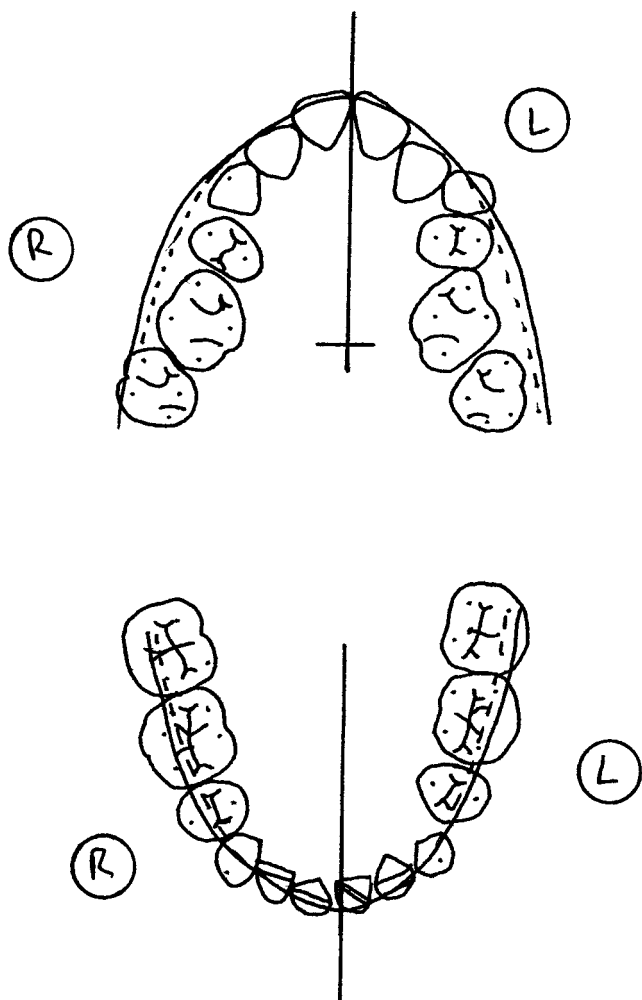


FIGURE 9. Occlusogram. All the treatment was predicted on this acetate tracing before performing a single orthodontic movement. The magnitude of the transverse discrepancy is easily viewed and measured as the distance from the maxillary cusp tips to the solid line (or from the maxillary contact points to the dashed line). These predictions allow for estimation of the efficacy of the treatment before initiating treatment, thereby producing a more efficient treatment time by having concrete, definable, and measurable treatment goals.

patient's anatomy and an already steep occlusal plane. In addition, elevating the maxilla nine mm created a distinct possibility of the superior maxilla telescoping the tooth-bearing portion of the maxilla, thereby creating a difficult fixation situation as well as a need for a bone graft and additional surgical morbidity.

At the time of appliance removal, two incisors appeared to have a slight grayish color. Examination of the radiographs before surgery, immediately after surgery, and at the day of appliance removal showed no periapical pathology. In addition, no visible radiographic evidence of surgical trauma to either the maxillary left lateral incisor or the mandibular left lateral incisor was present. Both of the teeth

were asymptomatic and are currently being followed by pulp testing.

Because of the tooth mass discrepancy between the maxillary and mandibular anterior teeth, slight spaces were left between the maxillary lateral incisors and the maxillary canines. The spaces were treatment planned for restoration by the general dentist with either bonding or veneers. It was impossible to close the space completely because there was no overjet, and a Class I molars and canine relationship was present bilaterally. Mild interproximal recontouring in the mandible could have been performed, but the shape of the mandibular incisors was not favorable.

CONCLUSIONS

This case illustrates the importance of proper diagnosis and treatment planning. A team approach with the orthodontist, surgeon, and restorative dentist all having input before the initiation of treatment is the best way to achieve stable, functional, and esthetic results. Through this combined approach, the patient had a dramatic skeletal, dental, and occlusal improvement. As an added benefit, the patient has reported a better self-esteem and a greater degree of pleasure related to her appearance.

ACKNOWLEDGMENT

We would like to thank Dr Scott B. Boyd, Professor and Chairman of Oral and Maxillofacial Surgery at Vanderbilt University Medical Center, for the necessary surgical expertise. His assistance in maximizing the patient's esthetic, functional, and occlusal improvement was invaluable.

REFERENCES

1. Woods MG, Nanda RS. Intrusion of posterior teeth with magnets. An experiment in growing baboons. *Angle Orthod.* 1988;58:136-150.
2. Woodside DG, Linder-Aronson S. Progressive increase in lower anterior facial height and the use of posterior occlusal bite-block in its management. In: Graber LW, ed. *Orthodontics: State of the Art, Essence of the Science*. St Louis, MO: Mosby; 1986:209-218.
3. Pearson LE. Vertical control in fully-banded orthodontic treatment. *Angle Orthod.* 1986;56:205-224.
4. Yamaguchi K, Nanda RS. The effects of extraction and nonextraction treatment on the mandibular position. *Am J Orthod Dentofacial Orthop.* 1991;100:443-452.
5. Kim YH. Anterior openbite and its treatment with multiloop edgewise archwire. *Angle Orthod.* 1987;57:290-321.
6. Epker BN, Fish LC. Surgical-orthodontic correction of open bite deformity. *Angle Orthod.* 1977;71:278-299.
7. Tulley WJ. The role of extractions in orthodontic treatment. *Br Dent J.* 1959;107:199-205.
8. Staggers JA. Vertical changes following first premolar extractions. *Am J Orthod Dentofacial Orthop.* 1994;105:19-24.
9. Nemeth RB, Isaacson RJ. Vertical anterior relapse. *Am J Orthod.* 1974;65:565-585.
10. Brammer J, Finn R, Bell WH, Sinn D, Reisch J, Dana K. Stability after bimaxillary surgery to correct vertical maxillary excess and mandibular deficiency. *J Oral Surg.* 1980;38:664-670.
11. Burstone CJ, James RB, Legan HL, Murphy GA, Norton LA.

- Cephalometrics for orthognathic surgery. *J Oral Surg.* 1978;36:269–277.
12. Legan HL, Burstone CJ. Soft tissue cephalometric analysis for orthognathic surgery. *J Oral Surg.* 1980;38:744–751.
 13. Legan HL. Orthodontic Planning and Biomechanics for Transverse Distraction Osteogenesis. *Semin Orthod.* 2001;7:160–168.
 14. Frost DE, Fonseca RJ, Turvey TA, Hall DJ. Cephalometric diagnosis and surgical-orthodontic correction of apertognathia. *Am J Orthod.* 1980;78:657–669.
 15. Proffit WR, Turvey TA, Phillips C. Orthognathic surgery: a hierarchy of stability. *Int J Adult Orthod Orthognath Surg.* 1996;11:191–204.
 16. Jacobs JD, Bell WH, Williams CE, Kennedy JW. Control of the transverse dimension with surgery and orthodontics. *Am J Orthod.* 1980;77:284–306.
 17. Faber RD. Occlusograms in orthodontic treatment planning. *J Clin Orthod.* 1992;26:396–401.
 18. White LW. The clinical use of occlusograms. *J Clin Orthod.* 1982;16:92–103.
 19. Marcotte MR. The use of the occlusogram in planning orthodontic treatment. *Am J Orthod.* 1976;69:655–667.
 20. McNeil RW, Hooley JR, Sundberg RJ. Skeletal relapse during intermaxillary fixation. *J Oral Surg.* 1973;31:212–227.