

# Maxillary Expansion and Protraction in Correction of Midface Retrusion in a Complete Unilateral Cleft Lip and Palate Patient

Masayoshi Kawakami, DDS, PhD<sup>a</sup>; Takakazu Yagi, DDS, PhD<sup>b</sup>; Kenji Takada, DDS, PhD<sup>c</sup>

**Abstract:** A 7-year-old girl with a cleft lip and palate had a midface retrusion due to growth inhibition of the maxillary complex. She presented for correction of a severe total crossbite with a Class III skeletal pattern. Initially, maxillary expansion was provided to widen the maxilla and then maxillary protraction headgear was worn to improve the sagittal skeletal relation. Fixed orthodontic appliances were placed to align the dentition and Class III elastics were used to establish intercuspation and stability. The maxillary expansion and protraction usually provide effective improvement in skeletal Class III patients with repaired cleft lip and palate patients. The success of the orthopedic procedure essentially depends on the individual growth of the maxilla and the mandible. This case report shows the significant growth of the mandible after maxillary expansion and protraction in late adolescence. (*Angle Orthod* 2002;72:355–361.)

**Key Words:** Maxillary protraction; Cleft lip; Cleft palate; Mandibular growth

## INTRODUCTION

The most common craniofacial malformation that an orthodontist will encounter is a cleft lip and palate. A patient presenting with a cleft lip and cleft palate and maxillomandibular positional deformity is likely to have a midface retrusion with mandibular prognathism. Skeletal Class III patients with a retrognathic maxilla resulting from a repaired cleft lip and palate can be effectively improved with maxillary expansion and protraction.<sup>1</sup> However, the success or failure of such orthopedic treatment is substantially dependent on the individual potential for growth.<sup>2,3</sup> This article presents the case of a patient with unilateral cleft lip and palate treated with orthodontic and orthopedic intervention who underwent significant growth of the mandibular condyle during the late pubertal period.

## Patient history, clinical examination, and diagnosis

The patient was referred for treatment at the age of 7 years and 10 months. She was born with a unilateral cleft lip and palate and both clefts were surgically repaired at an early age. On initial examination, the patient demonstrated mandibular prognathism, a concave soft tissue profile, an inverted upper lip outline, and an everted lower lip (Figure 1). The maxillary teeth were completely contained behind the mandibular teeth in a total crossbite with an overjet of –8.5 mm and an overbite + 6.3 mm. A mesial step relationship of the deciduous molar was present and the right upper second premolar and left upper lateral incisor were congenitally missing. The maxillary buccal segments were collapsed bilaterally, with the deciduous canines, deciduous first molars and the permanent first molars all within the lower buccal segment. The lower dental arch exhibited mild crowding in the permanent incisors (Figures 2 and 3). Cephalometric analysis of the skeletal relations indicated a maxillary growth deficiency with an ANB angle of –2.0°. The mandible was prognathic with a mandibular plane angle (SN-MP) of 33.0° (Figure 4). The overall facial profile was mildly convex. The mandibular incisors were slightly proclined, whereas the maxillary incisors had an average inclination.

## Treatment prognosis

The primary treatment objectives were to correct the total crossbite and encourage maxillary growth in an anterior

<sup>a</sup> Assistant Professor, Department of Oral Maxillofacial Surgery, Nara Medical University, Nara, Japan.

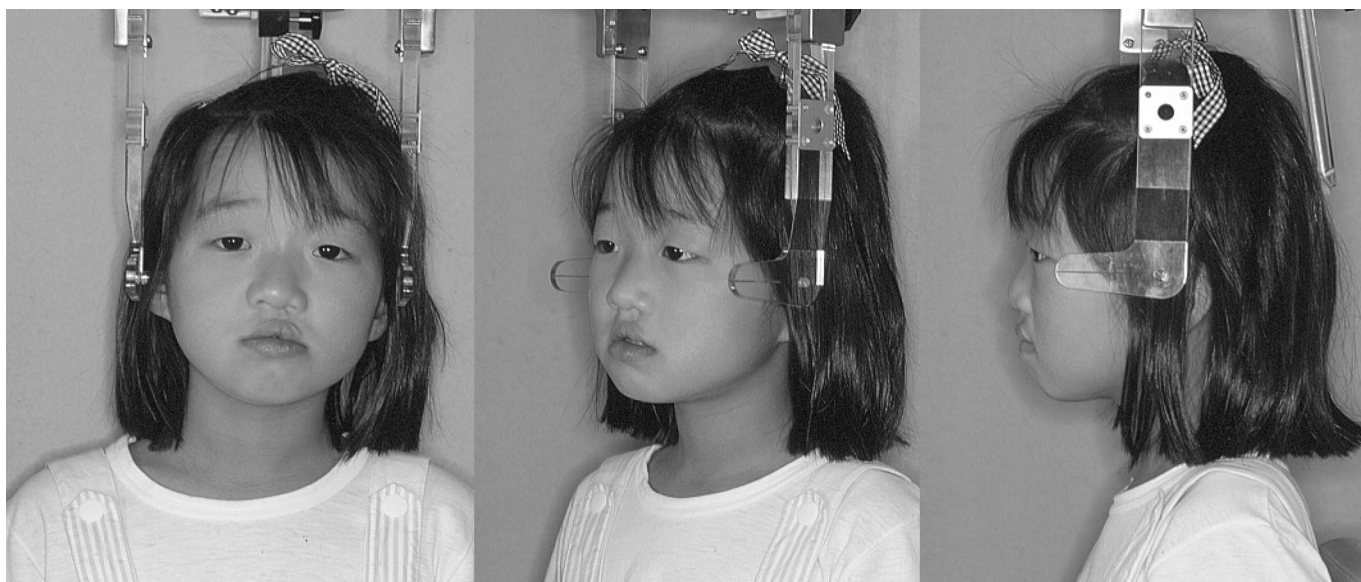<sup>b</sup> Staff of Department of Dentistry and Oral Maxillofacial Surgery, NTT West Osaka Hospital, Osaka, Japan.

<sup>c</sup> Professor and Chair, Department of Orthodontics and Dentofacial Orthopedics, Osaka University Graduate School of Dentistry, Osaka Japan.

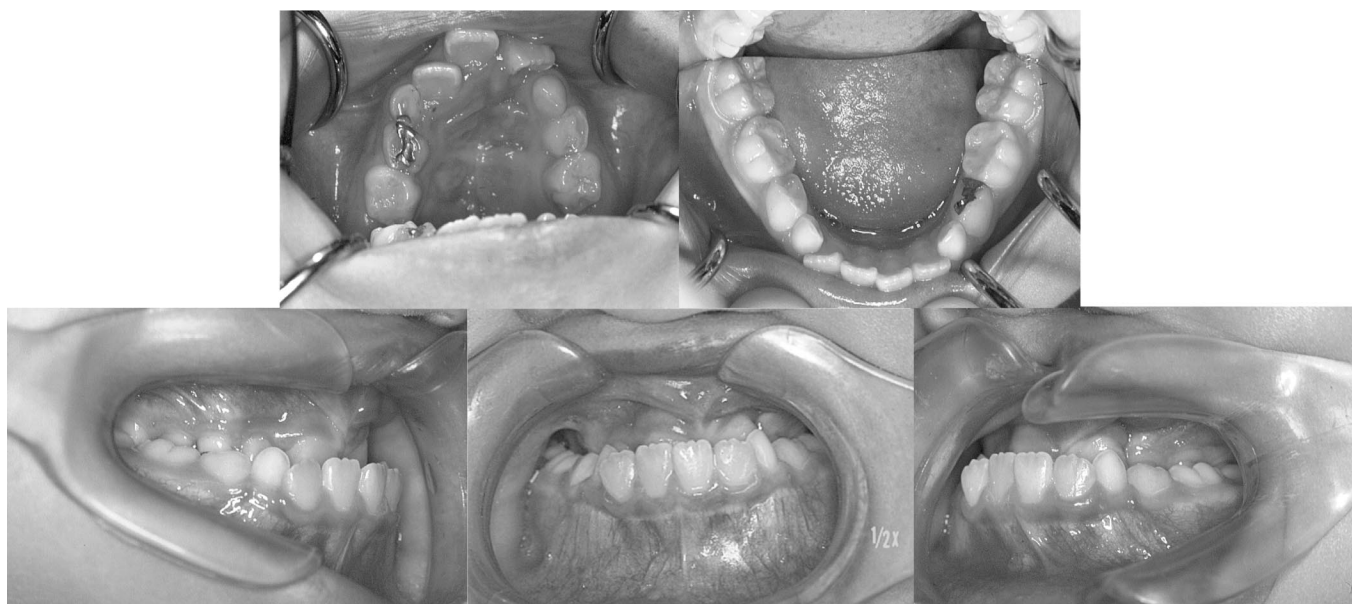Corresponding author: Masayoshi Kawakami, DDS, PhD, Department of Oral Maxillofacial Surgery, Nara Medical University, 840 Shijo-cho Kashihara, Nara, 634–8522, Japan (e-mail: mkawaka@naramed-u.ac.jp).

Accepted: December 2001. Submitted: March 2002.

© 2002 by The EH Angle Education and Research Foundation, Inc.



**FIGURE 1.** Initial facial photographs.



**FIGURE 2.** Initial intraoral photographs.

direction. Treatment was initiated by placing a rapid maxillary expansion appliance with occlusal acrylic coverage to expand the collapsed maxillary buccal segments while opening the bite to free up the occlusion during expansion (Figure 5). Advancing the jackscrew a quarter turn every other day activated the appliance. At 8 years and 4 months, and after bilaterally expanding the maxilla 9.8 mm, a mask type maxillary protraction headgear was used for the anterior protraction of the maxillary complex. The headgear applied 400–500 g of force with 5/16-inch elastics and was accompanied by a chin cup for anchorage for the forward

protraction. The patient was advised to wear the protraction headgear at least 14 hours each day.

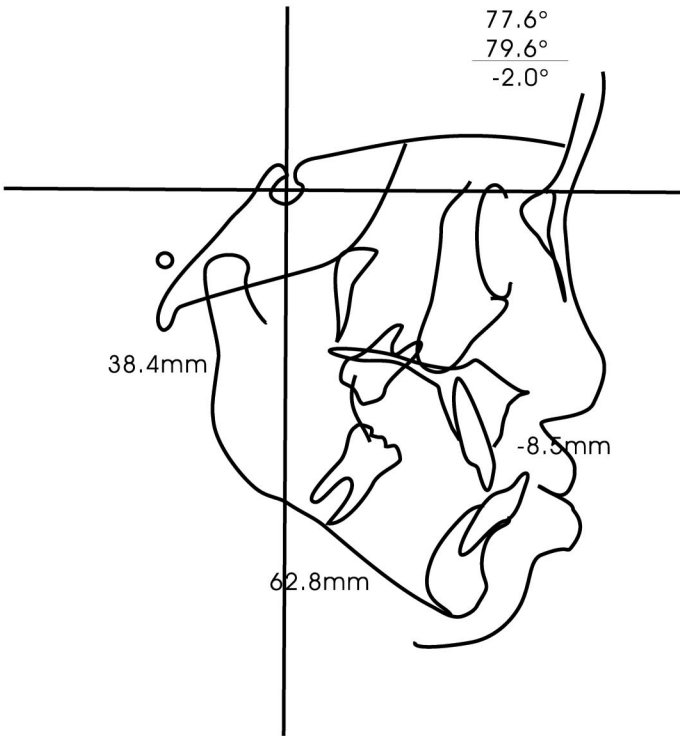
Excellent patient cooperation helped to attain the first stage of clinical treatment. The SNB angle decreased from  $79.6^\circ$  to  $75.3^\circ$  and the ANB angle increased from  $-2.0^\circ$  to  $1.0^\circ$ , resulting in a downward movement of point B. The mandibular plane angle (SN-MP) increased from  $33.0^\circ$  to  $39.4^\circ$  while the palatal plane inclination was maintained (Figure 6; Table 1). The maxilla moved anteriorly and the mandible rotated downward, with an increase in the mandibular plane angle (Figure 6). Iliac bone grafting was per-

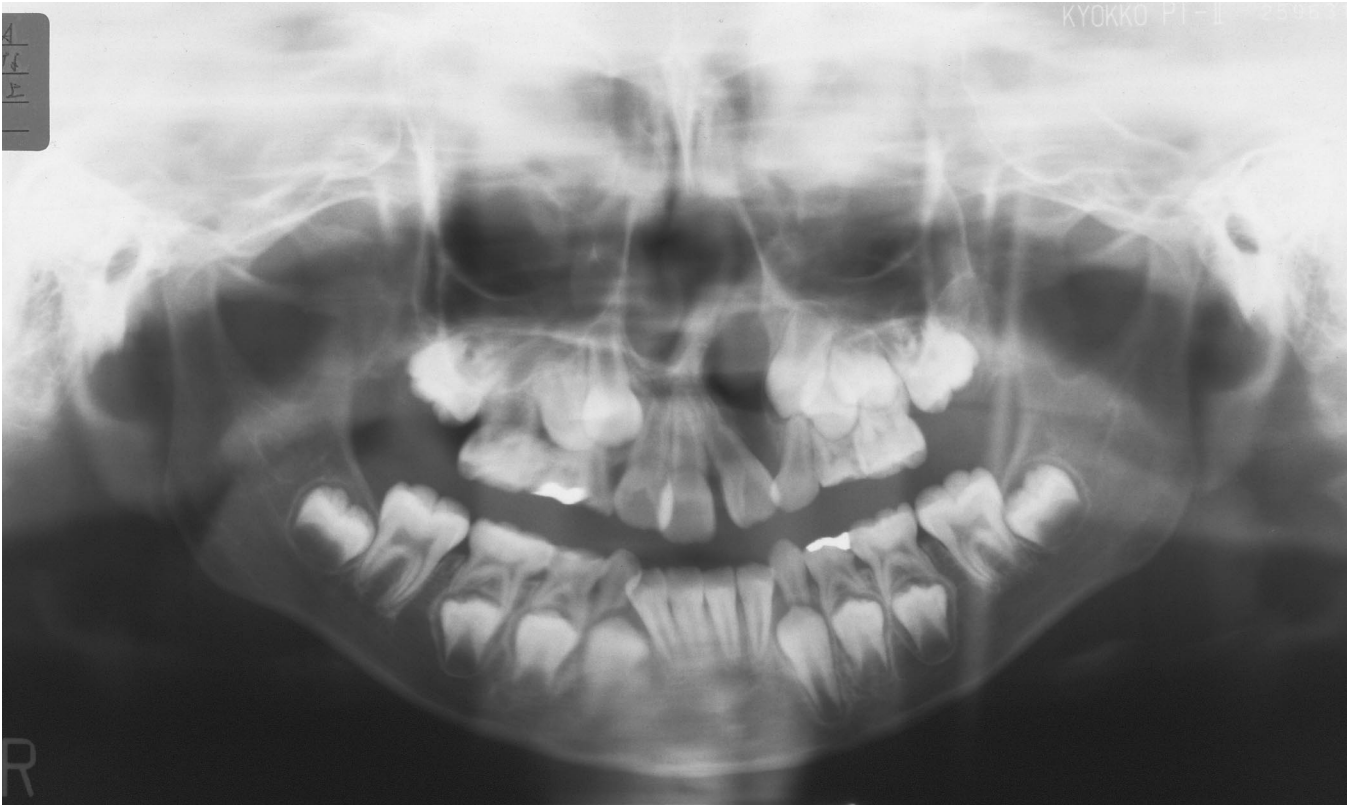
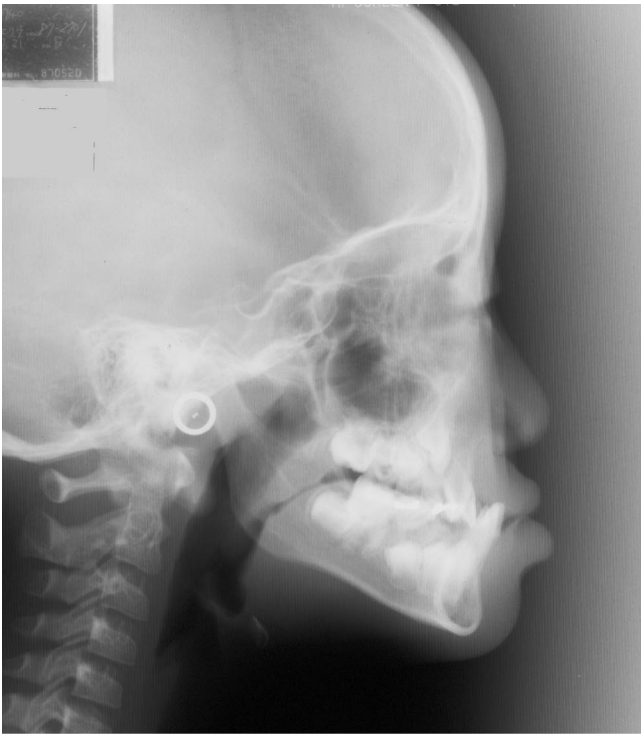
FIGURE 3. Initial panoramic radiograph.



A



B

FIGURE 4. Initial lateral cephalometric radiograph (A) and its tracing (B).



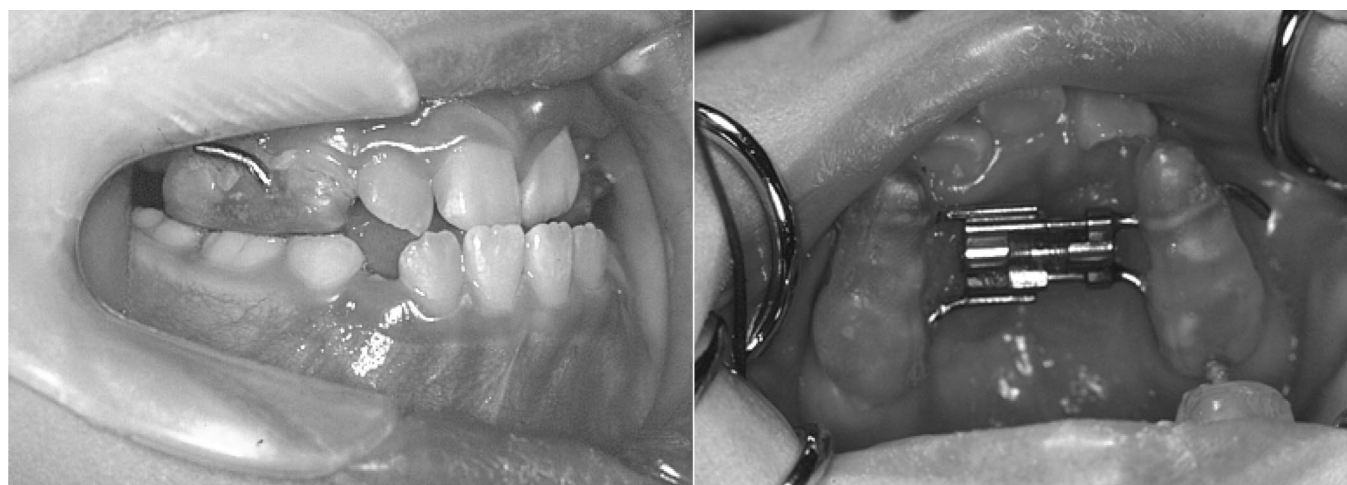

FIGURE 5. Progress intraoral photographs with expansion appliance in place.

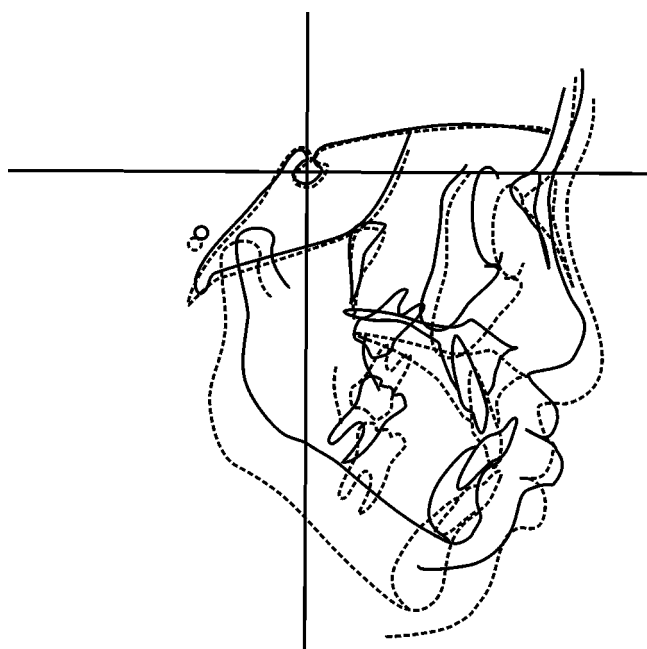


FIGURE 6. Cephalometric tracings and superimpositions at the ages of 7 years 4 months and 15 years 4 months.

formed at 14 years and 4 months of age to aid in the stabilization of the maxillary arch length, width, and symmetry. Nose and lip revisions were performed the following year.

At 15 years and 4 months, when eruption of the permanent dentition was complete except for the congenitally missing teeth and the third molars, the use of the protraction headgear was stopped and a 0.018-inch preadjusted edge-wise appliance was placed in the maxillary and mandibular dentition. After a short time, the overjet and overbite decreased, probably due to unanticipated mandibular growth although she had passed the age of peak velocity of height

TABLE 1. Cephalometric Analysis

	Pretreatment 7y10m	Active treat- ment 15y4m	Posttreat- ment 20y4m	Reten- tion 22y4m
SNA (deg)	77.6	76.3	76.7	76.7
SNB (deg)	79.6	75.3	74.6	74.6
ANB (deg)	-2.0	1.0	2.1	2.1
Mand.pl to SN (deg)	33.0	39.4	38.3	39.6
G0-Me (mm)	62.8	68.5	68.0	69.8
Ar-Go (mm)	38.4	41.0	45.8	45.8
Ar-Me (mm)	92.9	100.1	102.4	102.6
Overjet (mm)	-8.5	-1.5	1.6	1.6
Overbite (mm)	6.3	-1.3	0.8	0.8
Ptm-ANS/NF (mm)	44.2	44.9	44.8	47.2

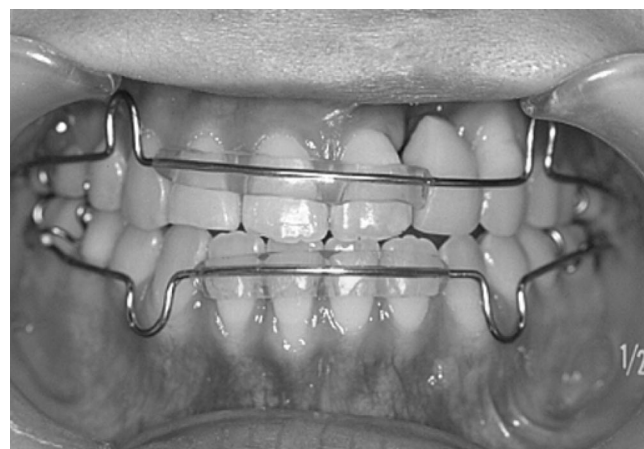
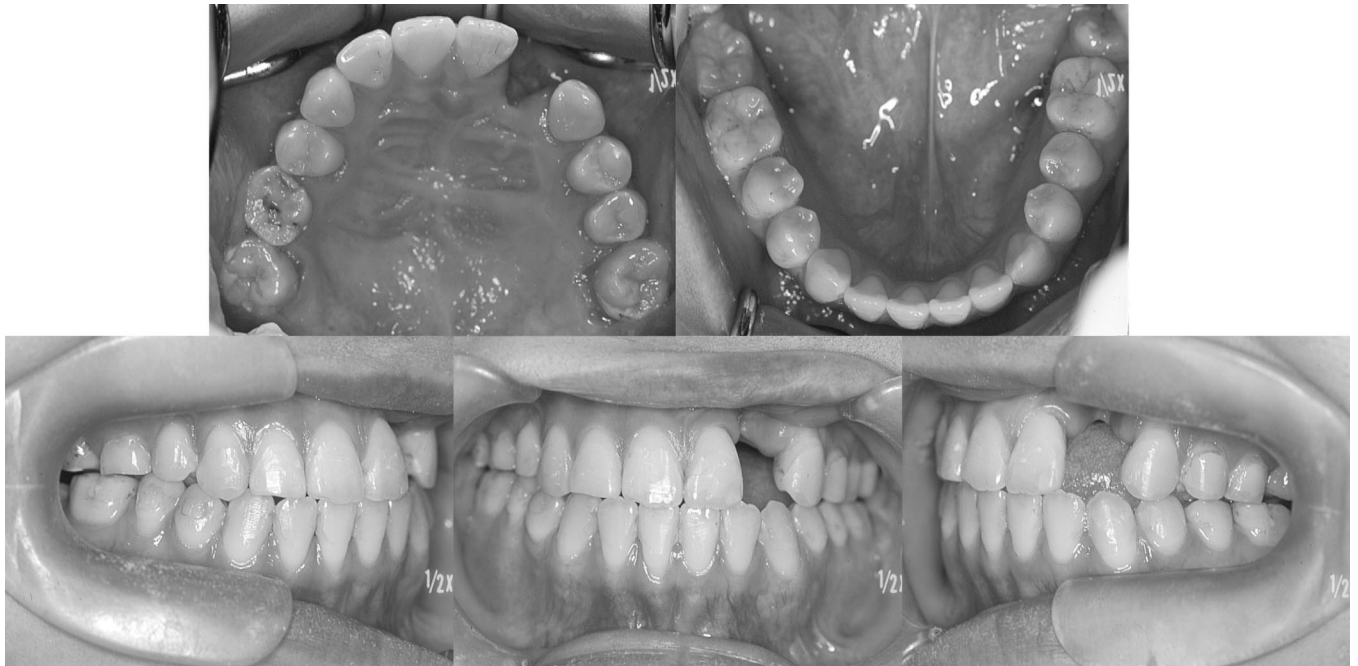


FIGURE 7. Intraoral photographs after active treatment.

growth. The possibility of surgical correction for the mandibular prognathism was suggested, but because the patient and her parents did not want the surgery, we continued with orthodontic treatment alone.

We established a new treatment that included bilateral



**FIGURE 8.** Intraoral photographs at the retention phase.

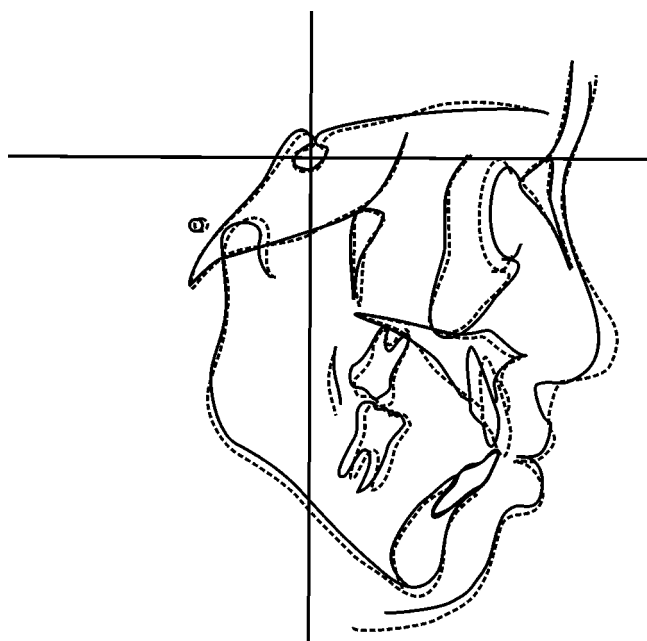


**FIGURE 9.** Facial photographs after active treatment.

extraction of the lower third molars and the use of Class III elastics to procline the upper central incisors and retrocline the lower incisors. At 20 years and 6 months of age, the edgewise treatment was complete and the use of a removable acrylic retainer for the maxillary arch was started (Figure 7). The patient has continued postretention follow-up visits.

## RESULTS

Posttreatment orthodontic records revealed a well-interdigitated and aligned dentition, with a Class I occlusion on both sides allowing the maxillary right deciduous second molar to be used as the missing premolar (Figure 8). The profile was straighter than normal, but the overall appear-

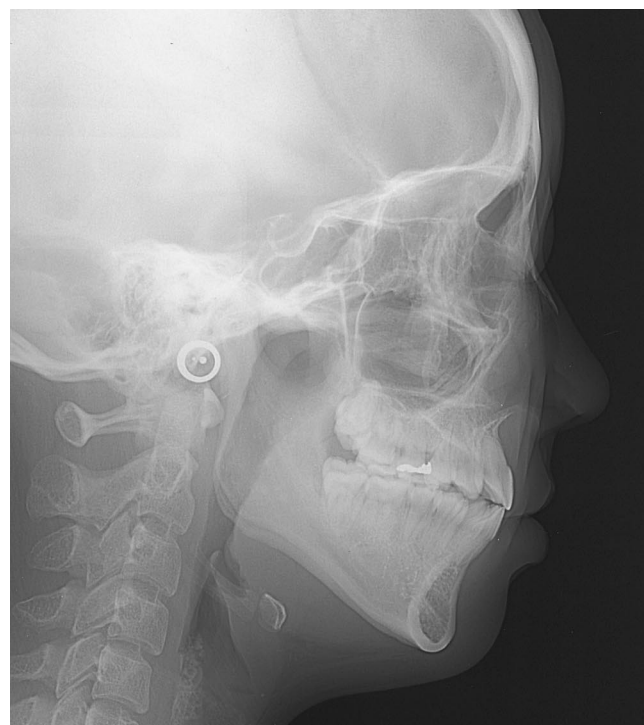

**FIGURE 10.** Cephalometric tracings and superimpositions at the ages of 15 years 4 months and 20 years 4 months.

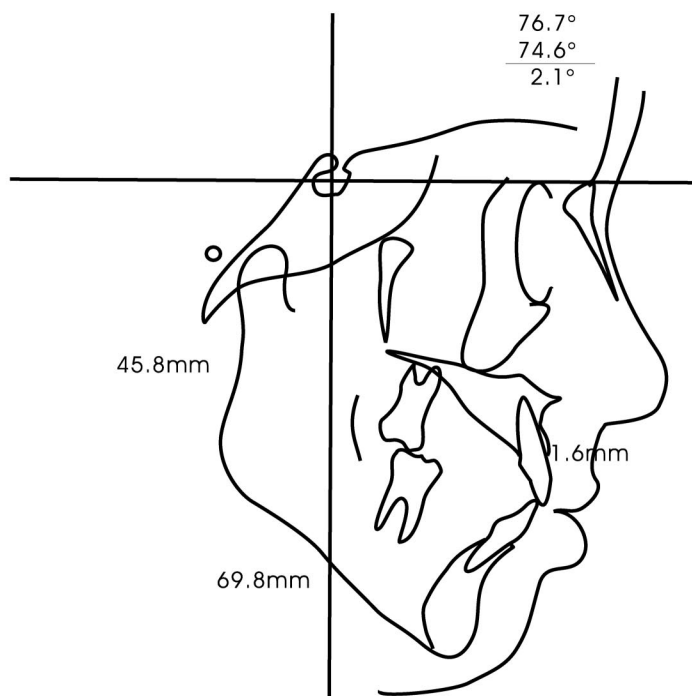
ance of the face was still very good (Figure 9). Superimposition of the initial tracing and the retention lateral cephalograms showed downward growth of the mandible (Figures 10 and 11). The measurement of mandibular height revealed a marked vertical growth of 4.7 mm at Ar-Me, whereas no substantial growth of the maxilla was seen (Figure 12; Table 1). The growth was slightly vertical and exceeded normal limits. A bonded bridge will replace the missing maxillary left lateral incisor after sufficient retention. Maxillary and mandibular removable retainers are being continued as stability is evaluated.

## DISCUSSION

The comprehensive orthodontic treatment was initiated at 15 years of age. Very large amounts of mandibular growth were observed between the onset of her menstruation until the treatment was completed at 20 years of age. The mandibular height increased 4.9 mm at Ar-Go and 2.5 mm at Go-Me. These amounts are significantly larger than those in other repaired cleft lip and palate patients.<sup>4</sup> Girls, in general, show the average age of the maximum peak growth of the craniomaxillary component between 10 and 12 years old.<sup>5</sup> Since the growth of the face is completed in girls at the age of about 15 years, subsequent developmental changes should be minimal. An exception is in girls in whom the mandible continues to show growth, even though



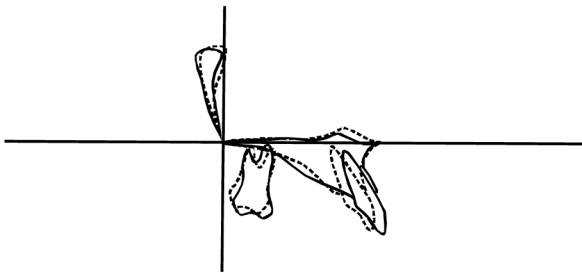
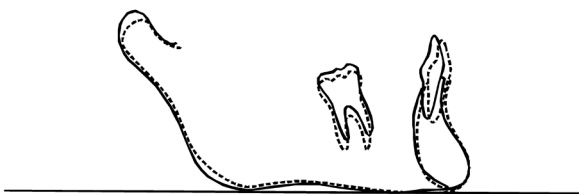**A**



**B**

**FIGURE 11.** Lateral cephalometric radiograph (A) and its tracing (B) at the retention phase.



*Superimposed on Palatal plane at Ptm'**Superimposed on Mandibular plane at Me*

**FIGURE 12.** Superimpositions on the palatal plane at Ptm' and on mandibular plane at Me at 15 years 4 months and 20 years 4 months.

such growth is at a rate several times slower than the rate shown during puberty.<sup>6</sup> This case clearly demonstrated continuous growth at the mandibular condyle in a girl even after 15 years of age.

Anterior crossbite is often found in repaired cleft lip and palate patients. An underdeveloped maxilla in these patients often results in skeletal crossbites, posterior crossbites, or both, with a midface retrusion.<sup>1</sup> There are many reports concerning the effects of orthopedic devices like the maxillary protraction headgear with a chin cup.<sup>2,7,8</sup> Treatment with maxillary protraction headgear induces significant skeletal and dentoalveolar changes. Transverse expansion and anterior protraction of the maxillary complex is an essential therapy to correct anterior and posterior crossbites during the deciduous and early mixed dentition and to obtain an optimal alveolar cleft space to enhance tooth eruption and alveolar development. Indeed the major effect of maxillary protraction is downward and backward movement of the mandible combined with retroclination of the mandibular incisors.<sup>3</sup>

The backward positioning of the mandible by a downward and backward rotation was greater than the forward

movement of the maxilla in the treatment using the maxillary protraction appliance with the chin cup.<sup>9</sup> The treatment effect of increased overjet was diminished, mainly due to proclination of the mandibular incisors. Such a relapse has been demonstrated in a previous study<sup>10</sup> and may be due to removal of the restriction forces from the chin cup portion of the protraction headgear. Thus, proclination of the upper central incisors and retroclination of the lower incisors using Class III elastics after extraction of bilateral lower third molars is one of the possible procedures to avoid surgical correction to the mandible. It is obvious that maxillary protraction and expansion of the maxillary arch is necessary in the orthodontic treatment protocol for repaired cleft lip and palate. However, it is suggested that continuous growth of the mandibular condyle should be carefully monitored after maxillary protraction even when the peak velocity has passed.

## REFERENCES

1. Bhatia S, Nanda RS. Role of protraction headgear in correction of a skeletal midface deficiency in a unilateral cleft lip and palate—an interim case report. *Amer J Orthod Dentofacial Orthop.* 1994;105:529–535.
2. Chen KF, So LL. Sagittal skeletal and dental changes of reverse headgear treatment in Chinese boys with complete unilateral cleft lip and palate. *Angle Orthod.* 1996;66:363–372.
3. Chong YH, Ive JC, Artun J. Changes following the use of protraction headgear for early correction of Class III malocclusion. *Angle Orthod.* 1996;66:351–362.
4. Hayahi I, Sakuda M, Takimoto K, Miyazaki T. Craniofacial growth in complete unilateral cleft lip and palate: a roentgenoccephalometric study. *Cleft Palate J.* 1976;13:215–237.
5. Takada K, Petdachai S, Sakuda M. Changes in dentofacial morphology in skeletal Class III children treated by a modified maxillary protraction and a chin cup: a longitudinal cephalometric appraisal. *Eur J Orthod.* 1993;15:211–221.
6. Smahel Z, Mullerova Z. Postpubertal growth and development of the face in unilateral cleft lip and palate as compared to the pubertal period: a longitudinal study. *J Craniofac Genet Dev Biol.* 1996;16:182–192.
7. Tindlund RS, Rygh P, Boe OE. Orthopedic protraction of the upper jaw in cleft lip and palate patients during deciduous and mixed dentition periods in comparison with normal growth and development. *Cleft Palate J.* 1993;30:182–194.
8. Wisth PJ, Tritapunt A, Rygh P, Boe OE, Norderval K. The effect of maxillary protraction on front occlusion and facial morphology. *Acta Odontol Scand.* 1987;45:227–237.
9. Bell WH, Proffit WR, White RP, eds. *Surgical Correction of Dentofacial Deformities*. Philadelphia, Penn: WB Saunders; 1980: 442–473.
10. Ishii H, Morita S, Takeuchi Y, Nakamura S. Treatment effect of combined maxillary protraction and chin cup appliance in severe skeletal Class III cases. *Amer J Orthod Dentofacial Orthop.* 1987; 92:304–312.