

Mandibular Symphyseal Distraction Osteogenesis: Diagnosis and Treatment Planning Considerations

Richard Conley, DMD^a; Harry Legan, DDS^a

Abstract: Treatment planning decisions in the transverse dimension have historically been based on the presenting mandibular arch width and form. Distraction osteogenesis (DO), originally developed by Russian orthopedic surgeon Ilizarov, has produced significant results in limb lengthening. Mandibular symphyseal DO was introduced by Guerrero, providing a new paradigm for patients whose treatment alternatives and results were previously limited. Orthodontic and surgical techniques and principles will be shown using completed and current cases. (*Angle Orthod* 2003;73:3–11.)

Key Words: Mandibular symphyseal distraction osteogenesis; Diagnosis; Mandibular transverse deficiency; Brodie bite

INTRODUCTION

Advances in the field of orthopedic surgery have shown dramatic changes in limb length using the technique of distraction osteogenesis (DO).¹ Several investigators have adapted these advances to the facial skeleton to change the anterior-posterior position of the jaws with good success.^{2,3} Historically, the mandibular arch dimension has been considered immutable. Mandibular arch expansion has been attempted with a variety of methods including Schwarz plates, lingual arches,⁴ functional appliances,⁵ and arch wires.⁶ Typically, each of these methods has produced limited dimensional change with questionable long-term stability.⁷ Adapting the Ilizarov treatment protocol to the mandibular symphysis can produce a regenerate bone thereby adding dimension to the innate basal bone. The additional basal bone and arch dimension can then be used to produce a potentially greater effect than previous expansion methods. Currently, only a limited number of practitioners have realized the potential benefits of mandibular symphyseal distraction to widen the mandible. The principal factors and their effects in the diagnosis and treatment of mandibular transverse deficiency and symphyseal DO will be presented.

Interarch transverse relationship

Dental crossbites may involve only a few teeth but may also involve segments of teeth or the entire dentition. A

dental crossbite often exhibits aberrant buccal-lingual inclinations of one or more teeth. With skeletal crossbites, the transverse dimension of the maxillary basal bone is smaller than the mandibular basal bone. Such transverse deficiencies can be corrected with rapid maxillary expansion (in adolescents), surgically assisted RME (called transverse maxillary DO more recently), or a segmental LeFort I osteotomy. If mandibular symphyseal distraction is being considered, the anticipated maxillary transverse expansion must be predicted before determining the appropriate amount of increase in the mandibular arch width.

In some patients, the appropriate amount of buccal overjet is present, but both the maxillary and mandibular arches are narrow and need to be expanded (Figure 1A). Patients will often comment “I don’t like these dark spaces between my teeth and cheeks,” or “I want a full, broad smile” or “I want a Hollywood smile.” Treatment decisions should not be predicated strictly on esthetics but should also address function, stability, and balance. But if a full, broad, functional, and stable smile can be obtained, each clinician should strive to achieve the patient’s stated goals. With maxillary transverse expansion previously limited by the mandibular arch width, patients were not always able to obtain their desired results. Now with the ability to expand both arches using DO, a full, functional, and stable occlusion can be achieved.

Occasionally, patients will present to the office with a complete buccal crossbite where the maxillary dentition telescopes over the mandibular dentition (Figure 1B). The possible etiologies could be related to a habit, an excessively large maxilla, or a skeletal mandibular transverse deficiency associated with hypoglossia hypodactylia syndrome. Previously, the only method of correction was a vertical symphyseal osteotomy, rotating the two hemi-man-

^a Division of Orthodontics, Vanderbilt University Medical Center, Nashville, Tenn 37212

Corresponding author: R. Scott Conley, DMD, Assistant Professor, Division of Orthodontics, Vanderbilt University Medical Center, 1500 21st Avenue South Suite # 3400, Nashville, Tenn 37212 (e-mail: scott.conley@vanderbilt.edu).

Revised and Accepted: July 2002. Submitted: May 2002.

© 2003 by The EH Angle Education and Research Foundation, Inc.

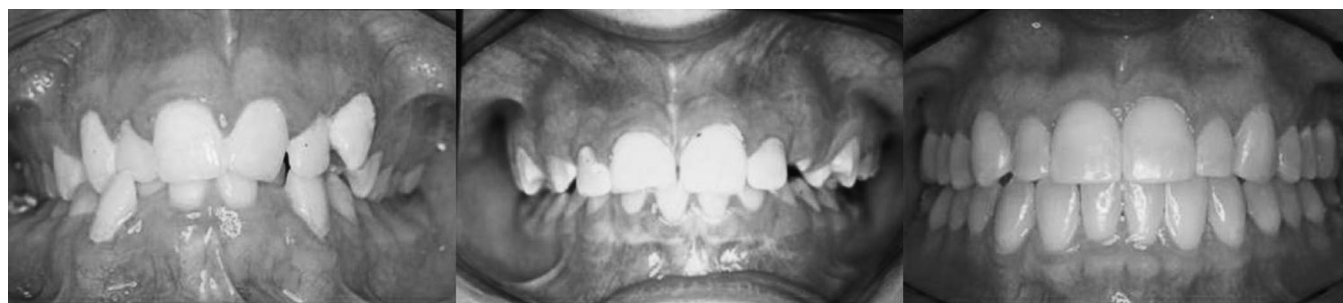

FIGURE 1. (A–C) Interarch transverse relationship. (A) The first picture illustrates a patient with both a narrow maxillary and mandibular arch with some moderate arch length deficiency. The patient would benefit from both widening the transverse dimension in both arches. Previously, the mandibular arch would have dictated extractions to resolve the arch length deficiency. (B) Buccal crossbite (Brodie bite). This patient would benefit from mandibular transverse widening to resolve the deficiency. (C) A patient with full arch dimensions and good interdigitation of the teeth. No expansion is warranted.

dibles laterally, placing a bone graft, and fixating. DO has the benefit of tremendous adjustability and does not require a bone graft. In addition, the regenerate bone, once calcified, has the same properties as the innate mandibular bone. As a result, there are no questions regarding the success and viability of a graft material.

Patients with normal buccal corridors should be evaluated closely before considering distraction (Figure 1C). Overexpansion or expansion of already sufficient width would be ill advised. Although long-term results are forthcoming, it is clear from the treatment that is commonly currently provided that limits for expansion exist and that it is unwise to exceed them. Attempts to expand with combined Schwarz plates and rapid maxillary expansion have led to as much as 4 mm of increase in the maxillary and mandibular arch perimeter.⁸ The long-term stability has not yet been determined. Little⁷ has shown that cases that are expanded to >1 mm have the largest postretention irregularity. Unfortunately, Little's reports do not include either rapid maxillary expansion or mandibular functional appliance expansion. Surgical assisted rapid maxillary expansion has shown varied stability, but most reports indicate better long-term stability than orthopedic, functional, or orthodontic expansion in adult patients.^{9–12} It is logical to infer that the same should hold true for mandibular symphyseal DO until further long-term stability studies can be completed. Although the tone of the buccal musculature must be considered, one benefit that the distraction has over functional appliances is a change in the basal bone not just a change in the alveolar bone, thereby producing a change in the functional matrix. As a result, the expansion should have better long-term stability.

An additional factor that is important to assess includes the transverse relationship relative to the anterior-posterior occlusion (Figure 2). Absolute crossbites¹³ are observed in patients who do not present with a crossbite until they occlude in Class I. For example, many Class II patients appear to have a normal transverse relationship in the current Class II occlusion. But when advanced to a Class I occlusion, a

crossbite exists. Relative crossbites¹³ include any patient who presents with an apparent crossbite; however, when the patients (or the models) occlude in Class I, no crossbite is present. Class III patients often demonstrate this relationship. When planning for symphyseal distraction, the anterior-posterior position must be included to prevent either over- or under-performing the symphyseal distraction. When making expansion decisions, the models should always be analyzed in the anticipated final occlusion (ie, when treating to a Class I molar and canine relationship, examine the models in Class I; if the final occlusion is a Class II molar with a Class I canine relationship, the models should be examined accordingly). Such analysis aids treatment planning so that the appropriate skeletal change can be obtained without having to resort to dental compensations.

Magnitude and location of arch length deficiency

Before performing distraction, it is essential to determine the magnitude and location of any arch length deficiency (Figures 3 and 4). Traditional means such as dental tipping, air rotor stripping, or extractions can resolve varying degrees of arch length deficiency. If, however, arch length deficiency correction by an expansion of the basal bone is desired, mandibular symphyseal DO can be performed to increase the dimension of the innate mandibular basal bone. Arch wire expansion, Schwarz plates, and proclination can all produce alveolar expansion; however, this expansion appears to have limited long-term stability and potential undesirable side effects.

Distraction is particularly effective at resolving anterior crowding because of the proximity of the osteotomy to the space deficiency. Arch length can be gained in the posterior region as well, but must be managed carefully for optimal use. In the maxillary arch, it has been suggested that for every 1.0 mm of rapid maxillary expansion, approximately 0.7 mm of arch length gain can be realized.^{14–17} Currently, no such relationship exists for mandibular expansion, but

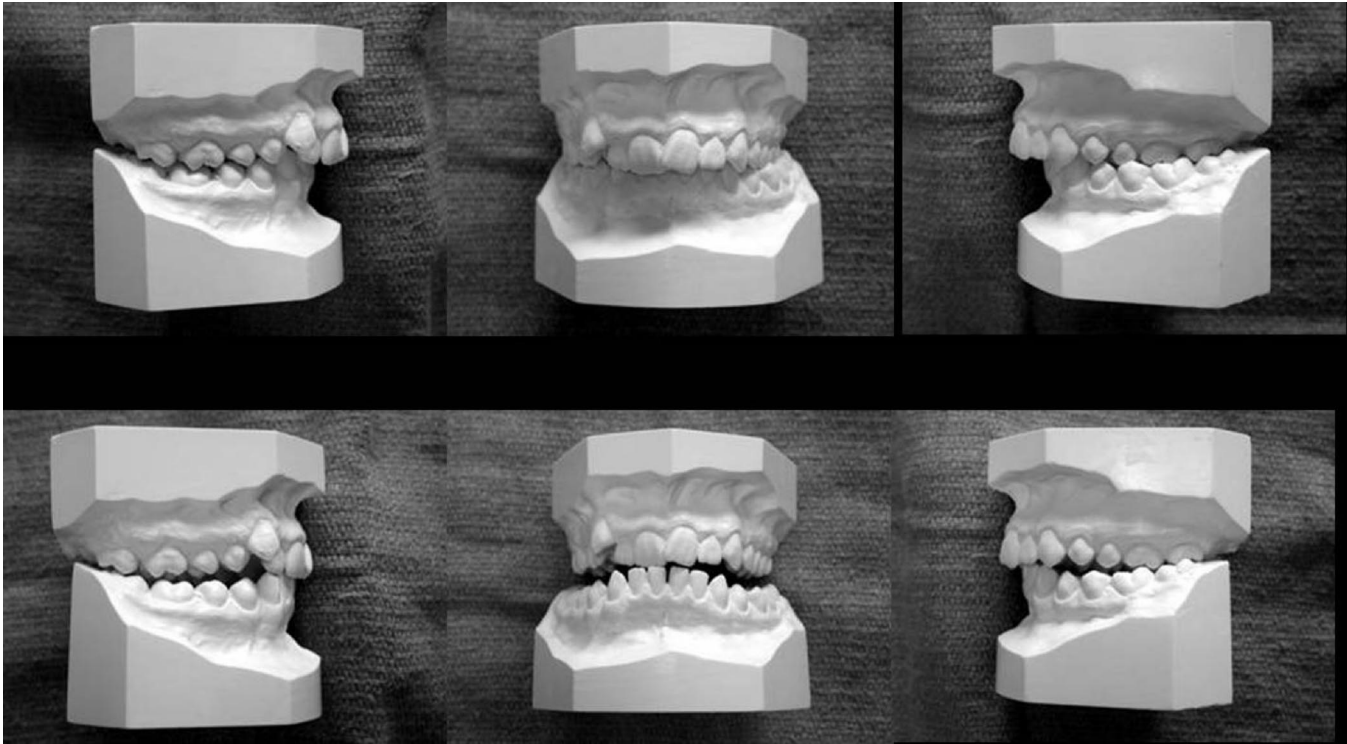


FIGURE 2. (A–F) Affect of anterior-posterior position on the interarch transverse relationship. In the top row, the patient is observed in a full cusp Class II molar and canine relationship. In the bottom row, the models are analyzed in the anticipated final anterior-posterior position after a mandibular advancement. The magnitude of the interarch transverse maxillary deficiency is increased, which must be accounted for if mandibular transverse DO were being considered for this patient.

is currently being investigated.¹⁸ To adequately use the arch length in posterior alignment, the teeth adjacent to the osteotomy must first be moved into the regenerate bone. Then, any remaining space can be used for buccal segment tooth-tooth alignment.

Choosing a template arch and occlusogram analysis

Historically the mandibular arch has been considered the template arch for determining arch width and arch form. Researchers have shown that the most stable treatment preserves the mandibular canine width.¹⁹ An occlusogram analysis^{20–22} (Figure 5) can give the practitioner an accurate template for developing a plan for the symphyseal distraction. Typically the maxillary arch is used as the reference arch to determine the appropriate amount of mandibular expansion when planning for mandibular symphyseal DO. The current maxillary width is drawn on a 1:1 copy of the models. Then, the appropriate amount of buccal overjet is transferred to the mandibular acetate. The distance between the planned transverse dimension and the current mandibular transverse dimension represents the amount of required symphyseal distraction.

Patients with crossbites and narrow maxillary arches have benefited tremendously from rapid maxillary expansion.

But the amount of maxillary expansion was limited by the perceived immutability of the mandibular arch width. Now, patients with narrow maxillary and mandibular arches can benefit from expansion. With distraction, bi-maxillary expansion is a real and viable option. The desired (and appropriate) maxillary expansion can be determined with the occlusogram. Then, the amount of mandibular distraction can be evaluated based on the new, expanded maxilla. At this point, the clinician can initiate the maxillary expansion. As the patient progresses, the maxillary expansion should be evaluated. If good skeletal expansion is observed, expansion in the maxilla can proceed to completion followed by mandibular distraction. If only dental expansion occurs, then the maxillary appliance can either be deactivated or removed. Then, at the time of the planned mandibular symphyseal osteotomy, maxillary transverse DO can be performed concurrently to assure good skeletal expansion in both jaws.

The occlusogram analysis allows all of the planned movements to be performed on an acetate tracing before any clinical procedures. The final result can be seen before moving a single tooth. It is possible to determine whether the movements are too large or impractical before performing any orthodontic or surgical procedures clinically. Such meticulous planning can significantly reduce unnecessary and ill-advised treatment.

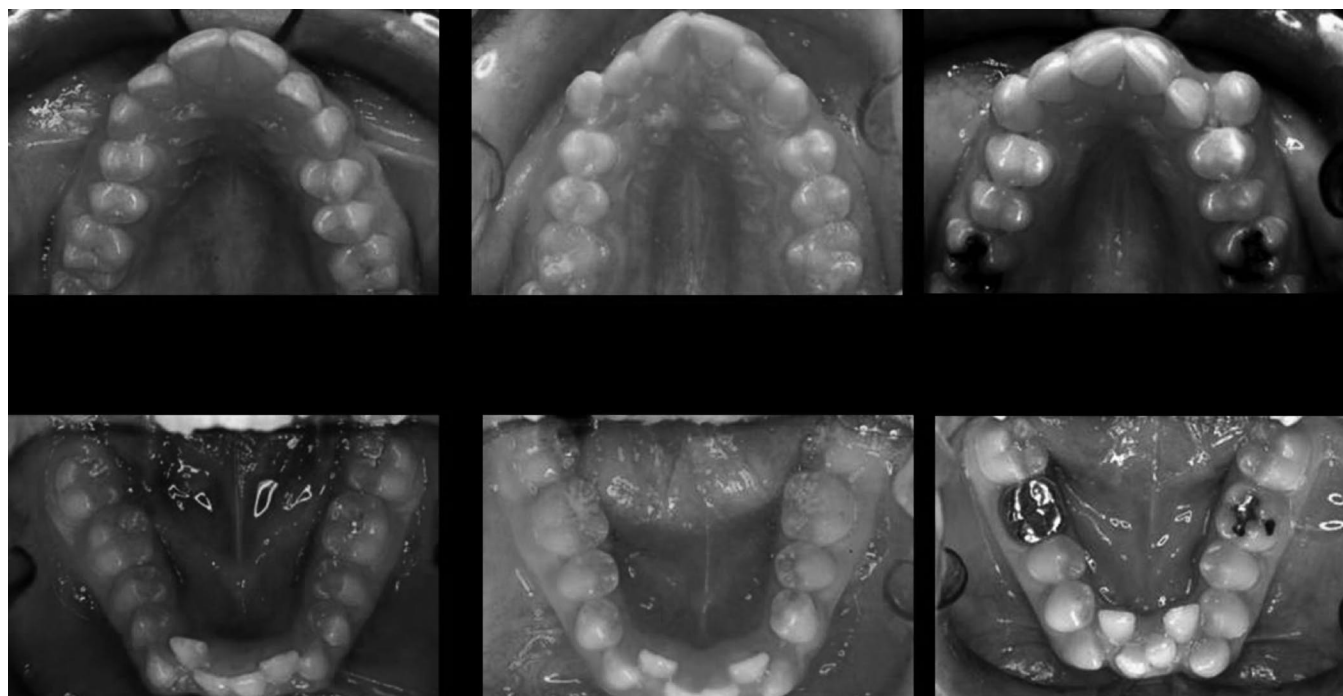


FIGURE 3. (A–F) Arch length deficiency is important to assess. Although mandibular transverse DO can increase the mandibular basal bone, it is not a panacea. Some clinical situations will benefit from the expansion, but DO cannot be anticipated to solve all arch length deficiencies.

Appliance design

A tremendous number of symphyseal distraction appliances are currently available (Figure 6). Each appliance shares a common theme, which it attaches to the bone, to the teeth, or to both. Each appliance has its own advantages and disadvantages, and clinical trials need to be performed to determine the most effective appliance design(s). Currently, little, if any, data is available to assess the clinical efficacy other than anecdotal evidence or case reports.

Controversy has long been present in maxillary expansion whether a Haas or a Hyrax appliance can produce better expansion. Haas appliance proponents cite that the addition of acrylic palatal shields produces more skeletal expansion and less dental tipping than the Hyrax appliances. Hyrax proponents will say that the acrylic in the palatal shields is not rigid enough to cause any effect on the palatal bone. Currently, similar controversy exists among the three symphyseal distractor designs. Some feel that the tooth-borne distractor design leads to a greater amount of dental/dentoalveolar expansion and less skeletal expansion. Other practitioners state that the bone-borne appliance by virtue of the forces being applied directly to the mandible leads to a greater skeletal effect. In truth, if the bony resistance is removed (ie, an osteotomy is performed) and the appliance is sufficiently rigid, the force applied to the teeth should be directly transferred to the bone and only permit skeletal changes to occur. This has been observed repeatedly in the maxilla during surgically assisted rapid maxillary expansion.

Predistraction orthodontic movement and osteotomy design

Before performing the osteotomy, several items must be analyzed to minimize/prevent damage to the teeth, the periodontium, and the bone. Some of the indications for predistraction orthodontic movement include crowding, root convergence, and no available osteotomy site. Often in the mandibular anterior region because of crowding and space deficiency, the incisor roots will converge with little to no interdental space present. The best way to determine the need for predistraction tooth movement involves the standard orthodontic records (lateral and posterior-anterior cephalograms, panoramic X-ray, models, intraoral and extraoral photographs, and a detailed clinical examination) in addition to mandibular anterior periapical, mandibular occlusal, and/or submentovertex radiographs.

Obtaining the necessary root divergence can often be difficult, as there may be no space to diverge the central incisor roots. What may be required is diverging the lateral incisor roots first, and then moving the central incisor roots into the newly available space. This can be performed with an arch wire and altering the angulation of the brackets on the incisors (Figure 7). Care must be taken to avoid proclination of the teeth in an attempt to align them in an area of space deficiency. To verify adequate root divergence, a second mandibular periapical X-ray or mandibular occlusal film should be taken and evaluated with the surgeon.

The ideal location for the interdental osteotomy is generally between the central incisor roots. This allows for ease

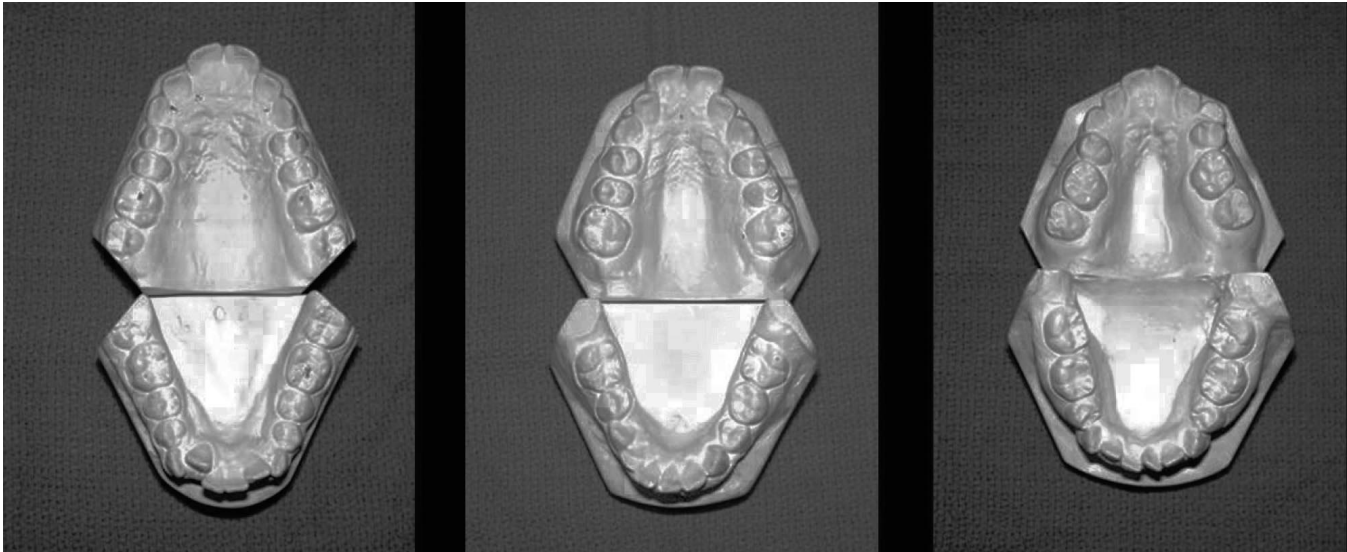


FIGURE 4. (A–C) Not only is the amount of arch length deficiency important, but also the location. When the crowding is in the midarch such as in B, the anterior teeth must be brought into the newly formed regenerate bone. Then the midarch can be brought forward as well.

of surgical access, no horizontal osteotomy below teeth, symmetric forces, symmetric chin expansion, and symmetric space creation. The surgeon performs a low energy vertical osteotomy (Figure 8A,B). The appliance (whether tooth borne, bone borne, or hybrid) is then activated to assess the osteotomy site. Once complete mobilization is observed, the appliance is deactivated and soft tissue closure is performed.

The surgical procedure, although similar, does have some significant differences depending on the type of distraction appliance being used. Tooth-borne appliances will be fabricated by the orthodontist after fitting bands typically on the mandibular first premolars and first molars. The tooth-borne appliance is cemented before going to the operating room. Once anesthetized, a horizontal incision is made 5 mm labial to the depth of the labial sulcus and the muscle is reflected. The vertical osteotomy is initiated with a reciprocating saw up to approximately 5 mm below the incisor roots. Then, the buccal cortical bone is scored with a fissure bur if adequate interdental space is present. If not, a small spatula osteotome is used to complete the interdental osteotomy.

With bone-borne or hybrid distraction appliances, the osteotomy is initiated before the placement of the appliance. The portion of the osteotomy below the dental roots is completed in the same way as before. Then, before completing the interdental osteotomy, the distractor fixation plates are adapted to the inferior portion of the mandibular symphysis and fixated in place. The vertical osteotomy is then completed with either the fissure bur or a spatula osteotome and the remaining portion of the appliance is fixed to the dentition. At this point, the surgeon activates the appliance (whether tooth borne or bone borne) to assure complete mobilization and symmetric and parallel activation.

Occasionally, sufficient midsagittal space is impossible to obtain for alignment of the teeth but sufficient interradicular space may exist parasagittally. This situation allows for a variation to the osteotomy design. Instead of a midline cut, the osteotomy is moved laterally to the area of more interradicular bone, such as between the lateral incisor and canine. The advantage is that distraction can still take place, predistraction orthodontic movement is minimized, and the potential for damage to the teeth can be decreased. In addition, the teeth are not proclined, but are aligned in the newly available regenerate bone. With a parasagittal osteotomy, the cut must be oriented in a stepwise manner so that the part of the osteotomy below the incisor roots is brought medially into the symphysis (Figure 8C,D). Failure to return to the median portion of the symphysis can create an iatrogenic chin asymmetry.

Distraction protocol

The osteotomy for DO is not the same as an osteotomy for orthognathic surgery. Care must be taken to preserve as much periosteum, endosteum, periodontium, and bone as possible in the osteotomy/distraction site. If too much tissue is traumatized or removed, a greater void is created and callus formation is slower and less organized. The formation of a high quality, highly organized callus for subsequent molding is essential. Ways to minimize tissue trauma include using copious amounts of water, a low setting on the reciprocating saw, and greater use of small spatula osteotomes. In addition, the muscular and periodontal reflection should be done as atraumatically as possible to prevent undue tissue stretch, tissue tension, and flap devascularization.

A latency period is critical for DO. Without allowing

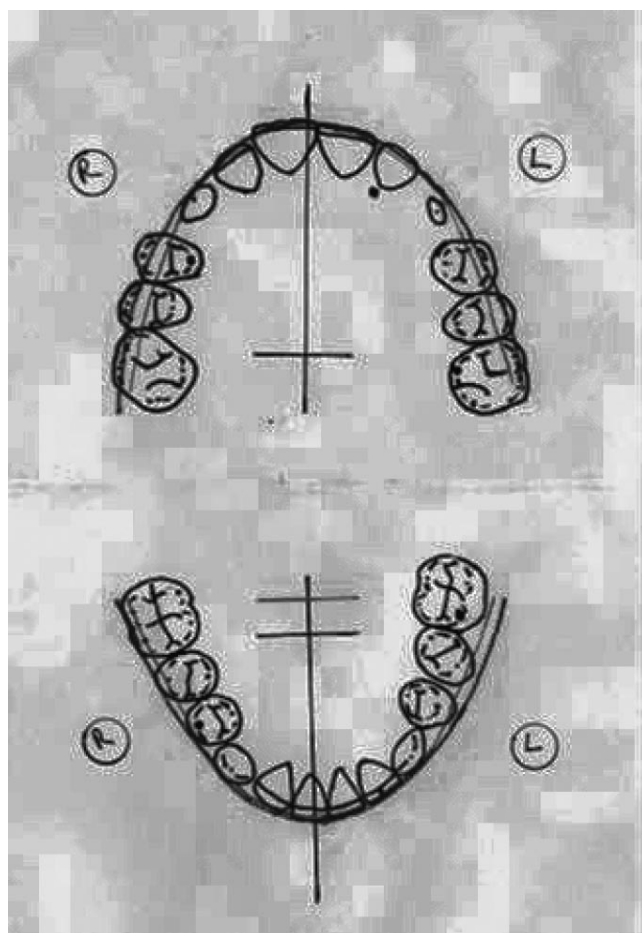


FIGURE 5. The occlusogram is a powerful diagnostic tool that can be used to diagnosis and treatment plan any orthodontic case. The treatment decisions are made on the acetate tracing to determine the magnitude and direction of the intended movements. Analyzing the start and desired finished positions of the teeth can assist in determining the feasibility of the treatment before sending the patient to the surgeon.

time for a callus to form, callus manipulation cannot occur. Without a good callus, the quality of the regenerate bone can be adversely affected, possibly creating bone of poor quality, fibrous union, nonunion, tooth loss, periodontal defects, and other complications. The latency period is typically seven days. In young children, healing is accelerated, and may require a shorter latency period. Older patients may require a slightly increased latency period because of a slower rate of healing.

The rate of distraction can be a very important factor as well. Too fast a rate can lead to poor bone quality, nonunion, poor union, fibrous union, or partial union. Distracting too slowly can lead to premature consolidation and an inability to obtain the planned amount of expansion. A typical rate of distraction is 1 mm a day.

The rhythm of distraction refers to the number of increments required to reach the preplanned daily rate of distraction. The rate of 1 mm can be performed all at once or in various smaller increments. To some degree, the appliance will dictate the rate because it may have set activation increments. Most of the tooth-borne appliances are set for approximately 0.20–0.25 mm per activation, whereas most bone-borne appliances are set at approximately 0.50 mm per activation. The ideal rhythm would closely approximate normal physiologic growth increments but our current level of appliance design does not allow for such a high number of minute activations. A clinically efficient rhythm has been 0.25 mm four times a day or 0.50 mm twice a day.

Postdistraction orthodontic movement

Tooth movement should not begin until radiographic evidence of consolidation is observed. Occlusal X-rays allow excellent visualization of the teeth, distraction site, and evidence of calcification (Figure 9). Typically, three months is sufficient to observe calcification of the site. The distractor should never be removed until this evidence is observed because the rigidity it provides increases the quality of the callus.

Closure of the interdental space should be delayed until the bone is observed. To prevent premature mesial migra-



FIGURE 6. (A–C) Distraction appliances. (A) A bone-borne symphyseal distractor. (B) A tooth-borne distractor fabricated using a standard rapid maxillary expansion jackscrew with bands on the mandibular first premolars and first molars. (C) A hybrid distractor. The inferior legs are fixed to the inferior portion of the mandibular symphysis with screws. The superior arms are attached to the mandibular canines with a circumferential wire.

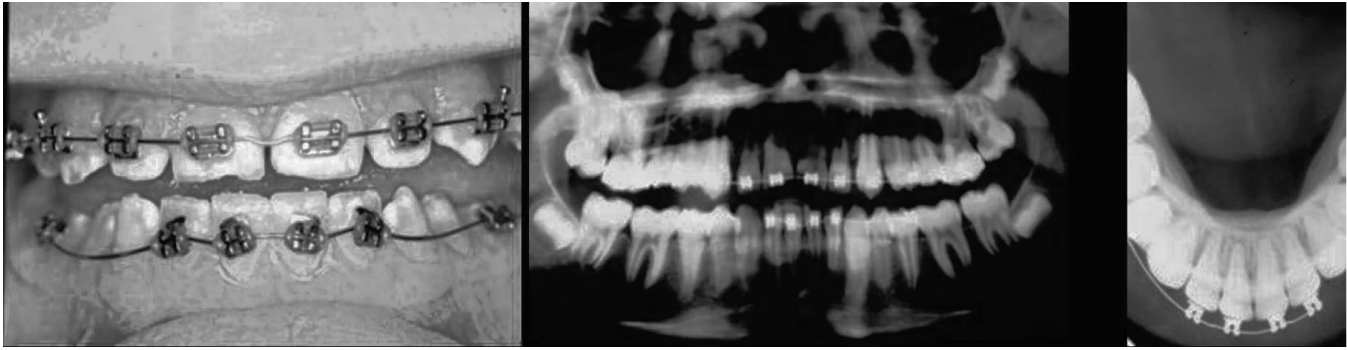


FIGURE 7. (A–C) Predistraction orthodontic movement can be done to diverge the mandibular anterior teeth to allow for an osteotomy site. The panoramic and occlusal X-rays show adequate space has been created to minimize the risk of trauma to the incisors during the osteotomy.

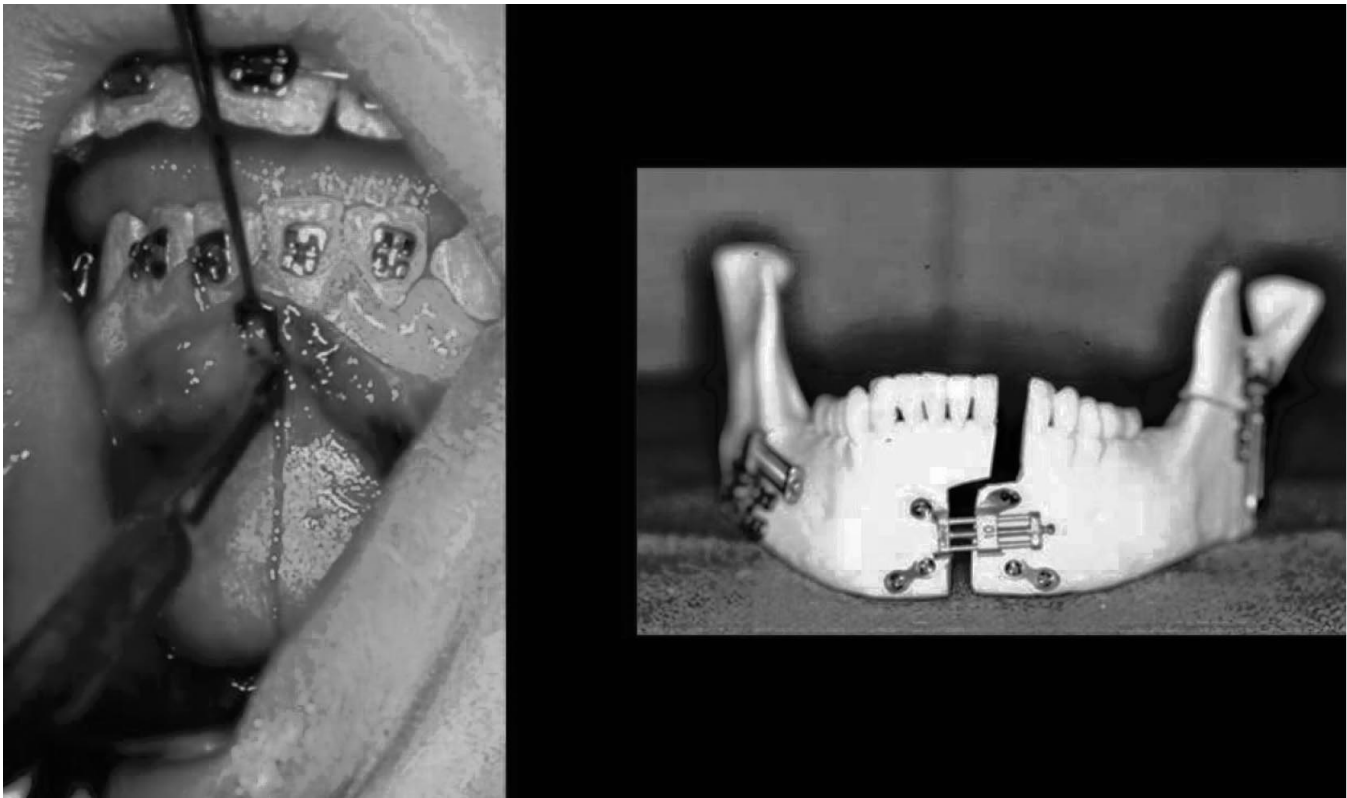


FIGURE 8. (A–B) The osteotomy design has two basic forms, vertical midsagittal cut, and a stepped parasagittal cut. When performing the parasagittal osteotomy, care must be taken to be below the level of the incisor roots before stepping back into the midline to avoid incisal trauma.

tion, a step in the arch wire, an open coil spring, or an acrylic denture tooth can be placed in the distraction space. Allowing the teeth to move into the gap too early could lead to periodontal defects, bony defects, and potential loss of one or more teeth. If divergence of incisor roots was performed before distraction, the teeth should be brought into an appropriate axial inclination. Brackets placed pre-surgically to diverge roots should be repositioned into ideal positions. The goals of orthodontic treatment in conjunction with DO should be the same as all other methods of orthodontic treatment: parallel roots, forces placed over the long

axis of the teeth, and a well-interdigitated functional occlusion.

To maintain the expansion obtained from distraction, a passive 0.036-inch stainless steel lingual arch should be placed upon removal of the distraction appliance for the remainder of the orthodontic treatment. Because we have learned from rapid maxillary expansion, the longer the transverse dimension is retained the greater the stability and ultimate treatment success. In addition, by having the 0.036-inch stainless steel lingual arch, light stainless steel wires that are useful in aligning the teeth (but not good for

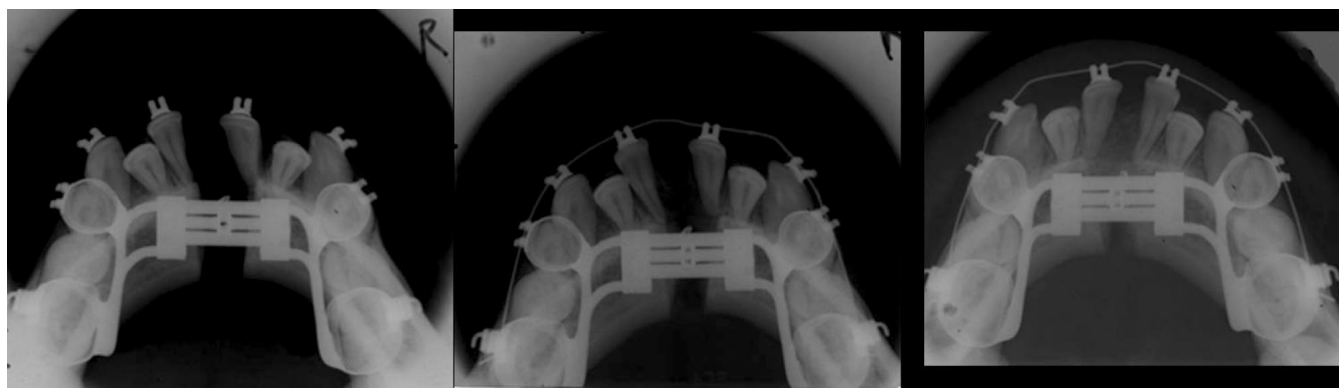


FIGURE 9. (A–C) Mandibular occlusal radiographs. (A) An X-ray taken at the day the distraction stops shows the distraction gap. It is essential to keep the teeth in place to avoid premature movement into the gap that might result in periodontal defects. (B) An X-ray taken one month after active distraction reveals an increase in the amount of calcified tissue in the distraction gap. (C) After three months, almost complete calcification of the distraction gap has occurred. Now, the teeth can be moved back to the midline to resolve the arch length deficiency.

maintaining arch width) can be used without concern for the loss of the expansion.

Retention

Any of the standard forms of retention can be used to maintain the distraction result, but the Essix type retainers may not be sufficiently rigid to maintain the increased transverse dimension. If an Essix retainer is required for patient esthetics and compliance, it should only be used during the day and a Hawley retainer used for evening wear. A fixed lower canine-to-canine wire will adequately maintain the canine width and anterior alignment, but cannot be expected to aid in maintaining any posterior expansion. Consequently, a Hawley retainer with integral lingual support wire is a good form of mandibular retention.

TMJ considerations

Currently, concern exists regarding the potential for trauma/damage to the temporomandibular joint and supporting structures. A proposed mathematical model states that for 10 mm of expansion approximately 3° of rotation occurs at the condyle.²³ This has led to our clinical investigation that seeks to determine the center of rotation of the mandible during symphyseal distraction.²⁴ Intraoral vertical ramus osteotomies have been reported to have as much as $4\text{--}7^\circ$ of rotation and have been well tolerated (C. Guerrero, personal communication). Further study is needed to determine first, whether any rotation exists at the temporomandibular joint, secondly, how much rotation occurs, and finally, whether the rotation causes any detrimental or degenerative effects at the temporomandibular joint.

Stability

At this point, only a limited number of investigations have been performed and further study is needed to determine the occlusal, skeletal, and periodontal stability.²⁵ Sev-

eral difficulties have led to the current lack of information regarding treatment stability. First, the mandibular transverse symphyseal DO sample population is currently somewhat limited. In addition, although current research has shown that symphyseal distraction has yielded significantly increased intercanine and intermolar arch widths, some of the study patients had incisal proclination if presurgical orthodontic manipulation was not performed. This dental tipping may result in some long-term incisal instability. Another current shortcoming is the lack of long-term assessment. With current stability studies, the long-term follow up was slightly more than one year after surgery, and greater than half of the patients still had orthodontic appliances in place.

CONCLUSIONS

Individualized diagnosis and treatment planning are essential to appropriately address each patient's needs and goals. Cases that historically have been treated with air rotor stripping, dentoalveolar expansion, or extractions now have another alternative. Mandibular symphyseal DO offers a new option for orthodontic treatment consideration.

REFERENCES

1. Ilizarov GA. Clinical application of the tension-stress effect for limb lengthening. *Clin Orthop Rel Res.* 1990;250:8–26.
2. Toth BA, Kim JW, Chin M, Cedars M. Distraction osteogenesis and its application to the midface and bony orbit in craniosynostosis syndromes. *J Craniofac Surg.* 1998;9(2):100–113.
3. Molina F, Ortiz Monasterio F. Mandibular elongation and remodeling by distraction: a farewell to major osteotomies. *Plast Reconstr Surg.* 1995;96:825–842.
4. Burstone CJ. Precision lingual arches. Active applications. *J Clin Orthod.* 1982;23(2):101–109.
5. McDougall PD, McNamara JA Jr, Dierkes JM. Arch development in Class II patients treated with the Frankel appliance. *Am J Orthod-Dentofacial Orthop.* 1982;82(1):10–22.
6. Weinberg M, Sadowsky C. Resolution of mandibular arch crowding in growing patients with Class I malocclusion treated non-

- extraction. *Am J Orthod-Dentofacial Orthop.* 1996;110(4):359–364.
7. Little RM, Riedel RA, Stein A. Mandibular arch length increase during the mixed dentition: post retention evaluation of stability and relapse. *Am J Orthod-Dentofacial Orthop.* 1990;97(5):393–404.
 8. O'Grady PW. Long-term stability of rapid maxillary expansion concurrent with Schwarz appliance therapy in the mixed dentition. [Thesis]. Ann Arbor, Mich: University of Michigan; 2002.
 9. Bays RA, Greco JM. Surgically assisted rapid palatal expansion: an outpatient technique with long-term stability. *J Oral Maxillofacial Surg.* 1992;50(2):110–113.
 10. Phillips C, Medland WH, Fields HW Jr, Proffit WR, White RP Jr. Stability of surgical maxillary expansion. *Int J Adult Orthod Orthognathic Surg.* 1992;7(3):139–146.
 11. Pogrel MA, Kaban LB, Vargervik K, Baumrind S. Surgically assisted rapid maxillary expansion in adults. *Int J Adult Orthod Orthognath Surg.* 1992;7(1):37–41.
 12. Wertz RA. Skeletal and dental changes accompanying rapid mid-palatal suture opening. *Am J Orthod.* 1970;58:41–66.
 13. Jacobs JD, Bell WH, Williams CE, Kennedy JW. Control of the transverse dimension with surgery and orthodontics. *Am J Orthod.* 1980;77:284–306.
 14. Adkins MD, Nanda RS, Currier GF. Arch perimeter changes on rapid palatal expansion. *Am J Orthod-Dentofacial Orthop.* 1990; 97(3):194–199.
 15. McNamara JA Jr, Brudon WL. *Orthodontic and Orthopedic Treatment in the Mixed Dentition.* Ann Arbor, Mich: Needham Press; 1993.
 16. McNamara JA Jr. Early intervention in the transverse dimension: is it worth the effort? *Am J Orthod-Dentofacial Orthop.* 2002; 121:572–574.
 17. Brust EW, McNamara JA Jr. Arch dimensional changes concurrent with expansion in mixed dentition patients. In: Trotman CA, McNamara JA Jr, eds. *Orthodontic Treatment: Outcome and Effectiveness. Monograph 30 Craniofacial Growth Series.* Ann Arbor, Mich: Center for Human Growth and Development, University of Michigan; 1995.
 18. Braun S, Hnat WP, Hnat TW, Legan HL. Taking the guesswork out of mandibular symphyseal distraction osteogenesis. *Am J Orthod-Dentofacial Orthop.* 2001;119(2):121–126.
 19. Strang R. The fallacy of denture expansion as a treatment procedure. *Angle Orthod.* 1949;19:12–22.
 20. Faber RD. Occlusograms in orthodontic treatment planning. *J Clin Orthod.* 1992;26(7):389–401.
 21. White LW. The clinical use of occlusograms. *J Clin Orthod.* 1982; 16(1):92–103.
 22. Marcotte WR. The use of the occlusogram in planning orthodontic treatment. *Am J Orthod.* 1976;60:65–67.
 23. Samchukov ML, Cope JB, Harper RP, Ross JD. Biomechanical considerations of mandibular lengthening and widening by gradual distraction using a computer model. *J Oral Maxillofacial Surg.* 1998;56:51–59.
 24. Braun S, Bottrel JA, Legan HL. Condylar displacement related to mandibular symphyseal distraction. *Am J Orthod-Dentofacial Orthop.* 2002;121(2):162–165.
 25. Del Santo M Jr, Guerrero CA, Buschang PM, English JD, Samchukov ML, Bell WH. Long-term skeletal and dental effects of mandibular symphyseal distraction osteogenesis. *Am J Orthod-Dentofacial Orthop.* 2000;118(5):485–493.