

An Improved Transpalatal Bar Design. Part II. Clinical Upper Molar Derotation—Case Report

Elif Gündüz, DDS^a; A. G. Crismani, DDS^a; H. P. Bantleon, MD, DDS, MS, PhD^a;
Klaus D. Hönigl, MD, DDS^b; Bjorn U. Zachrisson, DDS, MSD, PhD^c

Abstract: Bilaterally rotated upper first molars (mesial in, distal out) were derotated in two different cases by using a custom-made transpalatal bar. The bars were reactivated, if necessary, at four-week controls. The derotations were fully corrected after about three months. (*Angle Orthod* 2003;73:244–248.)

Key Words: Molar rotation; Transpalatal bar

INTRODUCTION

Angle,¹ who in 1899 referred to maxillary first permanent molars as the “key to occlusion,” was the first to mention their importance within the dentition. After Angle, other authors have discussed the position of upper molars from different viewpoints, such as their relation or position in the maxilla, anteroposterior axial inclination, and rotation. In this article only rotations of molars will be addressed. Andrews² defined “no rotations of the teeth in the dentition” as one of the six keys to normal occlusion. Ricketts³ maintained that in an ideal occlusion a line can be drawn between the mesiolingual and the distobuccal cusps of the upper first molars, transecting the distal third of the canine on the opposite side. The position of this line may indicate the need for molar rotation. In an ideal occlusion the buccal surfaces of the upper first molars are usually parallel to one another.⁴ As indicated by Lamons and Holmes,⁵ molar rotations commonly exist in Class II malocclusions. The molars are usually rotated around an axis lingual to their central fossae. Ten Hove⁶ discussed the degree of Class II malocclusion in relation to maxillary first-molar rotation, and the importance of examining the occlusion from the lingual aspect. According to Liu and Melsen,⁷ the buccal molar relationships are not consistent with their corresponding lingual relationship in 90% of the conventionally diagnosed Class II cases.

The space between the buccal and lingual cortical plates

becomes narrow anterior to the first-molar roots. When the upper first molar drifts mesially, the large lingual root contacts the lingual plate and allows the two buccal roots to rotate mesiolingually. The occlusal surface of the first permanent molar is trapezoidal in shape, with the long diagonal from distolingual to mesiobuccal.⁸ Therefore, more mesiodistal space is used in the dental arch when this tooth rotates mesially with the lingual root as the axis.⁹ By correction of these rotations, one to two mm of arch length per side and partial Class II correction can be achieved. These corrections also are needed to provide good intercuspation. After the introduction of the transpalatal bar by Goshgarian, soldered or removable transpalatal bars have become a routine part of orthodontic treatment in the derotation of molars, because it is generally difficult to correct their rotation with labial archwires. The transpalatal bar is useful when the need for derotation is the same on both sides of the dental arch. If there are symmetrical upper-molar rotations, equal and opposite moments of rotation can be used to derotate the molars without creating mesiodistal forces (Figure 1a,b). If there are asymmetric molar rotations, the molar that is more mesiopalatally rotated will receive a larger derotation moment and will move mesially. The molar that is less rotated will have a smaller derotation moment and will move distally (Figure 1c). This article describes the clinical effectiveness of a new design of the transpalatal bar (see Part I).

MATERIALS

The main differences between the design described by Zachrisson (Zachrisson-type transpalatal bar [ZTPB]) and the traditional Goshgarian-type transpalatal bar (GTPB) are in the amount and shape of the wire in the palatal loop. The ZTPB has three loops (Figures 1 through 3). The middle loop is larger and longer than the single round loop of the GTPB. The additional smaller loops are symmetrically positioned on either side of the middle loop. The middle

^a Department of Orthodontics, University of Vienna, Vienna, Austria.

^b Private practice, Judenburg, Austria.

^c Department of Orthodontics, University of Oslo, Oslo, Norway.

Corresponding author: E. Gündüz, DDS, Department of Orthodontics, University of Vienna, Waehringer Strasse 25a, A-1090 Vienna, Austria
(e-mail: elifgunduz@hotmail.com).

Accepted: October 2002. Submitted: August 2002.

© 2003 by The EH Angle Education and Research Foundation, Inc.

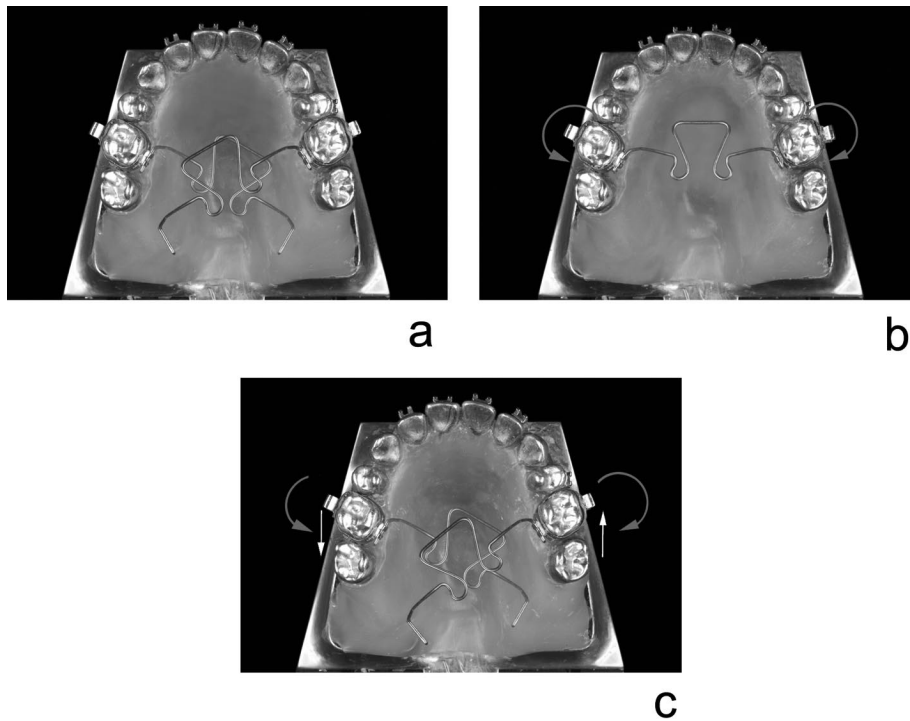


FIGURE 1. Model demonstration of potential tooth movements with the transpalatal bar. (a) A passive Zachrisson-type transpalatal bar is inserted into the attachments of the symmetrically rotated (mesial in, distal out) upper first molars. (b) Model showing equal, but opposite, moments produced during derotation of symmetrically rotated molars. No sagittal forces are produced. (c) Model showing equal, but opposite, sagittal forces produced during derotation of asymmetrically rotated molars or as a side effect of the asymmetrically bent transpalatal bar. The sagittal force will be mesial on the side where the moment of derotation is greater.

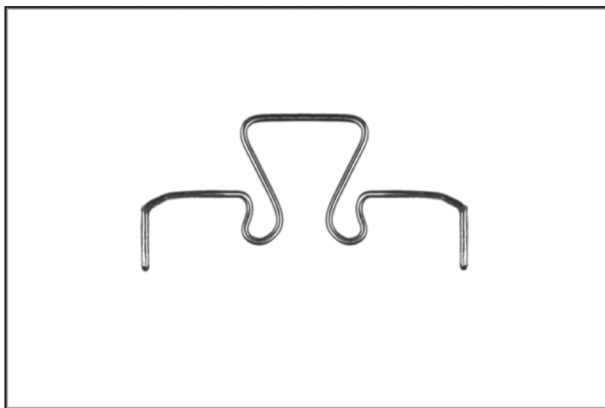


FIGURE 2. Occlusal view of a Zachrisson-type transpalatal bar. The bar is hand made from a 0.036-inch (0.9 mm) Blue Elgiloy wire, has longer double wire ends to secure improved engagement to the lingual sheaths and has three loops: one, a mesially directed larger and longer central loop and two small, distally directed loops on either side of the central loop.

loop is directed mesially, and the additional loops are directed distally. The optimal length of the ZTPB is about 89 mm. Although adaptations are required for individual palatal vault designs, the size of the central loop is generally about 9 mm, and the distance from the two farthest points is approximately 12 mm (Figures 1 through 3). The ends

of the ZTPB are longer than those of the standard GTPB, to secure improved engagement to the lingual sheaths and make safe ligations possible.

Our procedure to bend the ZTPB is as follows:

- At the first appointment, separators for the upper molars are placed.
- At the second appointment (about one week later), molar bands are fitted, and alginate impression is taken with the bands in place.
- The ZTPB is then made indirectly, using a 0.036-inch (0.9 mm) Blue Elgiloy wire (Rocky Mountain/Orthodontics, Denver, Colo). The excellent formability of the Blue Elgiloy wire facilitates the making of the bar.
- The bar is contoured in an optimal position, one to two mm above the palate, on the plaster model to avoid any soft-tissue impingement. The bar should be entirely passive in both the vertical and the horizontal planes. After bending, the bar should be stress relieved by heat treatment with a memory maker.
- At the third appointment, the bands are cemented to the upper molars, and the bar is placed in the lingual sheaths on the bands.

METHODS

Bilaterally rotated upper molars (mesial in, distal out) were derotated using ZTPBs by one investigator. Photo-

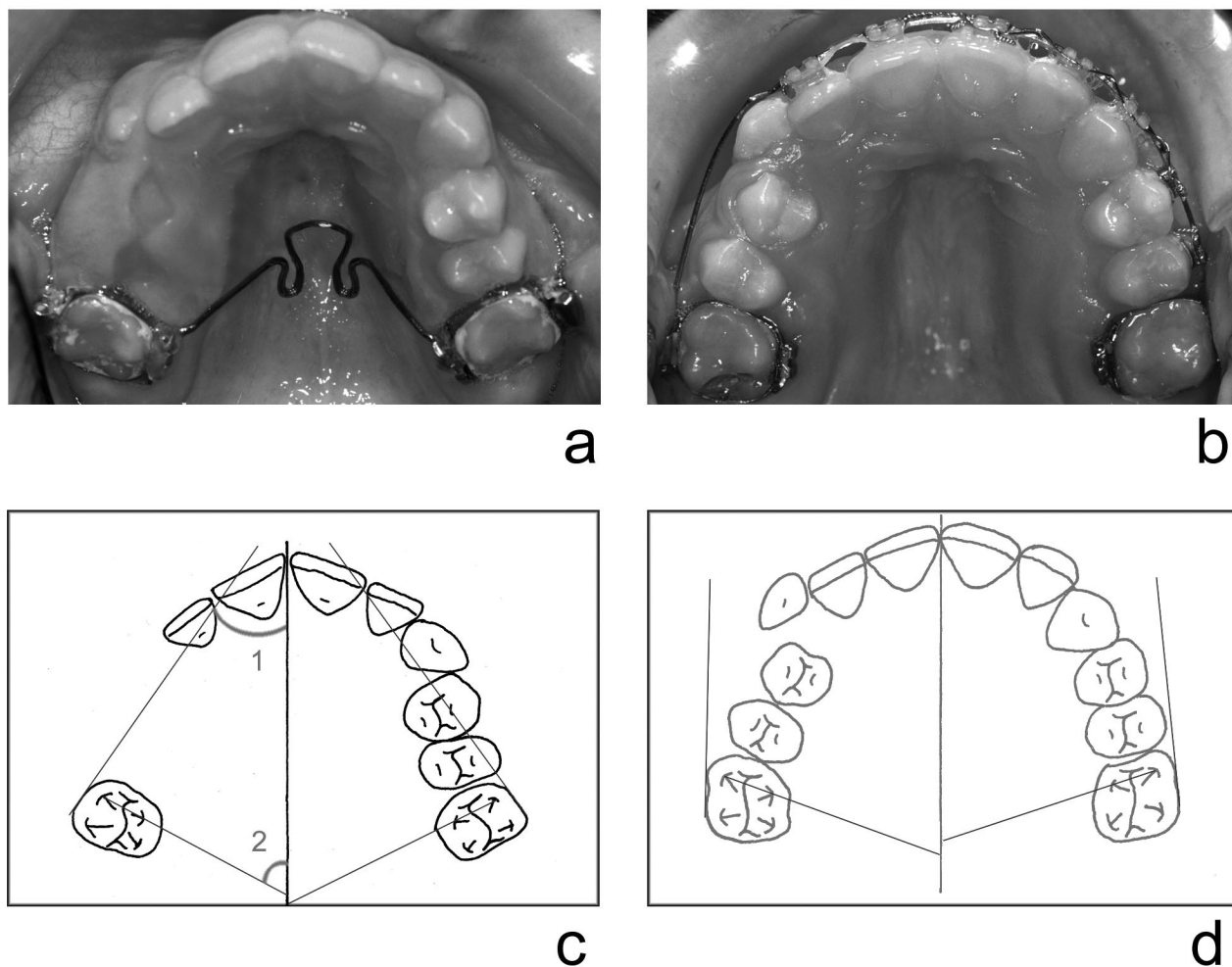


FIGURE 3. (a) Case 1 at the start of treatment. Note the mesial rotation of both maxillary first molars. (b) Occlusal view of Case 1 after optimal derotation of both first molars. (c) Occlusogram at the beginning of derotation. (d) Occlusogram after molar derotation.

graphs of the patients were taken at the beginning of the treatment and after satisfactory derotation (Figures 3a,b and 4a,b). Occlusograms of the upper dental arches were drawn at the initial phase of treatment and at the end of derotation (Figures 3c,d and 4c,d). Two measurements were made on each occlusogram to evaluate the degree of rotation (Figure 3c):

1. the angle between the line passing through the buccal surface of the molar and the midsagittal line marked on the median raphe;
2. the angle between the line through the mesiobuccal and mesiopalatal cusps of the molar and the midsagittal line marked on the median raphe.

RESULTS

Clinically satisfactory upper-first-molar rotations were obtained in both cases. Table 1 shows the comparison of pre- and posttreatment results.

No intrusion of the molars was detected clinically at the

end of derotation. The measured overbite was the same before and after derotation. The transpalatal bar was reactivated at each four-week control. The angles drawn on the occlusograms show the initial (Figures 3c and 4c) and final positions (Figures 3d and 4d) of the left and right molars.

DISCUSSION

By enlarging the midline omega loop and directing the loop mesially, the force of the tongue can produce intrusive forces on the teeth where the transpalatal bar is anchored.^{4,10-12} However, in the short time span (three months) in the present cases, no intrusion of upper molars was observed. The time needed for derotation with ZTPB was shorter than the time taken by traditional GTPB.^{13,14} The use of prefabricated transpalatal bars reduces the number of appointments. However, fabrication of the ZTPB is not very time-consuming. The Blue Elgiloy wire has excellent formability and can be easily bent to the proper shape. After bending and heat treatment (up to 480°C), the Elgiloy wire has a slightly higher stiffness than stainless steel has.¹⁵

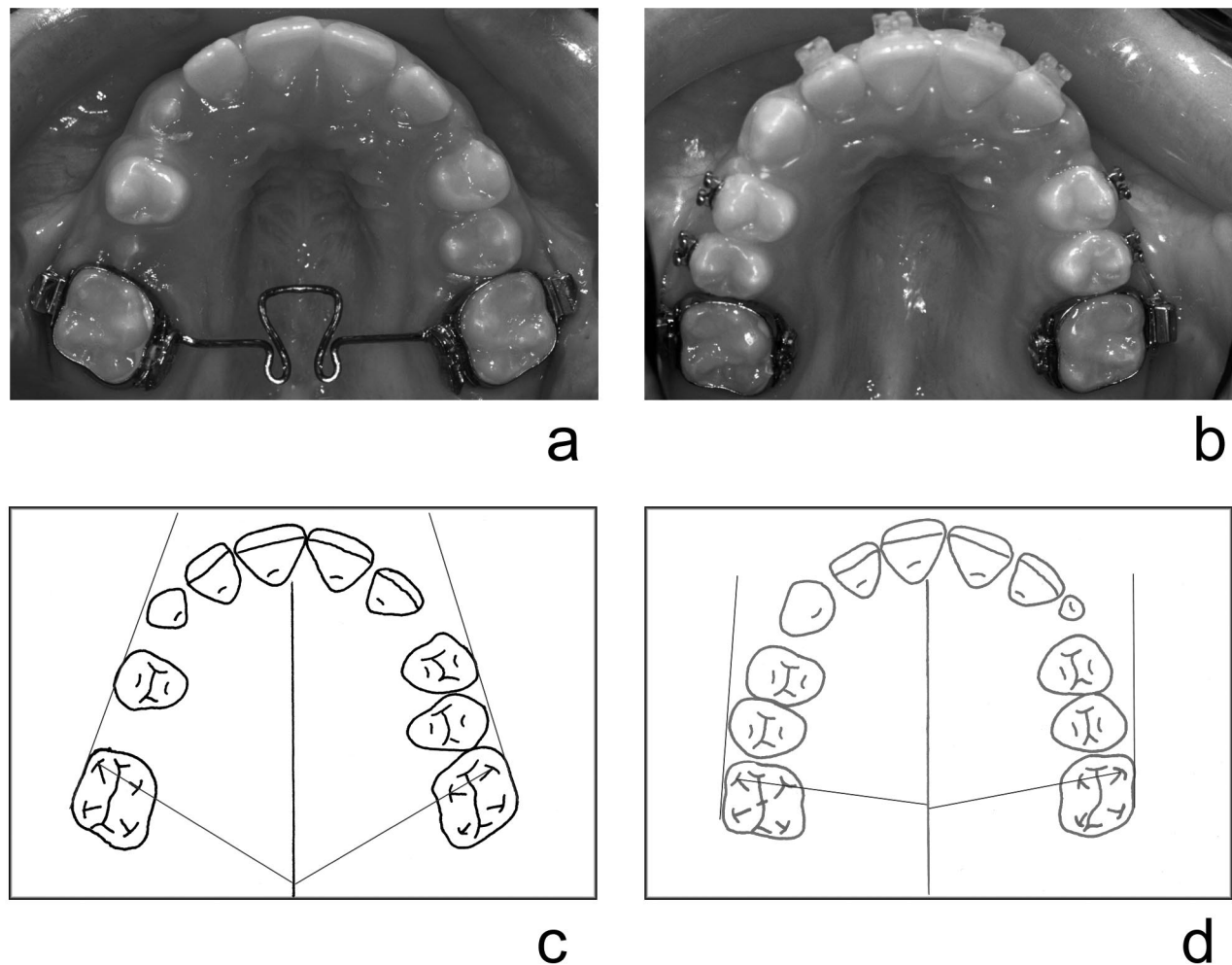


FIGURE 4. (a) Case 2 at the start of treatment. (b) Occlusal view of Case 2 after optimal derotation of both first molars. (c) Occlusogram at the beginning of derotation. (d) Occlusogram after molar derotation.

TABLE 1. Comparison of Pre- and Posttreatment Angles After Molar Derotation With the Zachrisson-type transpalatal bar^a

Patient No.	Treatment Time (d)	Upper Molar	Angle 1 (°)		Angle 2 (°)	
			Pre treatment	Post treatment	Pre treatment	Post treatment
1 (Figure 3)	90	Left	18	2	60	79
		Right	21	5	59	82
2 (Figure 4)	73	Left	36	4	63	72
		Right	35	3.5	62	70

With the ZTPB a greater length of wire is used over the same distance than for the routine GTPB. This lowers the load deflection rate and allows greater flexibility to the bar, making the forces more constant and predictable. When the bar is fully engaged in the attachments, the middle bigger loop opens, and the additional loops on either side of this big loop close. The bar is active until the loops come to

their original shape (Figures 2b and 3a). The clinical use of the ZTPB for different treatment purposes, such as upper molar derotation, expansion of the upper arch, maintaining arch widths, supporting anchorage, improving vertical control, is found to be satisfactory by the present investigators. A large number of patients who have received this custom-made palatal bar design have been treated by one of us during the last eight years.

A comparison of the ZTPB with the standard stainless steel GTPB was recently done at the University of Vienna by using a computer-based, strain-gauge measuring system, which measures the horizontal forces, sagittal forces, and derotation moments at the left and right molars. The results of these investigations are reported in Part I.

Further clinical studies with larger samples of patients and including superimpositions of cephalometric films taken before and after molar derotation should be undertaken to better assess potential short- and long-term side effects (such as intrusion of molars) of the new bar design.

REFERENCES

1. Angle EH. Malocclusion of the Teeth. 7th ed. Philadelphia, S. S. White Dental Mfg.Co. 1907:17.
2. Andrews LF. The six keys to normal occlusion. *Am J Orthod.* 1972;62:296–309.
3. Ricketts RM. Occlusion—the medium of dentistry. *J Prosthet Dent.* 1969;21:39–60.
4. McNamara JA, Brudon WL. *Orthodontic and Orthopedic Treatment in the Mixed Dentition.* Ann Arbor, Mich: Needham Press; 1993:179–192.
5. Lamons FF, Holmes CW. The problem of the rotated maxillary first permanent molar. *Am J Orthod.* 1961;47:246–272.
6. Ten Hoeve A. Palatal bar and lip bumper in nonextraction treatment. *J Clin Orthod.* 1985;19:272–291.
7. Liu D, Melsen B. Reappraisal of Class II molar relationships diagnosed from the lingual aspect. *Eur J Orthod.* 2001;23:457.
8. Stoller AE. The normal position of maxillary first permanent molar. *Am J Orthod.* 1954;40:259–271.
9. Burstone CJ. Precision lingual arches active application. *Am J Orthod Dentofacial Orthop.* 1989;23:101–109.
10. Ney T, Göz G. Kraft-Moment—Messungen am passiven Palatinalbügel unter dem Einfluss der Zunge. *Fortschr Kieferorthop.* 1993;54:249–254.
11. DeBerardinis M, Stretesky T, Sinha P, Nanda RS. Evaluation of the vertical holding appliance in the treatment of high-angle patients. *Am J Orthod Dentofacial Orthop.* 2000;117:700–705.
12. Baumann A. Sagittale, vertikale und kippende Einflüsse des Palatinalbogens nach Goshgarian auf die oberen ersten Molaren. *Schweiz Mschr Zahnheilk.* 1981;91:310–314.
13. Dahlquist A, Gebauer U, Ingervall B. The effect of a transpalatal arch for the correction of first molar rotation. *Eur J Orthod.* 1996; 18:257–267.
14. Wise JB, Magnes B, Powers JM. Maxillary molar vertical control with the use of transpalatal arches. *Am J Orthod Dentofacial Orthop.* 1994;106:403–408.
15. Burstone CJ. Beta titanium: a new orthodontic alloy. *Am J Orthod Dentofacial Orthop.* 1980;77:121–132.