

Muscular Adaptation to Gradual Advancement of the Mandible

Xi Du, DDS, PhD^a;

Urban Hägg, DDS, Odont Dr, FHKAM, FCDSHK (Ortho), FDRSRCS (Edin), PhD^b

Abstract: Muscular activity of the superficial masseter muscle and anterior portion of the temporal muscle before, during, and after treatment, with gradual advancement of the mandible, was evaluated by assessing the average integrated electromyogram (EMG) with the mandible in retruded position (RP) and incisal edge-to-edge (EE) position on 23 consecutive subjects with skeletal Class II malocclusion. Toward the end of active treatment and follow-up, the RP position and EE position coincided. At any given registration, the EMG activity of the masseter muscle was at least twice ($P < .001$) that of the anterior portion of the temporal muscle. The EMG activity in RP for the anterior portion of the temporal muscle was not affected significantly, whereas the EMG activity at EE position decreased significantly ($P < .05$) during the initial treatment, but, thereafter, it increased continuously. The difference in EMG activity between six months of follow-up and pretreatment level reached statistical significance ($P < .05$). For the masseter muscle, the EMG activity at both RP and EE position was reduced about 20% during the initial treatment but returned to the pretreatment level during active treatment and exceeded pretreatment level by approximately 30% to 50% at two and six months of follow-up, respectively. In conclusion, it seemed that gradual advancement affected the anterior portion of the temporal muscle to a minor extent, whereas the effect on the masseter muscle was significant. (*Angle Orthod* 2003;73:525–531.)

Key Words: EMG; Class II; Herbst; Functional appliance; Prospective study

INTRODUCTION

The role of jaw muscle function as a determinant of the growth and development of the human craniofacial complex has been studied extensively. The first attempt to study muscular activity in orthodontics was reported by Moyers.¹ He suggested that the inherent imbalance of the temporomandibular musculature, particularly the temporal muscle, was an etiologic factor of “true Class II cases” and that a different pattern of muscle activity seemed to be associated with a different type of occlusion. It has also been reported that the synergistic behavior of the masseter and temporal muscles varied with the occlusion of the teeth.^{2–4} Pancherz⁵ postulated that the impaired muscle activity found in Class II cases might be attributed to diverging dentofacial morphology and unstable occlusal contact conditions.

Many muscular studies were focused on treatment effects of functional appliances, especially the activator. It has been reported that the immediate response to activator treatment was a strong reduction in temporalis activity during biting with the activator in place but that a normal pattern of balance reappeared after successful treatment.^{6–8}

The influence of the Herbst appliance with maximum bite-jumping on the electromyogram (EMG) pattern of the temporal and masseter muscles was investigated by Pancherz.^{5,9} It was found that the EMG activity from both the temporal and the masseter muscles was reduced at the start of treatment, increased to almost pretreatment values after three months of treatment, and exceeded pretreatment values when the appliance was removed after six months of treatment. Twelve months after treatment, when the occlusion was stabilized, the contraction pattern in the two muscles was similar to that seen in subjects with normal occlusion. In most previous studies on muscular activity in connection with functional appliance treatment, the mandible has been jumped to edge-to-edge (EE) incisal relationship. The movement of muscle action becomes extreme, and the forces transmitted to the dentition.

However, one might expect that the pattern in muscular activity might differ when the mandible is advanced gradually in a step-by-step pattern vs a one-step maximum advancement of the mandible. From a recent study, it was reported that there was favorable muscular response to a

^a Department of Orthodontics, West China College of Stomatology, Sichuan University, Chengdu, China.

^b Orthodontics, Faculty of Dentistry, University of Hong Kong, Hong Kong, SAR China, People's Republic of China.

Corresponding author: Urban Hägg, DDS, Odont Dr, FHKAM, FCDSHK (Ortho), FDRSRCS (Edin), PhD, Orthodontics, Faculty of Dentistry, University of Hong Kong, 2/F Prince Philip Dental Hospital, 34 Hospital Road, Hong Kong, SAR China, People's Republic of China
(e-mail: euohagg@hkusua.hku.hk).

Accepted: September 2002. Submitted: July 2002.

© 2003 by The EH Angle Education and Research Foundation, Inc.

TABLE 1. Dentofacial Morphology of 23 Subjects with Class II division Malocclusion Before Headgear-Herbst Treatment

Variable	Mean	SD
NS Ba	131.4°	5.0
SNA	82.4°	3.3
SNB	74.4°	3.5
ANB	8.1°	2.2
MxP/MnP	29.5°	5.6
N-MxP	56.9 mm	3.2
Me-MxP	65.8 mm	5.5
UI/MxP	120.7°	5.8
LI/MnP	98.5°	5.5
A and B on OP	7.2 mm	3.7
Esthetic line—UL	4.0 mm	1.4
Esthetic line—LL	5.6 mm	2.5
Overbite	4.1 mm	1.8
Overjet	8.9 mm	2.5

regimen of progressive Herbst appliance activation during the initial six months when the mandible was advanced gradually by six mm only.¹⁰ Therefore, it would be of interest to study the muscular response during further progressive advancement and after treatment. Therefore, the aim of this study was to investigate the changes in muscular activity when jumping the mandible step by step for a longer period and during a follow-up period.

MATERIALS AND METHODS

Subjects

The sample comprised 23 Class II, division 1 malocclusion subjects (13 boys and 10 girls) with a mean pretreatment age of 13.2 years (SD 1.4 years). Before treatment, each patient had a full-unit Class II molar relationship and an ANB angle of more than 5° (Table 1). We used hand-wrist radiographs to determine the developmental stage of all patients. Only patients who were between just before to just past the peak of the pubertal growth spurt were included in the study.¹¹ No subject had symptoms of temporomandibular joint disorder.

The sample of consecutive subjects was treated with the cast silver splint Herbst appliance with a high-pull occlusal headgear, and the mandible was advanced step by step at a rate of two mm every two months until a Class III incisal relationship was achieved.^{12,13} After six months, all subjects had the mandible advanced to the same extent, ie, three times two mm. Thereafter, the mandible continued to be advanced by two mm every two months, with the total amount of mandibular advancement (8–16 mm) based on the severity of the individual's malocclusion. The average treatment period was 1.1 years (SD 0.2 years; range 10 to 15 months). After active treatment, all the patients had a headgear activator as the retainer.^{14,15} During the whole observation period, the patients were instructed to use the headgear 10 hours or more a day with a force of 400 to 500 g.

Method of EMG registrations

The patients' EMG readings were taken on three separate occasions within four weeks before the insertion of the Herbst appliance so as to establish the individual's baseline measurements. EMG registrations were thereafter taken at one week and then at two, four, and six months into Herbst appliance therapy. During the follow-up period, ie, the retention period, EMG registrations were done at one week and at two, four, and six months.

EMG recordings and acrylic bite plate

Direct and integrated EMG activities from the superficial masseter and anterior temporalis muscles were measured bilaterally during maximum voluntary isometric contraction (MVIC), with the aid of a Myo-tronic K6-I Diagnosis System (Myo-tronics Inc., Seattle, Wash) in-built Scan 11 protocol (specifically for testing these two muscles). Disposable silver–silver chloride bipolar surface disk electrodes (Duo-trode, Myo-tronics) were used to gather data. The data were transmitted through eight double and one reference electromyographic channel to the system's preamplifier with no significant amplification bias. The muscular activities recorded were amplified and full-wave rectified and integrated. Integral values were of 50-ms epochs, and the corresponding analog signals were displayed in real time on the monitor.

The EMG activity was registered during maximum biting of the lower incisors onto a three-mm-thick customized acrylic bite plate with the mandible in both a retruded position (RP) (the pistongs of the Herbst appliance were released) and an incisal EE sagittal position.

At all recordings, each subject's custom-made acrylic bite plate (three mm thick) was constructed to register both the RP and the EE incisal relationship to ensure a reproducible and stable occlusal relationship. The transparent acrylic plate was constructed to be in contact with the upper incisors and second premolars with respect to the lower incisors. The plate was relieved from all other tooth contact.

The EMG registration was carried out with the subject sitting upright and relaxed in a dental chair, with the head in a normal position facing forward. Each EMG registration consisted of three periods of maximum biting lasting two seconds each and separated by two seconds of rest. Two registrations were taken with each set of electrodes (one in EE and one in RP). Three trials were taken with each of the EE and RP incisal bite positions. Two fresh sets of electrodes were used for each occasion.

Electrode placement

The bipolar prejelled, adhesive skin surface electrode (Duo-trode, Myo-tronics) used consisted of two circular silver–silver chloride disk electrodes (10.5 mm in diameter) placed on an adhesive tape cushion with a fixed distance

of two cm (bipolar recording). The electrodes were coated with a thin membrane of electrode paste, ready for instant use. The skin area overlying the muscles of interest was vigorously scrubbed with 70% alcohol and pumice, washed with alcohol, and dried carefully. Electrode position was marked with ink dots (about one mm in diameter). The masseter electrodes were placed midway from the inferior border of the zygomatic arch at the zygomaticotemporal suture to the gonial angle, about one cm distal to the anterior border of the muscle, using intraoral palpation. In the anterior temporalis, electrodes were placed 1–1.5 cm from the anterior border of the muscle, in an area of maximum contraction upon isometric contraction. In all cases, the electrodes were placed parallel to the muscle fiber and halfway between the origin and insertion of the muscles.

Electrode alignments were facilitated by palpation of the muscles, when the individual was requested to clench and relax at the position of maximum intercuspation. The electrode was gently pressed into place, ensuring that the circular adhesive foam cushion of the electrode was properly in contact with the skin. A grounding electrode was attached to the back of the subject during the registration. The electrode positions were then viewed from the front and top to check for asymmetry in placement with respect to surface landmarks. The EMG leads were then clipped onto the electrode snaps and left to stabilize for a few minutes (as per the manufacturer's instructions). To ensure proper correction, the K6-I computer was used to measure the impedance of each active electrode in situ.

After the completion of each set of EMG recordings, the electrodes were removed. All residual electrolytic gel as well as any surface markings were removed with alcohol-dampened gauze and dried. After a 20-minute rest, the whole procedure was repeated with a new set of electrodes, and the EMG-recording procedure was repeated once more.

Statistical methods

The average integrated activity during maximum biting of the incisors on a bite plate in RP and in an incisal EE position was measured at each EMG registration. For evaluation, the mean value of six (three \times two electrodes) periods of maximum biting at each EMG registration occasion was recorded. Differences between the values obtained at each visit and the "baseline data" (see below) were tested by the paired *t*-test. The levels of significance used were $P < .001$, $P < .01$, and $P \geq .05$. $P \geq .05$ was regarded as not significant (NS).

RESULTS

During all the observation periods, before treatment, during retreatment, or after treatment, there were no significant differences of the EMG activity between the left and right sides for each of the anterior temporal muscles and masseter muscles, respectively. Consequently, the data for the left

and right sides were pooled, and each value represents that at a single muscle only. After treatment and during the follow-up period, the RP and EE positions coincided. Consequently, the EMG values became the same and were represented with one value for the temporal muscle and masseter muscle at each follow-up registration.

Baseline data

Three separate EMG recordings were obtained within four weeks before treatment as baseline with the purpose of providing data. The EMG activities taken in the first occasion were lower than those taken in the second and third occasions. Comparing the first with the third occasion, the EMG activities of both sides of the masseter muscles were significantly different ($P < .05$). There was no significant difference (NS) of EMG activities between the second and third occasions on both sides of the temporal muscles and the left masseter muscle. Subsequently, the EMG activities on the second and third occasions were combined as baseline values (Table 2). At baseline, there was no significant difference in EMG activity between RP and EE position, respectively, for the anterior portion of the temporal muscle or the masseter muscle (Figures 1 and 2; Table 2).

Treatment changes

EMG activity during maximal biting in RP. For the anterior portion of the temporal muscle, there were statistically no significant changes between before treatment, during treatment, and after treatment (Figure 1; Table 2).

For the masseter muscle, after one week and two months of treatment, the EMG activity was reduced (NS), but, thereafter, the EMG activity increased, and from two to six months of follow-up, it was significantly above the pretreatment level (Figure 2; Table 2).

EMG activity during maximal biting in EE position. For the anterior portion of the temporal muscle, after two months of treatment, the EMG activity reduced significantly compared with pretreatment level. Thereafter, the EMG activity gradually increased and was significantly greater than the pretreatment level at the six months of follow-up (Figure 1; Table 2).

The EMG activity was reduced for the masseter muscle after one week and two months of treatment, the reduction being statistically significant. Thereafter, the EMG activity became similar to the pretreatment level. The EMG activity at four and six months was significantly increased compared with the pretreatment level (Figure 2; Table 2).

EMG activity during maximal biting in RP vs EE position. For the anterior portion of the temporal muscle, the difference in the EMG activity at RP vs EE became pronounced during treatment, with the difference becoming statistically significant at two and four months of treatment. For the masseter muscle, there was no significant difference

TABLE 2. Mean Voltage Amplitude (MicV) During Maximal Bite in Retruded Position (RP) and Edge-to-Edge Position (EE) in Various Recordings

Months	n	Temporalis					Muscular Muscle				
		RP		EE		Difference (RP – EE)	RP		EE		Difference (RP – EE)
		Mean	SD	Mean	SD		Mean	SD	Mean	SD	
Baseline	23	54.8	24.0	46.6	18.9	8.2	122.2	37.3	123.7	36.3	–1.5
Treatment											
0.25	23	51.5	22.3	39.9	18.2	11.6	106.1	38.7	113.2	39.3	–7.1
2	23	52.8	23.8	31.4	13.9	21.4***	102.6	42.2	100.7	33.6	1.9
4	22	54.8	20.3	40.0	20.0	14.8*	118.1	38.5	121.0	36.4	–2.9
6	22	56.1	28.0	45.4	22.0	10.7	129.3	48.7	131.2	43.9	–1.9
12	—	—	—	—	—	—	—	—	—	—	—
Follow-up											
0.25	12	47.2	27.7				134.0	40.4			
2	14	53.6	31.4				150.8	47.0			
4	12	61.3	31.5				166.4	55.8			
6	16	62.7	31.6				169.2	51.2			
MicV and % of baseline											
Treatment											
0.25		–3.3 (–6.0%)		–6.8 (–14.6%)			–16.1 (–13.2%)		–10.5 (–8.5%)		
2		–2.0 (–3.6%)		–15.2** (–32.6%)			–19.6 (–16.0%)		–23.0* (–18.6%)		
4		0.0 (0.0%)		–6.6 (–14.2%)			–4.1 (–3.4%)		–2.7 (–2.2%)		
6		1.3 (2.4%)		–1.2 (–2.6%)			7.1 (5.8%)		7.5 (6.1%)		
12		—		—			—		—		
Follow-up											
0.25		–7.6 (–13.9%)		0.6 (1.3%)			11.8 (9.7%)		10.3 (8.3%)		
2		–1.2 (–2.2%)		7.0 (15.0%)			28.6* (23.4%)		27.1 (21.9%)		
4		6.4 (11.7%)		14.6 (31.3%)			44.2** (36.2%)		42.7** (34.5%)		
6		7.9 (14.4%)		16.1* (34.5%)			47.0** (38.5%)		45.5** (36.8%)		

* $P < .05$; ** $P < .01$; *** $P < .001$.

in EMG activity between RP and EE positions during active treatment (Figures 1 and 2; Table 2).

EMG activity of anterior portion of temporal muscle vs masseter muscle. The EMG activity of the masseter muscle was at least twice ($P < .001$) that of the anterior portion of the temporal muscle throughout the study.

DISCUSSION

To investigate the reproducibility of the EMG measurements, a comparison was made between registrations performed on each of the three baseline registrations before treatment. The results showed that most of the EMG values obtained at the first registration were significantly lower than those taken at the second and third registrations. The reason for this pattern might be that the subjects had to get used to biting on the acrylic plate and did not bite with maximal force at the first registration. Therefore, the values obtained in the second and third registrations were combined and became the “baseline data.”

A three-mm-thick custom-made acrylic bite plate with impressions of upper and lower anterior teeth was made for each subject and used at each registration throughout the study to permit EMG recordings to be obtained in a standardized manner.¹⁶ Using a bite plate can also avoid the

possible influence on EMG recordings by the occlusal interference or the instability of the occlusion during the course of treatment, as reported by other researchers.^{8,9,17–19}

In this study, the EMG recordings of maximal biting force were taken both in RP and in incisal EE position. As the mandible was advanced by two mm every two months, the RP and EE position came closer, eventually coinciding toward the end of treatment and at the follow-up registrations. Recordings taken in RP represented the muscular activity at a potentially new RP, ie, to what extent the muscles adapted to the new position of the mandible. The EE position itself was also affected because of changes in the incisor angulations during the treatment and the settling of the dentition during the six-month follow-up period.²⁰

There were fewer patients with EMG registrations during the follow-up period (Table 2). This was mainly due to patients becoming increasingly reluctant to participate in the rigorous procedures.

The general pattern of the EMG activity of the muscles observed in this study was similar when biting in RP and in EE position (Figures 1 and 2; Table 2). At the beginning of treatment, the EMG activity was reduced. Thereafter, it increased to the pretreatment level at four and six months of treatment, which was in general agreement with previous

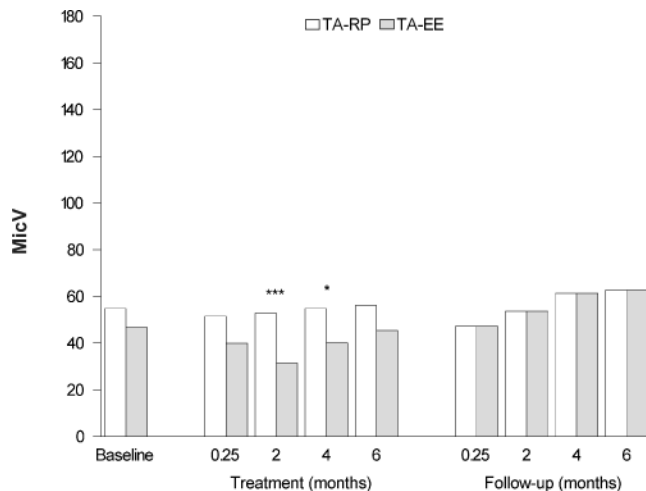


FIGURE 1. Average voltage for the temporal muscle at retruded position (RP) and incisal edge-to-edge relationship (EE). At the follow-up registration, RP and EE coincided. Significant differences between RP and EE position are marked. *, $P < .05$; ***, $P < .001$.

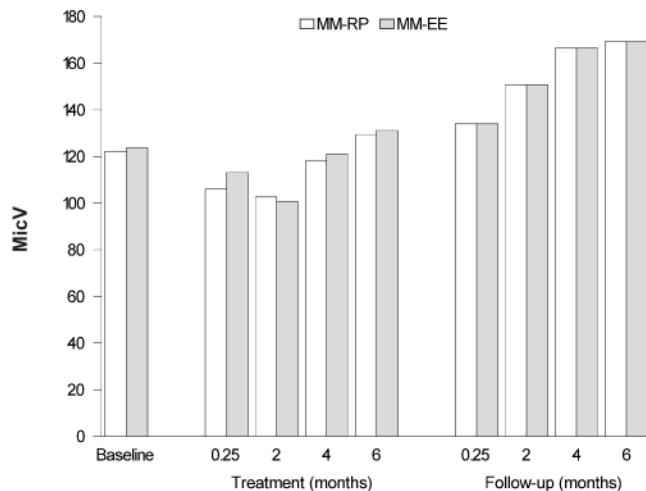


FIGURE 2. Average voltage for the masseter muscle at retruded position (RP) and incisal edge-to-edge relationship (EE). At follow-up registration, RP and EE coincided.

studies on Herbst treatment,^{9,10,18,21} despite the different mode of advancement of the mandible in those studies compared with the present study.

Biting on an activator has also shown a reduced temporal muscle activity.^{7,8,19,22} In normal occlusion, when the mandible was protracted, the anterior temporal muscle activity also became reduced.²³ However, in this study, in which the mandible was gradually advanced, the anterior portion of the temporal muscle was not significantly affected when the mandible was in RP and in EE position for only two months into treatment. There was a significant imbalance of the EMG activity between RP and EE positions at two and four months of treatment. For the masseter muscle, there was no significant difference in EMG activity at RP and EE positions at any registration. It has been suggested

that the reported significant decrease of the amplitude of the anterior temporal and masseter muscles could be due to occlusal instability caused by changed tooth position and intermaxillary relations brought about by treatment.^{8,19} However, other studies have shown no relation between occlusal contact conditions in the posterior or anterior dental arch segment and EMG activity from the temporal and masseter muscles during maximal biting.^{5,18,24} A correlation was found between an impaired EMG activity from the masticatory muscles and a cusp-to-cusp occlusion.^{5,25} Consequently, the unstable occlusal situation at the initial phase of Herbst treatment could explain the reduced EMG activity reported previously.¹⁸ However, because a custom-made bite plate was used at all recordings of EMG activity, one would assume that the changes in EMG activity were not caused by an unstable occlusion in this study. On the other hand, the fact that the bite plate made of hard acrylic might cause some decrease in EMG activity cannot be ignored.²⁶

When a functional appliance was placed in the mouth, the elevator muscles became elongated and the amount of elongation was proportional to the amount of bite raising and mandibular protrusion caused by the appliance.²⁷ The shape and amplitude of the motor unit potential waveform changed progressively with a change in the length of the masseter muscle.²⁸ Carels and van Steenberghe²⁹ observed significant changes in the poststimulus electromyographic complex of the masseter muscles in children undergoing treatment with the Bionator. When the forward positional response of the mandible was achieved during the first few months of treatment, a stretch of the masseter muscle—chiefly of the vertical deeper part—was present. Before a structural adaptation to the masseter muscle lengthening took place, increased γ activity could act to restore the original muscle length reflexively, which would give rise to the muscle imbalance.²⁹

In an animal study,³⁰ it had been shown that initial placement of the Herbst and functional appliances to induce marked mandibular protrusion were associated with a statistically significant decrease in postural EMG activity in the superficial masseter muscles. This decreased postural EMG activity persisted for approximately six weeks.³⁰ From the changing pattern of EMG recordings obtained in this study, it was obvious that the lowest EMG activity during treatment also occurred within the first two months (Figures 1 and 2; Table 2).

After four months of Herbst appliance treatment, the EMG activity in the two muscles investigated had increased again, especially in the masseter muscle, and after six months of treatment, the EMG activity had reached its pretreatment values. During the retention period, when the RP and EE position did coincide, the EMG activity for both investigated muscles continued to increase gradually, becoming larger than the pretreatment values. For the anterior portion of the temporal muscle, the EMG activity at the six-month follow-up was significantly higher for the EE

position only. For the masseter muscle, the increased EMG activity was much higher, being close to 30% larger at two months of follow-up and 50% larger at six months of follow-up when compared with the pretreatment values (Table 2). The overall pattern of the EMG activity demonstrated in this study was in general agreement with previous studies on Herbst appliance treatment.^{5,10,25}

In this study, the EMG activity from the anterior temporal muscle was much lower ($P < .001$) than that from the masseter muscle during the whole observation period, and the difference increased with time (Figures 1 and 2; Table 2). An increasing difference in EMG activity between the two investigated muscles had also been reported from a previous study on gradual advancement of the mandible.¹⁰ In a study on activator patients, it was found that the EMG activity from the masseter muscle was less than that from the temporal muscle before treatment, but after treatment, no difference in the EMG activity was found between the two muscles.²⁵ The fan-shaped temporal muscle was the main postural muscle of the mandible.^{1,31} It has a broad origin, which extends over a wide area from the laterotemporal portion of the skull and inserts on the coronoid process and the anterior border of the ascending ramus of the mandible.³² The muscle has been divided into three separate components, ie, an anterior part, in which the fibers are almost vertical; a middle part; and a posterior part. The vertically directed fibers (anterior part) showed the greatest number of active motor units during biting in habitual (centric), retruded, and ipsilateral molar occlusion. Fewer motor units were active in protruded occlusion. There were very few active motor units during incisor and contralateral molar biting,^{21,33} and this possibly explains why the EMG activity from the anterior temporal muscle was much lower during maximal biting, especially when biting in the EE position.

Considerable individual variation in EMG activity has been observed in this study and other studies, which highlights the question of the reliability and usefulness of EMG registration of individual subjects.^{34–36} In a recent study,¹⁰ a sample of similar age with similar type of malocclusion, treated with a similar appliance, mode of activation, recording technique, and type of electrode, were used. However, that study included only the initial six months of active treatment and was based on a smaller sample. In this study, the sample size was larger and the total observation period three times longer. Moreover, in this study, the muscular activity was expressed at the average EMG achieved and presented for one muscle at a time only. In the other study,¹⁰ considerably higher values for the muscular activity were reported because of the maximum EMG achieved, and the values for the left and right side of each muscle were added together. We considered the average EMG achieved to be a better representation of the muscular activity than the maximum EMG based on short-lived peak values of EMG activity. In this study, the EMG activity seemingly

continued to increase during the final six months of Herbst treatment and the six months of retention with the headgear activator. When the Herbst appliance was removed, there was no significant decrease in the EMG activity, which might indicate that there was no obvious difficulty in adjusting to a new RP position after 12 months of active treatment, when the Herbst appliance had been removed. During the six months of retention period, when most of the dental settling occurs and the occlusion becomes stable,²⁰ there was a steady increase of EMG activity, especially for the masseter muscle. It seems that quantitative EMG of the masticatory muscles is an informative tool in the evaluation of treatment results, to be added to the conventional dentofacial measurements that have been reported elsewhere for this sample.^{12,13}

CONCLUSIONS

In conclusion, this study confirmed that Herbst treatment of skeletal Class II patients had initially decreased the muscular activity, but, thereafter, there was a positive effect on muscular activity, which continues to improve, especially for the masseter muscle when the treatment was prolonged.

ACKNOWLEDGMENTS

Sincere thanks are expressed to Mr. Shadow Yeung for his kind help with analysis of the data and Ms. Sue Cheung for her assistance with the manuscript. The research was supported by the University and Polytechnic Grant Committee, the University of Hong Kong, grant 30205.10201264.15633.08003.323.01.

REFERENCES

1. Moyers RE. Temporomandibular muscle contraction patterns in Angle Class II division 1 malocclusions: an electromyographic analysis. *Am J Orthod.* 1949;35:837–857.
2. Pruzansky S. The application of electromyography to dental research. *J Am Dent Assoc.* 1952;44:49–68.
3. Perry HT Jr. Functional electromyography of the temporal and masseter muscles in Class II, division 1 malocclusion and excellent occlusion. *Angle Orthod.* 1955;25:49–58.
4. Moss JP. Function—fact or fiction? *Am J Orthod.* 1955;67:625–646.
5. Pancherz H. Activity of the temporal and masseter muscles in Class II, division 1 malocclusions. An electromyographic investigation. *Am J Orthod.* 1980;77:679–688.
6. Ahlgren J. An electromyographic analysis of the response to activator (Andresen-haupl) therapy. *Odontol Revy.* 1960;11:125–151.
7. Ahlgren J. The neurophysiologic principles of the Andresen method of functional jaw orthopedics: a critical analysis and new hypothesis. *Swed Dent J.* 1970;63:1–9.
8. Ingervall B, Bitsanis E. Function of masticatory muscles during the initial phase of activator treatment. *Eur J Orthod.* 1986;8:172–184.
9. Pancherz H. The Herbst appliance—its biologic effects and clinical use. *Am J Orthod.* 1985;87:1–20.
10. Leung DK, Hägg U. An electromyographic investigation of the first six months of progressive mandibular advancement of the Herbst appliance in adolescents. *Angle Orthod.* 2001;71:177–184.

11. Hägg U, Taranger J. Maturation indicators and the pubertal growth spurt. *Am J Orthod.* 1982;82:299–309.
12. Hägg U, Du X, Rabie ABM. Initial and late treatment effects of Headgear-Herbst appliance with mandibular step-by-step advancement. *Am J Orthod. Dentofacial Orthop.* 2002;122:477–485.
13. Hägg U, Du X, Rabie ABM, Bendeus M. What does headgear add to Herbst treatment and to retention? *Semin Orthod.* 2003;9: 56–66.
14. Van Beek H. Overjet corrections by a combined headgear activator. *Eur J Orthod.* 1982;4:279–290.
15. Van Beek H. Combination headgear-activator. *J Clin Orthod.* 1984;18:185–189.
16. Jimenez ID. Electromyography of masticatory muscles in three-jaw registration positions. *Am J Orthod.* 1989;95:282–288.
17. Randow K, Carlsson K, Edlund J, Oberg T. The effect of an occlusal interference on the masticatory system. An experimental investigation. *Odontol Revy.* 1976;27:245–256.
18. Pancherz H, Anehus-Pancherz M. Muscle activity in Class II division 1 malocclusions treated by bite jumping with the Herbst appliance. An electromyographic study. *Am J Orthod.* 1980;78: 321–329.
19. Ingervall B, Thuer U. Temporal muscle activity during the first year of Class II, division 1 malocclusion treatment with an activator. *Am J Orthod.* 1991;99:361–368.
20. Pancherz H, Hansen H. Occlusal changes during and after Herbst treatment: a cephalometric investigation. *Eur J Orthod.* 1986;8: 215–228.
21. Bakke M, Paulsen HU. Herbst treatment in late adolescence: clinical, electromyographic and radiographic analysis of one case. *Eur J Orthod.* 1989;1:397–407.
22. Latif A. An electromyographic study of the temporalis muscle in normal persons during selected positions and movements of the mandible. *Am J Orthod.* 1978;43:577–591.
23. Ahlgren J. Early and late electromyographic response to treatment with activators. *Am. J. Orthod.* 1978;74:88–93.
24. Ingervall B, Thilander B. Relation between facial morphology and activity of the masticatory muscles. *J Oral Rehabil.* 1974;1: 131–147.
25. Pancherz H, Anehus M. Masticatory function after activator treatment. An analysis of masticatory efficiency, occlusal contact conditions and EMG activity. *Acta Odontol Scand.* 1978;36:309–316.
26. al-Quaran FA, Lyons MF. The immediate effect of hard and soft splints on the EMG activity of the masseter and temporalis muscles. *J Oral Rehabil.* 1999;26:559–563.
27. Yuen SW, Hwang JC, Poon PW. Changes in power spectrum of electromyograms of masseter and anterior temporal muscles during functional appliance therapy in children. *Am J Orthod.* 1990; 97:301–307.
28. Miles TS, Nordström MA, Turker KS. Length-related changes in activation threshold and waveform of motor units in human masseter muscle. *J Physiol Lond.* 1986;370:457–465.
29. Carels C, van Steenberghe D. Changes in neuromuscular reflexes in the masseter muscles during functional jaw orthopedic treatment in children. *Am J Orthod.* 1986;90:410–419.
30. Sessle BJ, Woodside DG, Bourque P, Gurza S, Powell G, Voudouris J, Metaxas A, Altuna G. Effect of functional appliances on jaw muscle activity. *Am J Orthod.* 1990;98:222–230.
31. Moyers RE. An electromyographic analysis of certain muscles involved in temporomandibular movement. *Am J Orthod.* 1959; 36:481–515.
32. Gianelly AA, Goldman HM. *Tooth Movement. Biologic Basis of Orthodontics.* Philadelphia, Pa: Lea & Febiger; 1971:116–204.
33. Greenfield BE, Wyke BD. Electromyographic studies of some of the muscles of mastication. *Br Dent J.* 1956;100:129–143.
34. Pancherz H, Winnberg A. Reliability of EMG registrations. A quantitative analysis of masseter muscle activity. *Electromyogr Clin Neurophysiol.* 1981;21:67–81.
35. Burdette BH, Gale EN. Reliability of surface electromyography of the masseteric and anterior temporal areas. *Arch Oral Biol.* 1990;35:747–751.
36. Cerere F, Ruf S, Pancherz H. Is quantitative electromyography reliable? *J Orafac Pain.* 1996;10:38–47.