

Intrusion of Supererupted Molars with Titanium Miniplate Anchorage

Keith H. Sherwood, DDS^a; James Burch, DDS, MS^b; William Thompson, DDS, MS^c

Abstract: Titanium miniplates, normally used in orthognathic surgery for osteotomy fixation, were placed in the maxilla and mandible for skeletal anchorage to orthodontically intrude severely hypererupted unopposed molars. (*Angle Orthod* 2003;73:597–601.)

INTRODUCTION

Numerous orthodontic approaches to achieve “intrusion” of posterior teeth have been reported. These techniques were usually applied to patients with open-bite malocclusions to alter the occlusal plane by intruding posterior teeth. High pull headgear has been used to intrude maxillary molars, especially in mixed-dentition patients.¹ The use of posterior bite blocks has been advocated for correcting open bites.^{1,2} Bite blocks augmented with magnets^{3–5} or springs⁶ have also been recommended.

The use of bite blocks and headgear may achieve relative intrusion of posterior teeth in growing patients with open bites. The molars are held in place, whereas the remainder of the dentoalveolus grows downward. There is little scientific evidence, however, to show that any of the traditional orthodontic approaches can predictably intrude posterior teeth in adult patients.

Placement of dental implants for orthodontic anchorage has been reported. Implants such as screws,^{7,8} cylindrical implants,^{9–12} and onplants¹³ have been used for skeletal anchorage to move teeth mesially or distally in the arch. Recently there have been reports of the use of osteotomy miniplates in the maxilla¹⁴ and mandible¹⁵ to assist in orthodontic correction of open bites. The need to intrude individual supererupted posterior teeth in adult patients is a good indication for implant-based skeletal anchorage.

CASE REPORT

Two adult patients, one female (patient 1) and one male (patient 2), were referred for orthodontic treatment of hypererupted molars. The patients had lost the opposing occluding teeth many years earlier. The molar(s) to be treated had extruded into the edentulous space to such an extent that the occlusal surface was in contact with the opposing alveolar ridge. Without intervention, an implant or prosthesis could not be placed to restore the edentulous area.

Treatment options

The supererupted teeth could have been drastically reduced. This would have required root canal therapy, crown lengthening surgery, and restoration with crowns. Some patients may have required reduction alveoloplasty in the opposing edentulous area as well.

Treatment plan

The treatment plan, with the patient's informed consent, was to orthodontically intrude the supererupted teeth with elastic traction from the band on the affected molar using a miniplate anchored into cortical bone (Figure 1). The objective was to increase the interarch space to allow dental restoration of the edentulous area without damaging the hypererupted teeth.

Treatment procedures

Under local anesthesia, a 1.5-cm incision was made in the buccal vestibule adjacent to the hypererupted molars. A full thickness mucoperiosteal flap was reflected and the cortical bone exposed. An L-shaped titanium miniplate (Figure 2) was contoured over the bone and the last loop on the plate allowed to project through the vestibular wound adjacent to the extruded molar. Two self-tapping screws, three mm each, were placed to secure the plate to the bone (Figure 3). The mucosal incision was sutured and allowed to heal around the exposed miniplate loop for approximately two months. The procedure took 15 minutes per plate, and

^a Assistant Professor, Department of Orthodontics and Co-Director Postgraduate Orthodontic Residency Program, Nova Southeastern University College of Dental Medicine, Ft Lauderdale, Fla.

^b Professor, Department of Orthodontics, Nova Southeastern University College of Dental Medicine, Ft Lauderdale, Fla.

^c Professor, Department of Orthodontics, Nova Southeastern University College of Dental Medicine, Ft Lauderdale, Fla.

Corresponding author: Keith H. Sherwood, DDS, Department of Orthodontics and Co-Director Postgraduate Orthodontic Residency Program, Nova Southeastern University College of Dental Medicine, 3200 South University Drive, Ft Lauderdale, FL 33328-2018 (e-mail: sherwood@nova.edu).

Accepted: December 2002. Submitted: December 2002.

© 2003 by The EH Angle Education and Research Foundation, Inc.

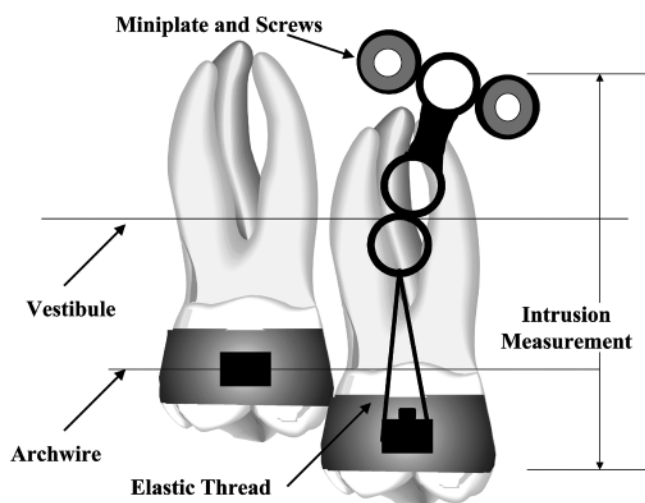


FIGURE 1. Diagram of molar intrusion.




FIGURE 2. Leibinger miniplate, screw, and screwdriver.

there was minimal patient morbidity at the time of surgery or postoperatively.

Meanwhile, the other teeth were orthodontically leveled exclusive of the extruded molars. The hyperextruded teeth were banded and left unattached to the archwire. Eight



FIGURE 3. Photograph of miniplate inserted in patient 1.

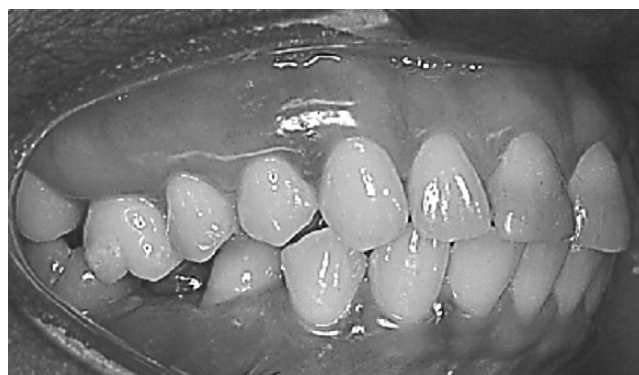

FIGURE 4. Pretreatment photograph of patient 1.

weeks after plate placement, new records were made for dental cast, photographic, cephalometric, and panoramic radiographic measures for analysis of progress.

Before intrusion mechanics were begun, a continuous 0.016- × 0.022-inch stainless steel archwire was placed excluding the supererupted molar(s). In the maxillary case, buccal crown tipping of the tooth to be intruded was controlled by an overlay 0.020-inch round Australian archwire. The wire was moderately constricted and placed only in the headgear tubes of the maxillary hyperextruded molar and the contralateral normal first molar. This wire was not engaged in the brackets of the other teeth, allowing it to rotate freely anteriorly and laterally so that it generated no vertical force on the molars or on any other teeth. However, it provided an effective counterbalancing moment to the buccal tipping moment created by the elastic thread traction. The normal contralateral molar was stabilized by the continuous rectangular archwire. In the mandibular case, an offset, adjustable lingual arch was used to control tipping.

An elastic thread was passed through the exposed loop on the implanted miniplate and tied tightly over the buccal tube of the extruded molar to initiate intrusion. New elastic thread was applied and activated every month (Figures 4 through 11).

Intrusion mechanics were terminated when the supererupted tooth was at the plane of occlusion of the other

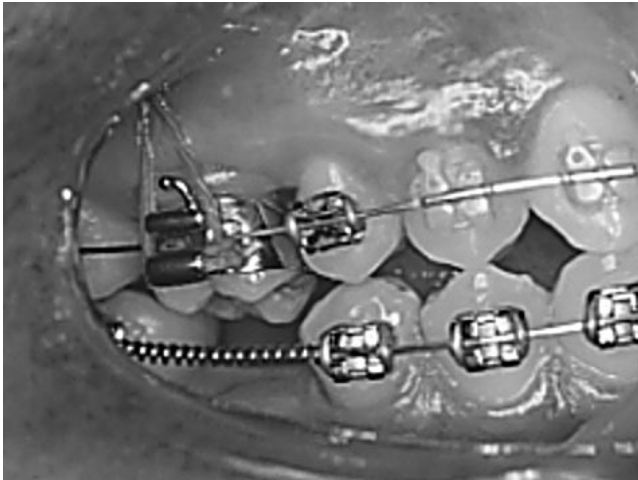


FIGURE 5. Postintrusion photograph of patient 1.

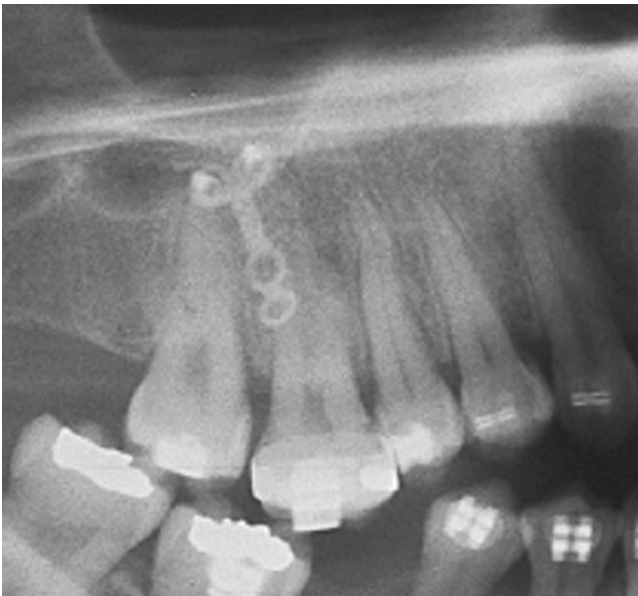

FIGURE 6. Pretreatment panoramic radiograph of patient 1.

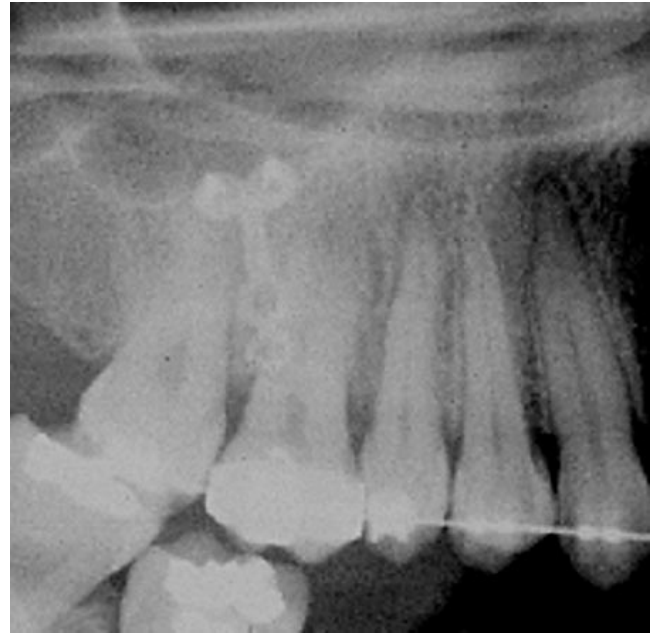


FIGURE 7. Postintrusion panoramic radiograph of patient 1.

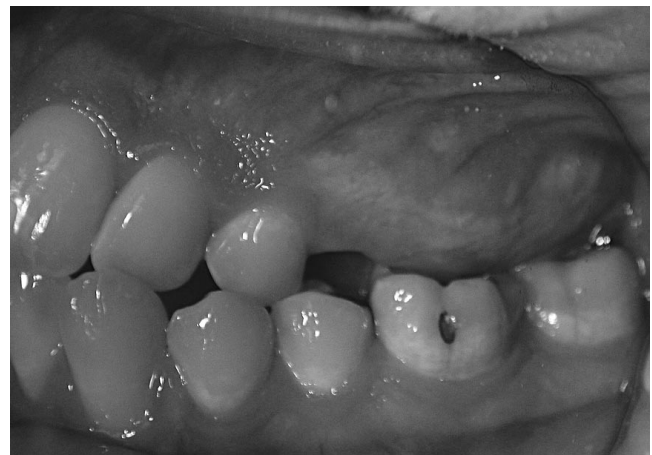

FIGURE 8. Pretreatment photograph of patient 2.

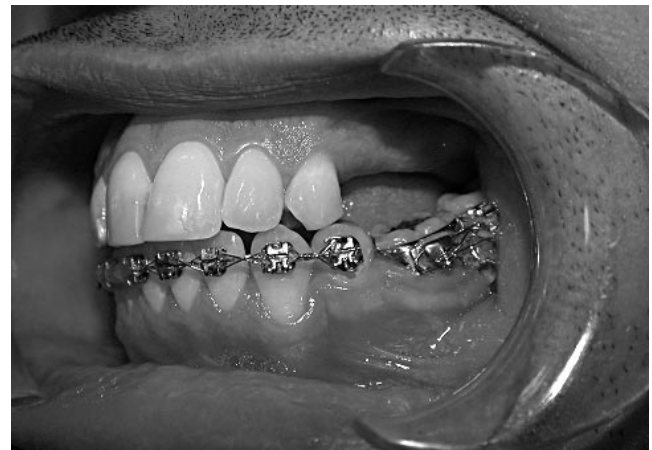

FIGURE 9. Postintrusion photograph of patient 2.

teeth in the arch (mean active intrusion time, 6.5 months). The plate was then lightly ligated to the molar tube with wire ligature and a continuous rectangular archwire placed. When the orthodontic treatment is completed, the intruded molars will be retained in position until the opposing occlusion is restored.

A corrected panoramic radiograph is most useful for the analysis of the intrusion process. It shows the entire treated dental segment, alveolus, and miniplate. Unlike a cephalometric radiograph, the image does not superimpose on that of the contralateral side. Radiographs were corrected for magnification with the aid of IVSD Image Version 1.5 Software (Indiana University School of Dentistry).

Analysis tracings of pre and postintrusion pans were made using the paralleling technique.¹⁴ This analysis stan-

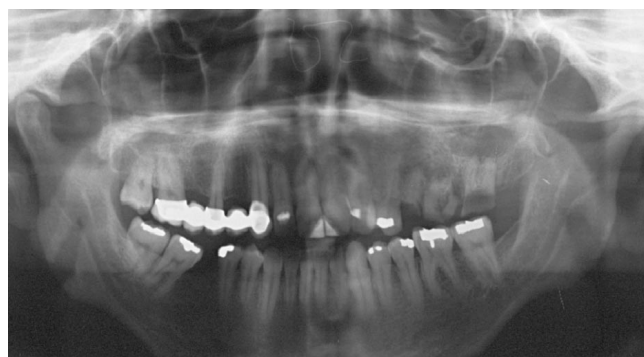

FIGURE 10. Pretreatment panoramic radiograph of patient 2.

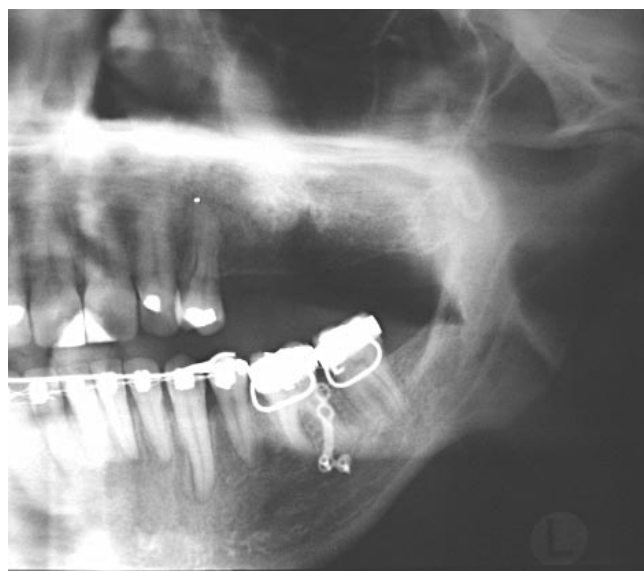

FIGURE 11. Postintrusion panoramic radiograph of patient 2.

TABLE 1. Corrected Intrusion Results

	Patient	
	1	2
First molar intrusion (mm)	4.00	4.15
Months active intrusion	5.5	7.5

dardizes the measurement of linear distance changes from the molar band to a designated point on the miniplate.

Treatment progress and results

Table 1 summarizes the treatment results for the two patients described above. Both subjects had significant intrusion of the affected molars, resulting in a leveling of the occlusal plane and alveolar bone. There was no discernable movement of any of the miniplates observed either clinically or radiographically. There was no incident of post-operative infection or periodontal pathology attributable to the placement, presence, or maintenance of the miniplates. Patient tolerance of the plates was excellent.

DISCUSSION

In 1997, Kanomi¹⁶ reported the use of mini implants as anchorage to intrude and retract anterior teeth. More recently, Sherwood et al¹⁴ and Umemori et al¹⁵ reported the use of titanium miniplates for skeletal anchorage to intrude posterior teeth in an effort to close anterior open bites. Titanium miniplates are commonly used to stabilize facial fractures and osteotomy segments. The use of miniplates for skeletal anchorage in orthodontics is recommended for the following reasons:

- Miniplates have a long history of use and biocompatibility in stabilizing facial fractures and osteotomy segments.^{17,18}
- Miniplates come in a variety of convenient shapes and sizes and are easily adaptable to most bony surfaces.
- Miniplates can be used for a variety of anchorage purposes.
- Miniplate placement is minimally invasive and appropriate to an office setting.
- Miniplates, when used properly have little or no risk of causing damage to nerves or tooth roots.
- Most oral surgeons already have substantial experience with placement and manipulation of miniplates.

The miniplate proved to be an effective skeletal anchorage device for intrusion in the cases presented. There was little patient discomfort associated with the placement, maintenance, and removal of the plates.

CONCLUSIONS

Titanium miniplates placed in the maxilla or mandible provide skeletal anchorage to orthodontically intrude severely hypererupted unopposed molars.

REFERENCES

1. Proffit WR. *Contemporary Orthodontics*. 2nd ed. Mosby Year Book, St. Louis; 1993: 236.
2. Iscan HN, Sarisoy L. Comparison of the effects of passive posterior bite-blocks with different construction bites on the craniofacial and dentoalveolar structures. *Am J Orthod Dentofacial Orthop*. 1997;112:171-177.
3. Breunig A, Rokosi T. The treatment of open-bites using magnets. *Fortschr Kieferorthop*. 1992;53:179-186.
4. Dellinger EL. Active vertical corrector treatment. *Am J Orthod Dentofacial Orthop*. 1996;110:145-154.
5. Noar JH. The performance of bonded magnets used in the treatment of anterior open bite. *Am J Orthod Dentofacial Orthop*. 1996;109:649-656.
6. Kuster R, Inger Vall B. The effect of treatment of skeletal open bite with two types of bite-blocks. *Eur J Orthod*. 1992;14:489-499.
7. Costa A, Raffaini M, Melsen B. Miniscrews as orthodontic anchorage: a preliminary report. *Int J Adult Orthod Orthognath Surg*. 1998;13:201-209.
8. Southard TE, Buckley MJ, Spivey JD, Krizen KE, Casko JS. Intrusion anchorage potential of teeth vs rigid endosseous implants. *Am J Orthod Dentofacial Orthop*. 1995;107:115-120.

9. Kokich VG. Managing complex orthodontic problems; the use of implants for anchorage. *Semin Orthod.* 1996;2:153–160.
10. Schweizer CM, Schlegel KA, Rudzki-Jason I. Endosseous dental implants in orthodontic therapy. *Int Dent J.* 1996;46:61–68.
11. Roberts WE. Rate of mesial translation of mandibular molars using implant anchored mechanics. *Angle Orthod.* 1996;66:331–337.
12. Higuchi K. The use of titanium fixtures for intraoral anchorage to facilitate orthodontic tooth movement. *Int J Oral Maxillofac Implants* 1991;6:338–344.
13. Block MS, Hoffman DR. A new device for absolute anchorage for orthodontics. *Am J Dentofacial Orthop.* 1995;107:251–258.
14. Sherwood KH, Burch JG, Thompson WJ. Closing anterior open bites by intrusion of molars using titanium miniplate anchorage. *Am J Orthod Dentofacial Orthop.* 2002;122:593–600.
15. Umemori M, Sugawara J, Mitani H, Kamamura H. Skeletal anchorage for open bite correction. *Am J Orthod Dentofacial Orthop.* 1999;115:166–174.
16. Kanomi R. Mini-implant for orthodontic anchorage. *J Clin Orthod.* 1997;31:763–767.
17. Cobetto GA, McClary SA, Zallen RD. Treatment of mandibular fractures with malleable titanium mesh plates. *J Oral Maxillofac Surg.* 1983;41:597–600.
18. Acero J, Calderon J, Salmeron JI, Verdaguer JJ, Concejo C, Somacarrera ML. The behavior of titanium as a biomaterial; microscopy study of plates and surrounding tissue in facial osteosynthesis. *J Craniomax Surg.* 1999;27:117–123.