

# Modulation of Masticatory Muscle Activity by Tongue Position

Shigeki Takahashi, DDS, PhD<sup>a</sup>; Gen Kuribayashi, DDS<sup>b</sup>; Takashi Ono, DDS, PhD<sup>c</sup>;  
Yasuo Ishiwata, DDS, PhD<sup>d</sup>; Takayuki Kuroda, DDS, PhD<sup>e</sup>

**Abstract:** The purpose of this study was to test whether the tongue position affects the electromyographic (EMG) activities of masticatory muscles. We recorded the EMG activities of the masseter and anterior temporalis muscles in 10 skeletal Class I adults. Tongue position was monitored by two pressure transducers embedded in the midpalatal region and the lingual flange of a custom-made acrylic monoblock. We instructed subjects to assume three different tongue positions: rest, superior, and anterior. Friedman's test and Sheffe's *F*-test were used to statistically examine differences in muscle activities induced by changes in tongue position. Significant differences were found in masseter muscle activity between the rest and anterior positions and in anterior temporalis muscle activity between the rest and both the anterior and the superior tongue positions. We concluded that masticatory muscle activity is affected by tongue position. (*Angle Orthod* 2004;75:35–39.)

**Key Words:** Tongue position; Masticatory muscle; Myofunctional therapy

## INTRODUCTION

Previous studies in both cats<sup>1</sup> and humans<sup>2</sup> have shown that tongue position is reflexively controlled by jaw position. Although little is known about the reverse relationship, the tongue position is an important subject that has attracted the interest of orthodontists.

Some investigators have noted that an abnormal tongue position at rest (ie, static) and during function (ie, dynamic) can cause certain types of malocclusion including anterior open bite.<sup>3–10</sup> Proffit<sup>5</sup> has stated that the resting pressure of the tongue is one of the primary factors in the maintenance of dental equilibrium. In addition, an augmented electromyographic (EMG) activity in the tongue-protruding muscle (ie, genioglossus muscle) has been reported in subjects with anterior open bite.<sup>11</sup> Moreover, it has been suggested that the resting tongue position in subjects with skeletal

open bites appears to be related to the position of the incisors.<sup>12</sup>

Tongue position during dynamic movement is also of clinical significance. While swallowing, the tongue is positioned anteriorly in subjects with anterior open bite.<sup>13</sup> This triggers changes in dentofacial morphology, including the proclination of incisors, overeruption of molars, and increased facial height.<sup>14–16</sup> Recently, it has been demonstrated that tongue pressure is gradually distributed on the palatal surface during swallowing in adult subjects with normal oral function and occlusion, ie, weaker pressure is exerted anteriorly, whereas stronger pressure is exerted posteriorly.<sup>17</sup>

In subjects with obstructive sleep apnea (OSA), in which the tongue plays a crucial role, there are several significant correlations between craniofacial and tongue variables.<sup>18</sup> Furthermore, an inferior position of the tongue was associated with the severity of OSA, which causes a fan-like configuration of the lower part of the face in the sagittal plane.<sup>19</sup> Thus, the static position of the tongue appears to affect both occlusion and craniofacial morphology.

It has been reported that the position of the tongue affects the EMG activity of the temporalis and suprahyoid muscles, indicating that at least some jaw-closing-muscle EMG activity can be modulated as a function of tongue position.<sup>20</sup> However, those reports did not focus on the position of the body of the tongue but rather on the position of the tongue tip.<sup>20</sup>

Myofunctional therapy (MFT)<sup>21,22</sup> has been reported to reestablish normal oral function in patients with myofunctional disorders such as tongue thrusting. Cayley et al<sup>23</sup> have demonstrated by electropalatographic assessment that

<sup>a</sup> Postdoctoral Fellow, Maxillofacial Orthognathics, Graduate School, Tokyo Medical and Dental University, Tokyo, Japan.

<sup>b</sup> Clinical Fellow, Maxillofacial Orthognathics, Graduate School, Tokyo Medical and Dental University, Tokyo, Japan.

<sup>c</sup> Lecturer, Maxillofacial Orthognathics, Graduate School, Tokyo Medical and Dental University, Tokyo, Japan.

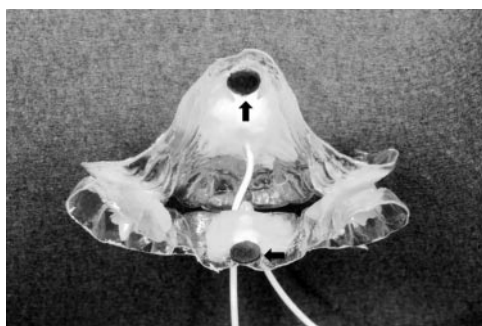
<sup>d</sup> Private practice, Ebina, Kanagawa, Japan.

<sup>e</sup> Professor Emeritus, Graduate School, Tokyo Medical and Dental University, Tokyo, Japan.

Corresponding author: Takashi Ono, DDS, PhD, Maxillofacial Orthognathics, Graduate School, Tokyo Medical and Dental University, 5-45 Yushima 1-chome, Bunkyo-ku, Tokyo 113-8549, Japan (e-mail: t-ono.mort@tmd.ac.jp).

Accepted: January 2004. Submitted: November 2003.

© 2004 by The EH Angle Education and Research Foundation, Inc.



**FIGURE 1.** Photograph of a custom-made intraoral appliance. Arrows indicate the location of the pressure sensor.

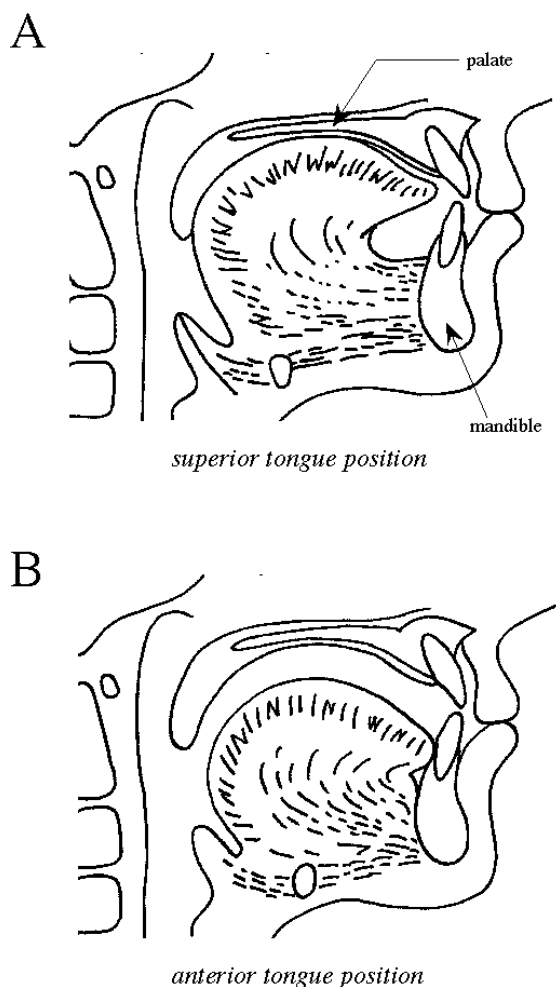
normal swallowing behavior resumes after MFT in subjects with anterior open bite. In addition, according to Zickefoose<sup>24</sup> the goal of MFT is to improve the static position of the tongue. To this end it has been suggested that the MFT therapist should train a patient with myofunctional disorders to lift the body of the tongue in order to learn the normal static position of the tongue.<sup>24</sup> However, it is still controversial which part of the tongue is important. Although Carlson et al<sup>20</sup> contended that the position of the tongue tip was most important for physiological function of the temporomandibular joint (TMJ), MFT therapists usually regard not only the tip but also the gross position of the tongue to be important during training.<sup>24</sup> Moreover, the pressure exerted by the body of the tongue, and not the tongue tip, during swallowing has been suggested to be important in subjects with normal oral function.<sup>17</sup>

Thus, the purpose of this study was to determine whether changes in the gross position of the tongue affected the EMG activities of masticatory muscles.

## MATERIALS AND METHODS

The subjects consisted of 10 skeletal Class I adults (eight males and two females) with a mean age of  $27.2 \pm 2.3$  (SD) years. Subjects with an ongoing respiratory infection or TMJ dysfunction or who were taking any medication that was known to affect muscle activity were excluded from the study. All the subjects had complete dentition except for the third molars. Each subject had a normal overjet and overbite. Informed consent was obtained from each subject before the study.

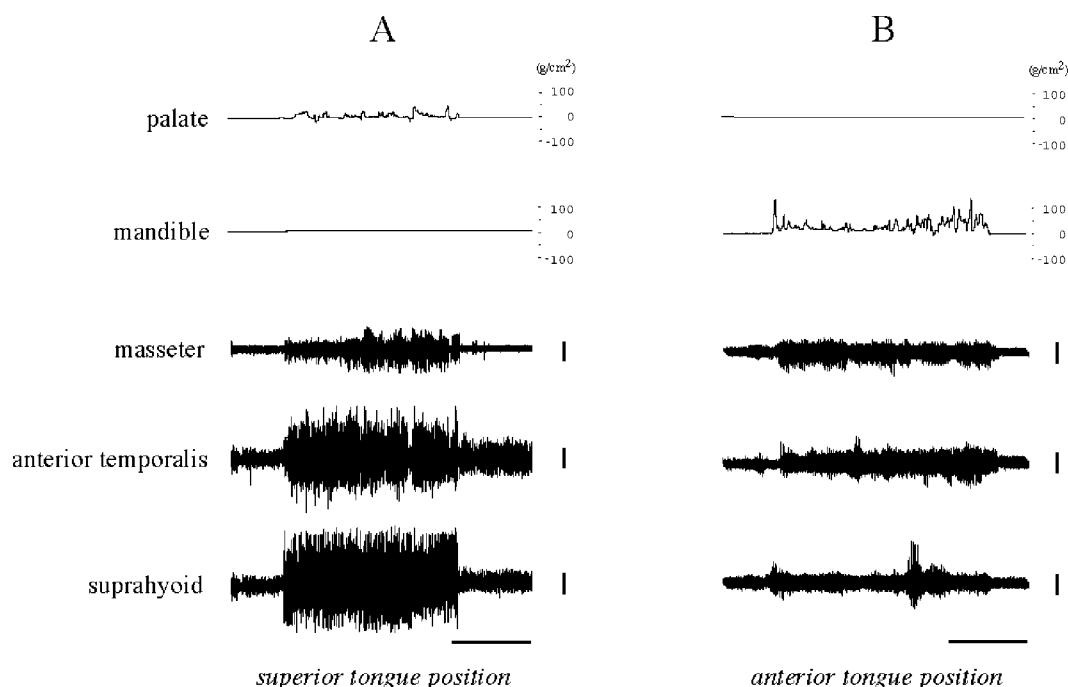
EMG activities of both the right masseter and the anterior temporalis muscles were recorded by a pair of surface electrodes (NT615U, Nippon Koden, Tokyo, Japan). Electrodes were placed midsagittally on the median skin of the submental region to record mass potentials of the EMG activity of suprahyoid muscles. A neutral electrode was placed on the right ear lobe. We embedded two pressure transducers (PS-A type, Kyowa Co, Tokyo, Japan), in the middle of the first maxillary molars of the midpalatal region and in the lingual flange of the mandibular central incisor region of a custom-made intraoral appliance (Figure 1), to monitor



**FIGURE 2.** Schematic illustrations of the (A) superior and anterior (B) tongue positions.

tongue position. The location of the pressure transducer was carefully standardized. The output of the transducers was affected by temperature at the rate of 0.1%/degree Celsius. The intraoral appliance was fabricated when the subject's mandible was in the resting position by connecting maxillary and mandibular parts that were made separately of acrylic resin.

The subject sat in a reclining chair in an upright position and remained awake with both eyes open, with the Frankfort plane maintained parallel to the floor throughout the recording session. We instructed the subject to assume three tongue positions: rest, superior, and anterior. The superior tongue position was defined as that in which the dorsal surface of the tongue body (and not the tip) touched the sensor located in the palate (Figure 2A). The anterior tongue position was defined as that in which the tongue tip touched the sensor located in the lingual surface of the mandibular incisor region (Figure 2B). Before recording, subjects were asked to confirm the location of the two pressure sensors and practice touching each sensor at approximately 25 g/cm<sup>2</sup> using visual feedback for five minutes. We



**FIGURE 3.** Typical simultaneous records of two pressure sensors and electromyographic (EMG) activities of the masseter, anterior temporalis, and suprahyoid muscles with the tongue in the (A) superior and (B) anterior positions in the same individual. Vertical bars represent 20  $\mu$ V for EMG activity, and horizontal bars represent 20 seconds.

also monitored the mass potentials of the EMG activity of the suprahyoid muscles, which was recorded by submental electrodes, using auditory feedback to confirm that the change in pressure was accompanied by EMG activity of the suprahyoid muscles.

After a 20-minute habituation period following insertion of the appliance, we recorded EMG activities of the masseter and anterior temporalis muscles in the resting mandibular position while the tongue position was changed randomly. We instructed subjects to maintain the tongue position for 30 seconds using visual feedback, and to assume the rest position between the superior and anterior positions, as they had practiced. EMG signals were amplified and band pass filtered at 30 Hz to 1 kHz. After the signals were passed through an A/D converter (MacLab/8S, AD Instruments, Castle Hill, Australia), they were stored in a personal computer (Macintosh Performa 5270, Apple Computer, Cupertino, Calif) for data analysis. For each subject, EMG records for 20 seconds were selected randomly for the three tongue positions. Friedman's test and Sheffe's *F*-test were used to compare EMG activities among the three different tongue positions. Statistical significance was established at  $P < .05$ . A power analysis<sup>25</sup> was used to confirm statistical power in this study after experimental sessions using free software (<http://www.psych.uni-duesseldorf.de/aap/projects/gpower/>).

## RESULTS

Figure 3 shows a typical simultaneous record of the tongue pressure and EMG activities with the tongue in the

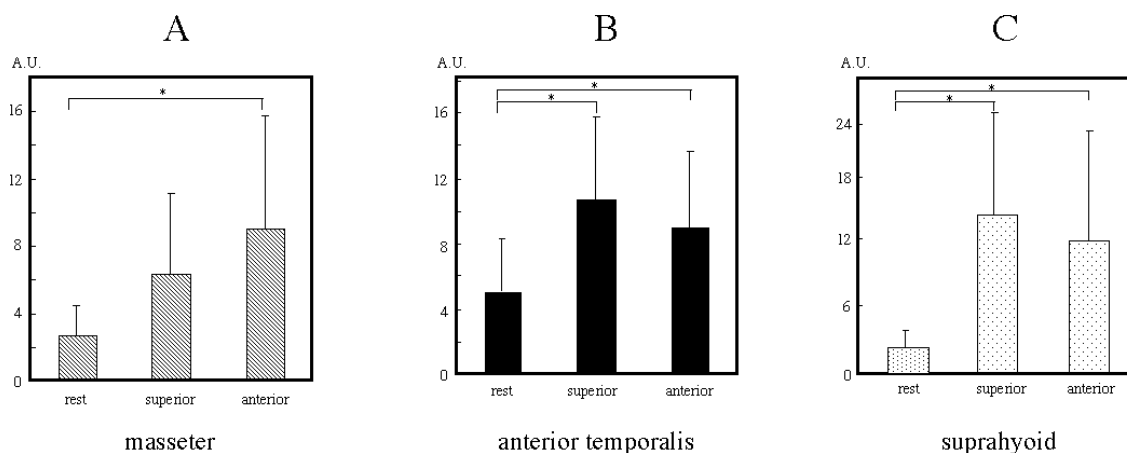
superior (Figure 3A) and anterior (Figure 3B) positions. The full-wave rectified, integrated EMG activity of the masseter, anterior temporalis, and suprahyoid muscles in the three tongue positions is summarized in Figure 4.

The masseter EMG activity with the tongue in the anterior position was significantly greater than that with the tongue in the rest position (Figure 4A). The EMG activity of the anterior temporalis muscle with the tongue in the anterior position was significantly greater than that with the tongue in the rest position (Figure 4B). The EMG activity of the anterior temporalis muscle with the tongue in the superior position was significantly greater than that with the tongue in the rest position. The EMG activity of the suprahyoid muscles with the tongue in both the anterior and the superior positions was significantly greater than that with the tongue in the rest position (Figure 4C).

The results of the power analysis are shown in Table 1. All values were greater than 0.85.

## DISCUSSION

In the current study we demonstrated that the EMG activity of masticatory muscles changed in association with a volitional change in tongue position. Unfortunately, we could not determine whether jaw position is reflexively controlled by the position of the tongue because of the use of the intraoral appliance, which restricts jaw movement. The overall effect of modulated EMG activities of jaw-closing and jaw-opening muscles on jaw position should be examined in a future study because it is possible that chron-



**FIGURE 4.** Comparisons of full-wave rectified and integrated electromyographic activities of the (A) masseter, (B) anterior temporalis, and (C) suprahyoid muscles with the tongue in the rest (*rest*), superior (*superior*), and anterior (*anterior*) positions. Vertical bars represent standard deviations. AU indicates arbitrary unit. \*  $P < .05$ .

**TABLE 1.** Power Analysis for the Masseter, Anterior Temporalis, and Suprahyoid Muscles

	Power ( $P = .05$ )
Masseter	.8591
Anterior temporalis	.8502
Suprahyoid	.9464

ic abnormal tongue position during childhood may affect masticatory muscle activity and secondarily induce abnormal craniofacial morphology in association with growth.

There was a significant difference in masseter EMG activity between the rest and anterior positions (Figure 4). Likewise, there was a significant difference in EMG activity of the anterior temporalis muscle between the rest and anterior positions. Moreover, a significant difference was also found in anterior temporalis muscle activity between the rest and superior positions. We speculate that this reflects a cooperative action of the tongue and masticatory muscles.

Hiyama et al<sup>26</sup> reported that genioglossus EMG activity was closely linked to that of the masticatory muscle during jaw-tapping movement, suggesting that there may be a link between the mutual central pattern generators for the tongue and masticatory muscles in the central nervous system. Ishiwata et al<sup>1,2</sup> demonstrated that group II afferents that originated from muscle spindles in the temporalis muscle in both animals<sup>1</sup> and humans<sup>2</sup> were mainly responsible for the reflexive fluctuation in the membrane potentials of hypoglossal motoneurons. They concluded that tongue position was reflexively controlled by jaw position.<sup>1,2</sup>

Unfortunately, there has been no report on whether the jaw position is reflexively controlled by tongue position. It seems likely that cooperative activity between the tongue and masticatory muscles is controlled not only by the jaw-tongue reflex<sup>1,2</sup> or an integrative central pattern generator but also by a reflexive pathway through which jaw position

is controlled by tongue position, perhaps by way of afferents from the extrinsic tongue muscle (eg, muscle spindles).<sup>27</sup> This is because we used feedback to carefully determine the tongue position and to confirm a change in tongue position, especially when the tongue was in the anterior position, with the activation of both intrinsic and extrinsic tongue muscles. Interestingly, there was no significant increase in masseter EMG activity when the tongue was in the superior position, whereas the EMG activity of the anterior temporalis muscle showed a significant increase when the tongue was in that position. The reason for this behavioral discrepancy between the masseter and anterior temporalis muscles is unknown, but the effect of superior positioning of the tongue may be different for the two jaw-closing muscles.

Tongue posture is an important factor in orthodontic treatment.<sup>10,17,28,29</sup> We previously reported changes in tongue posture with the respiratory mode and indicated that the tongue moved forward during oral respiration.<sup>30</sup> It has also been reported that the posterior part of the tongue body moved anteroinferiorly during oral respiration.<sup>31</sup> With regard to the interaction among malocclusion, tongue position, and respiratory mode, Benkert<sup>32</sup> suggested that the aim of oral MFT programs is to establish a new neuromuscular pattern and to correct abnormal functional and resting postures. Zickefoose<sup>24</sup> argued that the main purpose of MFT is to improve abnormal tongue posture not only during function but also in the resting condition. Furthermore, it has been emphasized that a patient with TMJ dysfunction should avoid lifting the tongue against the palate<sup>24,32</sup> because this may lead to pain in the masticatory muscle or TMJ region. We believe that our results support their contention. In the course of MFT the subject trains both the tongue and the masticatory muscle.<sup>21,22</sup> On the basis of the present findings, it appears that the position of the tongue body affects masticatory muscle activity. Thus, MFT, which



aims to train the tongue muscle, may also unintentionally strengthen masticatory muscles.

Carlson et al<sup>20</sup> showed that the EMG activity of the temporal muscle was significantly greater when the tongue tip was in contact with the palate than when it was in the rest position. They also showed that there were no significant differences in masseter EMG activity with a change in the position of the tongue tip.<sup>20</sup> Because the position of the tongue tip plays an important role in the treatment of TMJ dysfunction and orofacial muscle pain, they studied the effect of different positions of the tongue tip on the EMG activity of the masticatory muscle.<sup>20</sup> On the other hand, Chiba et al<sup>17</sup> focused on the gross position of the tongue with regard to the effect of tongue pressure on the transpalatal arch. They compared the tongue pressure recorded at the loop of the appliance during swallowing with reference to various anteroposterior positions and the distance from the palatal mucosa. A gradual increase in pressure was observed with an increase in the anteroposterior and vertical distances.<sup>17</sup> Taken together, these findings suggest that the dynamic position of the tongue should be controlled to maintain normal occlusion.

## ACKNOWLEDGMENTS

We are grateful to Dr Ryo Otsuka and Dr Kiyo Saito for their cooperation throughout the experiment. This work was supported by grants-in-aid for scientific research projects (10307052 and 09470467) from the Japanese Ministry of Education, Science, Culture and Sports.

## REFERENCES

- Ishiwata Y, Ono T, Kuroda T, Nakamura Y. Jaw-tongue reflex: afferents, central pathways, and synaptic potentials in hypoglossal motoneurons in the cat. *J Dent Res*. 2000;79:1626–1634.
- Ishiwata Y, Hiyama S, Igarashi K, Ono T, Kuroda T. Human jaw-tongue reflex as revealed by intraoral surface recording. *J Oral Rehabil*. 1997;24:857–862.
- Proffit WR. Muscle pressures and tooth position: North American whites and Australian aborigines. *Angle Orthod*. 1975;45:1–11.
- Proffit WR. Equilibrium theory revisited: factors influencing position of the teeth. *Angle Orthod*. 1978;48:175–186.
- Proffit WR. The etiology of orthodontic problems. In: Proffit WR, ed. *Contemporary Orthodontics*. 2nd ed. St. Louis, Mo: Mosby; 1993:128.
- Proffit WR, Ackerman JL. Diagnosis and treatment planning in orthodontics. In: Graber TM, Vanarsdall RL Jr, eds. *Orthodontics: Current Principles and Techniques*. 2nd ed. St. Louis, Mo: Mosby; 1994:3.
- Ackerman JL, Proffit WR. Soft tissue limitations in orthodontics: treatment planning guidelines. *Angle Orthod*. 1997;67:327–36.
- Pedrazzi ME. Treating the open bite. *J Gen Orthod*. 1997;8:5–16.
- Kuroda T, Ono T. Diagnosis and management of oral dysfunction. *World J Orthod*. 2000;1:125–133.
- Lowe AA, Johnston WD. Tongue and jaw muscle activity in response to mandibular rotations in a sample of normal and anterior open-bite subjects. *Am J Orthod*. 1979;76:565–576.
- Lowe AA. Correlations between orofacial muscle activity and craniofacial morphology in a sample of control and anterior open-bite subjects. *Am J Orthod*. 1980;78:89–98.
- Lowe AA, Takada K, Yamagata Y, Sakuda M. Dentoskeletal and tongue soft-tissue correlates: a cephalometric analysis of rest position. *Am J Orthod*. 1985;88:333–341.
- Fujiki T, Takano-Yamamoto T, Noguchi H, Yamashiro T, Guan G, Tanimoto KA. Cineradiographic study of deglutitive tongue movement and nasopharyngeal closure in patients with anterior open bite. *Angle Orthod*. 2000;70:284–289.
- Hanson ML, Barnard LW, Case JL. Tongue-thrust in preschool children. II. Dental occlusal patterns. *Am J Orthod*. 1970;57:15–22.
- Alexander S, Sudha P. Genioglossus muscle electrical activity and associated arch dimensional changes in simple tongue thrust swallow pattern. *J Clin Pediatr Dent*. 1997;21:213–222.
- Cheng CF, Peng CL, Chiou HY, Tsai CY. Dentofacial morphology and tongue function during swallowing. *Am J Orthod Dentofacial Orthop*. 2002;122:491–499.
- Chiba Y, Motoyoshi M, Namura S. Tongue pressure on loop of transpalatal arch during deglutition. *Am J Orthod Dentofacial Orthop*. 2003;123:29–34.
- Lowe AA, Santamaria JD, Fleetham JA, Price C. Facial morphology and obstructive sleep apnea. *Am J Orthod Dentofacial Orthop*. 1986;90:484–491.
- Pae E, Lowe AA, Fleetham JA. A thin-plate analysis of the face and tongue in obstructive sleep apnea. *Clin Oral Invest*. 1997;1:178–184.
- Carlson CR, Sherman JJ, Studts JL, Bertrand PM. The effects of tongue position on mandibular muscle activity. *J Orofac Pain*. 1997;11:291–297.
- Bacha SM, Rispoli CF. Myofunctional therapy: brief intervention. *Int J Orofac Myol*. 1999;25:37–47.
- Garretto AL. Orofacial myofunctional disorders related to malocclusion. *Int J Orofac Myol*. 2001;27:44–54.
- Cayley AS, Tindall AP, Sampson WJ, Butcher AR. Electropalatographic and cephalometric assessment of myofunctional therapy in open-bite subjects. *Aust Orthod J*. 2000;16:23–33.
- Zickefoose WE. *Techniques of Oral Myofunctional Therapy*. 1st ed. Sacramento, Calif: OMT Materials; 1989.
- Cohen J. *Statistical Power Analysis for Behavioral Science*. 2nd ed. New York, NY: Academic Press; 1988.
- Hiyama S, Iwamoto S, Ono T, Ishiwata Y, Kuroda T. Genioglossus muscle activity during rhythmic open-close jaw movements. *J Oral Rehabil*. 2000;27:664–670.
- Kubota K, Negishi T, Masegi T. Topological distribution of muscle spindles in the human tongue and its significance in proprioception. *Bull Tokyo Med Dent Univ*. 1975;22:235–242.
- Yashiro K, Takada K. Tongue muscle activity after orthodontic treatment of anterior open bite: a case report. *Am J Orthod Dentofacial Orthop*. 1999;115:660–666.
- Takahashi S, Ono T, Ishiwata Y, Kuroda T. Effect of wearing cervical headgear on tongue pressure. *J Orthod*. 2000;27:163–167.
- Takahashi S, Ono T, Ishiwata Y, Kuroda T. Effect of changes in the breathing mode and body position on tongue pressure with respiratory-related oscillations. *Am J Orthod Dentofacial Orthop*. 1999;115:239–246.
- Subtelny JD. *Early Orthodontic Treatment*. 1st ed. Chicago, Ill: Quintessence; 2000:188.
- Benkert KK. The effectiveness of orofacial myofunctional therapy in improving dental occlusion. *Int J Orofac Myol*. 1997;23:35–46.