

Evening Primrose Oil Effects on Osteoclasts during Tooth Movement

Suwimol Taweechaisupapong^a; Nitipavee Srisuk^b; Chawalit Nimitpornsuks^c; Thepharith Vattraphoudes^d; Charunee Rattanayatikul^e; Keith Godfrey^b

Abstract: This study was conducted to investigate the influence of supplemented evening primrose oil (EPO) on osteoclast expression during experimental tooth movement in rats. Forty-eight 10-week-old male Sprague-Dawley rats were divided into experimental and control groups. Animals in the experiment group were fed a 7.25 g/kg daily dose of EPO orally by gastric intubation for 20 days before orthodontic tooth movement. The animals in the control group received an equivalent volume of distilled water by the same method. On day 21, a 40-g mesial tipping force was applied to the maxillary right first molar of each rat. After loading, six animals in each group were sacrificed on days 0, 3, 7, and 14 with the appliance in situ. On day 3, the number of osteoclasts on the appliance side of the experimental group was significantly increased compared with the control group ($P < .05$). On day 7, the number of osteoclasts on the non-appliance side of the experimental group was significantly increased compared with the control group ($P < .05$). This study indicates that oral administration of EPO can increase the number of osteoclasts and may accelerate orthodontic tooth movement. (*Angle Orthod* 2005;75:356–361.)

Key Words: Evening primrose oil; Osteoclast

INTRODUCTION

Orthodontic tooth movement is accompanied by the appearance of osteoclasts and subsequent alveolar bone resorption. Bone remodeling, induced by orthodontic forces, has been suggested to be mediated by prostaglandins (PGs).^{1,2} The PGs, which are synthesized and secreted by local cells have been shown to stimulate the osteoclastic process of bone resorption.³ In vitro, a strong proresorptive effect, associated with increased osteoclast development predominates,⁴ and the important role of PGs in osteoclastogenesis has been confirmed after their reduced production in cyclooxygenase-2 knockout mice.⁵ Local injection of

prostaglandin E₁ (PGE₁) or prostaglandin E₂ (PGE₂) in humans,⁶ monkeys,¹ and rats⁷ has been reported to accelerate orthodontic tooth movement. Moreover, a significant increase in the degree and rate of orthodontic tooth movement was noted in guinea pigs after oral administration of a stable PGE₁ analog such as misoprostol.⁸

Recently, γ -linolenic acid (GLA)-containing oils (evening primrose oil [EPO], blackcurrant seed oil, and borage oil) have become increasingly popular and are being sold as encapsulated supplements. GLA, an 18-carbon polyunsaturated fatty acid of the (n-6) series, is a metabolite of linoleic acid (LA), from which dihomogamma-linolenic acid [DGLA, 20:3(n-6)] and PGE₁ are synthesized⁹ (Figure 1). When provided as a dietary supplement, GLA has been reported to improve clinical symptoms of several inflammatory disorders such as rheumatoid arthritis^{10,11} and atopic dermatitis^{12,13} through regulation of eicosanoid production from arachidonic acid [AA, 20:4(n-6)]. The usual explanation of dietary lipid effects is that GLA administration resulted in increased proportions of its first metabolite, DGLA, which is the immediate precursor of PGE₁. In rheumatoid arthritis patients, this effect is accompanied by a fall in PGE₂ and leukotriene B₄ (LTB₄) synthesis by stimulated monocytes.¹⁴ LTB₄ is a potent proinflammatory compound,¹⁵ so its decrease is an important contributory factor to the anti-inflammatory effect of DGLA.

Because PGE₁, which is a metabolite of GLA, has been reported to accelerate orthodontic tooth movement, it may

^a Associate Professor, Department of Oral Diagnosis, Faculty of Dentistry, Khon Kaen University, Khon Kaen, Thailand

^b Associate Professor, Department of Orthodontics, Faculty of Dentistry, Khon Kaen University, Khon Kaen, Thailand

^c Doctor, Department of Orthodontics, Faculty of Dentistry, Khon Kaen University, Khon Kaen, Thailand

^d Associate Professor, Department of Oral and Maxillofacial Surgery, Faculty of Dentistry, Khon Kaen University, Khon Kaen, Thailand

^e Assistant Professor, Department of Orthodontics, Faculty of Dentistry, Khon Kaen University, Khon Kaen, Thailand

Corresponding author: Suwimol Taweechaisupapong, DDS, PhD, Department of Oral Diagnosis, Faculty of Dentistry, Khon Kaen University, Khon Kaen 40002, Thailand (e-mail: suwi.taw@kku.ac.th)

Accepted: October 2004. Submitted: April 2004.

© 2005 by The EH Angle Education and Research Foundation, Inc.

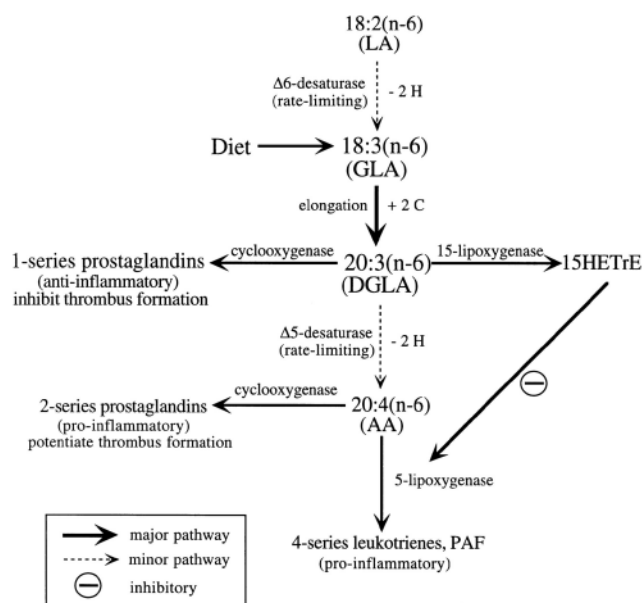


FIGURE 1. Metabolism of γ -linolenic acid (GLA). In many animal tissues and cells, linolenic acid (LA) is converted to arachidonic acid (AA) by an alternating sequence of $\Delta 6$ desaturation, chain elongation, and $\Delta 5$ desaturation. Here, hydrogen atoms are selectively removed to create new double bonds, and then two carbon atoms are added to lengthen the fatty acid chain. Dietary GLA bypasses the rate-limited $\Delta 6$ desaturation step and is quickly elongated to dihomo- γ -linolenic acid (DGLA) by elongase, with only a very limited amount being desaturated to AA by $\Delta 5$ desaturase. DGLA can be converted to prostaglandin E_1 (PGE_1) through the cyclooxygenase pathway or converted to 15-(*S*)-hydroxy-8,11,13-eicosatrienoic acid (15-HETrE) through the 15-lipoxygenase pathway. 15-HETrE is capable of inhibiting the formation of AA-derived 5-lipoxygenase (proinflammatory) metabolites (adapted from Fan and Chapkin⁹).

be assumed that regular EPO administration for orthodontic patients would affect bone remodeling and subsequent orthodontic tooth movement. However, direct histologic evidence of the effect of EPO supplementation on bone remodeling has never been reported. The aim of this study was therefore to determine the effect of oral administration of EPO on osteoclast number in the periodontal ligament on orthodontic tooth movement in rats.

MATERIALS AND METHODS

Animals and diets

A total of 48 male Sprague-Dawley rats, weighing 220–260 g, obtained from the central animal care unit of the Faculty of Medicine, Khon Kaen University, were used. All rats were 10 weeks old, kept in four-five/cage, and provided ground laboratory food and water ad libitum. After acclimatizing for seven days, the animals were divided into control and experimental groups (24 rats/group). Each animal in the experimental group received a 7.25 g/kg daily dose of EPO vegetable seed oil products (Barendrecht, Holland) orally for 20 days before orthodontic tooth movement by

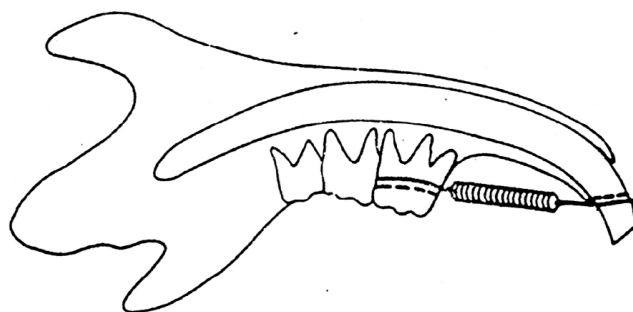


FIGURE 2. Schematic diagram of appliance used for experimental tooth movement, sagittal view.

gastric intubation. This concentration corresponded to previous recommended therapeutic dosage in the study of Al-Shabanah.¹⁶ The animals in the control group received equivalent volume of distilled water by the same method. The handling of animals was scrutinized by the Animal Ethics Research Committee, Faculty of Medicine, Khon Kaen University.

Experimental tooth movement

After 20 days of feeding, the right maxillary first molar of each rat was tipped mesially by the method described by Katzhendler and Steigman¹⁷ using a stainless steel, closed-coil spring (HI-T coil spring, Unitek Corp, Monrovia, Calif). Briefly, the spring was anchored at each end with 0.009-inch stainless steel ligature wires, and attached at the right maxillary first molar and the two maxillary incisors on the same side.

Anteriorly, the ligature was tied around the incisor and secured in a shallow groove cut into the labial and distal surfaces of the tooth close to the gingival margin. A second ligature was linked to the distal end of the spring, passed between the first and second molars, and ligated around the cervical area of the first molar (Figure 2). Rapid-cure resin was used to cover these wires to ensure maximum retention of the ligature wire and spring. The spring was activated one mm to deliver 40 g mesial tipping force and was not reactivated during the course of the experiment. The force level was measured using a Correx Dynamometer (Hahn-Kolb, Stuttgart, Germany). The contralateral maxillary first molar of each rat served as a nonappliance control. After the loading, six animals of each group (both the control and experimental group) were scheduled to be sacrificed at days 0, 3, 7, and 14, with the appliances in situ.

Histological procedures

All animals were sacrificed by cervical dislocation. The maxillary bones were dissected and fixed in 10% neutral buffered formalin for one week. The left and right maxillary first molars and their associated periodontium with supporting bone of each rat were decalcified in 14% ethylenediaminetetraacetic acid solution (pH 7.4) for two

TABLE 1. Osteoclast Numbers on Appliance Side of the Control and Experimental Groups at Various Time Intervals

Days	Numbers of Osteoclast/mm ²	
	Control Group	Experimental Group
0	0.22 ± 0.22	0.45 ± 0.36
3	15.53 ± 2.48	25.65 ± 5.75*
7	22.32 ± 4.71	16.79 ± 2.62*
14	5.39 ± 2.71	9.41 ± 4.18

* $P < .05$ compared with the control group.

weeks and embedded in paraffin. Five-micron sagittal serial sections were dewaxed and stained with hematoxylin and eosin. Periodontal tissues including interradicular bone at the furcation areas of the left and right maxillary first molars were examined using a light microscope.

The degree of bone resorption was estimated by counting the osteoclast numbers per furcation area of the left and right maxillary first molars on three sections for each animal with an eyepiece graticule, and the mean numbers of osteoclasts were obtained. All slides were coded and read without prior knowledge (blinded). The area of the field count was calculated, and osteoclast numbers were expressed per square millimeter. Every third section was included in the total count of osteoclast cells per specimen. The decision to count osteoclast cells in every third section was based on the assumption that the average osteoclast was no more than 15 μm in diameter. The elimination of two thirds of the sections would reduce the possibility of counting the same osteoclast cell twice.

Statistical analysis

For statistical comparison between osteoclast numbers of control and experimental groups, the Poisson test was used and a P value of $< .05$ was regarded significant.

RESULTS

After insertion of a stainless steel, closed-coil spring for three days, an increase in the number of osteoclasts was observed on the appliance side of both experimental and control groups (Table 1). The osteoclast number on the appliance side of the experimental group increased significantly by day 3 and had dropped significantly by day 7 compared with the control group ($P < .05$).

For the control group, the number of osteoclasts on the appliance side gradually increased to day 3 and on to day 7 and dropped by day 14. Several histologic changes on the appliance side of both experimental and control groups were noted, ie, on day 0 (20 hours after the loading), the width of the periodontal space was narrowed on the pressure side of both groups due to initial tooth movement (Figure 3). On day 3, both groups showed signs of hyaline degeneration of the periodontal membrane (Figure 4). On

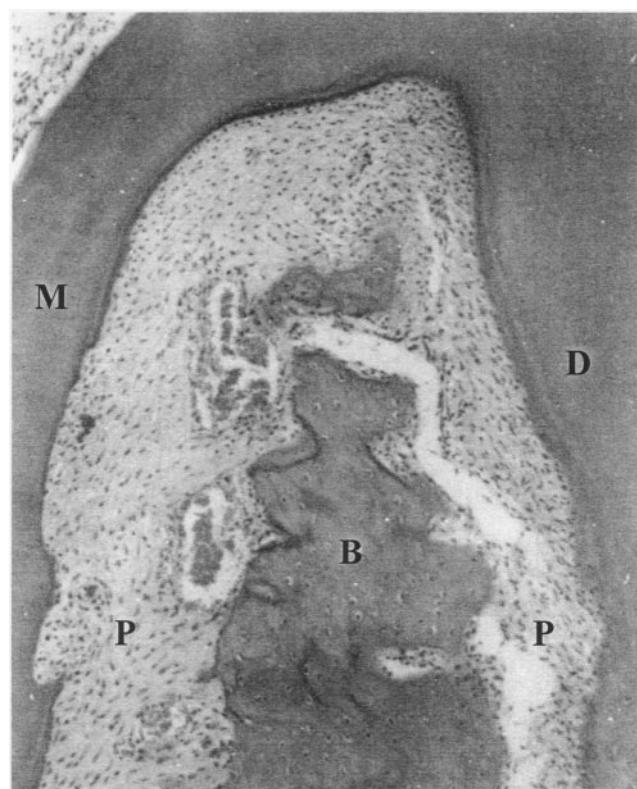


FIGURE 3. Histological changes of periodontal tissues in the experimental groups on day 0 after the application of force. The periodontal space was enlarged on the mesial side and was compressed on the distal side of the interradicular septum because of initial tooth movement. B indicates interradicular bone; D, distal root; M, mesial root; P, periodontal tissues; original magnification, 100 \times .

days 7 and 14, part of the hyalinized tissues and interradicular bone of both groups had been removed.

On the nonappliance side of both groups, normal histologic features were observed (Figure 5). A physiologic pattern of bone resorption was noted, although the osteoclast number in the experimental group increased significantly on days 7 and 14 compared with the control group ($P < .05$) (Table 2).

DISCUSSION

Orthodontic tooth movement is produced by a repeated process of bone resorption and deposition. Bone resorption caused by the application of an orthodontic force may be mediated through the local production and action of PGs. PGs have been shown to be induced in the periodontal tissues around teeth that are orthodontically moved.¹⁸ It has also been found that local injection of PGE_1 or PGE_2 results in a dose-dependent increase in the appearance of osteoclasts at the site of tooth movement in rats² and accelerates the rate of tooth movement in monkey models and humans.^{3,6} Lee,¹⁹ in 1990, observed that the number of osteoclasts in rats receiving systemic administration of PGE_1 was greater than in those receiving local administration.

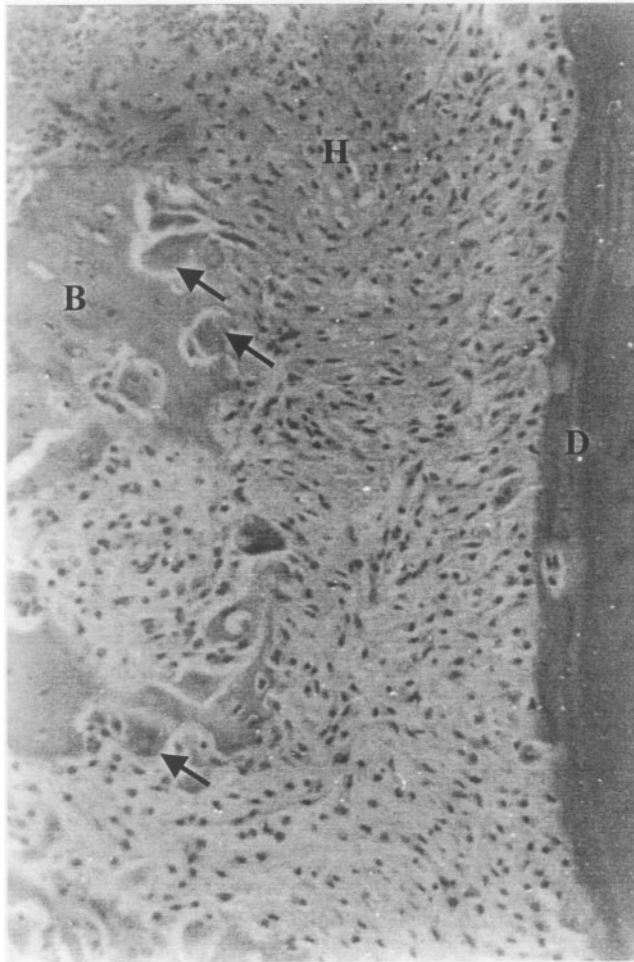


FIGURE 4. Histological changes of periodontal tissues on the pressure side of right maxillary first molar in the experimental group at day 3 after the application of force. Hyalinized degeneration of the periodontal ligament appeared, and bone resorption by numerous osteoclasts was observed. Arrows indicate osteoclast; B, interradicular bone; D, distal root; H, hyalinized tissue; original magnification, 100 \times .

Moreover, a significant increase in the degree and rate of orthodontic tooth movement was noted in guinea pigs after oral administration of a stable PGE_1 analog such as misoprostol.⁸

Several studies showed that the ingestion of GLA-enriched oils resulted in the accumulation of DGLA (Figure 1) in tissue phospholipids and triacylglycerols.^{9,20} DGLA can be further desaturated to AA by $\Delta 5$ desaturase. However, because of the limited activity of $\Delta 5$ desaturase in rodents and humans, only a small fraction of DGLA is converted to AA.^{11,20} These data indicated that in many cell types, DGLA, the elongase product of GLA, accumulated after GLA supplementation. Johnson et al²⁰ also observed that enrichment of membrane glycerolipids with DGLA occurs within the first 2–3 weeks of GLA supplementation and is not further enhanced with prolonged supplementation.

Although data from both animal studies and human trials showed that there are many fatty acid pools where GLA or its metabolites can reside after GLA consumption and can modulate inflammation, very little is known about their effects after the discontinuation of such supplements. Therefore, in this study, we decided to determine the effect of EPO on osteoclast number in rats that received EPO orally for 20 days before orthodontic tooth movement.

The results in this study demonstrated that oral administration of EPO, rich in GLA, appeared significantly effective in increasing the appearance of osteoclasts on both appliance and nonappliance sides of the experimental group on days 3 and 7, respectively, compared with the control group. The number of osteoclasts on the appliance side of the experimental group, which reached a peak on the third day and then gradually decreased, is consistent with the study of Lee¹⁹ who examined the effect of PGs administration on tooth movement.

Many experiments in orthodontics have indicated that the force applied to move the teeth causes local inflammation, increasing vascular permeability and stimulating cellular infiltration followed by lymphocytes, monocytes, and macrophages infiltrating into the inflammatory tissue where the PGs are released.^{1,2,18,19,21,22} PGs, in turn, activate adenylcyclase, which induces an increase in intracellular cyclic adenosine 5' monophosphate. This increase stimulates the release of PGs again. The secretion of PGs appears to be regulated by a feedback mechanism because PGs are believed to inhibit adenylcyclase activity above a certain concentration.²³ They are reported to promote bone resorption not only by increasing the number and the size of osteoclasts but also by stimulating the activation of existing osteoclasts.^{24–26} This study did not demonstrate the presence of mediators, although an increase in the number of osteoclasts was apparent.

Based on these data, we propose that the EPO supplement may induce more PGE_1 synthesis by shifting the pathway of LA metabolism to an elevation of plasma DGLA, and DGLA can be converted to PGE_1 by means of the cyclooxygenase pathway (Figure 1) because an increase in PGE_1 derived from DGLA was observed in rats fed with dietary oils containing GLA.^{27,28} An increase in PGE_1 synthesis led to an increase the presence of osteoclasts found on both appliance and nonappliance sides of the experimental group in this study. A marked increase in the number of osteoclasts on the appliance side of the experimental group, compared with the control group on the third day, could be due to the combined effects of mechanical stress and supplemented EPO that induce the production of PGE_1 .

While on the appliance side of the control group, the duration for reaching a peak of osteoclast numbers was longer (at day 7), and the number of osteoclasts was slightly lower than those of the experimental group; this may be due to the effects of mechanical stress alone. After reaching a peak, the number of osteoclasts on the appliance side of

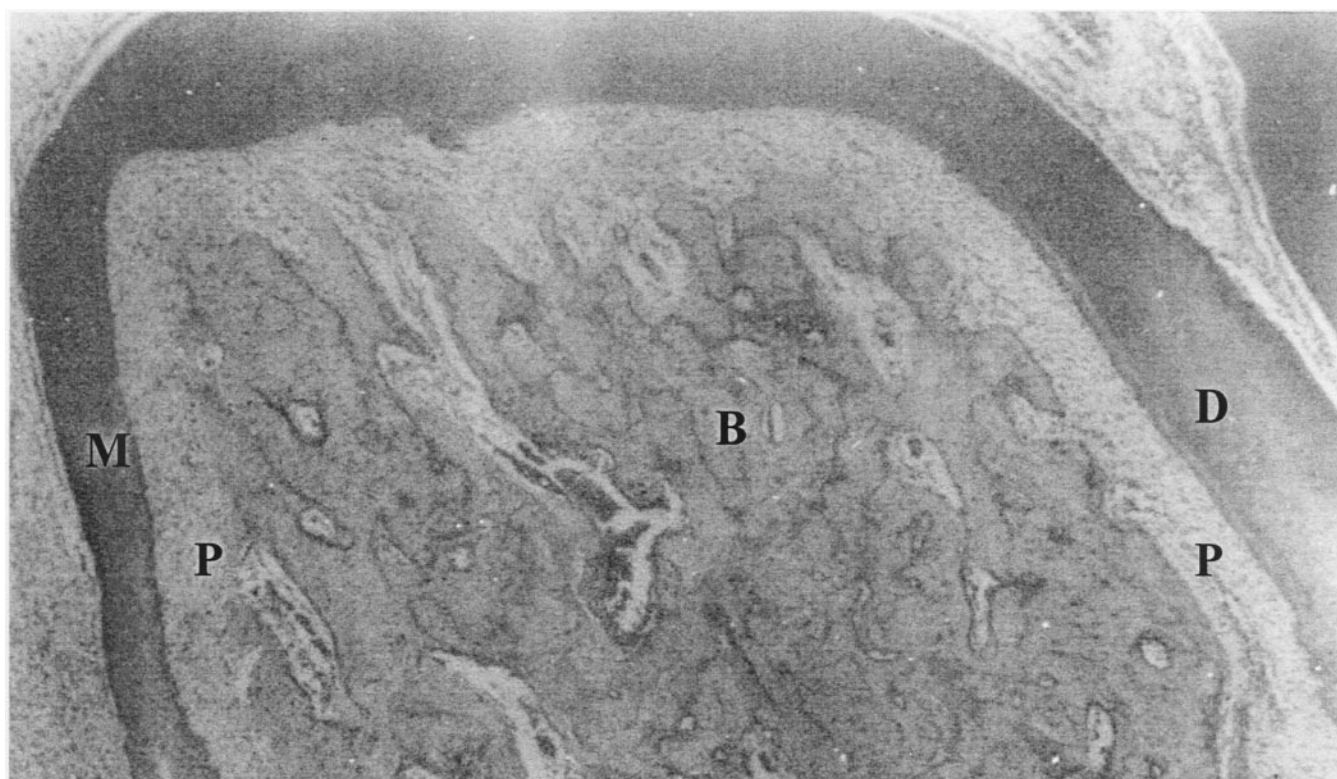


FIGURE 5. Normal histologic feature of periodontal tissues including interradicular bone at furcation area of left maxillary first molar (non-appliance side). B indicates interradicular bone; D, distal root; M, mesial root; P, periodontal tissues; original magnification, 40 \times .

TABLE 2. Osteoclast Numbers on Nonappliance Side of the Control and Experimental Groups at Various Time Intervals

Days	Numbers of Osteoclast/mm ²	
	Control Group	Experimental Group
0	0.20 \pm 0.20	0.29 \pm 0.20
3	0.22 \pm 0.16	0.16 \pm 0.12
7	0.39 \pm 0.20	2.17 \pm 0.84*
14	0.44 \pm 0.28	6.83 \pm 1.88*

* $P < .05$ compared with the control group.

both the experimental and control groups gradually decreased. This activity suggests a recovery of the tissue and the feedback mechanism of PGs.²³ In addition, PGE₁ may stimulate the production of other anti-inflammatory PGs, which could explain the rapid drop in the number of osteoclasts at day 7 in the experimental group. Surprisingly, in the nonappliance side of the experimental group, the number of osteoclasts was significantly increased on day 7 and 14 compared with the control group. The probable explanation may be that dietary GLA supplementation may affect systemic bone remodeling. However, the systemic effects of dietary n-6 polyunsaturated fatty acids on bone remodeling are not elucidated, and thus further studies are needed to clarify the issue.

At present, clinicians, patients, pharmaceutical and nutraceutical companies are all increasingly using natural

products for the treatment of clinical disorders. As this trend continues, it is important that these products be both safe and effective. Overall, little attention has been paid to the potentially adverse effects of dietary supplements and specifically, dietary fatty acid supplementation strategies.

As the nutraceutical industry continues to experience explosive growth, it will be increasingly important to understand the safety profiles of dietary supplements and avoid complications that arise from such supplements. The results reported here indicate that supplementation of diets with GLA-containing oil (EPO) could produce a rapid increase in the appearance of osteoclasts under the influence of orthodontic mechanical stress in rats. In a clinical application, we should be aware of the effect of this oil, especially in patients who use this supplement, because this oil may cause a rapid increase in osteoclast cells and might enhance initial orthodontic tooth movement. However, further studies are required to elucidate the effect of dietary EPO on bone remodeling in humans.

REFERENCES

1. Yamasaki K, Shibata Y, Fukuhara T. The effect of prostaglandins on experimental tooth movement in monkeys (*Macaca fuscata*). *J Dent Res.* 1982;61:1444-1446.
2. Yamasaki K, Miura F, Suda T. Prostaglandin as a mediator of bone resorption induced by experimental tooth movement in rats. *J Dent Res.* 1980;59:1635-1642.

3. Yamasaki K. The role of cyclic AMP, calcium, and prostaglandins in the induction of osteoclastic bone resorption associated with experimental tooth movement. *J Dent Res*. 1983;62:877-881.
4. Kaji H, Sugimoto T, Kanatani M, Fukase M, Kumegawa M, Chihara K. Prostaglandin E2 stimulates osteoclast-like cell formation and bone-resorbing activity via osteoblasts: role of cAMP-dependent protein kinase. *J Bone Miner Res*. 1996;11:62-71.
5. Okada Y, Lorenzo JA, Freeman AM, Tomita M, Morham SG, Raisz LG, Pilbeam CC. Prostaglandin G/H synthase-2 is required for maximal formation of osteoclast-like cells in culture. *J Clin Invest*. 2000;105:823-832.
6. Yamasaki K, Shibata Y, Imai S, Tani Y, Shibasaki Y, Fukuhara T. Clinical application of prostaglandin E1 (PGE1) upon orthodontic tooth movement. *Am J Orthod*. 1984;85:508-518.
7. Leiker BJ, Nanda RS, Currier GF, Howes RI, Sinha PK. The effects of exogenous prostaglandins on orthodontic tooth movement in rats. *Am J Orthod Dentofacial Orthop*. 1995;108:380-388.
8. Kehoe MJ, Cohen SM, Zarrinnia K, Cowan A. The effect of acetaminophen, ibuprofen, and misoprostol on prostaglandin E2 synthesis and the degree and rate of orthodontic tooth movement. *Angle Orthod*. 1996;66:339-349.
9. Fan YY, Chapkin RS. Importance of dietary gamma-linolenic acid in human health and nutrition. *J Nutr*. 1998;128:1411-1414.
10. Leventhal LJ, Boyce EG, Zurier RB. Treatment of rheumatoid arthritis with gamma-linolenic acid. *Ann Intern Med*. 1993;119:867-873.
11. Zurier RB, Rossetti RG, Jacobson EW, DeMarco DM, Liu NY, Temming JE, White BM, Laposata M. Gamma-linolenic acid treatment of rheumatoid arthritis. A randomized, placebo-controlled trial. *Arthritis Rheum*. 1996;39:1808-1817.
12. Andreassi M, Forleo P, Di Lorio A, Masci S, Abate G, Amerio P. Efficacy of gamma-linolenic acid in the treatment of patients with atopic dermatitis. *J Int Med Res*. 1997;25:266-274.
13. Horrobin DF. Fatty acid metabolism in health and disease: the role of delta-6-desaturase. *Am J Clin Nutr*. 1993;57:732S-736S.
14. Pullman-Moore S, Laposata M, Lem D, Holman RT, Leventhal LJ, DeMarco D, Zurier RB. Alteration of the cellular fatty acid profile and the production of eicosanoids in human monocytes by gamma-linolenic acid. *Arthritis Rheum*. 1990;33:1526-1533.
15. Devchand PR, Keller H, Peters JM, Vazquez M, Gonzalez FJ, Wahli W. The PPARalpha-leukotriene B4 pathway to inflammation control. *Nature*. 1996;384:39-43.
16. Al-Shabanah OA. Effect of evening primrose oil on gastric ulceration and secretion induced by various ulcerogenic and necrotizing agents in rats. *Food Chem Toxicol*. 1997;35:769-775.
17. Katzhendler E, Steigman S. Effect of repeated orthodontic treatment on the dental and periodontal tissues of the rat incisor. *Am J Orthod Dentofacial Orthop*. 1999;116:642-650.
18. Stanfeld J, Jones J, Laster L, Davidovitch Z. Biochemical aspects of orthodontic tooth movement. I. Cyclic nucleotide and prostaglandin concentrations in tissues surrounding orthodontically treated teeth *in vivo*. *Am J Orthod Dentofacial Orthop*. 1986;90:139-148.
19. Lee WC. Experimental study of the effect of prostaglandin administration on tooth movement—with particular emphasis on the relationship to the method of PGE1 administration. *Am J Orthod Dentofacial Orthop*. 1990;98:231-241.
20. Johnson MM, Swan DD, Surette ME, Stegner J, Chilton T, Fonteh AN, Chilton FH. Dietary supplementation with gamma-linolenic acid alters fatty acid content and eicosanoid production in healthy humans. *J Nutr*. 1997;127:1435-1444.
21. Chumbley AB, Tuncay OC. The effect of indomethacin (an aspirin-like drug) on the rate of orthodontic tooth movement. *Am J Orthod*. 1986;89:312-314.
22. Roberts WE, Goodwin WC Jr, Heiner SR. Cellular response to orthodontic force. *Dent Clin North Am*. 1981;25:3-17.
23. Horton EW. Hypotheses on physiological roles of prostaglandins. *Physiol Rev*. 1969;49:122-161.
24. Schelling SH, Wolfe HJ, Tashjian AH Jr. Role of the osteoclast in prostaglandin E2-stimulated bone resorption: a correlative morphometric and biochemical analysis. *Lab Invest*. 1980;42:290-295.
25. Santoro MG, Jaffe BM, Simmons DJ. Bone resorption *in vitro* and *in vivo* in PGE-treated mice. *Proc Soc Exp Biol Med*. 1977;156:373-377.
26. Galasko CS, Bennett A. Relationship of bone destruction in skeletal metastases to osteoclast activation and prostaglandins. *Nature*. 1976;263:508-510.
27. Raederstorff D, Moser U. Borage or primrose oil added to standardized diets are equivalent sources for gamma-linolenic acid in rats. *Lipids*. 1992;27:1018-1023.
28. Fan YY, Chapkin RS. Mouse peritoneal macrophage prostaglandin E1 synthesis is altered by dietary gamma-linolenic acid. *J Nutr*. 1992;122:1600-1606.