

Anchorage Provided During Intra-arch Distal Molar Movement: A Comparison Between the Nance Appliance and a Fixed Frontal Bite Plane

Lars Bondemark^a; Johan Thornéus^b

Abstract: The aim of this retrospective study was to evaluate and compare the anchorage provided with the Nance appliance (NA) and the fixed frontal bite plane (FBP) during intra-arch distal molar movement. After a sample size calculation, 20 patients were recruited and randomly selected for each group from patients who fulfilled the following criteria: use of an intra-arch Ni-Ti coil appliance with either NA or FBP to provide anchorage during a six-month molar distalization period, no orthodontic treatment before molar distalization, and first and second maxillary molars in occlusion. The outcome measures assessed were anchorage loss, ie, anterior movement of maxillary central incisors, distal movement of maxillary molars, and bite opening effect. The mean age in the NA group was 14.7 years (SD 1.09) and in the FBP group 15.0 years (SD 0.99). The data revealed that the maxillary central incisors moved anteriorly 1.4 mm in the NA group and 1.9 mm in the FBP group. The difference in anchorage loss was not significant. The mean amount of molar distalization within the maxilla was 1.7 mm in the NA group and 1.8 mm in the FBP group. In both groups, the overbite was significantly reduced and the overbite was decreased significantly more in the FBP group. Because neither the NA nor FBP provided stable anchorage, a second treatment phase is recommended to reverse the anchorage loss after distal molar movement. If molar distalization is planned in deep bite cases, the FBP is the anchorage system of choice. (*Angle Orthod* 2005; 75:437–443.)

Key Words: Anchorage; Distal molar movement; Intraoral appliance

INTRODUCTION

A common strategy to correct a Class II dental malocclusion or to create space in the maxillary arch by a non-extraction protocol is to move the maxillary molars distally in the initial stages of treatment, and thereby gain space to convert the Class II molar relationship to a Class I. The molars are then held in place whereas the premolars, canines and incisors are retracted.

Traditionally, extraoral traction and extraoral traction in combination with removable appliances have been used for distal molar movement.^{1–3} However, these treatments are highly dependent on patient cooperation and, therefore, various intra-arch devices have been introduced, which have

almost eliminated reliance on the patient. These techniques include Wilson arches,^{4,5} Hilgers pendulum appliances,^{6–8} repelling magnets, and superelastic coils.^{9–16} Most of the intra-arch devices use palatal anchorage such as a Nance appliance (NA), but a fixed acrylic frontal bite plane (FBP) can also be used.¹⁷ Despite the anchorage arrangement, it has been reported that anchorage loss still occurs, resulting in increased overjet up to two mm during the distal molar movement.^{5,7,8,10,13,17}

Because loss of orthodontic anchorage may lead to prolonged treatment time and less predictable treatment result, it is of great concern to analyze different anchorage systems. In the literature, few articles exist comparing the ability of different anchorage systems to resist tooth movements, and no study has yet compared different anchorage approaches during intra-arch distal molar movement. Therefore, the aim of this retrospective study was to analyze and compare the anchorage provided with NA and FBP during intra-arch distal molar movement.

MATERIALS AND METHODS

On the basis of an alpha significance level of 0.05 and a beta of 0.1, the sample size for each group was calculated

^a Head and Associate Professor, Department of Orthodontics, Faculty of Odontology, Malmö University, Malmö, Sweden.

^b Consultant, Specialist in Orthodontics, Orthodontic Clinic, National Health Service, Blekinge County Council, Karlskrona, Sweden.

Corresponding author: Lars Bondemark, DDS, Odont Dr, Department of Orthodontics, Faculty of Odontology, Malmö University, Carl Gustavs väg 34, SE-20506 Malmö, Sweden
(e-mail: lars.bondemark@od.mah.se)

Accepted: November 2004. Submitted: October 2004.

© 2005 by The EH Angle Education and Research Foundation, Inc.

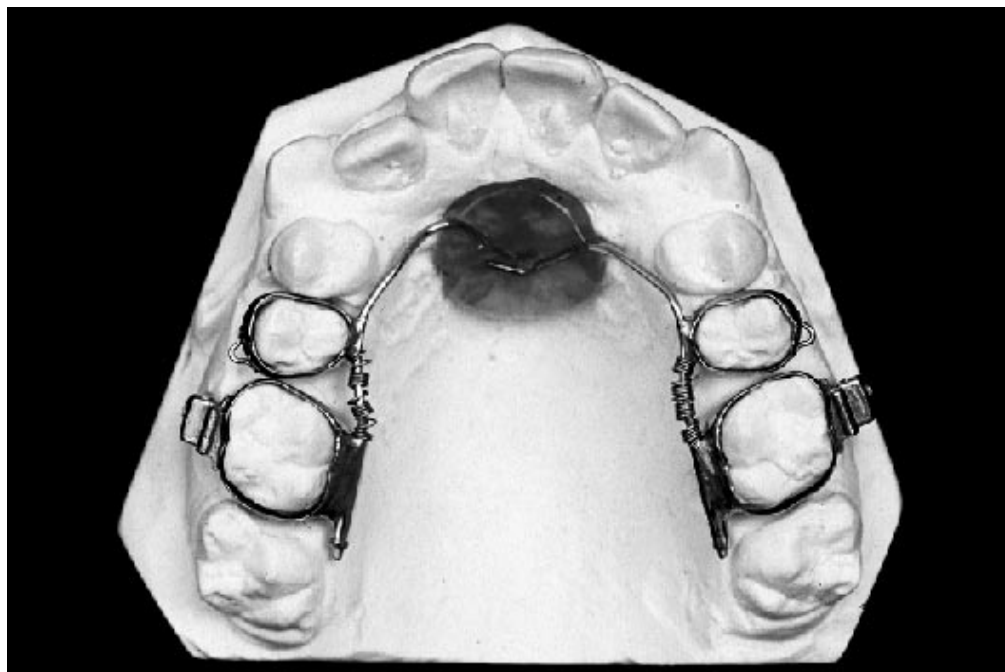


FIGURE 1. Occlusal view of the intra-arch Ni-Ti coil appliance provided with a Nance button as anchorage.

to achieve 90% power to detect a clinically meaningful difference of 1.5 mm (± 1.0 mm) in anchorage loss between the NA and the FBP groups. The sample size calculation showed that 10 patients in each group were needed, and to increase the power even more, it was determined to select 20 patients for each group.

The patients were from one Orthodontic Clinic at National Health Service, County Council Skane, Hassleholm, Sweden, and 20 patients were randomly selected (through a random table) for each group from among 87 patients who fulfilled the following criteria: (1) used an intra-arch Ni-Ti coil appliance with either NA or FBP to provide anchorage during a six-month molar distalization period; (2) a nonextraction treatment plan; (3) no orthodontic treatment before molar distalization; (4) both first and second maxillary molars in occlusion; as well as those cases with mild (2–3 mm) Class II molar relation with the aim to achieve Class I molar relation or cases with normal occlusion with the aim to increase the arch perimeter (or both).

One experienced orthodontic specialist had treated all the patients. In the NA group, there were six boys and 14 girls (mean age of 14.7 years, SD 1.09) and in the FBP group five boys and 15 girls (mean age of 15.0 years, SD 0.99). In the NA group, there were 17 mild Class II and three Class I, whereas in the FBP group, there were 18 mild Class II and two Class I. In both groups, maxillary third molars were present in the alveolar bone on both the right and left sides in 16 of the 20 patients.

The main outcome measures to be assessed on cephalograms were:

- Anchorage loss, ie, anterior movement and proclination of maxillary central incisors.
- Distal movement and distal tipping of maxillary first permanent molars.

In addition, the bite opening effect and the skeletal sagittal position changes of the maxilla and mandible also were measured.

Design of the intra-arch appliance provided with a Nance button as anchorage

The lingual intra-arch Ni-Ti coil appliance is shown in Figure 1. The appliance consisted of bands placed bilaterally on the maxillary first molars and second premolars. A tube, 1.1 mm in diameter and approximately 10 mm in length, was soldered on the lingual side of the molar band. A 0.9-mm lingual archwire that united a Nance acrylic button was soldered on to the lingual side to the second premolar band. The lingual archwire also provided two distal pistons that passed bilaterally through the palatal tubes of the maxillary molar bands. The tubes and pistons were required to be parallel in both the occlusal and sagittal views. A Ni-Ti coil (GAC Int Inc, Central Islip, NY), 0.3 mm in diameter, with a lumen of 1.1 mm, and cut to 10 to 14 mm in length, was inserted on the distal piston and compressed to half its length, when the molar band with its lingual tube was adapted to the distal piston of the lingual archwire. When the coil was compressed, two forces were produced, one distally directed to move the molars distally and a reciprocal mesially directed force against which the Nance

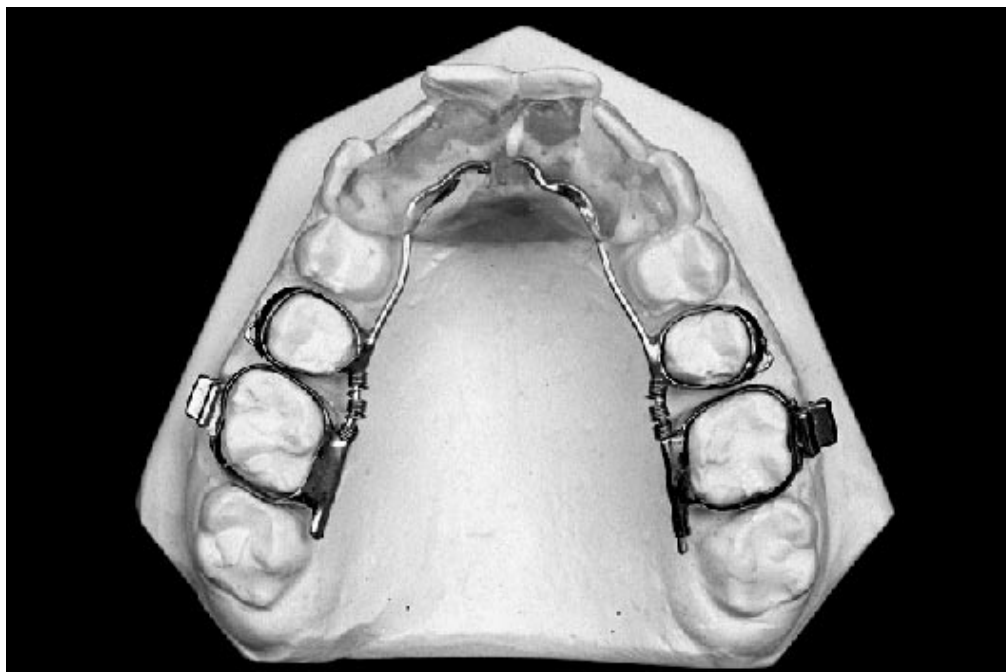

FIGURE 2. Occlusal view of the intra-arch Ni-Ti coil appliance provided with a fixed acrylic frontal bite plane as anchorage. Note that the bite plane was extended to the palatal vault to improve anchorage.

button provided anchorage. All appliances in the NA group were made by one orthodontic technician and efforts had been made to construct the Nance button with equal size and dimension for all patients.

Design of the intra-arch appliance provided with a fixed acrylic frontal bite plane as anchorage

The design was similar to the intra-arch appliance described above, but a fixed acrylic frontal bite plane (Figure 2) replaced the Nance button. Compared with an ordinary frontal bite plane, the bite plane in this study was extended to the palatal vault to increase or improve the anchorage against the reciprocal mesially directed force. Also in the FBP group, all appliances were made by one orthodontic technician and efforts had been made to construct the frontal bite planes with equal size and dimension for all patients.

Data collection

Lateral head radiographs in centric occlusion were obtained at the start and after completion of the molar distalization. The measuring points, reference lines, and measurements used were based on those defined and described by Björk¹⁸ and Pancherz.¹⁹ Dental and skeletal changes as well as dental changes within the maxilla and mandible were obtained by the Pancherz analysis.¹⁹

Measurements were made to the nearest 0.5 mm or 0.5°. Images of bilateral structures were bisected. No correction was made for linear enlargement (10%). Changes in the

different measuring points during the treatment were calculated as the difference in the after-minus-before position.

The cephalograms were scored and coded by an independent person, and the examiner conducting the measurement analysis of the cephalograms was unaware of the group to which the patient had been allocated.

Statistical analysis

The arithmetic mean and standard deviation (SD) were calculated for each variable. Differences in means within samples/groups were tested by paired *t*-tests and between samples and groups by unpaired *t*-tests after *F*-tests for equal and unequal variances. Differences with probabilities of less than 5% ($P < .05$) were considered statistically significant.

Error of the method

Ten randomly selected cephalograms were traced on two separate occasions. No significant mean differences between the two series of records were found by using paired *t*-tests. The method error²⁰ did not exceed 0.7 mm and 0.9° for the different measurements used except the variables, inclination of lower incisors and first maxillary molar inclination, where the error was 1.5° and 1.4°, respectively.

RESULTS

No significant difference in treatment effects was found between girls and boys, and consequently, the data for girls and boys were pooled and analyzed together.

Nance appliance group

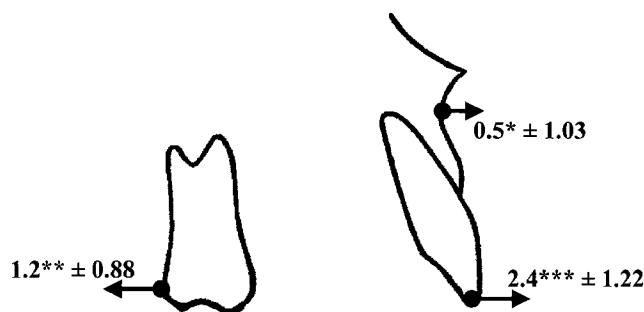

FIGURE 3. The Nance appliance group (N = 20). Skeletal and dental mean changes (in mm) and standard deviations contributing to alterations in sagittal movements of incisors and molars in the maxilla. The average forward movement of the incisors was 1.9 mm (SD 1.19) and the mean distal molar movement within the maxilla was 1.7 mm (SD 1.20). * $P < .05$; ** $P < .01$; *** $P < .001$.

Frontal bite plane group

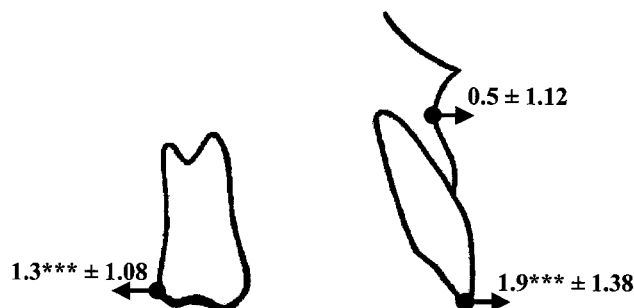

FIGURE 4. The frontal bite plane group (N = 20). Skeletal and dental mean changes (in mm) and standard deviations contributing to alterations in sagittal movements of incisors and molars in the maxilla. The average forward movement of the incisors was 1.4 mm (SD 1.16) and the mean distal molar movement within the maxilla was 1.8 mm (SD 1.02). * $P < .05$; ** $P < .01$; *** $P < .001$.

In the NA group, the anchorage loss, ie, the average anterior movement within the maxilla of maxillary incisors and proclination of the incisors, was 1.9 mm and 3.3° , respectively. The corresponding anchorage loss in the FBP group was 1.4 mm and 4.0° (Figures 3 and 4; Table 1). The difference in anchorage loss between the groups was not significant (Table 1). The mean overjet was increased 1.2 mm in the NA and 0.4 mm in the FBP group. Significantly more proclination and anterior movement of the mandibular incisors was the reason for the smaller increase in overjet in the FBP group (Table 1).

In both groups, the overbite was significantly reduced, and the overbite was decreased significantly more in the FBP group, 2.4 vs 1.1 mm (Table 1). The decrease in overbite was mainly because of overeruption of mandibular and maxillary molars (Table 1).

The mandibular plane angle tilted posteriorly in both groups as well as the maxillary plane angle in the NA group (Table 1).

The mean amount of distal molar movement within the maxilla was almost equal in both groups, 1.7 mm (SD 1.20) in the NA group vs 1.8 mm (SD 1.02) in the FBP group (Figures 3 and 4; Table 1). The amount of average distal molar tipping was small and with no significant difference between the groups (Table 1).

The ratio of molar vs incisor movement within the maxilla was 1.7/1.9 (0.89) for the NA group and 1.8/1.4 (1.28) for the FBP group, indicating more effective distal molar movement in the FBP group, although no statistically significant difference was found between the groups. From Table 1, it can also be determined that the molar relation in both groups was corrected not only by distal molar movement of maxillary molars but also by mesial movement of mandibular molars.

During the molar distalization, small sagittal skeletal changes occurred in the maxilla and mandible (Table 1).

DISCUSSION

The most significant findings of this study were that the anchorage systems did not provide stable anchorage during intra-arch molar distalization and no difference in provided anchorage was found between the NA and the FBP. The anchorage loss found in the two groups in this study was at an equal level as reported in previous case series, when first and second maxillary molars during six months were simultaneously moved distally.^{5,7,8,10,13,17}

In most instances, the anchorage loss, ie, forward movement of the incisors, can be corrected with modest intervention. It has been shown that forward movement of the maxillary incisors associated with distal molar movement was totally reversed and eliminated by subsequent multi-bracket appliance and intermaxillary Class II elastics.²¹ However, in a case with retroclined maxillary incisors, for example a Class II division 2 occlusion, the reciprocal effect of forces can be used for proclination of the incisors. On the other hand, if stable or absolute anchorage is desired, anchorage systems using onplants or osseointegrated mini screws conceivably can be used. These systems have shown promising results in respect to achieving stable anchorage during the molar distalization procedure.^{22,23}

Both appliances used in this study were made by one laboratory technician who had instructions to design and construct the Nance button as well as the frontal bite plane with equal size and dimension for all patients in the NA group and FBP group, respectively. In this respect, the provided anchorage was equal for all patients in each group. Of course, it is relevant that small differences in size and design could exist in few patients because of difference in palatal anatomy; however, this was not deemed to be of decisive importance for the outcome of the anchorage.

TABLE 1. Changes in Cephalometric Variables Within and Between the Two Groups After Distal Movement of Maxillary Molars. Changes Were Calculated as the Difference After-Minus-Before Position^a

	NA (N = 20)		FBP (N = 20)		Group Difference
	Mean	SD	Mean	SD	P value
Skeletal sagittal variables (mm)					
Maxillary base, A-OLp	0.5*	1.03	0.5	1.12	NS
Mandibular base, Pg-OLp	0.7**	0.92	-0.2	1.90	NS
Skeletal + dental sagittal variables (mm)					
Overjet	1.2**	1.66	0.4	1.30	NS
Maxillary incisor position, Is-OLp	2.4***	1.22	1.9***	1.38	NS
Mandibular incisor position, li-OLp	1.2**	1.42	1.6***	1.64	NS
Maxillary molar position, Ms-OLp	-1.2***	0.88	-1.3***	1.08	NS
Mandibular molar position, Mi-OLp	0.6**	0.91	0.4	1.76	NS
Dental sagittal variables within the maxilla and mandible					
Maxillary incisor, Is-OLp (d) minus A-OLp (d)	1.9***	1.19	1.4***	1.16	NS
Mandibular incisor, li-OLp (d) minus Pg-OLp (d)	0.5	1.32	1.7***	1.75	*
Maxillary molar, Ms-OLp (d) minus A-OLp (d)	-1.7***	1.20	-1.8***	1.02	NS
Mandibular molar, Mi-OLp (d) minus Pg-OLp	-0.1	0.64	0.6**	0.89	**
Sagittal variables (°)					
Maxillary incisor inclination, ILs/NSL	3.3***	3.62	4.0***	2.73	NS
Mandibular incisor inclination, ILi/ML	-0.2	4.11	3.7***	3.56	**
Maxillary first molar inclination, M1s/NSL	-4.0**	5.39	-1.9	4.98	NS
Vertical variables (mm)					
Overbite	-1.1***	1.18	-2.4***	1.18	**
Maxillary incisor position, Is-NL	0.2	0.77	-0.5	1.12	*
Maxillary molar position, Ms-NL	0.8**	1.25	1.0***	0.66	NS
Mandibular incisor position, li-ML	1.2***	0.71	0.6	1.90	NS
Mandibular molar position, Mi-ML	0.3	1.55	1.4***	1.12	*
Vertical variables (°)					
Mandibular inclination, NSL/ML	0.6*	1.05	0.6*	0.96	NS
Maxillary inclination, NSL/NL	0.9**	1.14	-0.2	1.21	*
Occlusal plane inclination, OL/NSL	-1.6***	1.42	-2.2***	1.61	NS

^a NA indicates Nance appliance; FBP, frontal bite plane; and NS, not significant.

* $P < .05$; ** $P < .01$; *** $P < .001$.

An advantage with the FBP is that a pronounced bite opening effect can be combined with the molar distalization procedure. The bite opening achieved was primarily a result of dental changes. After the FBP was inserted, maxillary and mandibular molar heights increased. Similar findings of overeruption of the lateral segments in bite plane therapy have been reported earlier.²⁴ Moreover, the frontal bite plane made an inclined plane for the mandibular incisors that resulted in an anterior tipping of the mandibular incisors with a subsequent mesial drift of mandibular premolars and molars. This was the main explanation for smaller increases in overjet found in the FBP group compared with the NA group.

Furthermore, because only the incisors and cuspids were in occlusion in the mandibular arch in the FBP group, lateral occlusal forces were eliminated. This means that the maxillary molars could move distally independent of these forces. Therefore, it is reasonable to claim that there was a possibility for the molars in the FBP group to move distally more easily and conceivably to a greater extent than in the NA group, but this was not found in this study. However,

if the ratio of molar vs incisor movement within the maxilla is calculated, the distal molar movement seems to be a little bit more effective in the FBP group although no statistically significant difference was found between the groups.

Overall, the amount of distal molar movement was at the same level as could be expected when first and second maxillary molars simultaneously are moved distally.²⁵ It is also relevant to consider that correction of the molar relationship occurs not only by distal movement of the maxillary molars but also by spontaneous mesial movement of the mandibular molars and forward growth of the mandible. It can also be pointed out that 16 of the 20 patients in each group had maxillary third molars present in the alveolar bone, and this was regarded to be of minor importance in the outcome of the distal molar movement and anchorage loss.

The Pancherz method was used as the superimposition method and also to detect dental and skeletal changes as well as dental changes within the maxilla and mandible. This method is well known and has been proven to be reliable, especially for assessment of patients in groups.²⁶

In any scientific study, it is important that the power is

high. The sample size calculation revealed that a sample size of 10 patients per group was sufficient. Because 20 patients per group were analyzed in this study, it can be stressed that the power was sufficiently high to reveal reliable results. When the power was calculated, a clinical meaningful difference in anchorage loss was set at 1.5 mm. It can be claimed that this difference is rather high, but the intention with the study was to carry out an investigation that primarily revealed clinical significance, not a statistical significance only. In this study, a difference of 0.5 mm (SD 0.59) in anchorage loss was found. This difference was of no clinical or statistical significance. Hypothetically, if a post hoc power analysis is made, the result will be that 29 patients are needed for each group. However and importantly, the difference of 0.5 mm is still of no clinical significance.

Because the patients in each group were selected randomly among patients who fulfilled the preset criteria, characterized for instance as only successful treatments, selection bias was avoided in the study. Furthermore, the reliability and the methodological soundness were increased even more because the measurement analysis of the cephalograms was performed in a blinded manner, ie, the examiner was unaware of the anchorage system that had been used. Thus, the risk of measurements being affected by the researcher was low.

On the other hand, from an evidence-based view it can be argued that the scientific evidence drawn from results or conclusions of a retrospective study can only be classified or ranked as low. However, even if a randomized controlled trial is the gold standard and shall rule, it has been claimed that sound methodology in well-designed prospective or retrospective studies shall not be ignored when assessing scientific literature.²⁷

CONCLUSIONS

- The NA and FBP did not provide stable anchorage during the molar distalization, instead an anchorage loss could be found, ie, anterior movement of the maxillary incisors, of 1.9 and 1.4 mm, respectively;
- The difference in anchorage loss between the NA and the FBP was not significant;
- The mean amount of distal molar movement within the maxilla was almost equal in both groups, 1.7 mm in the NA group vs 1.8 mm in the FBP group;
- In both groups, the overbite was significantly reduced, and the overbite was decreased significantly more in the FBP group;
- Because none of the NA and FBP provided stable anchorage, a second treatment phase with multibracket technique and Class II elastics is recommended to reverse the anchorage loss after distal molar movement;
- If molar distalization is planned in deep bite cases, the FBP is the anchorage system of choice.

REFERENCES

1. Graber TM. Extraoral force—facts and fallacies. *Am J Orthod.* 1955;41:490–505.
2. Wieslander L. Early or late cervical traction therapy of Class II malocclusion in the mixed dentition. *Am J Orthod.* 1975;67:432–439.
3. Cetlin NM, TenHoeve A. Nonextraction treatment. *J Clin Orthod.* 1983;17:396–413.
4. Wilson RC. Modular orthodontic systems. Part 1. *J Clin Orthod.* 1978;12:259–278.
5. Muse DS, Fillman MJ, Emmerson WJ, Mitchell RD. Molar and incisor changes with Wilson rapid molar distalization. *Am J Orthod Dentofacial Orthop.* 1993;104:556–565.
6. Hilgers JJ. The pendulum appliance for Class II non-compliance therapy. *J Clin Orthod.* 1992;26:706–714.
7. Gosh J, Nanda RS. Evaluation of an intraoral maxillary molar distalization technique. *Am J Orthod Dentofacial Orthop.* 1996;110:639–646.
8. Byloff FK, Darendeliler MA. Distal molar movement using the pendulum appliance. Part 1: clinical and radiological evaluation. *Angle Orthod.* 1997;67:249–260.
9. Jones R, White J. Rapid Class II molar correction with an open coil jig. *J Clin Orthod.* 1992;26:661–664.
10. Bondemark L, Kurol J. Distalization of maxillary first and second molars simultaneously with repelling magnets. *Eur J Orthod.* 1992;14:264–272.
11. Carano A, Testa M. The distal jet for upper molar distalization. *J Clin Orthod.* 1996;30:374–380.
12. Gianelly AA. Distal movement of the maxillary molars. *Am J Orthod Dentofacial Orthop.* 1998;114:66–72.
13. Gulati S, Kharbanda OP, Parkash H. Dental and skeletal changes after intraoral molar distalization with sectional jig assembly. *Am J Orthod Dentofacial Orthop.* 1998;114:319–327.
14. Bondemark L. A comparative analysis of distal maxillary molar movement produced by a new lingual intra-arch Ni-Ti coil appliance and a magnetic appliance. *Eur J Orthod.* 2000;22:683–695.
15. Papadopoulos MA, Mavropoulos A, Karamouzos A. Cephalometric changes following simultaneous first and second maxillary molar distalization using a non-compliance intraoral appliance. *J Orofac Orthop.* 2004;65:123–136.
16. Fortini A, Lupoli M, Giuntoli F, Franchi L. Dentoskeletal effects induced by rapid molar distalization with the first class appliance. *Am J Orthod Dentofacial Orthop.* 2004;125:697–705.
17. Bondemark L, Kurol J, Bernhold M. Repelling magnets versus superelastic nickel-titanium coils in simultaneous distal movement of maxillary first and second molars. *Angle Orthod.* 1994;64:189–198.
18. Björk A. The relationship of the jaws to the cranium. In: Lundström A, ed. *Introduction to Orthodontics*. New York, NY: McGraw-Hill; 1960:104–140.
19. Pancherz H. The mechanism of Class II correction in Herbst appliance treatment. A cephalometric investigation. *Am J Orthod.* 1982;82:104–113.
20. Dahlberg G. *Statistical Methods for Medical and Biological Students*. London: Allen and Unwin; 1940:122–132.
21. Bondemark L, Kurol J. Class II correction with magnets and superelastic coils followed by straight-wire mechanotherapy. *J Orofac Orthop.* 1998;59:127–138.
22. Bondemark L, Feldmann I, Feldmann H. Distal molar movement with an intra-arch device provided with the Onplant system for absolute anchorage. *World J Orthod.* 2002;3:117–124.
23. Park HS, Kwon TG, Sung JH. Nonextraction treatment with microcrew implants. *Angle Orthod.* 2004;74:539–549.
24. Forsberg CM, Hellsing E. The effect of a lingual arch appliance

- with anterior bite plane in deep overbite correction. *Eur J Orthod.* 1984;6:107–115.
25. Atherton GJ, Glenny AM, O'Brien KD. Development and use of a taxonomy to carry out a systematic review of the literature on methods described to effect distal movement of maxillary molars. *J Orthod.* 2002;29:211–216.
26. You QL, Hagg U. A comparison of three superimposition methods. *Eur J Orthod.* 1999;21:717–725.
27. Ioannidis JP, Haidich AB, Pappa M, Pantazis N, Kokori SI, Tektonidou MG, Contopoulos-Ioannidis DG, Lau J. Comparison of evidence of treatment effects in randomized and non randomized studies. *JAMA.* 2001;286:821–830.