

Zygomatic Anchorage for En Masse Retraction in the Treatment of Severe Class II Division 1

Nejat Erverdi^a; Ahu Acar^b

Abstract: An adult female patient who presented with a severe Class II division 1 malocclusion was treated by en masse retraction of upper anterior teeth against zygomatic anchorage. This case report describes the surgical and orthodontic procedures followed during the treatment. En masse retraction of the six anterior teeth by using zygomatic bone anchorage proved to be an efficient method for the correction of a severe overjet problem. (*Angle Orthod* 2005;75:483–490.)

Key Words: Zygomatic anchorage; En masse retraction; Class II division 1 malocclusion; Overjet correction; Absolute anchorage

INTRODUCTION

Anchorage control is one of the most important aspects of orthodontic treatment. Moderate anchorage is relatively easy to manage using some intraoral appliances and bio-

mechanical procedures. On the other hand, cases that require maximum anchorage require extraoral support to reinforce the anchorage. In some instances, 100% anchorage has to be maintained, and such an anchorage can be termed as absolute anchorage. It is difficult and often impossible to obtain absolute anchorage by conventional methods such as extraoral force application.

Nowadays, clinicians seek alternative anchorage protocols, which will not incorporate extraoral appliances and which will not require patient cooperation. Recent developments in the field of osseointegration have made possible the use of implants for orthodontic anchorage. Wehrbein et al,¹ Bernhart et al,² Triaca et al,³ Tosun et al,⁴ and Keles et al,⁵ all used palatal implants to achieve absolute anchorage and reported successful results.

^a Professor and Chair, Department of Orthodontics, School of Dentistry, Marmara University, Nisantasi, Istanbul, Turkey.

^b Associate Professor, Department of Orthodontics, Faculty of Dentistry, Marmara University, Nisantasi, Istanbul, Turkey.

Corresponding author: Ahu Acar, DDS, PhD, Department of Orthodontics, Faculty of Dentistry, Marmara University, Buyukciftlik Sok. No: 6, Nisantasi, Istanbul 34367, Turkey (e-mail: ahuacar@yahoo.com)

Accepted: November 2004. Submitted: July 2004.

© 2005 by The EH Angle Education and Research Foundation, Inc.

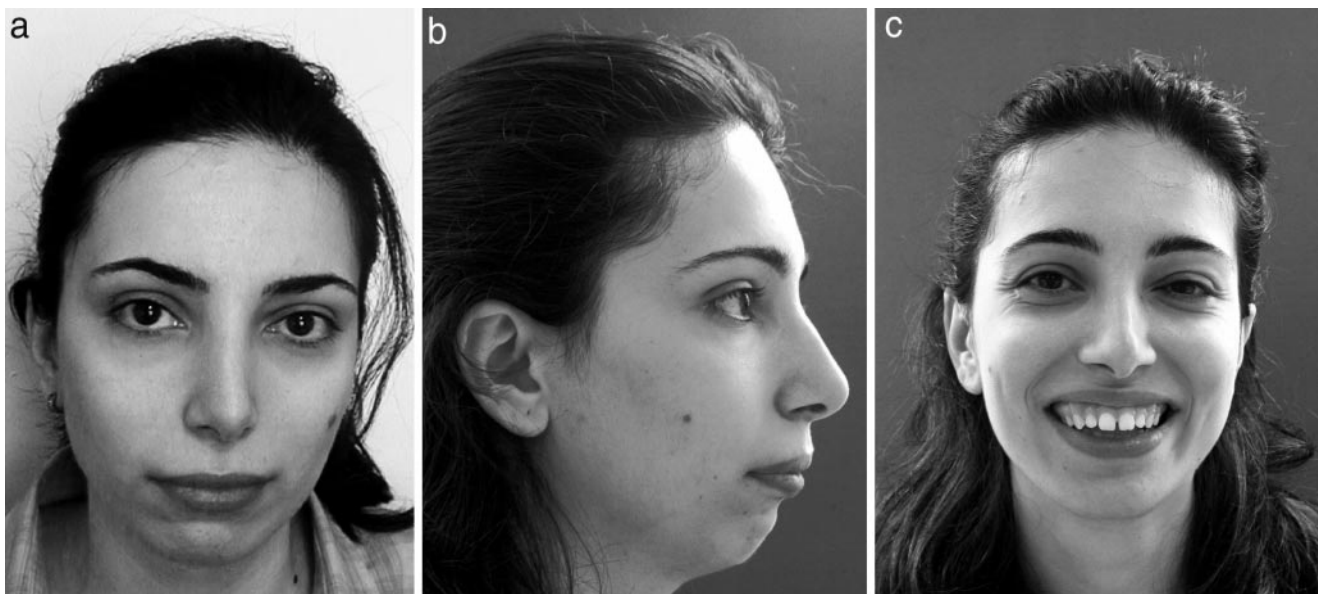

FIGURE 1. Pretreatment extraoral views.

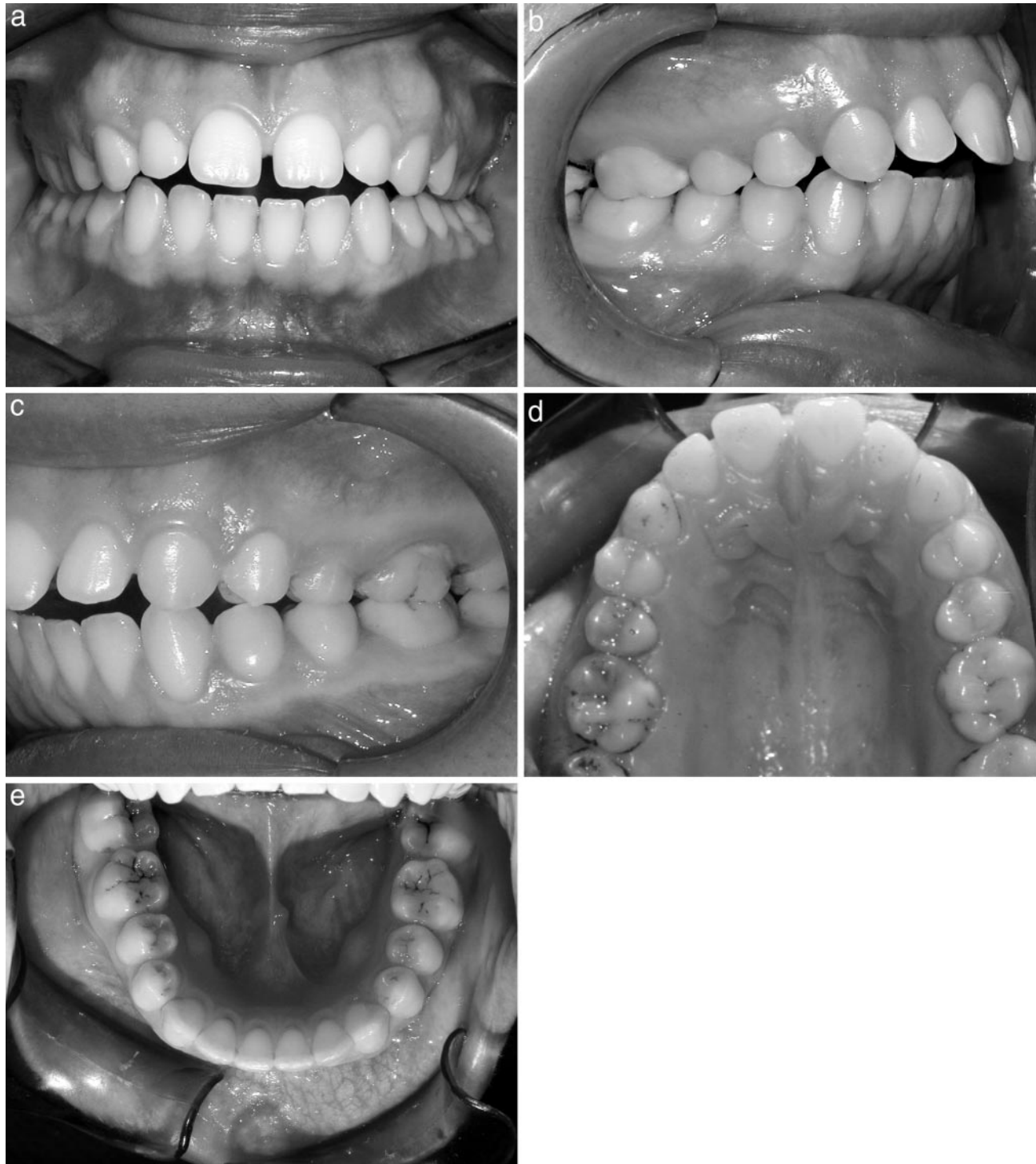


FIGURE 2. Pretreatment intraoral views.

Some other investigators have used dental implants as orthodontic anchorage units.⁶⁻¹² The term “skeletal anchorage” became popular after titanium miniplates and micro-screws began to be used for anchorage purposes.¹³⁻¹⁷ To treat skeletal open bite, Erverdi et al¹⁸ and Sherwood et al¹⁹ used the anchorage provided by titanium miniplates, which

were placed in the zygomatic area. De Clerck et al²⁰ used zygomatic anchorage during retraction of maxillary anterior teeth. Their reports suggest that the zygomatic buttress serves as a useful site for obtaining absolute orthodontic anchorage.

The en masse retraction of upper anterior teeth has al-

TABLE 1. Cephalometric Evaluation

Measurement (°)	Norm	Pretreatment	Posttreatment
SNA	82 ± 2	81	81
SNB	80 ± 2	72	72
ANB	2	9	9
SN-Mandibular plane	32 ± 7	40	40
FMA	25	30	30
SN-Palatal plane	8 ± 2	9	9
1-SN	103	107	90
IMPA	90	105	105

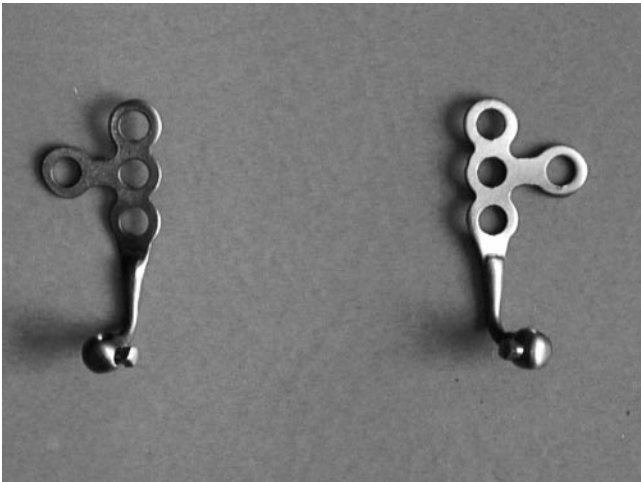


FIGURE 3. Zygomatic implant.

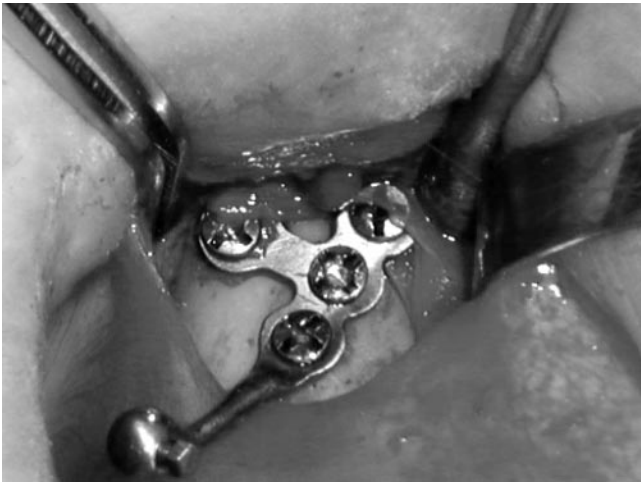

FIGURE 4. Fixing of the zygomatic implant.

ways been a popular option in the treatment of maxillary protrusion cases, with the shortened treatment time being its main advantage. Bodily movement of the anterior segment during retraction creates a more favorable tissue response compared with the alternative tipping and uprighting technique,^{21,22} and it allows the extraction space to be closed in a single step. However, the anchorage requirement for

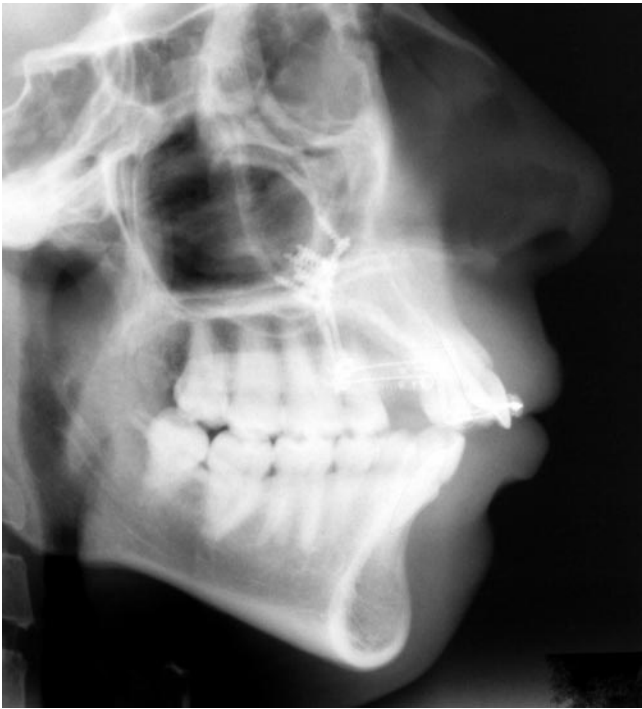

FIGURE 5. Point of force application as seen on the lateral head film.

bodily retraction is much greater than that for tipping. Bodily movement during retraction can be achieved by applying a force and a couple at the bracket level or by carrying the point of force application to the level of center of resistance of the anterior segment.²³ The center of resistance of the anterior segment, including the canines, has been shown to be about 3.5 mm apical to the palatal bone level at the incisor region.²⁴

In the case presented, en masse retraction of six anterior teeth was carried out using zygomatic anchorage. In an attempt to achieve bodily movement of the anterior segment, retraction force was applied approximately at the level of center of resistance of the anterior segment.

CASE PRESENTATION

The patient was a 24-year-old female who presented with a Class II division 1 malocclusion. Her chief complaints were an unaesthetic facial appearance and a gummy smile. Her anamnesis showed no contraindication to orthodontic treatment.

Diagnosis

The patient was characterized by an excessively convex facial profile resulting from a retrognathic mandible. Her facial appearance was characterized by a short mandibular corpus length, excessive lip strain in the closed lip position, and an insufficient chin prominence. She had a gummy smile, with an excessive gingival showing both in the an-

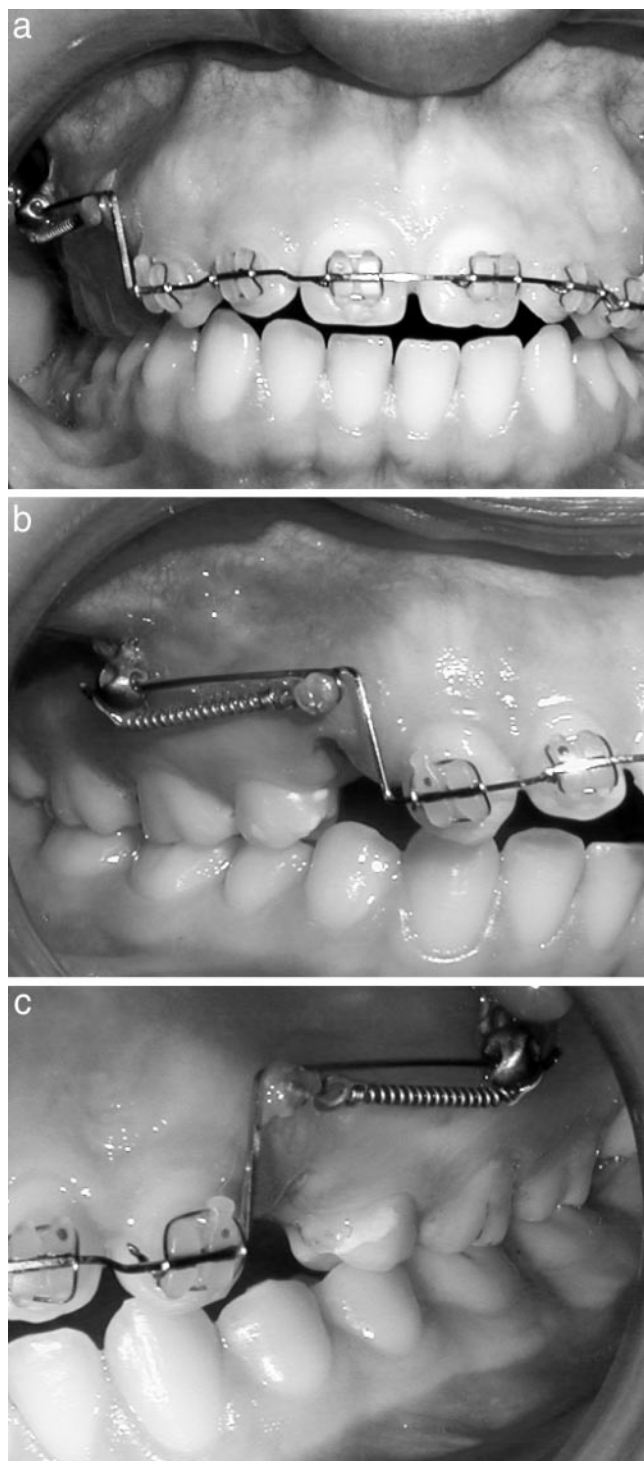


FIGURE 6. Application of the NiTi closed coil springs.

terior and posterior parts of the dentition and a slight open bite (Figure 1). She also had a tongue thrust swallow associated with the presence of an open bite.

She presented with a Class II molar and canine relationship on both sides, along with a 12-mm overjet and two-mm anterior open bite. She had a maxillary midline diaste-

ma and undersized upper laterals, too (Figure 2). Her cephalometric measurements are shown in Table 1.

Treatment objectives

The treatment plan consisted of extraction of the upper first premolars and retraction of the six anterior teeth to correct the excessive overjet. Because the patient firmly refused to wear a headgear during the treatment, en masse retraction had to be carried out with the anchorage provided by the zygomaticomaxillary buttress.

Treatment alternatives

Another treatment plan was to prepare the patient for a double jaw surgery, which would involve maxillary impaction and mandibular advancement. This would have been the ideal treatment for the correction of gummy smile and improvement of facial esthetics. However, because the patient rejected an invasive surgical procedure, the alternative plan involving upper first premolar extractions was adopted.

Surgical method

Under local infiltrative anesthesia, a one-cm-long vertical incision was carried along the crest of the zygomatic buttress, ending at the intersection of the attached and mobile gingiva. A mucoperiosteal flap was elevated, and by blunt dissection, the lower aspect of the zygomatic process of the maxilla was totally exposed. A zygomatic implant manufactured by Surgi-Tec (Brugge, Belgium) was adjusted to fit the contour of the inferior border of each zygomatic process and fixed with four bone screws (Figures 3 and 4). The ball end of the zygomatic implant was exposed to the oral cavity from the incision area. Care was taken to adjust the position of the ball end in such a manner that its horizontal tube would be parallel to the buccal surface of the first molar crowns. The orientation of the horizontal tube was a critical step during the surgical procedure because this tube would be used instead of a molar tube during retraction of the anterior teeth. The incision site was closed and sutured. The patient was advised to use antiseptic mouthwash for one week and practice good oral hygiene during the healing period. The bone anchor was loaded immediately after removal of the sutures.

Treatment progress

The maxillary first premolars were extracted as part of the orthodontic treatment plan. Roth prescription brackets (0.018 inch) were bonded to the upper six anterior teeth. Because there was only a slight misalignment in the incisor region, leveling was postponed until the end of en masse retraction.

A 0.017 × 0.25-inch stainless steel archwire with slight steps, insets, and offsets was placed passive in the upper

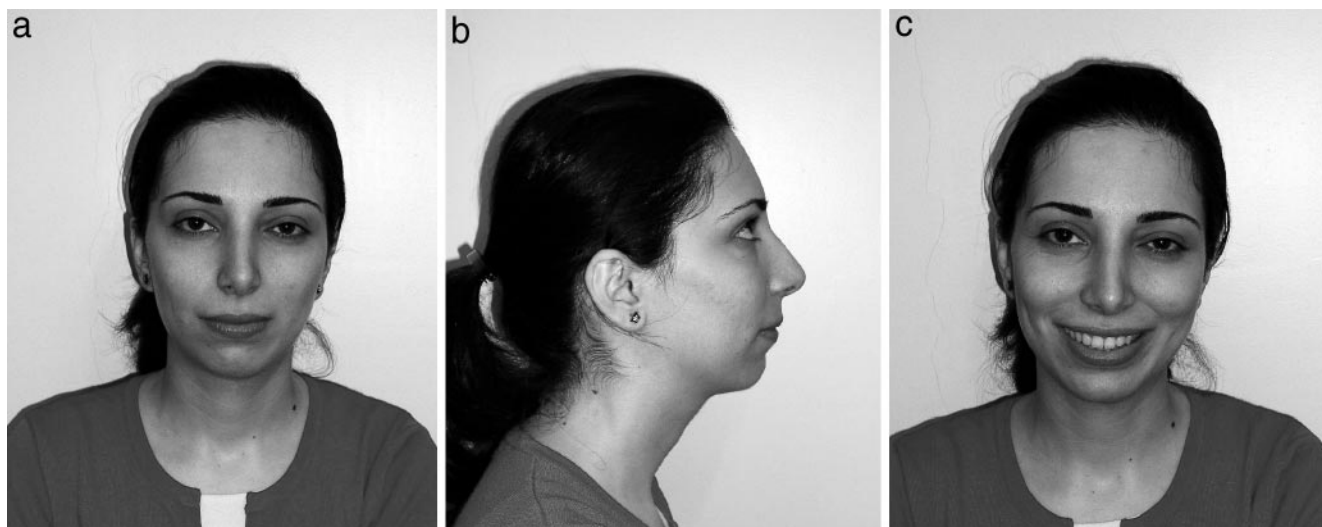


FIGURE 7. Posttreatment extraoral views.

bracket slots. The archwire was bent vertically in the apical direction after the canine bracket on each side and after the formation of a helix, bent distally at the same vertical level as the tube on the ball end. It was adjusted to pass through the tubes in the ball ends and two-mm wire extensions were left distal to the ball ends. The archwire was engaged in the brackets and the tubes and ligated tightly.

NiTi closed coil springs exerting 150 g of force were attached bilaterally to the helices on the archwire. The point of force application can be viewed in Figure 5. Activation was completed by engaging the free ends of the coil springs to the extensions of the arch wire distal to the tubes on both sides. To prevent soft tissue impingement, the helices and the ends of the coil springs were covered with adhesive material (Figure 6). The patient was requested to return to the clinic each month for control visits. No activation of the coil springs was necessary during these visits. Wire extensions distal to the tubes were shortened at each visit.

After correction of the overjet, molar bands and premolar brackets were applied and a round 0.016-inch NiTi archwire was engaged for leveling, followed by rectangular stainless steel archwires for finishing. No orthodontic treatment was performed in the lower arch. At debonding, slight diastemata were left mesial and distal to the undersized upper laterals, which were filled later during a composite buildup of these teeth. For retention, a fixed lingual canine-to-canine retainer was placed in the upper arch.

Treatment results

The overjet was reduced to normal limits in six months (Figures 7 and 8), and the overall treatment lasted 17 months. No movement in the molar area was observed. Cephalometric superimposition of the case is shown in Figure 9. The superimposition shows that the incisor movement was controlled tipping rather than bodily movement

as originally planned. A side effect observed during treatment was palatal tipping of the canines.

DISCUSSION

In this case, the optimal facial and smile esthetics could be achieved by a surgical intervention, which would involve maxillary impaction and mandibular advancement. However, the patient strongly rejected this option, objected, and demanded a treatment alternative, which would involve no extraoral appliance. With adoption of this treatment plan, upper first premolar extractions, and en masse retraction of six anterior teeth, it was possible to treat the dentition to an acceptable occlusion, but the profile was influenced only to a limited extent, with the mandible remaining in a retrognathic position.

The favorable outcome of the case described in this article shows that zygomatic bone anchorage can open a new field in the treatment of adults. By using skeletal anchorage, orthodontic procedures, which demand strict anchorage control, can be efficiently carried out without any need for extraoral force. Because there is no anchorage loss, treatment objectives can be fulfilled without any compromise.

Skeletal anchorage also can be obtained by palatal implants¹⁻⁵ and microscrews¹⁵⁻¹⁷ that are placed in the alveolar bone. Although palatal implants provide reliable absolute anchorage, they require a period of at least three months for osseointegration before orthodontic force application. Microscrews offer advantages such as simple placement surgery, less discomfort after implantation, immediate loading, and lower costs. However, their proximity to the roots can create problems during placement or when the adjacent teeth are moved. The success rate of microscrews with one- to 1.5-mm diameter has been reported lower in the maxilla than in the mandible because the buccal cortical bone of the maxilla is thinner than that of the mandible.²⁵

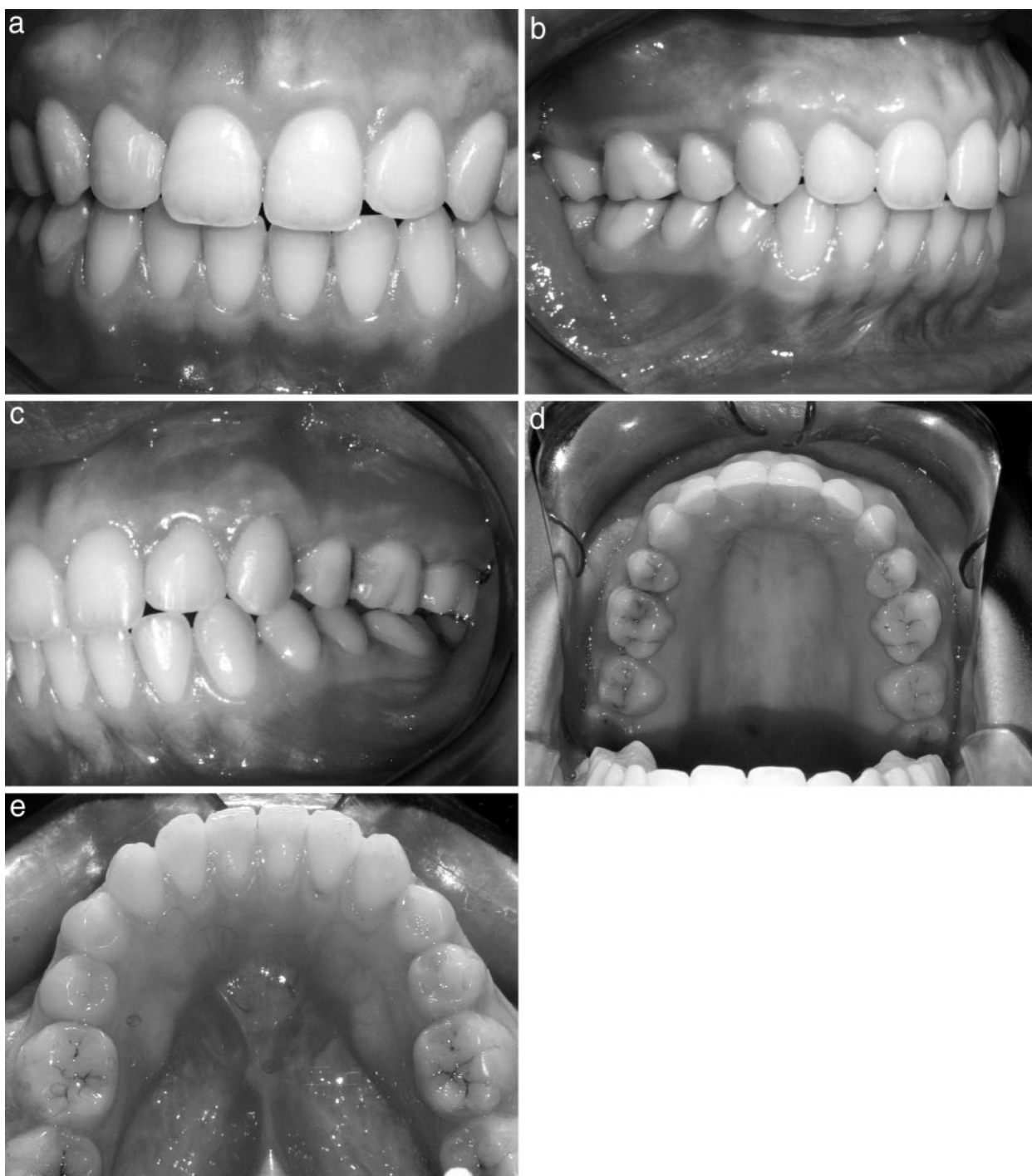


FIGURE 8. Posttreatment intraoral views.

Inferior border of the zygomatic process of the maxilla has a solid bone structure, and it is located at a safe distance from the roots of the upper molars. A miniplate, which is fixed with three or four miniscrews in this area, provides adequate retention for immediate loading. The bone anchorage in this area can be used indirectly to reinforce molar anchorage or can be used directly as described in this article. Considering the failure risk of microscrews in the

maxilla because of relatively thin buccal cortical bone, it was felt that zygomatic miniplate anchorage would be a more safe choice compared with microscrew anchorage.

The surgical procedure lasted about 30 minutes and was tolerated easily by the patient. Drilling and screwing was done with hand instruments to cause minimal trauma to the bone and to prevent overheating of the bone. There was only minor edema and pain postoperatively.

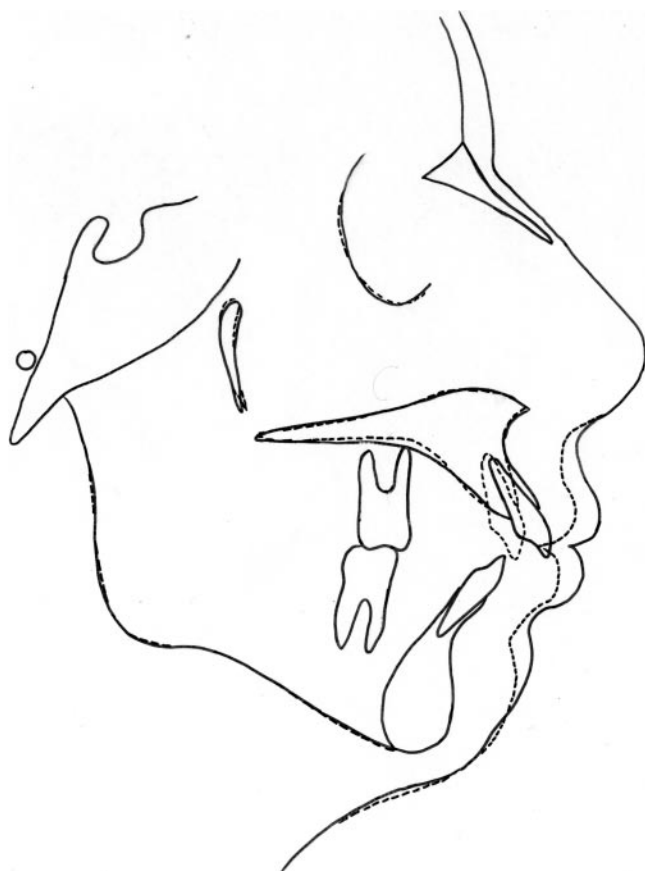

FIGURE 9. Superimposition of the pre- and posttreatment cephalometric tracings.

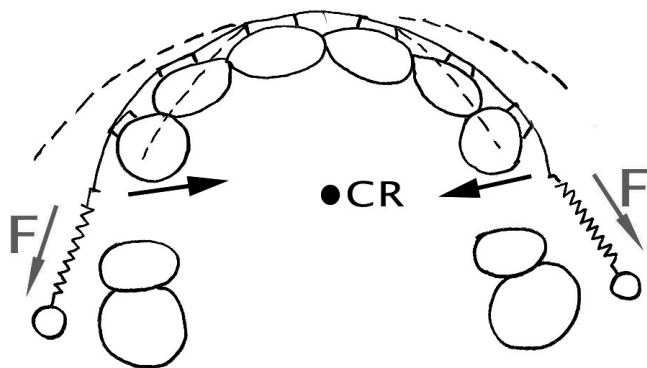


FIGURE 10. Schematic description of the force system which might have caused palatal tipping of the canines.

A significant side effect of the treatment was the palatal tipping of the canines. This movement can be attributed to the deformation that took place in the rectangular archwire because of the distal pull exerted by the coil springs (Figure 10). This effect can be counterbalanced by using a thicker archwire and 0.022-inch slot brackets or by placing canine offset bends in the archwire at the beginning of the treatment.

Straightening of the incisors was observed after comple-

tion of the retraction. During retraction of the anterior segment, the point of force application was adjusted to pass through the estimated center of resistance of the six anterior teeth, which was reported to be about 3.5 mm apical to the palatal bone level in the incisor region.²¹ Straightening of the incisors in this case indicates that the center of resistance might have been located one or two mm more apically. Placing compensating torque bends in the incisor region in the beginning could serve as insurance against such variations. The time spent for correction of the axial inclinations of the canines and incisors extended the overall treatment duration. The treatment could have been completed sooner had these complications not occurred.

The posttreatment extraoral photographs of the patient show that both maxillary anterior and posterior teeth still need intrusion to improve the gummy smile and encourage mandibular forward autorotation. Zygomatic miniplates could have been used to intrude the upper teeth as well as to prevent loss of anchorage.

Retention of treatment results in open bite cases is a difficult task for the orthodontist. Vertical development of the posterior teeth,²⁶ initial open bite severity,²⁷ and lack of adaptation of tongue posture²⁸ have been reported to be important factors in the relapse of open bite in the long term. Because the subject in the present study has completed her skeletal growth and presented only a slight open bite in the beginning of treatment, a significant relapse is not expected. Tongue pressures during function were reported to be relatively unimportant as determinants of malocclusion.²⁹ In this regard, a tongue thrust swallowing pattern can be considered as a consequence rather than the cause of a malocclusion, and it would be expected to be eliminated after the establishment of a correct overjet and overbite relationship. However, a forward tongue posture during rest position could present a problem from the point of stability.²⁹

CONCLUSION

- En masse retraction of the six anterior teeth by using zygomatic bone anchorage is an efficient method for the correction of a severe overjet problem.

REFERENCES

1. Wehrbein H, Glatzmaier J, Mundwiler U, Diedrich P. The ortho-system: a new implant system for orthodontic anchorage in the palate. *J Orofac Orthop.* 1996;57:142–153.
2. Bernhart T, Vollgruber A, Gahleitner A, Dörtbudak O, Haas R. Alternative to median region of the palate for placement of an orthodontic implant. *Clin Oral Implants Res.* 2000;11:595–601.
3. Triaca A, Antonini M, Wintermantel E. Ein neues Titan-Flachschraubenimplantat zur Verankerung am anterioren Gaumen. *Inf Orthod Kieferorthop.* 1992;24:251–257.
4. Tosun T, Keles A, Erverdi N. Method for the placement of palatal implants. *Int J Oral Maxillofac Implants* 2002;17:95–100.
5. Keles A, Erverdi N, Sezen S. Bodily distalization of molars with absolute anchorage. *Angle Orthod.* 2003;73:471–478.
6. Ödman J, Lekholm U, Jemt T, Branemark P-I, Thilander B. Os-

- seointegrated titanium implants—a new approach in orthodontic treatment. *Eur J Orthod.* 1988;10:98–105.
7. Roberts WE, Smith R, Zilberman Y, Mozsary PG, Smith RS. Osseous adaptation to continuous loading of rigid endosseous implants. *Am J Orthod.* 1984;86:95–111.
 8. Roberts WE, Helm FR, Marshall KJ, Gonglof RK. Rigid endosseous implants for orthodontic and orthopedic anchorage. *Angle Orthod.* 1989;59:247–256.
 9. Roberts WE, Marshall KJ, Mozsary PG. Rigid endosseous implant utilized as anchorage to protract molars and close an atrophic extraction site. *Angle Orthod.* 1990;60:135–152.
 10. Turley PK, Kean C, Sehur J, Stefanac J, Gray J, Hennes J, Poon LC. Orthodontic force application to titanium endosseous implants. *Angle Orthod.* 1988;58:151–162.
 11. Van Roekel NB. The use of Branemark system implants for orthodontic anchorage: report of a case. *Int J Oral Maxillofac Implants* 1989;4:341–344.
 12. Higuchi KW, Slack JM. The use of titanium fixtures for intraoral anchorage to facilitate orthodontic tooth movement. *Int J Oral Maxillofac Implants* 1991;6:338–344.
 13. Umemori M, Sugawara J, Mitani H, Nagasaka H, Kawamura H. Skeletal anchorage system for openbite correction. *Am J Orthod Dentofacial Orthop.* 1999;115:166–174.
 14. Ohmae M, Saito S, Morohashi T, et al. A clinical and histological evaluation of titanium mini-implants as anchors for orthodontic intrusion in the beagle dog. *Am J Orthod Dentofacial Orthop.* 2001;119:489–497.
 15. Kanomi R. Mini-implant for orthodontic anchorage. *J Clin Orthod.* 1997;31:763–767.
 16. Park HS, Bae SM, Kyung HM, Sung JH. Micro-implant anchorage for treatment of skeletal Class I bialveolar protrusion. *J Clin Orthod.* 2001;35:417–422.
 17. Park HS, Kwon TG. Sliding mechanics with microscrew implant anchorage. *Angle Orthod.* 2004;74:703–710.
 18. Erverdi N, Tosun T, Keles A. A new anchorage site for the treatment of anterior openbite: zygomatic anchorage. Case report. *World J Orthod.* 2002;3:147–153.
 19. Sherwood KH, Burch JG, Thompson WJ. Closing anterior open bites by intruding molars with titanium miniplate anchorage. *Am J Orthod Dentofacial Orthop.* 2002;122:593–600.
 20. De Clerck H, Geerinckx V, Siciliano S. The zygoma anchorage system. *J Clin Orthod.* 2002;36:455–459.
 21. Reitan K. Some factors determining the evaluation of forces in orthodontics. *Am J Orthod.* 1957;43:32–45.
 22. Wehrbein H, Fuhrmann RAW, Diedrich PR. Human histologic response after long-term orthodontic tooth movement. *Am J Orthod Dentofacial Orthop.* 1995;360–371.
 23. Nanda R, Kuhlberg A. Principles of biomechanics. In: Nanda R, ed. *Biomechanics in Clinical Orthodontics*. Philadelphia, Pa: WB Saunders Company; 1997:1–22.
 24. Yoshida N, Koga Y, Mimaki N, Kobayashi K. In vivo determination of the centers of resistance of maxillary anterior teeth subjected to retraction forces. *Eur J Orthod.* 2001;23:529–534.
 25. Miyawaki S, Koyama I, Inoue M, Mishima K, Sugahara T, Yamamoto TT. Factors associated with the stability of titanium screws placed in the posterior region for orthodontic anchorage. *Am J Orthod Dentofacial Orthop.* 2003;124:373–378.
 26. Küçükkeles N, Acar A, Demirkaya AA, Evrenol B, Enacar A. Cephalometric evaluation of open bite treatment with NiTi arch wires and anterior elastics. *Am J Orthod Dentofacial Orthop.* 1999;116:555–562.
 27. de Freitas MR, Beltrao RTS, Janson G, Henriques JFC, Cançado RH. Long term stability of anterior openbite extraction treatment in the permanent dentition. *Am J Orthod Dentofacial Orthop.* 2004;125:78–87.
 28. Proffit WR, Bailey LJ, Phillips C, Turvey TA. Long term stability of surgical openbite correction by Le Fort I osteotomy. *Angle Orthod.* 2000;70:112–117.
 29. Proffit WR. On the etiology of malocclusion. *Br J Orthod.* 1985; 13:1–11.