

Short-Term Treatment Effects Produced by the Herbst Appliance in the Mixed Dentition

Marcio Rodrigues de Almeida^a; José Fernando Castanha Henriques^b;
Renato Rodrigues de Almeida^c; Weber Ursi^d; James A. McNamara Jr^e

Abstract: This prospective clinical investigation evaluates the dentoalveolar and skeletal cephalometric changes produced by the Herbst appliance during treatment of mixed dentition patients with Class II division 1 malocclusion. Thirty individuals (15 male and 15 female individuals; initial mean age nine years 10 months) were treated with the Herbst appliance for a period of 12 months. For comparison, the records of 30 untreated Class II children (15 boys, 15 girls; initial mean age nine years eight months) were followed without treatment for a period of 12 months. The results indicated that the treatment effects produced in the mixed dentition patients were primarily dentoalveolar in nature. The mandibular incisors were tipped labially, and the maxillary incisors were retruded; a significant increase in mandibular posterior dentoalveolar height occurred, and there was a restriction in the vertical development of the maxillary molars. There was no difference in the forward growth of the maxilla between the two groups. In comparison with the controls, however, the Herbst treatment produced a modest but statistically significant increase in total mandibular length. This increase in total mandibular length, however, was less than that observed in adolescent Herbst patients in other studies. (*Angle Orthod* 2005;75:540–547.)

Key Words: Herbst appliance; Early treatment; Class II division 1 malocclusion; Functional orthopedics; Mixed dentition

INTRODUCTION

Several types of functional appliances currently used for Class II treatment are aimed at improving ex-

isting skeletal imbalances, arch form, and orofacial function.¹ One of these is the Herbst appliance, and the popularity of this appliance has increased so much during the past two and a half decades that it is now the most widely used functional appliance in the United States.^{1,2}

The short- and long-term effects of Herbst appliance treatment in Class II, division 1 malocclusions have been investigated in many studies.^{3,4-9} The restraining effect on maxillary growth has been reported to be of minor importance in improving maxillomandibular relationships.^{3,4,6,10-12} In contrast, previous Herbst studies have documented significant increases in mandibular length compared with untreated controls. These in-

^a Postdoctoral Fellow, Department of Orthodontics, Bauru Dental School, University of São Paulo, São Paulo, Brazil, and Associate Professor, Lins Dental School, Universidade Metodista de Piracicaba, São Paulo, Brazil.

^b Professor, Department of Orthodontics, Bauru Dental School, University of São Paulo, São Paulo, Brazil.

^c Associate Professor, Department of Orthodontics, Bauru Dental School, University of São Paulo, São Paulo, Brazil; Full Professor, Lins Dental School, Universidade Metodista de Piracicaba, São Paulo, Brazil; and Full Professor, University of São Paulo city, São Paulo, Brazil.

^d Associate Professor, Department of Orthodontics, São José dos Campos Dental School, UNESP, São Paulo, Brazil.

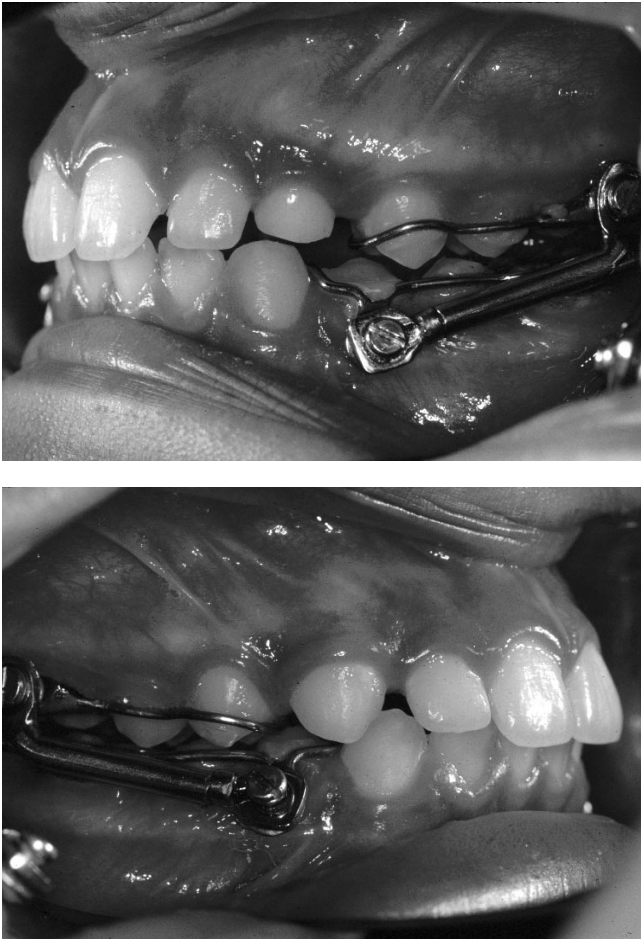
^e Thomas M. and Doris Graber Endowed Professor of Dentistry, Department of Orthodontics and Pediatric Dentistry, School of Dentistry, Professor of Cell and Developmental Biology, School of Medicine, and Research Scientist, Center for Human Growth and Development, University of Michigan, Ann Arbor, Mich.; and private practice, Ann Arbor, Mich.

Accepted: July 2004. Submitted: May 2004.

© 2005 by The EH Angle Education and Research Foundation, Inc.

Corresponding author: Marcio Rodrigues de Almeida, DDS, MSc, Dr Orthod, Department of Orthodontics, Bauru Dentistry School, University of São Paulo, R. Octávio Pinheiro Brizolla, 9-75 Bauru, São Paulo, CEP 17012-901, Brazil (e-mail: marcioralmeida@uol.com.br, marcio.almeida@aaomembers.org)

Based on research by Dr Almeida in partial fulfillment of the requirements for the Postdoctoral Program in Orthodontics, University of São Paulo, Bauru Dental School, Brazil.



FIGURES 1 and 2. Modified Herbst appliance.

creases in mandibular length ranged from 2.0 to 2.2 mm for a six-month period for the banded appliance^{4,6} and from 2.7 to 3.5 mm for a one-year treatment period for the acrylic splint Herbst appliance.¹²

The vast majority of previous studies have considered patients treated in the permanent dentition.^{4,12–19} To our knowledge, only four Herbst studies in the English literature have evaluated Herbst treatment effects for patients in the mixed dentition.^{20–23} No previous clinical investigation has considered only the treatment effects of the Herbst appliance while having an adequate sample size.

Therefore, this prospective clinical study investigates the effects of mixed dentition Herbst therapy in patients presenting Class II division 1 malocclusion as

compared with a matched untreated Class II control sample.

MATERIALS AND METHODS

Beginning in 2002, the first 40 patients with a Class II malocclusion in the mixed dentition applying for treatments at Lins Dental School, Methodist University, were evaluated by one investigator. Of the original 40 patients in the parent sample, 10 patients were excluded. Eight patients had the Herbst appliance removed prematurely because of breakage, and two patients had inadequate radiographs because of improper head positioning. Consequently, the final sample comprised 30 subjects (15 boys, 15 girls) with Class II division 1 malocclusions characterized by a bilateral distal molar relationship greater than one-half cusp, presence of mandibular deciduous second molars, and an ANB angle $\geq 4.5^\circ$. The initial mean age was nine years 10 months (range, 8.2–11.0 years), and the final mean age was 10 years 10 months (range, 9.2–12.0 years).

The patients were treated with a modified Herbst appliance with reinforcement wires soldered to bands on the maxillary permanent first molars and the primary mandibular first molars region (Figures 1 and 2). No brackets or other appliances were used during Herbst therapy. The construction bite was registered with the mandible protruded 5.0 mm in only one step.³

A control sample, derived from the files of the University of São Paulo (Bauru) Growth Study, comprised 30 subjects (15 boys, 15 girls; Table 1). The control subjects presented with a bilateral distal molar relationship (\geq one-half cusp), mandibular deciduous second molars still present, and an ANB angle $\geq 4.5^\circ$. The initial mean age of the control sample was nine years eight months (range, 8.0–10.9 years), and final mean age was 10 years eight months (range, 9.0–11.6 years). This Class II sample had no previous orthodontic treatment and was observed for a period of 12 months.

Both groups were matched in skeletal maturation at T₁ according to cervical vertebrae maturation (CVM).^{24,25} The mean maturation stage for all the groups at T₁ was between stage 1 and stage 3.

The 120 lateral cephalograms were traced on acetate paper by one investigator and verified by a second investigator. The tracings were digitized and analyzed

Table 1. Descriptive Statistics: Sample Description

Groups	n	Male	Female	T ₁	T ₂	Average Treatment/Observation
Controls	30	15	15	9 y 8 mo	10 y 8 mo	12 mo
Herbst	30	15	15	9 y 10 mo	10 y 10 mo	12 mo

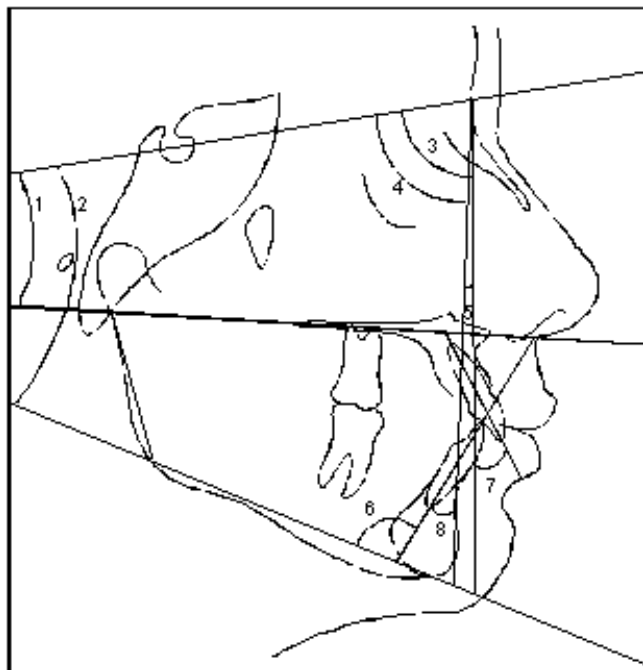


FIGURE 3. Angular measurements: 1, SN.PP; 2, SN.GoMe; 3, SNA; 4, SNB; 5, ANB; 6, IMPA; 7, U1.NA; 8, L1.NB.

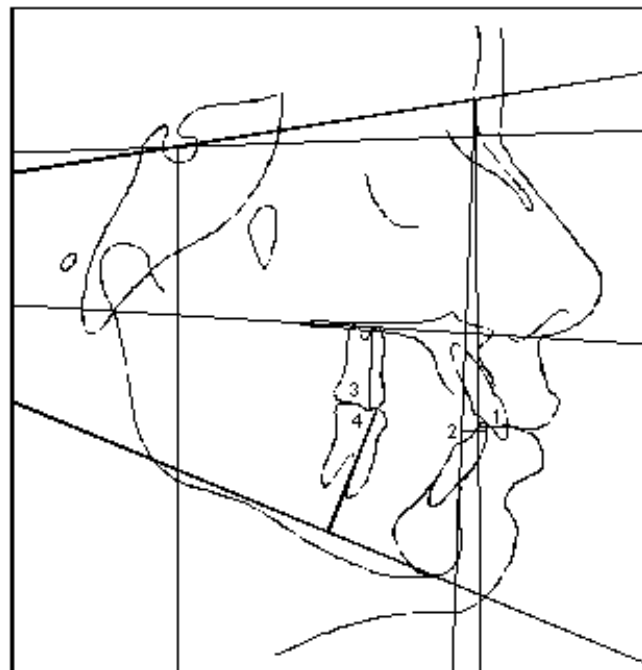


FIGURE 5. Dental linear measurements: 1, U1-NA; 2, L1-NB; 3, U6-PP; 4, L6-GoMe.

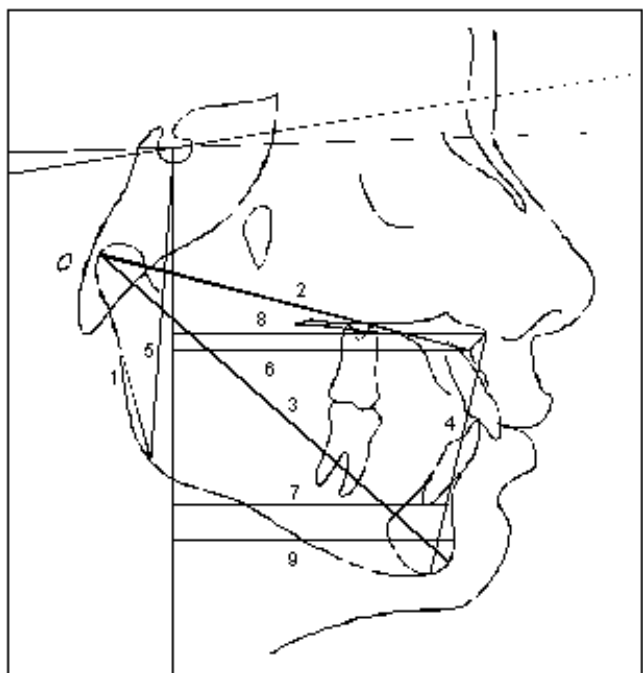


FIGURE 4. Skeletal linear measurements: 1, Ar-Go; 2, Co-A; 3, Co-Gn; 4, ANS-Me; 5, S-Go; 6, A-FHp; 7, B-FHp; 8, ANS-FHp; 9, Pog-FHp.

using the Dentofacial Planner 7.0 (Dentofacial Planner Software Inc, Toronto, Canada) (Figures 3 through 5). All statistical analyses were performed with the aid of a commercial statistical package (SigmaSta™, Statis-

tical Software for Windows, Version 1.0; SPSS Science, Chicago, Ill).

The analysis of treatment effects was derived from the tracings of the cephalometric headfilms taken immediately before and four weeks after the removal of the Herbst appliance. These data were compared with corresponding data derived from the control sample.

To assess the error of locating the reference points and the digitizing procedure, 20 randomly selected cephalograms were retraced and remeasured after approximately one month by the same examiner. The casual error of the method (Dahlberg formula) did not exceed 0.8° or 0.6 mm. Paired *t*-tests (Houston²⁶) demonstrated no statistically significant systematic error differences for all measurements. Sexual dimorphism, the pretreatment cephalometric measurements of the two groups (T_1), and the changes over the treatment/observation period were compared between the two groups using independent sample *t*-tests.

RESULTS

The overall comparison of the starting forms of the two groups showed a high level of similarity, with only three of the 21 variables showing statistical differences (Table 2). In addition, the mean cephalometric values for the two groups at T_1 also did not differ significantly according to sex, so the sexes were combined and evaluated together.

Table 2. Comparison of Starting Forms

	Control			Herbst			Significance ^a
Cephalometric measures	n	Mean	SD	n	Mean	SD	
Maxillary skeletal							
SNA (°)	30	80.4	2.8	30	83.4	3.8	**
Co-A (mm)	30	81.0	3.8	30	82.9	4.7	NS
A-FHp (mm)	30	62.7	3.8	30	63.8	4.7	NS
ANS-FHp (mm)	30	68.5	3.7	30	68.8	4.4	NS
Mandibular skeletal							
SNB (°)	30	75.3	3.0	30	76.7	3.2	NS
Ar-Go (mm)	30	37.6	2.1	30	38.1	4.0	NS
Co-Gn (mm)	30	99.2	4.3	30	100.9	5.6	NS
B-FHp (mm)	30	53.7	5.2	30	54.2	5.8	NS
Pog-FHp (mm)	30	54.0	5.5	30	54.7	6.7	NS
Maxillary/mandibular							
ANB (°)	30	5.0	1.8	30	6.6	2.0	NS
Vertical skeletal							
SN.GoMe (°)	30	34.7	3.7	30	33.8	5.0	NS
SN.PP (°)	30	7.6	2.7	30	6.8	3.9	NS
ANS to Me (mm)	30	58.7	3.9	30	59.3	2.4	NS
S-Go (mm)	30	64.1	3.7	30	66.2	5.4	NS
Maxillary dentoalveolar							
U1.NA (°)	30	24.8	6.7	30	24.8	6.3	NS
U1-NA (mm)	30	4.7	1.3	30	5.0	1.7	NS
U6-PP (mm)	30	18.2	1.6	30	19.3	2.5	NS
Mandibular dentoalveolar							
IMPA (°)	30	94.7	5.8	30	97.3	6.3	NS
L1.NB (°)	30	24.8	5.6	30	27.9	4.6	*
L1-NB (mm)	30	4.4	1.2	30	5.7	1.7	*
L6-GoMe (mm)	30	26.0	1.7	30	26.1	2.0	NS

^a NS, not significant; * $P < .05$; ** $P < .01$.

Changes from T₁ to T₂

Skeletal. There were no statistically significant differences between the Herbst and control groups in maxillary skeletal measurements (Table 3). The maxillae of the Herbst patients grew downward and forward at the same rate as the control group.

The effective mandibular length (Co-Gn) increased significantly more in the Herbst group as compared with the control group ($P < .05$). These greater increases in mandibular length also were evident in the significant increases in Ar-Go and the SNB angle ($P < .05$).

Maxillary mandibular relationship. The ANB angle was reduced significantly more in the Herbst group than the control group ($P < .01$). The mandibular plane and the palatal plane were unaffected by treatment. No differences in lower anterior facial height (LAFH) and in posterior facial height were present.

Dentoalveolar. The maxillary incisors were retracted significantly relative to NA both in millimeter and angulation ($P < .01$). In addition, the Herbst appliance

produced more inhibition of maxillary molar eruption relative to the palatal plane ($P < .05$).

The mandibular incisors were retracted significantly relative to IMPA as well as to NB both in millimeter and angulation ($P < .01$). The Herbst patients also showed more mandibular molar eruption relative to the mandibular plane ($P < .05$).

DISCUSSION

Changes in linear and angular measurements less than one millimeter or one degree were considered clinically insignificant, even if statistical significance was present.

Maxillary skeletal

There were no clinically significant changes in any of the four variables used to evaluate maxillary growth in the Herbst group. This result is in agreement with that of McNamara et al,¹² who also found no significant restriction of maxillary growth in patients treated by the acrylic splint Herbst appliance for a period of 12

Table 3. Difference in Mean Changes (T_1 to T_2)

	Control			Herbst			Significance ^a
Cephalometric measures	n	Mean	SD	n	Mean	SD	
Maxillary skeletal							
SNA (°)	30	−0.4	1.3	30	−0.8	1.8	NS
Co-A (mm)	30	2.3	2.8	30	1.8	2.6	NS
A-FHp (mm)	30	0.8	1.6	30	0.1	1.7	NS
ANS-FHp (mm)	30	1.3	1.9	30	0.5	2.0	NS
Mandibular skeletal							
SNB (°)	30	−0.1	1.3	30	0.5	1.3	*
Ar-Go (mm)	30	1.5	1.8	30	2.9	2.2	*
Co-Gn (mm)	30	3.2	3.4	30	4.8	3.5	*
B-FHp (mm)	30	0.9	1.9	30	1.3	2.4	NS
Pog-FHp (mm)	30	1.1	1.8	30	1.3	2.7	NS
Maxillary/mandibular							
ANB (°)	30	−0.4	0.9	30	−1.4	1.2	**
Vertical skeletal							
SN.GoMe (°)	30	−0.3	1.7	30	0.1	2.1	NS
SN.PP (°)	30	0.7	1.3	30	0.9	2.4	NS
ANS to Me (mm)	30	1.4	1.7	30	2.1	1.9	NS
S-Go (mm)	30	2.7	2.1	30	3.4	2.5	NS
Maxillary dentoalveolar							
U1.NA (°)	30	0.6	3.8	30	−4.9	6.5	**
U1-NA (mm)	30	0.4	1.2	30	−1.1	1.9	**
U6-PP (mm)	30	1.1	1.1	30	0.7	1.2	*
Mandibular dentoalveolar							
IMPA (°)	30	1.0	2.9	30	5.0	6.1	**
L1.NB (°)	30	0.3	3.5	30	5.7	5.8	**
L1-NB (mm)	30	0.2	0.7	30	1.2	1.1	**
L6-GoMe (mm)	30	0.7	1.2	30	1.4	1.2	*

^a NS, not significant; * $P < .05$; ** $P < .01$.

months. A slight restriction of maxillary growth was noted by Croft et al,²⁴ who reported a decrease of 0.9° in the SNA angle in their mixed dentition patients. They concluded that the maxillary orthopedic effect of early treatment in their sample produced a 1.2-mm restraint on the sagittal displacement of point A. In other studies, long-term maxillary orthopedic effects reported for older Herbst patients, if evident, appeared to be only temporary in nature.^{5,8,11,23}

Mandibular skeletal

One of the key questions addressed in this study was the effect of the Herbst appliance on increases in mandibular length of children in the mixed dentition. Are the resulting increases in length similar in magnitude to those documented previously in adolescent Herbst patients?^{3,4,6,10,12,13,20,23} For example, significant short-term increases in the length of the mandible have been documented in adolescents by Pancherz (2.2 mm)^{3,6} and Windmiller (3.4 mm).¹³

Franchi et al²⁷ indicated a favorable and clinically significant mandibular increase produced by the acryl-

ic splint Herbst appliance when the patients began treatment at CVM stages 3 and 4 at the peak in mandibular growth. According to the CVM analysis²⁵ used in this prospective study, most of the patients started orthopedic treatment before the pubertal growth spurt and mandibular length increased slightly more (1.6 mm) in the Herbst group than in the controls. Based on sample size (30 subjects), however, with the standard deviation of the change in mandibular length (Co-Gn) of 3.5 mm and taking into consideration the calculation of the "power of the study" (a value that indicates the probability to assess false positive findings), the level for clinical significance for the supplementary increase in mandibular length in this study should be about 2.5 mm. The actual difference between treated subjects and controls of 1.6 mm (Co-Gn in Table 3), even if apparently significant, is not considered clinically relevant. Therefore, the results of this study indicate that the increases in mandibular length in patients treated with the Herbst appliance, although evident, are less in children for whom treatment was started before the circumpubertal growth period than in those entering adolescence.

This age-related difference in treatment response has been shown in previous studies of functional appliance therapy.²⁸⁻³² For example, McNamara et al²⁸ examined a large group of patients (N = 100) treated with the FR-2 appliance of Fränkel. Mandibular length increased by 6.4 mm during a two-year period in the younger age group (~8.5 years at the beginning of treatment) and 8.0 mm in the older age group (~11.5 years). Other studies also have indicated that a greater mandibular growth response is observed if Class II treatment is initiated during the circumpubertal growth period.^{2,29,31}

Vertical. As a result of the observed interplay of both anterior and posterior facial heights, the mandibular plane (SN-GoMe) was not affected significantly. Similar findings have been reported by other investigators.^{10,12,23,33,34} There was a similar tendency for a clockwise rotation of the palatal plane (SN-PP) noted during Herbst therapy compared with the control group, which did not adversely affect LAFH.

McNamara³⁵ has reported that without treatment an increase of about one mm/y in LAFH can be expected. Although an increase in LAFH was observed in both groups, there were no statistically significant differences between the control and treatment groups. This finding corroborates the results of Lai and McNamara,¹⁴ who found no significant effects on LAFH after therapy with the acrylic splint Herbst appliance or at the end of the two-phase treatment. However, Croft et al²⁴ and Pancherz³³ observed a similar increase of 1.8 mm in lower facial height during Herbst treatment. Posterior face height (S-Go) showed no differences between the groups.

Dentoalveolar

In this study, the treatment group showed a statistically significant retraction of the maxillary incisors. McNamara et al¹² reported that the upper incisors moved slightly lingually (1.4 mm) relative to the untreated controls, whereas Windmiller¹³ observed that the maxillary incisors tipped lingually 4.3°.

Significant proclination of the mandibular incisors was found in the Herbst group (5.7°), and the IMPA increased by 5.0°. This proclination of the mandibular incisors probably is a consequence of the resultant mesial force on the lower incisors induced by the telescoping mechanism of the Herbst appliance that produces a downward and forward vector of force. This observation corroborates the results of Pancherz,³ who found an increase in IMPA of 5.4°, and Valant and Sinclair,¹⁰ who found a 2.5° increase. Croft et al,²⁴ however, reported that treatment with the Herbst appliance did not produce a significant "flaring" effect on the lower incisors in their mixed dentition study that examined

both treatment and posttreatment effects. The latter observation is in agreement with others who found that lower incisor flaring tends to rebound after Herbst treatment is terminated^{8,36} and occurs less in younger individuals.¹⁷

In the untreated group in this study, the maxillary first molars erupted 1.1 mm, which was statistically different, but clinically insignificant from the Herbst (0.7 mm) group. Even larger effects were observed by Pancherz and Anehus-Pancherz¹¹ with an average intrusion of 0.7 mm during treatment. The consequence of such control of maxillary molar movement is that vertical eruption of the lower first molars (L6-GoMe) was greater in the functional appliance group (Herbst, 1.4 mm) in comparison with the controls (0.7 mm). This effect also has been reported by Windmiller.¹³

Clinical implications

The findings of the current prospective investigation, although limited to a specific developmental stage (mixed dentition) and evaluating only a one-year treatment interval, are in agreement with previous studies²⁰⁻²³ that suggested that the correction of a Class II division 1 malocclusion with the Herbst appliance is achieved by a combination of significant dentoalveolar changes as well as by maxillomandibular skeletal effects. In this study, the Herbst appliance produced more dentoalveolar than skeletal effects in patients treated in the mixed dentition period. The greater skeletal changes appear to be present when the treatment period includes the peak in mandibular growth.

Several clinicians^{28,37,38} have advised against using the Herbst appliance in the mixed dentition. von Bremen and Pancherz³⁷ recently reported that Class II division 1 treatment was more efficient in the permanent dentition. On assessing skeletal maturity (hand-wrist films) of Herbst patients, Ruf and Pancherz³⁸ found that the ideal period for Herbst treatment was in the permanent dentition at or just after the peak of pubertal growth.

McNamara et al²⁸ also recommended against the use of the Herbst appliance in the mixed dentition. He stated that although attaining a Class I relationship can be achieved with a number of functional appliances, maintaining the correction throughout the transition to the permanent dentition often proves difficult. A fully corrected Class II malocclusion can revert back to its original occlusal relationship without proper posttreatment stabilization during the transition to the permanent dentition.

CONCLUSIONS

The effects produced by the Herbst appliance in this study were:

- no statistically significant changes in forward growth of the maxilla;
- a modest, but statistically significant increase in mandibular length. This increase was less than that observed in adolescent Herbst patients in other studies;
- a significant improvement of the anteroposterior relationship between the maxillary and mandibular dentition;
- no statistically significant increase in LAFH;
- labial tipping and protrusion of the mandibular incisors as well as a lingual inclination and retrusion of the maxillary incisors;
- a significant increase in mandibular posterior dentoalveolar height and a slight extrusion of the upper molars.

REFERENCES

- McNamara JA Jr, Brudon WL. *Orthodontics and Dentofacial Orthopedics*. Ann Arbor, Mich: Needham Press, 2001.
- Faltin K Jr, Faltin RM, Baccetti T, Franchi L, Ghiozzi B, McNamara JA Jr. Long-term effectiveness and treatment timing for Bionator therapy. *Angle Orthod*. 2003;73:221–230.
- Pancherz H. Treatment of Class II malocclusions by jumping the bite with the Herbst appliance: a cephalometric investigation. *Am J Orthod*. 1979;76:423–442.
- Pancherz H. The Herbst appliance—its biologic effects and clinical use. *Am J Orthod*. 1985;87:1–20.
- Pancherz H. The effect of continuous bite jumping on the dentofacial complex: a follow-up study after Herbst appliance treatment of Class II malocclusions. *Eur J Orthod*. 1981;3:49–60.
- Pancherz H. The mechanism of Class II correction in Herbst appliance treatment: a cephalometric investigation. *Am J Orthod*. 1982;82:104–113.
- Pancherz H. The nature of Class II relapse after Herbst appliance treatment: a cephalometric long-term investigation. *Am J Orthod Dentofacial Orthop*. 1991;100:220–233.
- Pancherz H, Hansen K. Occlusal changes during and after Herbst treatment: a cephalometric investigation. *Eur J Orthod*. 1986;8:215–228.
- Hansen K, Pancherz H. Long-term effects of the Herbst appliance treatment in relation to normal growth development. *Eur J Orthod*. 1992;14:285–295.
- Valant JR, Sinclair PM. Treatment effects of the Herbst appliance. *Am J Orthod Dentofacial Orthop*. 1989;95:138–147.
- Pancherz H, Anehus-Pancherz M. The headgear effect of the Herbst appliance: a cephalometric long-term study. *Am J Orthod Dentofacial Orthop*. 1993;103:510–520.
- McNamara JA Jr, Howe RP, Dischinger TG. A comparison of the Herbst and Fränkel appliances in the treatment of Class II malocclusion. *Am J Orthod Dentofacial Orthop*. 1990;98:134–144.
- Windmiller EC. The acrylic-splint Herbst appliance: a cephalometric evaluation. *Am J Orthod Dentofacial Orthop*. 1993;104:73–84.
- Lai M, McNamara JA Jr. An evaluation of two phase treatment with the Herbst appliance and preadjusted edgewise therapy. *Semin Orthod*. 1998;4:46–58.
- Franchi L, Baccetti T, McNamara JA Jr. Treatment and posttreatment effects of acrylic splint Herbst appliance therapy. *Am J Orthod Dentofacial Orthop*. 1990;98:134–144.
- Bakke M, Paulsen HV. Herbst treatment in “late” adolescence: clinical electromyographic, kinesiographic and radiographic analysis of one case. *Eur J Orthod*. 1989;11:397–407.
- Hansen K, Pancherz H, Hägg U. Long term effects of the Herbst appliance in relation to the treatment growth period: a cephalometric study. *Eur J Orthod*. 1991;13:471–481.
- Konik M, Pancherz H, Hansen K. The mechanism of Class II correction in late Herbst treatment. *Am J Orthod Dentofacial Orthop*. 1997;112:87–91.
- Hägg U, Du X, Rabie ABM. Initial and late treatment effects of headgear-Herbst appliance with mandibular step-by-step advancement. *Am J Orthod Dentofacial Orthop*. 2002;122:477–485.
- Baltromejus S, Ruf S, Pancherz H. Effective temporomandibular joint growth and chin position changes: activator versus Herbst treatment. A cephalometric roentgenographic study. *Eur J Orthod*. 2002;14:627–637.
- Wieslander L. Intensive treatment of severe Class II malocclusions with a headgear-Herbst appliance in the “early” mixed dentition. *Am J Orthod*. 1984;86:1–13.
- Wieslander L. Long term effect of treatment with the headgear-Herbst appliance in the “early” mixed dentition: stability or relapse? *Am J Orthod Dentofacial Orthop*. 1993;104:319–329.
- Küçükköles N, Arun T. Bio-thermal Herbst application during the mixed dentition period. *J Clin Pediatr Dent*. 1994;18:253–258.
- Croft RS, Buschang PH, English JD, Meyer R. A cephalometric and tomographic evaluation of Herbst treatment in the mixed dentition. *Am J Orthod Dentofacial Orthop*. 1999;116:435–443.
- O'Reilly M, Yanniello GJ. Mandibular growth changes and maturation of cervical vertebrae—a longitudinal cephalometric study. *Angle Orthod*. 1988;58:179–184.
- Houston WJB. The analysis of errors in orthodontic measurements. *Am J Orthod*. 1983;83:382–390.
- Franchi L, Baccetti T, McNamara JA Jr. Treatment and posttreatment effects of acrylic splint Herbst appliance therapy. *Am J Orthod Dentofacial Orthop*. 1999;115:429–438.
- McNamara JA Jr, Bookstein FL, Shaughnessy TG. Skeletal and dental changes following functional regulator therapy on Class II patients. *Am J Orthod*. 1985;88:91–110.
- Baccetti T, Franchi L, Toth LR, McNamara JA Jr. Treatment timing for twin block therapy. *Am J Orthod Dentofacial Orthop*. 2000;118:159–170.
- Baccetti T, Franchi L. Maximizing esthetic and functional changes in Class II treatment by appropriate treatment timing. In: McNamara JA Jr, Kelly KA, eds. *Frontiers of Dental and Facial Esthetics*. Monograph 38, Craniofacial Growth Series. Ann Arbor, Mich: Department of Orthodontics and Pediatric Dentistry and Center for Human Growth and Development, University of Michigan; 2001; 237–251.
- Janson GRP, Toruño JLA, Martins DR, Henriques JFC, Freitas MR. Class II treatment effects of the Fränkel appliance. *Eur J Orthod*. 2003;25:301–309.
- Tulloch JFC, Phillips C, Proffit WR. Benefit of early Class II treatment: progress report of a two-phase randomized clin-

- ical study. *Am J Orthod Dentofacial Orthop*. 1998;113:62–72.
33. Pancherz H. Vertical dentofacial changes during Herbst appliance treatment: a cephalometric investigation. *Swed Dent J Suppl*. 1982;15:189–196.
34. Ruf S, Pancherz H. The effect of Herbst appliance treatment on the mandibular plane angle: a cephalometric roentgenographic study. *Am J Orthod Dentofacial Orthop*. 1996;110:225–229.
35. McNamara JA Jr. A method of cephalometric evaluation. *Am J Orthod*. 1984;86:449–469.
36. Pancherz H, Hansen K. Mandibular anchorage in Herbst treatment. *Eur J Orthod*. 1988;10:149–164.
37. von Bremen J, Pancherz H. Efficiency of early and late Class II division 1 treatment. *Am J Orthod Dentofacial Orthop*. 2002;121:31–37.
38. Ruf S, Pancherz H. When is the ideal period for Herbst therapy—early or late? *Semin Orthod*. 2003;9:47–56.