

The Relation between the Point of Force Application and Flaring of the Anterior Segment

E. van Steenbergena^a; C. J. Burstone^b; B. Prah Andersen^c;
I. H. A. Aartman^d

Abstract: The purpose of this study was to determine whether application of an intrusive force by an intrusion arch at the distal wings of the lateral incisor brackets causes a change in the axial inclination of the anterior segment. Maxillary incisor intrusion was performed, and records were taken from 40 adolescent patients at the beginning and end of intrusion. Intrusion of the maxillary anterior segment caused a statistically significant mean increase in axial inclination of the central incisor of 8.74°. The following correlations were investigated and found not statistically significant. The correlation between the (1) distance from the point of force application to the center of resistance at the start of intrusion and the change in axial inclination of the incisor, (2) distance from the point of force application to the center of resistance at the start of intrusion and the change in distance from the incisal edge to the distal side of the first molar, (3) distance from the point of intrusive force application to the center of resistance at the start of intrusion and at the end of intrusion, (4) distance from the point of intrusive force application to the center of resistance at the start of intrusion and the change in this distance between start and end of intrusion, and (5) amount of intrusion and the change in axial inclination. (*Angle Orthod* 2005;75:730–735.)

Key Words: Biomechanics; Incisor intrusion

INTRODUCTION

This study focused on correction of deep overbite by intrusion of maxillary central and lateral incisors and evaluated various options to decrease side effects and to increase efficiency with minimal dependence on patient cooperation.^{1,2} To date, very few clinical studies have focused on intrusion.^{3–5}

One investigation was performed to compare different methods of deep overbite correction.⁴ Other reports on intrusion were based on in vitro or laboratory studies^{1,6,7} and animal studies.^{8–10} Because intrusion is

often the preferred way of deep overbite correction, a randomized clinical trial focusing on all aspects related to intrusion is needed as a scientific basis for clinical study and to increase treatment efficiency. This part of the study evaluated the influence of the location of the point of force application on change in axial inclination of the maxillary anterior segment.

The location of the point of force application in relation to the center of resistance of the anterior segment can alter the axial inclination of that segment. A more anterior location of the point of force application causes flaring, whereas a more posterior location will cause uprighting of the anterior teeth.^{1,2,6,7,11} Studies on dry skulls have determined that the center of resistance for a segment of four maxillary incisors with a normal axial inclination lies apical of a point between the distal side of the canine⁶ and the distal side of the lateral incisor.⁷ Therefore, if an intrusion arch is attached at that point, the anterior segment, the incisors will move bodily in an apical direction. When the axial inclination of the incisors is different, so is the location of the center of resistance in relation to the position of the incisor crowns. More flared incisors should have a more distal point of force application through the center of resistance than retroclined incisors.⁷

The purpose of this study was to determine whether,

^a Private Practice, Apeldoorn, The Netherlands.

^b Professor Emeritus, Department of Orthodontics, University of Connecticut Health Center, Farmington, Conn.

^c Professor and Chairperson, Orthodontic Department, Academic Centre for Dentistry, Amsterdam, The Netherlands.

^d Assistant Professor, Methodologist, Department of Orthodontics and Social Dentistry, Section Social Dentistry and Dental Health Education, Academic Centre for Dentistry, Amsterdam, The Netherlands.

Corresponding author: E. van Steenberg, DDS, MDS, Orthodontiepraktijk Van Steenberg, Hofdwaarsstraat 1 c, 7311 KK Apeldoorn, The Netherlands (e-mail: ecbt@vansteenbergen.nl)

Accepted: December 2004. Submitted: November 2004.

© 2005 by The EH Angle Education and Research Foundation, Inc.

in patients with a normal axial inclination (within 2 SD) of the anterior segment, application of an intrusive force at the distal wings of the lateral incisor brackets causes a change in axial inclination of that segment. In this study, the following null hypotheses were tested.

Application of an intrusive force by tying the intrusion arch at the distal wings of the lateral incisor brackets onto the anterior segment causes no change in axial inclination of that segment while it is being intruded.

There is no correlation between the distance from the point of force application to the center of resistance of the maxillary anterior segment at the start of intrusion and the change in axial inclination of the anterior segment.

There is no correlation between the distance from the point of force application to the center of resistance of the maxillary anterior segment at the start of intrusion and the change in distance from the incisal edge to the first molar between start and end of intrusion.

There is no correlation between the distance from the point of force application to the center of resistance of the maxillary anterior segment at the start of intrusion and at the end of intrusion.

There is no correlation between the distance from the point of force application to the center of resistance of the maxillary anterior segment at the start of intrusion and the change in this distance between the start and end of intrusion.

There is no correlation between the amount of intrusion and the change in axial inclination of the anterior segment.

MATERIALS AND METHODS

Sample

Orthodontic patients needing maxillary central and lateral incisor intrusion of at least two mm were recruited for this study from all patients referred to the principal investigator's practice. Treatment was performed by Dr. Van Steenberghe only.

Patients included in the sample had at least maxillary first molars, first and second premolars, canines, and all maxillary incisors present and fully erupted and were between nine and 14 years of age. Patients with extremely flared or upright (such as in Class II division 2 patients) incisors were excluded as well as patients with periodontal disease. Patients with crowding to the extent that they needed extractions to perform alignment were also excluded. No other form of orthodontic treatment was performed in these patients during the time of maxillary incisor intrusion. All patients willing to participate in this study were included in the sample if

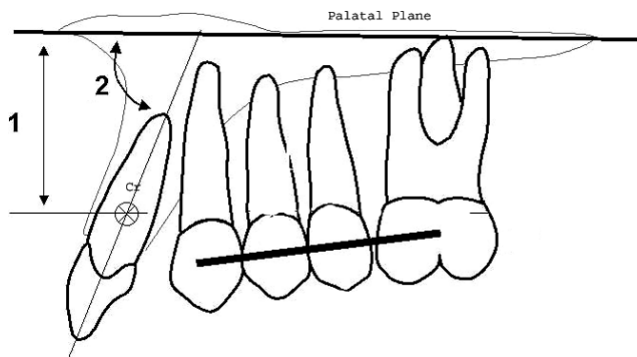


FIGURE 1. Incisor intrusion and axial inclination.

they met the above-mentioned requirements. During a four-year period, 40 patients were recruited.

Records

A lateral cephalometric radiograph, one set of impressions with a wax bite in centric occlusion, and intraoral photographs were taken of each patient at the start of intrusion and when intrusion of the four maxillary incisors was completed (approved by the Medical Ethical Committee of the University Hospital, Amsterdam, The Netherlands). The lateral cephalograms were taken with the aid of a cephalostat by the principal investigator. The patient's head position in the cephalostat was documented by recording the positions of the ear rods and nasal rest, so that pre- and postintrusion cephalograms were taken with the patient's head in the same position. To distinguish the patient's right and left side, a ligature wire was tied around the right canine bracket in such a way that it was clearly visible on the lateral cephalogram. Impressions were poured in plaster and trimmed in centric occlusion.

Measurements

Lateral cephalograms were traced on a computer screen and on acetate paper.¹² From each set of lateral cephalograms, a maxillary superimposition (structural) was made.¹³ The tracings were digitized and analyses performed by computer¹⁴ using the Quick Ceph Image program (Quick Ceph Systems, San Diego, Calif). The following measurements were performed.

1. Vertical movement of the center of resistance of the maxillary central incisor (indicating the amount of intrusion); vertical means perpendicular to the palatal plane (Figure 1, measurement 1). The center of resistance of the central incisor was selected instead of the center of resistance of the anterior segment because of its easier and therefore more reliable and reproducible location. Because of the ri-

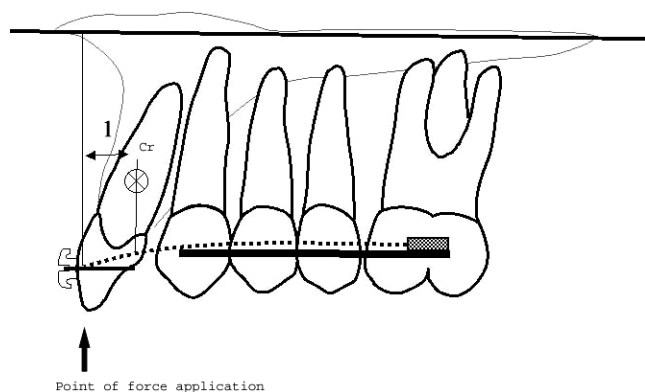


FIGURE 2. Distance between the point of force application to the center of resistance.

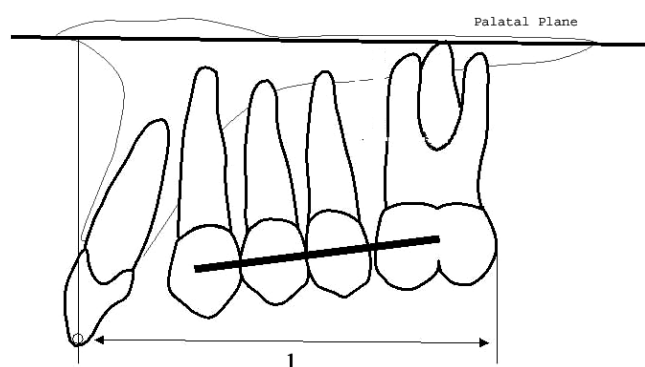


FIGURE 3. Distance from incisal edge to first molar.

gidity of the anterior segment, the displacement of the center of resistance of the central incisor is a good representation of the displacement of the center of resistance of the anterior segment.

2. Axial inclination of the anterior segment in the sagittal plane, which was determined by measuring the angle between the central incisor and the palatal plane (Figure 1, measurement 2).
3. Distance from the point of intrusive force application to the center of resistance of the central incisor. The greater this distance, the greater the chance of incisor flaring (Figure 2, measurement 1).
4. Distance from the incisal edge to the distal side of the maxillary first molar (Figure 3, measurement 1). This measurement in the sagittal plane indicates the amount of flaring of the maxillary incisor in combination with distal tipping of the buccal segment.

To make the measurement error as small as possible, the digital image was enlarged to the extent that the crosshair symbol used for landmark identification was much smaller than the enlarged landmark itself. The next step was to make tracings on acetate paper, make digital images of these tracings and of the cephalograms directly, and trace both. To make the superimpositions more reliable, it was decided to make

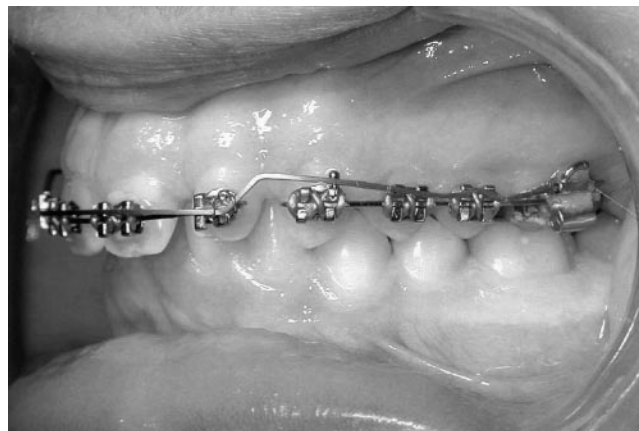

FIGURE 4. Patient at the start of intrusion.

structural superimpositions on maxillary skeletal structures, which were made using the tracings on acetate. This has the clear advantage over the computer superimposition because the complete outlines of the skeletal structures are used and not just a few digitized points. This method was checked independently by re-analyzing the start and end cephalograms of 10 patients. The mean differences between both measurements varied from 0.01° for the angular measurement between the central incisor and the palatal plane and 0.01 mm between the distance from the auxiliary tube to the point of intrusive force application to 0.24 mm for the distance between the incisal edge and the maxillary first molar. None of the differences were statistically significant.

Treatment protocol

Patients were recruited after an explanation of the treatment plan by the orthodontist. First, bands and brackets were placed and segments aligned. Alignment was performed in segments, the anterior segment extending from right to left lateral incisor and the buccal segment from canine to first molar.

When the wire segments were rigid and passive, one lateral cephalogram, five intraoral photographs (one frontal, two buccal, and two occlusal photographs), and one set of impressions with a wax bite in centric occlusion were taken. To be certain that the segments were passive, they were left in place for five weeks after insertion before records were taken and intrusion was started. At the same visit the intrusion arch was placed (Figure 4).

Visits were scheduled every five weeks. During each visit, the intrusive force was measured, recorded, and, when necessary, adjusted to the proper level. When the incisors were intruded to the proper level, the intrusion arch was removed, and a lateral cepha-

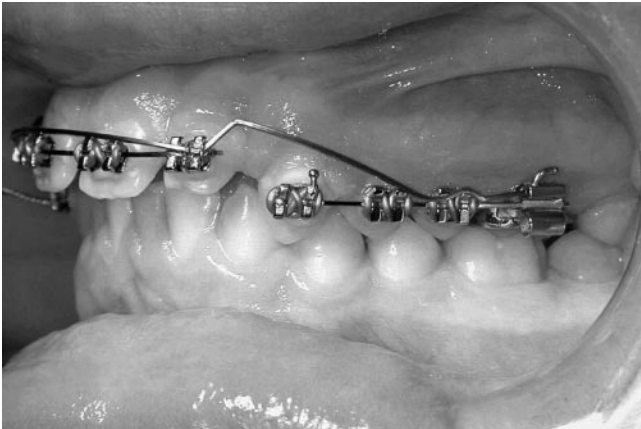

FIGURE 5. Patient at the end of intrusion.

TABLE 1. Change in Axial Inclination of the Maxillary Central Incisor

	Mean	SD
Incisor angulation at start (°)	71.03	6.09
Incisor angulation at end (°)	62.30	7.05
Incisor angulation change (°)	8.74	3.71

logram, impressions, and wax bite were taken (Figure 5). The same actions were undertaken when side effects were clearly present. Loose bands and brackets were recorded and replaced in such a manner that the segment remained passive.

To test the null hypotheses (see Introduction), Pearson’s product moment correlation coefficients (*r*; two-tailed) were calculated.^{15,16}

RESULTS

Table 1 demonstrates that the maxillary central incisor flared a mean of 8.74°, which was statistically significant (*P* < .001). Null hypothesis one was therefore rejected.

There was no statistically significant correlation between the distance from the point of force application to the center of resistance of the incisor at the moment when the intrusion was started and the change in axial inclination of the incisor between the start and end of intrusion (Table 2). Null hypothesis two was therefore accepted.

The correlation between the distance from the point of force application to the center of resistance of the maxillary anterior segment at the start of intrusion and the change in distance from the incisal edge to the first molar between start and end of intrusion was not statistically significant (Table 2). Null hypothesis three was therefore accepted. The mean distance from the point of force application to the center of resistance of

TABLE 2. Pearson’s Product Moment Correlation Coefficients (*r*) With the Significance in Parentheses (two-tailed)^a

	D pF-Cr	D Mx1-PP	D Mx1-Mx6
pF-Cr	0.16 (0.31)	0.11 (0.49)	−0.15 (0.37)
Mx1-PP		0.03 (0.88)	
D Cr-PP		−0.20 (0.21)	

^a pF-Cr indicates distance from the point of force application to the center of resistance of maxillary central incisor; D pF-Cr, change in distance from the point of force application to the center of resistance of maxillary central incisor; Mx1-PP, angle between the central incisor and the palatal plane; D Mx1-PP, change in angle between the central incisor and the palatal plane; Cr-PP, distance from the center of resistance of the central incisor to the palatal plane; D Cr-PP, change in distance from the center of resistance of the central incisor to the palatal plane; Mx1-Mx6, distance from incisal edge to the distal side of the first molar; and D Mx1-Mx6, change in distance from incisal edge to the distal side of the first molar.

the maxillary central incisor was 2.1 mm (SD 1.56) at the start of intrusion.

The correlation between the distance from the point of force application to the center of resistance at the start and at the end of intrusion was not statistically significant (Table 2), which resulted in the acceptance of null hypothesis four.

The correlation between the distance from the point of force application to the center of resistance of the central incisor at the start of intrusion and the change in this distance between start and end of intrusion was not statistically significant (Table 2). Null hypothesis five was therefore accepted.

There was no statistically significant correlation between the amount of intrusion and the change in axial inclination of the central incisor (Table 2). Therefore, null hypothesis six was also accepted.

DISCUSSION

According to the studies on dry skulls, the center of resistance for a segment of four maxillary incisors with a normal axial inclination lies apical of a point between the distal side of the canine⁶ and the distal side of the lateral incisor.⁷ In this study, a one-piece intrusion arch was used.^{1,2} The most distal point of force application is at the distal side of the lateral incisor bracket, which is approximately three mm anterior to the distal side of the lateral incisor. This study evaluated the clinical effects of the selection of this point of force application. The mean axial inclination of the central incisor increased a statistically significant 8.74° (Table 1). It was no surprise that this increase in axial inclination occurred because the point of force application was anterior to the center of resistance, as determined by both dry skull studies.^{6,7}

On the basis of this finding, it would be logical to assume that the larger the distance from the point of

force application to the center of resistance at the start of intrusion, the larger would be the change in axial inclination of the central incisor between the start and end of intrusion. An increase in axial inclination would increase the distance between the point of force application and the center of resistance.^{1,2}

The second hypothesis described the correlations between the distance from the point of force application to the center of resistance of the maxillary incisor and the change in axial inclination. The third hypothesis described the correlations between the distance from the point of force application to the center of resistance of the maxillary incisor and the distance from incisal edge to first molar. In case the incisor was flared, this distance would increase. The fourth hypothesis described the correlations between the distance from the point of force application to the center of resistance of the maxillary incisor and the distance from the point of force application to the center of resistance at the end of intrusion. The fifth hypothesis described the correlations between the distance from the point of force application to the center of resistance of the maxillary incisor and the change in distance from the point of force application to the center of resistance between start and end of intrusion.

In this study, none of the correlations, as tested for the second through the fifth hypothesis, were statistically significant. The most likely explanation for finding no statistically significant differences within the sample is that, in this sample, the axial inclination at the start of intrusion was normal. The differences in distance between the point of force application and the center of resistance were therefore small within the sample and caused no statistically significant differences in axial inclination and incisal edge position.

Each patient included in this study needed a minimum of two mm intrusion of the maxillary anterior segment. This was determined from the initial records. The decision to stop intruding the maxillary incisors was made clinically by observing the overbite. When incisors are flared, the overbite decreases.^{1,2,4} The amount of intrusion in this study is defined by the vertical movement in cranial direction of the center of resistance of the maxillary central incisor. On the basis of the assumption that an increase in axial inclination of the incisors can be related to a decrease in vertical movement of the center of resistance, the correlation between the amount of incisor intrusion and the change in incisor axial inclination was measured and found not statistically significant.

In a clinical situation where maxillary incisor intrusion is desired and the incisor axial inclination can be increased, incisor intrusion can be performed with a one-piece intrusion arch with the point of force application at the distal side of the lateral incisor bracket.

If an increase in axial inclination is not desired, the clinician should change the point of force application in the distal direction.

CONCLUSIONS

- Intrusion of the maxillary anterior segment by application of the intrusive force at the distal side of the lateral incisor bracket caused a statistically significant mean increase in axial inclination of the central incisor of 8° to 9°.
- There was no statistically significant correlation between the distance from the point of intrusive force application to the center of resistance at the start of intrusion and the change in axial inclination of the incisor.
- No statistically significant correlation was found between the distance from the point of intrusive force application to the center of resistance at the start of intrusion and the change in distance from the incisal edge to the distal side of the first molar.
- There was no statistically significant correlation between the distance from the point of intrusive force application to the center of resistance at the start of intrusion and at the end of intrusion.
- No statistically significant correlation between the distance from the point of intrusive force application to the center of resistance at the start of intrusion and the change in this distance between start and end of intrusion was found in this study.
- There was no statistically significant correlation between the amount of intrusion and the change in axial inclination.

REFERENCES

1. Burstone CJ. Deep overbite correction by intrusion. *Am J Orthod.* 1977;72:1–22.
2. Burstone CJ. Biomechanics of deep overbite correction. *Semin Orthod.* 2001;7(1):26–33.
3. van Steenberg E, Burstone CJ, Prahl-Andersen B, Aartman IHA. The role of a high pull headgear in counteracting side effects from intrusion of the maxillary anterior segment. *Angle Orthod.* 2004;74:480–486.
4. Weiland FJ, Bantleon HP, Droschl H. Evaluation of continuous arch and segmented arch leveling techniques in adult patients—a clinical study. *Am J Orthod Dentofacial Orthop.* 1996;110(6):647–652.
5. Melsen B, Agerbæk N, Markenstam G. Intrusion of incisors in adult patients with marginal bone loss. *Am J Orthod Dentofacial Orthop.* 1989;96(3):232–241.
6. Vanden Bulcke M, Sachdeva R, Burstone CJ. The center of resistance of anterior teeth during intrusion using the laser reflection technique and holographic interferometry. *Am J Orthod.* 1986;90(3):211–219.
7. Dermout LR, Vanden Bulcke MM. Evaluation of intrusive mechanics of the type “segmented arch” on a macerated human skull using the laser reflection technique and holographic interferometry. *Am J Orthod Dentofacial Orthop.* 1986;89(3):251–263.

8. Dellinger EL. A histological and cephalometric investigation of premolar intrusion in the macaca speciosa monkey. *Am J Orthod.* 1967;53:325–355.
9. Steigman S, Michaeli Y. Experimental intrusion of rat incisors with continuous loads of varying magnitude. *Am J Orthod.* 1981;80(4):429–436.
10. Woods MG. The mechanics of lower incisor intrusion: experiments in nongrowing baboons. *Am J Orthod Dentofacial Orthop.* 1988;93(3):186–195.
11. Burstone CJ, Pryputniewicz RJ. Holographic determination of centers of rotation produced by orthodontic forces. *Am J Orthod.* 1980;77:396.
12. Baumrind S, Frantz R. The reliability of headfilm measurements: 1 landmark identification. *Am J Orthod.* 1971;60:111–127.
13. Baumrind S. The reliability of headfilm measurements: 2 linear and angular measurements. *Am J Orthod.* 1971;60:506–517.
14. Baumrind S, Miller D, Molthen R. The reliability of headfilm measurements: 3 tracing superimpositions. *Am J Orthod.* 1976;70(6):617–644.
15. Faber R, Burstone CJ, Solonche DJ. System of computerized treatment planning. *Am J Orthod.* 1978;73(1):36–46.
16. Altman DG. *Practical Statistics for Medical Research.* London: Chapman & Hall; 1991:278–286.
17. Pocock SJ. *Clinical Trials, a Practical Approach.* Chichester, UK: Wiley & Sons; 1984:73–76.