

An Interdisciplinary Approach for Improved Functional and Esthetic Results in a Periodontally Compromised Adult Patient

Xingmei Feng^a; Tomoko Oba^b; Yasuo Oba^c; Keiji Moriyama^d

Abstract: In contemporary dental care, an increasing number of adult patients are seeking orthodontic treatment. In such adult patients, a combined orthodontic and other specialized therapy often offers the best option for achieving a predictable outcome to solve complex clinical problems. This case report demonstrates a combined therapy with orthodontic, periodontic, and implant-prosthetic treatments in a 56-year six-month-old female patient with mild diastemata in the maxillary anterior region and a missing left maxillary second premolar caused by a periodontal disease with medium bone loss. The patient had improved her oral hygiene condition through periodontal treatment before orthodontic treatment. The patient was orthodontically treated with a maxillary lingual arch and a maxillary edgewise orthodontic appliance. Active orthodontic treatment was completed in 18 months, and an implant-supported prosthesis was placed with a single crown in the region of the left maxillary second premolar. The treatment outcomes, including the periodontal condition and the dental implant treatment, were stable at two years after the active orthodontic treatment. We demonstrate that combined orthodontic-periodontic-implant-prosthetic treatment can achieve an improved masticatory function, esthetics, occlusion, and periodontal condition. (*Angle Orthod* 2005;75:1061–1070.)

Key Words: Adult orthodontics; Interdisciplinary treatment; Periodontally compromised patient; Implant-supported prosthesis

INTRODUCTION

Dentofacial esthetics is of great concern in the adult population, with an increasing demand for orthodontic treatment in appearance-conscious adults.¹ In this

group of patients the primary motivating factor is a desire to improve their dental appearance.^{2,3}

However, special attention must be given to the periodontal status of adults because they are more likely to be susceptible to or have already suffered from periodontal disease. Periodontal disease and its sequelae such as a diastema or a missing tooth often lead to functional and unesthetic problems, either alone or with other restorative problems.⁴ Advanced periodontal disease is primarily characterized as severe attachment loss and reduction of alveolar bony support. The periodontal condition is usually present as tooth mobility, migration, spacing, and marginal gingival recession. Particularly in the maxillary anterior region, functional discomfort is usually accompanied by compromised esthetics. Orthodontic treatment for realignment of migrated periodontally involved teeth is initiated only after control of the periodontal inflammation has been achieved.^{5,6} A long healing period and radiographic evidence of bone apposition are required before initiation of the orthodontic tooth movement.⁷

If the patient is reasonably motivated and responds well to the initial periodontal therapy, adult orthodontic

^a Visiting researcher, Department of Orthodontics and Dentofacial Orthopedics, Institute of Health Biosciences, The University of Tokushima Graduate School, Tokushima, Japan.

^b Research Associate, Department of Orthodontics and Dentofacial Orthopedics, Institute of Health Biosciences, The University of Tokushima Graduate School, Tokushima, Japan.

^c Assistant Professor, Department of Orthodontics and Dentofacial Orthopedics, Institute of Health Biosciences, The University of Tokushima Graduate School, Tokushima, Japan.

^d Professor and Chairman, Department of Orthodontics and Dentofacial Orthopedics, Institute of Health Biosciences, The University of Tokushima Graduate School, Tokushima, Japan.

Corresponding author: Keiji Moriyama, DDS, PhD, Department of Orthodontics and Dentofacial Orthopedics, Institute of Health Biosciences, The University of Tokushima Graduate School, 3-18-15 Kuramoto-cho, Tokushima 770-8504, Japan (e-mail: moriyama@dent.tokushima-u.ac.jp)

Accepted: September 2004. Submitted: May 2004.

© 2005 by The EH Angle Education and Research Foundation, Inc.

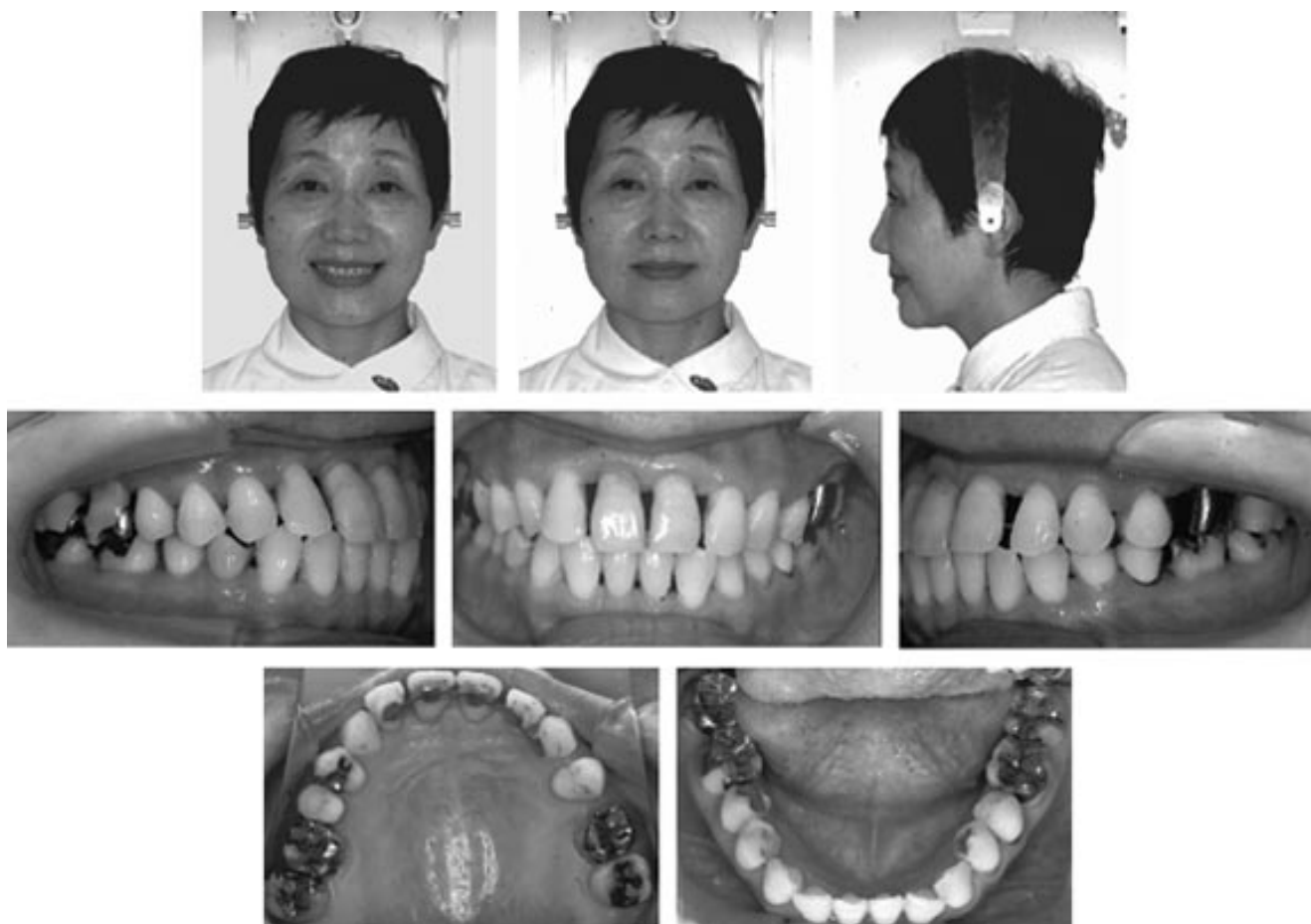

FIGURE 1. Pretreatment photographs, age 56 years six months.

therapy has a role in providing complete rehabilitation in terms of both function and appearance with a satisfactory long-term prognosis.⁸ Good oral hygiene at home and professional maintenance visits are important during and after active orthodontic treatment.

In this periodontally compromised case, a successful result was achieved. During active orthodontic treatment, attention was paid to the option for the use of segmented mechanics. A simple lingual arch designed with finger springs and an edgewise appliance with segmented mechanics were used to allow for good oral hygiene and periodontal health. This article presents a modified orthodontic-periodontic-implant-prosthetic approach that was applied for restoration of function and appearance.

CASE HISTORY

A 56-year six-month-old female patient presented for orthodontic treatment with a periodontally compromised dentition, medium diastemata in the maxillary anterior region, and a missing maxillary left second premolar. The patient's chief complaint was to improve her esthetics because her maxillary "teeth were

spaced and did not look good." Her maxillary left second premolar was extracted because of periodontal disease more than 10 years ago.

The patient first visited the periodontal clinic of our university hospital because of the mobility of a maxillary central incisor when she was 55 years of age. She was trained in personal oral hygiene and placed on periodontal maintenance care with professional cleaning, scaling, root planing, and curettage once a month for 1.5 years. When the periodontal inflammation was improved, the patient received treatment to stabilize the maxillary incisors and the canine with a fixed lingual wire. At the time of referral from the periodontal clinic, she had successfully completed the periodontal treatment and had received intensive oral hygiene instructions.

Case summary

Pretreatment facial photographs showed a symmetrical facial pattern with a straight profile (Figure 1). The maxillary dental midline deviated 1.5 mm toward the left. The molar relationship was Class I on both sides. Several diastemata were present in the maxillary an-

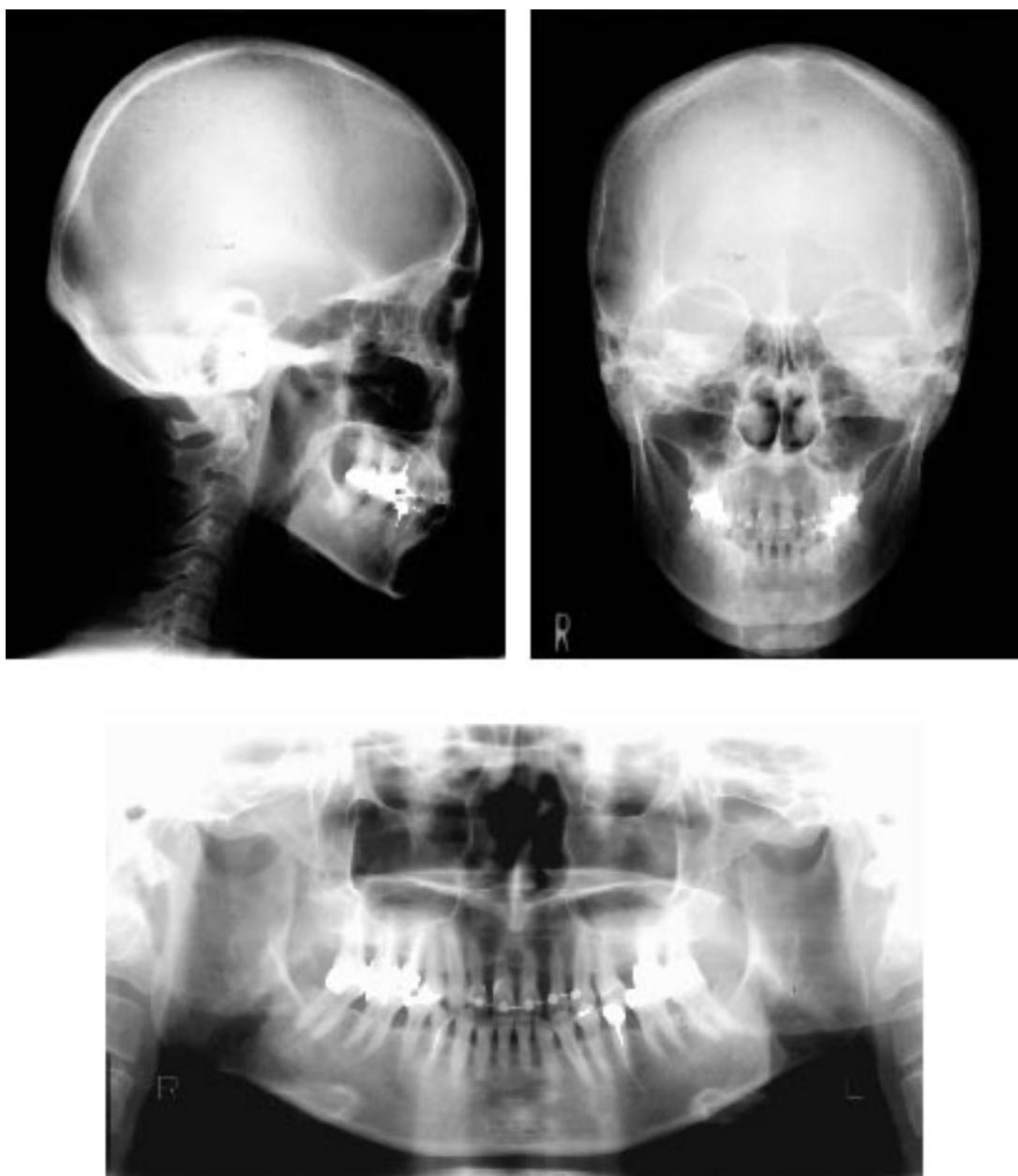

FIGURE 2. Pretreatment radiographs.

terior region as was a lateral anterior crossbite on the left (Figure 1). Spaces were present on the mesial and distal sides of the maxillary left first premolar because of the missing maxillary left second premolar. A lingual fixed wire bonded to the five maxillary anterior teeth was present. The mandibular anterior teeth were mildly crowded. The dentition showed generalized gingival recession but with no pockets greater than three mm and normal mobility. Radiographic examination revealed generalized moderate bone loss (Figure 2). No signs or symptoms of temporomandibular disorder were noted despite the occlusal dysfunction due to the missing maxillary left second premolar.

In the lateral cephalometric radiograph, the mandible and maxilla were normally positioned relative to Japanese standards⁹ (SNA 83.8, SNB 80.0, ANB 3.8), and showed a skeletal Class I relationship (Table 1). The mandibular plane angle and inclination of the incisors were also normal relative to the Japanese standards (FMA 25.8, U1 to SN plane angle 102.2, IMPA 98.5).

Diagnosis and treatment objectives

The patient was diagnosed as demonstrating a spaced maxillary arch caused by the periodontal dis-

TABLE 1. Lateral Cephalometric Analysis

Measurements (Angular: degrees)	Pretreatment (56 y 6 mo)	Posttreatment (58 y 2 mo)	Postretention (60 y 2 mo)	Standard (Normal Japanese Female Adult)	SD
SNA	78.4	78.6	78.5	82.3	3.5
SNB	75.3	75.8	75.8	78.9	3.5
ANB	3.1	2.8	2.7	3.4	1.8
FMA	28.6	28.1	28.3	28.8	5.2
FMIA	54.3	54.1	54.1	54.6	6.5
IMPA	97.1	97.8	97.6	96.3	5.8
U1-SN	97.1	98.8	97.9	104.5	5.6

ease and the missing maxillary left second premolar with a skeletal Class I jaw relationship. Prognosis of her periodontitis was good. The patient did not express concern regarding the crowded mandibular teeth, and she did not wish to have an appliance placed in the mandible. On discussing the options, the patient agreed to undergo periodontic-orthodontic treatment in an effort to restore function and appearance with an appliance for only the maxilla. The treatment objectives were (1) to correct the maxillary dental midline, (2) to close the space of the maxillary arch and to regain the space in the region of the maxillary left second premolar, (3) to achieve an acceptable occlusion, and (4) to restore esthetics.

Treatment progress

Before the start of the orthodontic treatment, the maxillary lingual fixed wire was removed from the right incisors and the left central incisor to move these teeth to the right. During the first phase of the treatment, the maxillary lingual arch was placed when the patient was 56 years eight months old, and the movements of the maxillary incisors were initiated (Figure 3A). Finger springs with a light force (50 g) were used for the movement of the maxillary incisors to the right and for movement of the maxillary left lateral incisor to the labial side.

During the second phase of the treatment, the rest of the maxillary lingual fixed wire was removed, and the maxillary left lateral incisors and maxillary left canine were moved to the mesial (Figure 3B). To prevent recurrence of the periodontitis and to encourage proper oral hygiene, the patient was carefully monitored by the orthodontist and periodontist.

During the third phase of the treatment, when the patient was 57 years one month old, edgewise orthodontic appliances (0.018 × 0.025 inch) were placed from the maxillary left canine to the maxillary left first molar for the mesial movement of the maxillary left first premolar (Figure 3C–E). The maxillary teeth were leveled with segmented arches, starting with 0.012-inch nickel-titanium archwire and working up to 0.016- × 0.016-inch stainless steel archwire. An opening coil

was used for the mesial movement of the maxillary left first premolar.

During the fourth phase of the treatment, when the patient was 57 years eight months old, the same type of transparent brackets were bonded from the maxillary right first premolar to the maxillary left lateral incisor (Figure 3F,G). The maxillary teeth were leveled with continuous archwires, restarting with 0.012-inch nickel-titanium and working up to 0.016- × 0.016-inch stainless steel. During the active orthodontic treatment, the patient was remotivated and periodontally maintained by the dental hygienist on a monthly basis.

Active orthodontic treatment was completed in 18 months when the patient was 58 years two months old. The maxillary lingual arch and the edgewise orthodontic appliances were removed, and fixed lingual retainers and a wrap-around retainer were placed on the maxilla. After six months of the active orthodontic treatment, an ad modum Brånemark (Nobel Biocare, Göteborg, Sweden) implant was inserted in the region of the maxillary left second premolar. After a healing period of seven months, provisional implant-supported restorations were installed in the region of the maxillary left second premolar. For definitive prosthetic restoration, an implant-supported prosthesis was placed with a single crown when the patient was 59 years five months old.

RESULTS

The posttreatment intraoral photographs show a Class I canine relationship with acceptable overbite and overjet (Figures 4 and 5). Diastemata in the maxillary anterior region and the lateral anterior crossbite on the left side were eliminated, and the maxillary dental midline was corrected. Clinical examination revealed a well-functioning anterior dentition, natural in appearance and in a harmonious occlusion and periodontal state of health. Radiographic examination revealed a favorable root/crown ratio (Figure 5). In the lateral cephalometrics, no significant skeletal changes were seen during the active orthodontic treatment period (Figure 6; Table 1). The labial inclination of the

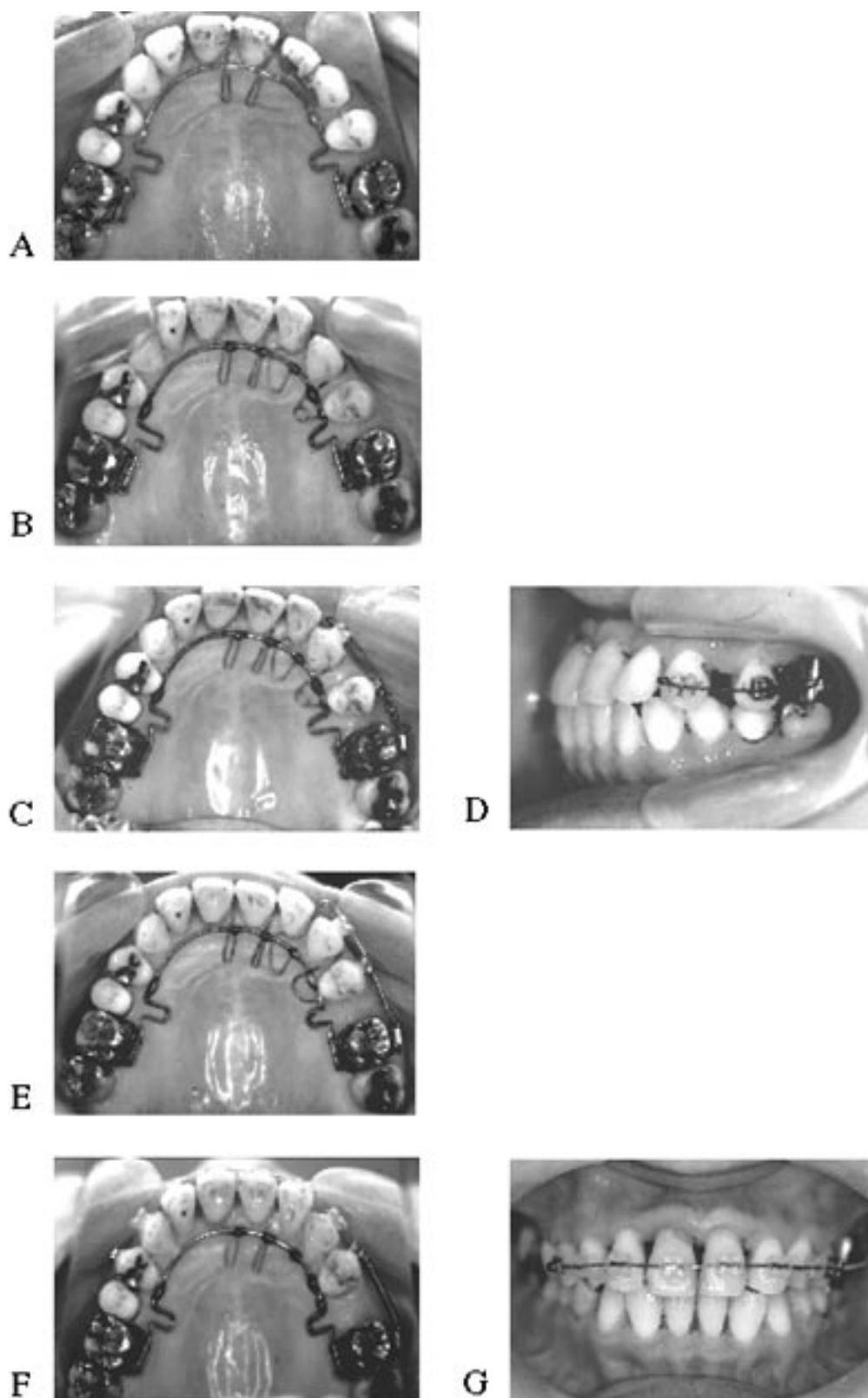


FIGURE 3. Photographs taken during treatment progress. (A) Movement of maxillary central incisors with finger springs. (B) Movement of maxillary left lateral incisor and canine with finger springs. (C, D, E) Movement of maxillary left first premolar with segmented appliance. (F, G) Leveling from maxillary right first premolar to maxillary left first molar.

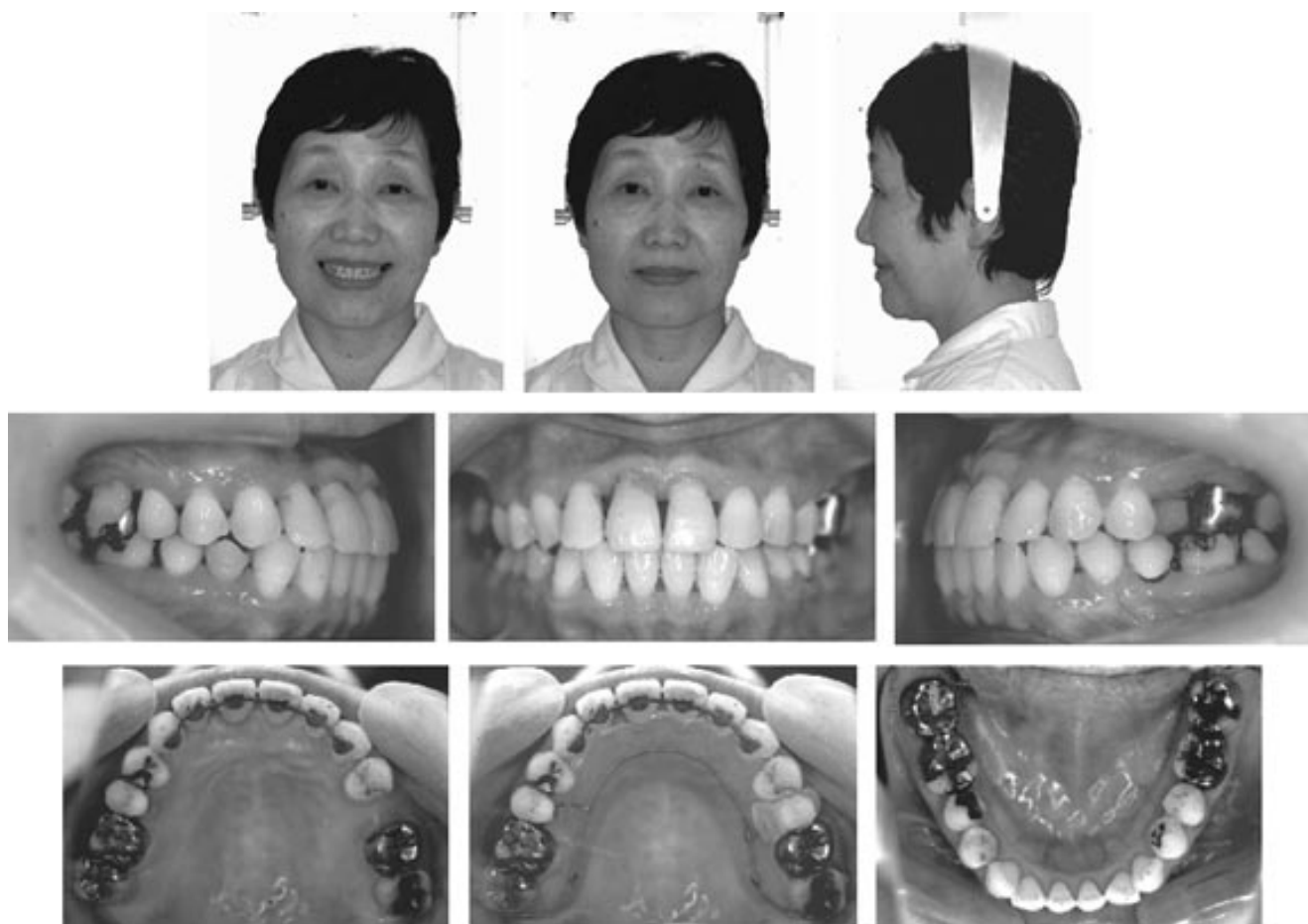

FIGURE 4. Posttreatment photographs, age 58 years two months.

maxillary incisors was increased slightly (Figure 6; Table 1).

Patient cooperation in maintenance of oral hygiene was excellent, and the examination at two years after active orthodontic treatment follow-up revealed that the clinical status and radiographic results observed at the completion of the treatment had been maintained (Figures 7 and 8; Table 1). The patient was satisfied with the results of the orthodontic-implant-prosthetic treatment.

DISCUSSION

Orthodontic treatment is no longer a contraindication in the therapy of severe adult periodontal disease in the maintenance of a healthy periodontal status after orthodontic treatment.¹⁰ In such cases, orthodontic treatment might enhance the possibilities of saving and restoring a deteriorated dentition. Thus, orthodontic treatment planning for any malocclusion will involve determining the method of the tooth movement, which sometimes results in an unusual tooth alignment. It is important to identify patients who are susceptible to the more severe manifestation of the disease and to

control an existing disease before starting a treatment plan involving comprehensive orthodontics.¹¹

In the present case, we used segmented mechanics with a lingual arch appliance and an edgewise orthodontic appliance. Tipping movements of teeth were performed by the finger springs of a lingual arch appliance, and then bodily movements of teeth were performed by the wires in an edgewise orthodontic appliance. These statically determinate orthodontic appliances lead to a successful result. The force system of segmented mechanics easily delivers predictable forces throughout a treatment and achieves an optimum biologic response.¹² This includes rapid tooth movement with a minimum lowering of the pain threshold.

Tissue damage, particularly root resorption, should be kept to a minimum. The root length and the nature of the periodontal support will influence the force system. During active orthodontic treatment, attention was paid to the optimal force magnitudes of the springs and the wires, which stimulated bone formation in the periodontium.¹³ Simple wire designs without complicated loops were used as much as possible to allow easier access to the teeth for oral hygiene purposes.

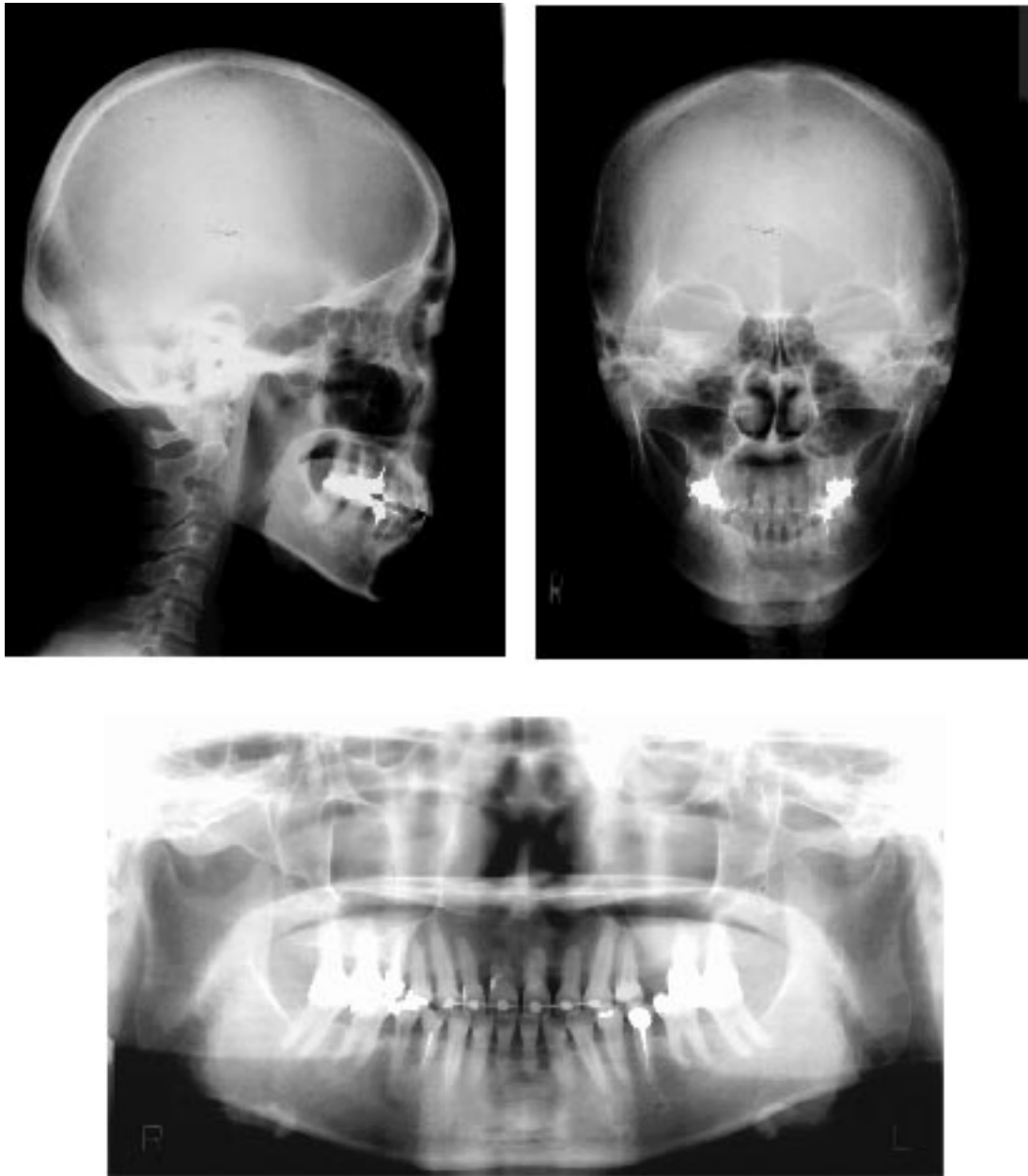

FIGURE 5. Posttreatment radiographs.

Periodontal treatment and the patient's cooperation in oral hygiene were also continued as supportive therapy. Previous reports have demonstrated that, with adequate plaque control, teeth with reduced periodontal support can undergo successful tooth movement without compromising their periodontal situation.¹⁴⁻¹⁶

In the present case, initial periodontal conditions were improved by scaling and root planing before the start of the orthodontic treatment. If this had not been done, an orthodontically applied force could enhance the gingival inflammation and could be destructive. Clinical examinations during postactive orthodontic treatment have demonstrated that reduced periodontal

support can undergo successful tooth movement without compromising their periodontal situation. Because the patient did not recently show any tooth mobility or dental relapse, a proper functional environment and the maintenance of oral hygiene could be attributable to the stable occlusion.

Implant-supported prostheses kept separate from natural teeth are considered the preferred definitive replacement for both single and multiple missing teeth.^{17,18} In the present case, after careful planning by an interdisciplinary team, a small unit restoration with a separate single crown implant-prosthesis was used to maintain optimal tactile sensibility of the natural

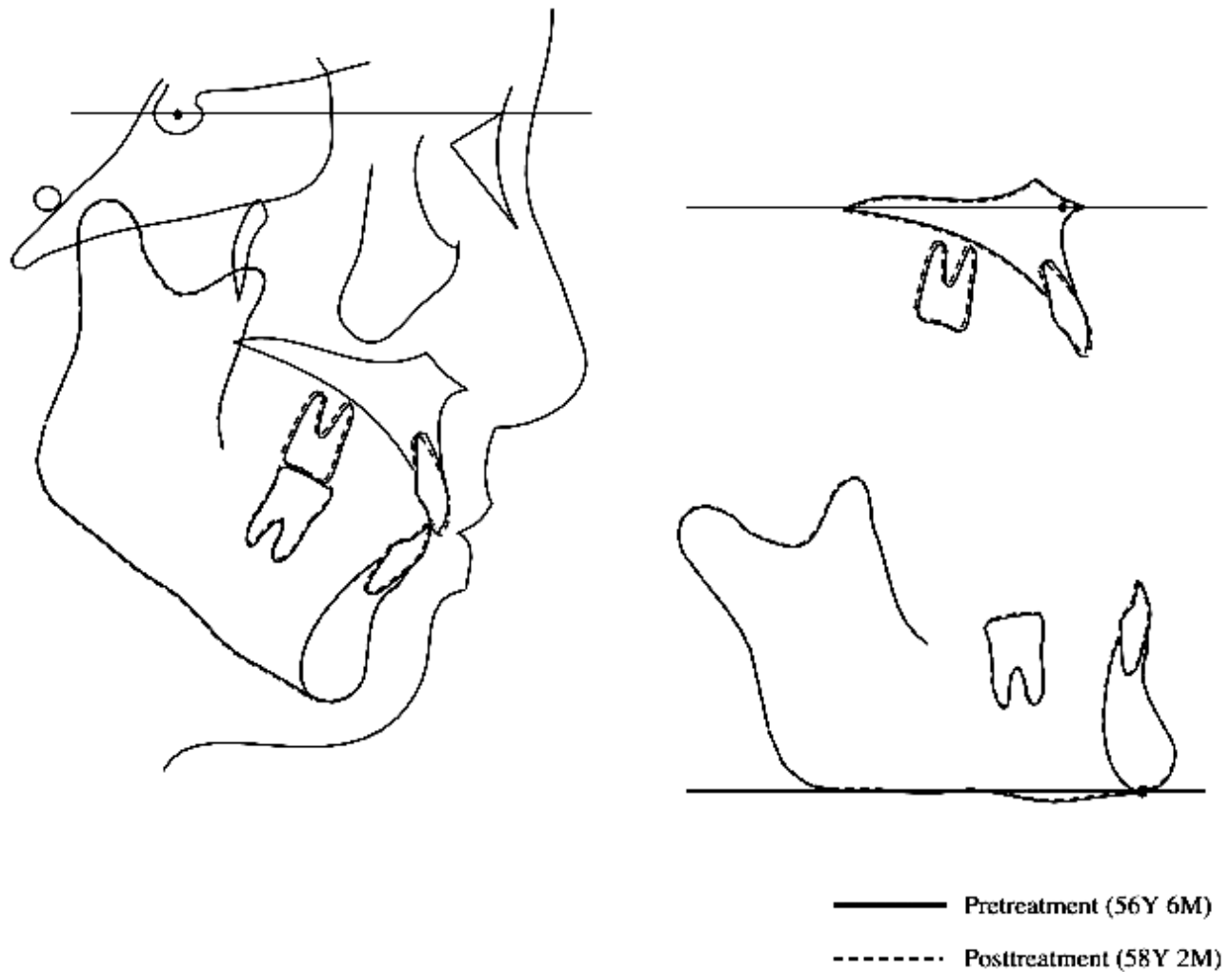


FIGURE 6. Superimposition of cephalometric tracings. Pretreatment tracing (solid line) was superimposed with posttreatment tracing (dotted line). (A) Superimposition on the Sella-Nasion plane at Sella. (B) Superimposition on the ANS-PNS plane at ANS. (C) Superimposition on the mandibular plane at Menton.

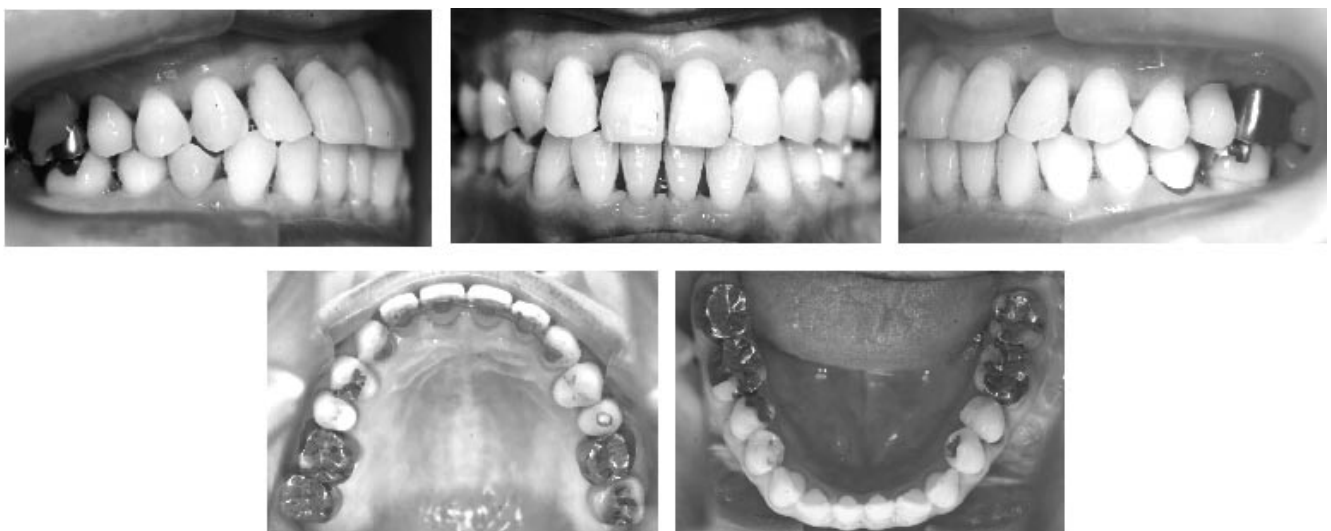

FIGURE 7. Postretention intraoral photographs, age 60 years two months.

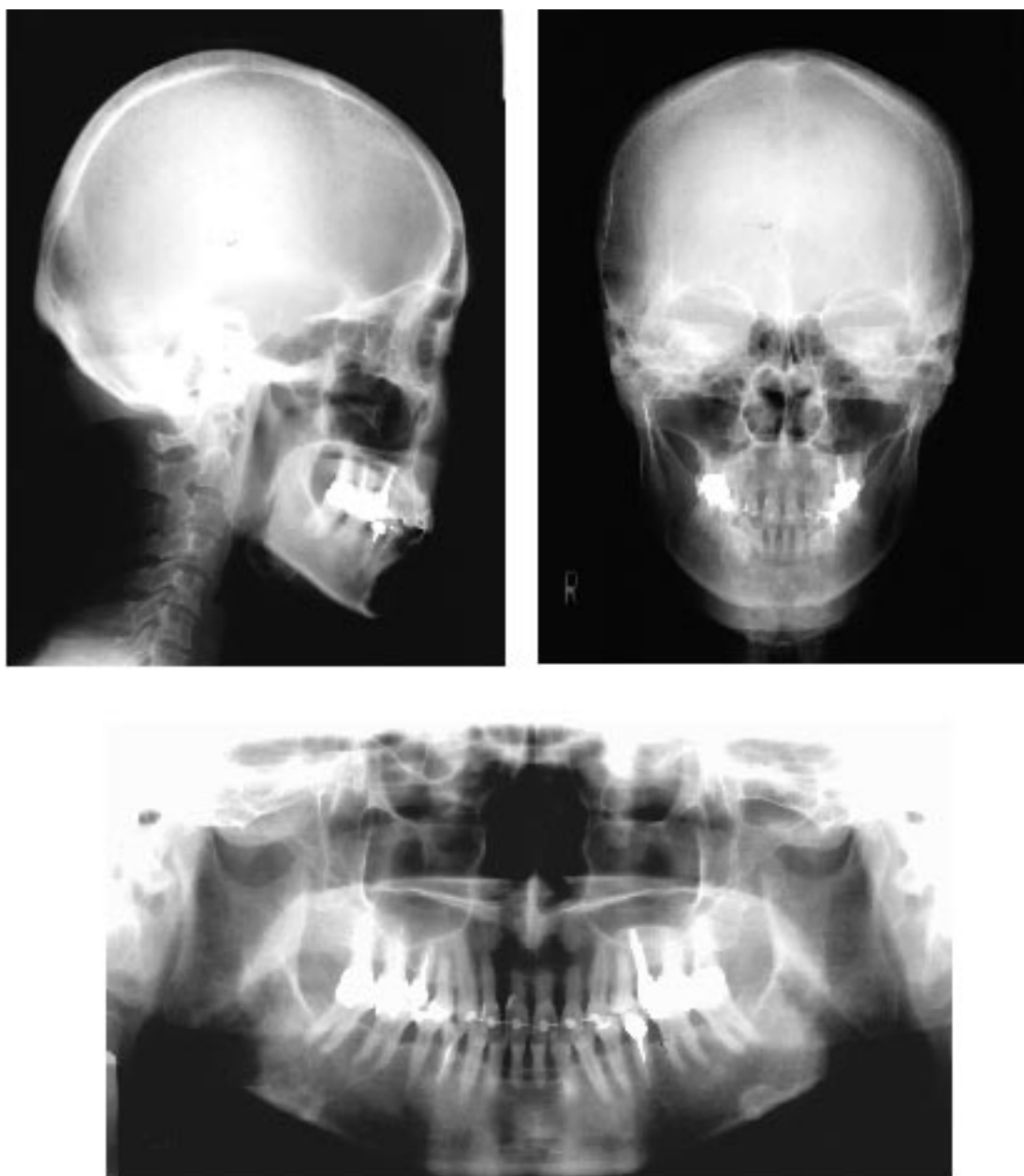

FIGURE 8. Postretention radiographs.

teeth and to create favorable conditions for oral function and hygiene maintenance.

In the periodontally compromised adult patient cases, such as this case, a close interdisciplinary approach is critical for successful outcomes. Advanced orthodontic-periodontic-implant-prosthetic treatment may result not only in the restoration of function to the periodontally involved dentition but also a marked improvement in esthetics. This article demonstrates the value of a multidisciplinary approach in therapeutic treatment and restoration of a periodontally compromised dentition to achieve long-lasting functional and esthetic results.

ACKNOWLEDGMENT

Dr Feng was supported by the Tokushima Prefectural Overseas Technical Trainees Aid Program.

REFERENCES

1. Proffit W. Special considerations in comprehensive treatment for adults. In: Proffit W, Fields HW, eds. *Contemporary Orthodontics*. 3rd ed. St Louis, Mo: Mosby; 2000:644–674.
2. McKiernan EX, McKiernan F, Jones ML. Psychological profiles and motives of adults seeking orthodontic treatment. *Int J Adult Orthod Orthognath Surg*. 1992;7:187–198.
3. Claman L, Alfaro MA, Mercado AM. An interdisciplinary approach for improved esthetic results in the anterior maxilla. *J Prosthet Dent*. 2003;89:1–5.

4. Kalia S, Melsen B. Interdisciplinary approaches to adult orthodontic care. *J Orthod.* 2001;28:191–196.
5. Marks M. Tooth movement in periodontal therapy. In: Goldman H, Cohen D, eds. *Periodontal Therapy*. 6th ed. St Louis, Mo: Mosby; 1980:565–568.
6. Romano R, Landsberg CJ. Reconstruction of function and aesthetics of the maxillary anterior region: a combined periodontal/orthodontic therapy. *Pract Periodont Aesthetic Dent.* 1996;8:353–361.
7. Viazis AD, Corinaldesi G, Abramson MM. Gingival recession and fenestration in orthodontic treatment: a case report. *J Clin Orthod.* 1990;98:633–636.
8. Melsen B, Agerbaek N, Markenstam G. Intrusion of incisors in adult patients with marginal bone loss. *Am J Orthod Dentofacial Orthop.* 1989;96:232–241.
9. Wada K, Matsushita K, Shimazaki S, Miwa Y, Hasuike Y, Susami R. An evaluation of a new case analysis of a lateral cephalometric roentgenogram. *J Kanazawa Med Univ.* 1981;6:60–70.
10. Re S, Corrente RS, Abundo G, Cardaropoli D. Orthodontic treatment in periodontally compromised patients: 12-year report. *Int J Periodontics Restorative Dent.* 2000;20:31–39.
11. Ong MMA, Wang HL. Periodontic and orthodontic treatment in adults. *Am J Orthod Dentofacial Orthop.* 2002;122:420–428.
12. Melsen B, Agerbaek N, Erikson J, Terp S. New attachment through periodontal treatment and orthodontic intrusion. *Am J Orthod Dentofacial Orthop.* 1988;94:104–116.
13. McLain JB, Proffit WR, Davenport RH. Adjunctive orthodontic therapy in the treatment of juvenile periodontitis: report of a case and review of the literature. *Am J Orthod.* 1983;83:290–298.
14. Eliasson L, Hugoson A, Kurol J, Siwe H. The effects of orthodontic treatment on periodontal tissues in patients with reduced periodontal support. *Eur J Orthod.* 1982;4:1–9.
15. Wagenberg BD. Periodontal preparation of the adult patient prior to orthodontics. *Dent Clin North Am.* 1988;32:457–480.
16. Boyd RL, Leggot PJ, Quinn RS, Eakle WS, Chambers DW. Periodontal implications of orthodontic treatment in adults with reduced or normal periodontal tissues versus those of adolescents. *Am J Orthod Dentofacial Orthop.* 1989;96:191–198.
17. Jepson NJ, Nohl FS, Carter NE, Gillgrass TJ, Meechan JG, Hobson RG, Nunn JH. The interdisciplinary management of hypodontia: restorative dentistry. *Br Dent J.* 2003;194:299–304.
18. Knabe C, Schendel KU. The use of implant-supported titanium prostheses for treatment of periodontally compromised patients including functional and orthodontic therapy. *Clin Oral Implants Res.* 1997;8:332–338.