

Arch Width Changes in Extraction and Nonextraction Treatment in Class I Patients

Muge Aksu^a; Ilken Kocadereli^b

Abstract: The aim of this retrospective study was to examine the dental arch width changes of extraction and nonextraction treatment in Class I patients. The study was performed on pretreatment and posttreatment dental casts of 60 patients (30 extraction and 30 nonextraction). The mean ages were 14.3 ± 2.02 years for the extraction group and 14.1 ± 2.9 years for the nonextraction group. The maxillary and mandibular crowding was -6.7 ± 3.1 and -6.3 ± 2.8 mm for the extraction group and -4.5 ± 3.6 and -2.1 ± 3.5 mm for the nonextraction group, respectively. The intercanine and intermolar arch width measurements were measured using a digital caliper. Paired samples *t*-test was used to evaluate the treatment changes within each group. To compare the changes between groups, independent samples *t*-test was performed. At the start of treatment, the maxillary and the mandibular intercanine and intermolar widths of both groups did not differ statistically. At the end of treatment, maxillary and mandibular intercanine widths of both groups increased significantly. The mandibular intermolar width decreased significantly for the extraction group and the maxillary intermolar width increased significantly for the nonextraction group. The decrease in maxillary intermolar width for the extraction group and the increase in mandibular intermolar width for the nonextraction group were not significantly different. No differences were observed between the groups in maxillary and mandibular intercanine widths. Maxillary and mandibular intermolar width indicated a significantly larger value in the nonextraction group than that in the extraction group. (*Angle Orthod* 2005;75:948–952.)

Key Words: Arch width changes; Extraction vs nonextraction

INTRODUCTION

Transverse or vertical arch malrelationships such as crowding and local irregularities are common causes of Class I malocclusions and are handled usually by extraction or nonextraction treatment in the permanent dentition. Considerable controversy still surrounds the question of whether better long-term results are achieved by extraction or by nonextraction therapy.

It is well established that increases in dental arch length and width during orthodontic treatment tend to return toward pretreatment values after retention.^{1–4} An undocumented criticism of extraction treatment is that

it results in narrower dental arches when compared with nonextraction therapy.⁵ Nonextraction treatments have gained widespread popularity because of the condylar displacement, narrowed smiles accompanied by dark corners, dished-in profiles with extractions, and suboptimal mandibular growth.^{6–13}

Some researchers have documented that arch dimensional changes occur both with the orthodontic treatment after the extraction of teeth and with the nonextraction therapy.^{14,15}

The maintenance of the pretreatment values for intercanine and intermolar distances was suggested as the key to posttreatment stability because these values were believed to represent a position of muscular balance for the patient.^{16,17} It has been suggested that in extraction cases the canines could be moved to the buccal if they were moved distally into the extraction sites, thereby occupying a wider part of the arch.¹⁸ However, subsequent studies have not found the stability of expansion in the canine region to differ between extraction and nonextraction cases.^{10,19–21}

Strang¹⁶ and Shapiro² concluded that the mandibular intercanine and intermolar width dimensions show

^a Assistant Professor, Department of Orthodontics, Faculty of Dentistry, Hacettepe University, Sıhhiye, Ankara, Turkey.

^b Professor and Head, Department of Orthodontics, Faculty of Dentistry, Hacettepe University, Sıhhiye, Ankara, Turkey.

Corresponding author: Muge Aksu, DDS, PhD, Department of Orthodontics, Faculty of Dentistry, Hacettepe University, Sıhhiye, Ankara 06100, Turkey (e-mail: mugepeh@hacettepe.edu.tr)

Accepted: December 2004. Submitted: November 2004.

© 2005 by The EH Angle Education and Research Foundation, Inc.

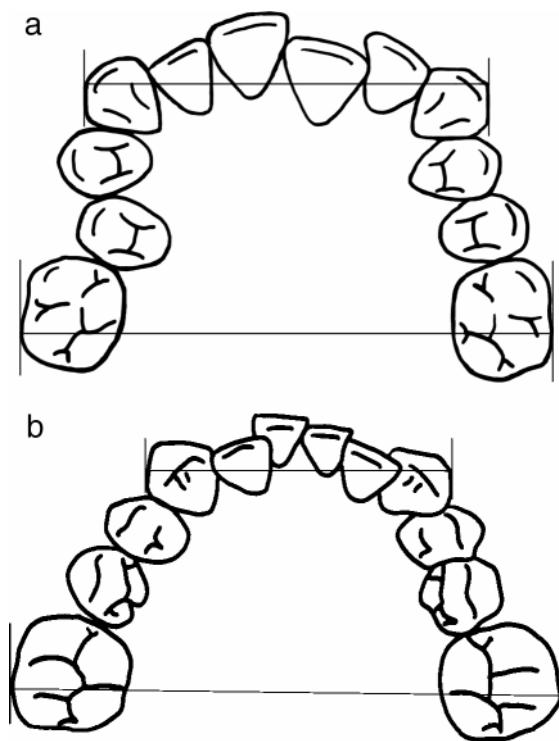


FIGURE 1. (A) Maxillary interarch measurements. (B) Mandibular interarch measurements.

a strong tendency to relapse and should be considered inviolate. Although the literature has provided information regarding the effects of extraction and nonextraction therapy, the findings on the amount of interarch changes of Class I extraction and nonextraction therapy display variation. This may be attributed to the differing treatment modalities, malocclusion types, and sample sizes. Therefore, an attempt was made in this study to have a homogenous study group in terms of malocclusion type and treatment mechanics.

The purpose of this study was to compare the dental arch width changes of Angle Class I malocclusion after both nonextraction and four first premolar extraction therapies and to determine the changes in arch widths because of treatment.

MATERIALS AND METHODS

A sample of 60 orthodontic patients (30 extraction and 30 nonextraction) was included in this retrospective study. The extraction group consisted of 19 girls and 11 boys, and the nonextraction group consisted of 18 girls and 12 boys. The mean ages of the study groups at the beginning of orthodontic treatment was 14.1 ± 2.9 years for the nonextraction group and 14.3 ± 2.02 years for the extraction group. Mean treatment time was 26.7 ± 7.1 months for the nonextraction group and 27.8 ± 8.3 months for the extraction group.

The maxillary tooth size arch length discrepancies were -6.7 ± 3.1 mm for the extraction group and -4.5 ± 3.6 mm for the nonextraction group. At pretreatment, the mandibular tooth size arch length discrepancies were -6.3 ± 2.8 mm for the extraction group and -2.1 ± 3.5 mm for the nonextraction group.

All the patients were treated by Dr Aksu and Dr Kocadereli at a university clinic. The patients who were treated by fixed edgewise appliances were selected on the basis of the following criteria.

1. All patients had skeletal Class I malocclusion.
2. At the start of treatment, all patients were in the permanent dentition without any missing permanent teeth or congenitally absent teeth.
3. None of the patients had any adjunctive appliance such as a Quad Helix, a functional appliance, or a rapid palatal expander used as part of their orthodontic treatment.
4. The patients whose treatment involved extraction had undergone four first premolar extractions as part of a comprehensive orthodontic treatment plan.

The intercanine and intermolar widths of the maxillary and mandibular dental arches were measured using a digital caliper (Sylvac, Fowler, OPTO-RS232 SIMPLEX/DUPLEX, Sweden). The widths of the anterior and posterior parts of the maxillary and mandibular dental arches were measured at the canine and the first molar regions from the most labial aspect of the buccal surfaces of those teeth, as described by Gianelly.⁵ The caliper was placed at the best estimate of a right angle to the palatal suture in the maxillary arch and to a line bisecting the incisor segment in the mandibular arch (Figure 1). Each distance was measured three times, and the average of the three values was used as the final measure.

All statistical analyses were performed using the SPSS software package (SPSS for Windows 98, version 10.0, SPSS Inc, Chicago, Ill). For each variable, the arithmetic mean and standard deviation were calculated. A paired samples *t*-test was used to evaluate the treatment changes within each group. To compare the changes observed in both groups, independent samples *t*-test was performed. Thirty study models were selected randomly and remeasured by the same examiner. Random error was calculated using Dahlberg's formula²² ($\text{Method Error} = \sqrt{(\sum d^2)/2n}$) where *d* is the difference in measurements of model values on two different occasions and *n* is the number of double recordings. Method error of the measurements ranged from 0.27 mm to 0.41 mm.

RESULTS

At the start of treatment, the maxillary and the mandibular intercanine and intermolar widths of both

TABLE 1. Comparison of Pretreatment Maxillary and Mandibular Inter canine and Intermolar Arch Widths (mm)^a

	Extraction (n = 30)	Nonextraction (n = 30)	<i>P</i> [*]
	Mean ± SD	Mean ± SD	
Maxillary intercanine width	39.23 ± 2.74	39.51 ± 2.45	NS
Maxillary intermolar width	55.33 ± 2.34	55.74 ± 2.94	NS
Mandibular intercanine width	31.74 ± 2.21	31.44 ± 1.58	NS
Mandibular intermolar width	53.13 ± 2.53	54.15 ± 2.37	NS

^a NS indicates not significant; SD, standard deviation.^{*} *P* < .05.**TABLE 2.** Pretreatment and Posttreatment Maxillary and Mandibular Inter canine and Intermolar Arch Width Averages and Standard Deviations (SD) (mm)^a

		Extraction (n = 30)	<i>P</i>	Nonextraction (n = 30)	<i>P</i>
		Mean ± SD		Mean ± SD	
Maxillary intercanine width	T1	39.23 ± 2.74	.001*	39.51 ± 2.45	.012*
	T2	40.70 ± 1.65		40.36 ± 1.98	
Maxillary intermolar width	T1	55.33 ± 2.34	NS	55.74 ± 2.94	.001*
	T2	53.19 ± 9.39		57.19 ± 2.96	
Mandibular intercanine width	T1	31.74 ± 2.21	.00*	31.44 ± 1.58	.002*
	T2	33.37 ± 1.30		32.46 ± 1.56	
Mandibular intermolar width	T1	53.13 ± 2.53	.00*	54.15 ± 2.37	NS
	T2	52.20 ± 2.45		54.74 ± 2.37	

^a NS indicates not significant; SD, standard deviation.^{*} *P* < .05.**TABLE 3.** Comparison of Posttreatment Maxillary and Mandibular Inter canine and Intermolar Arch Widths (mm)^a

	Extraction (n = 30)	Nonextraction (n = 30)	<i>P</i>
	Mean ± SD	Mean ± SD	
Maxillary intercanine width	40.70 ± 1.65	40.36 ± 1.98	NS
Maxillary intermolar width	53.19 ± 9.39	57.19 ± 2.96	.04*
Mandibular intercanine width	33.37 ± 1.30	32.46 ± 1.56	NS
Mandibular intermolar width	52.20 ± 2.45	54.74 ± 2.37	.00*

^a NS indicates not significant; SD, standard deviation.^{*} *P* < .05.

groups did not differ statistically (Table 1). At the end of treatment, the maxillary and mandibular intercanine arch widths of both groups had increased significantly (1.47 ± 2.11 , 1.63 ± 1.79 mm for the extraction group and 0.85 ± 1.71 , 1.02 ± 1.64 mm for the nonextraction group, respectively) ($P < .05$) (Table 2). The decrease in mandibular intermolar width for the extraction group (-0.93 ± 1.29 mm) and the increase in maxillary intermolar width for the nonextraction group (1.45 ± 2.25 mm) were statistically significant ($P < .05$) (Table 2). The decrease in maxillary intermolar width in the extraction group (-2.14 ± 8.9 mm) and the increases in mandibular intermolar width in the nonextraction group were not statistically significant (0.59 ± 1.80 mm, $P > .05$) (Table 2).

The comparison of the treatment changes for extraction and nonextraction Class I groups is shown in Table 3. No differences were observed between the

groups in maxillary and mandibular intercanine widths ($P > .05$) (Table 3). In addition, maxillary and mandibular intermolar width indicated a significantly larger value in the nonextraction group than that in the extraction group ($P < .05$).

DISCUSSION

It is well accepted that, during orthodontic treatment involving the extraction of teeth, arch dimensional changes occur and that these dimensions continue to change after active treatment.^{10,12,14,15,23}

Riedel¹⁷ stated that arch form, particularly in the mandibular arch, could not be altered by appliance therapy. Inter canine and intermolar widths tend to decrease during the postretention period, especially when expanded during treatment.^{2,16,17,24,25}

In this study, the arch width measurements in the

extraction and nonextraction Class I patients were examined. The data of this study revealed that intercanine arch widths increased regardless of the treatment modalities. However, the intermolar widths showed some differences. In the extraction group, there was no statistically significant difference in maxillary intermolar width but the decrease in mandibular intermolar width was statistically significant ($P < .05$) (Table 2). In the nonextraction group, there was a statistically significant increase in the maxillary intermolar width but there was no significant change in the mandibular intermolar width.

Weinberg and Sadowsky,²⁶ in a retrospective study of Class I malocclusion-treated nonextraction, found significant increases in the mandibular intercanine and intermolar arch widths and stated that the resolution of the crowding in the nonextraction therapy of Class I malocclusion was achieved by expansion of the buccal segments in mandibular arch. However, among the 30 patients participating in that study, 16 received some kind of palatal expander, which might cause expansion in the mandibular arch. Similar to that study, mandibular intercanine width increased significantly in the nonextraction group in this study. The increase in the mandibular intercanine width in nonextraction patients can be explained by minimal expansion with the archwires.

In a long-term stability study of a random sample of cases treated with nonextraction, Glenn et al²⁷ found that the mandibular intercanine width increased after treatment among the 14 patients with Class I malocclusions. Their findings are in accordance with the results of this study.

In the study of Boley et al,²⁸ the interarch changes of four premolar extraction cases were evaluated. According to their findings, maxillary intercanine widths increased one mm and the corresponding mandibular arch width increased 1.7 mm during treatment. Maxillary and mandibular intermolar widths decreased 1.7 and 2.1 mm, respectively. These findings are in accordance with the work of this study.

Despite the similar results given in these three mentioned studies,^{26–28} the study groups included either extraction or nonextraction modalities, but the differences found are of importance for this study.

This study shows that in either extraction- or nonextraction-treated cases, the intercanine widths increased significantly. Luppanapornlarp and Johnston¹² also evaluated the posttreatment results of extraction and nonextraction therapy in Class II patients and showed that mandibular intercanine width was greater in the extraction group than in the nonextraction group. In a recent study, Gianelly⁵ studied the interarch changes of extraction and nonextraction groups. He found that the changes in the maxillary and mandibular

arch widths indicated that extraction treatment does not result in narrower dental arches than nonextraction treatment. However, the group included in that study was not homogenous and the distribution of malocclusions was not the same in the extraction or nonextraction groups. Thus, the results reported in Gianelly's study⁵ might be influenced by the wide range of individual variation.

Bishara et al²⁹ studied the long-term stability of extraction and nonextraction orthodontic treatment and found that during the treatment the maxillary intercanine width of the males increased significantly in the extraction group because of the alignment of the crowded anterior segment. However, they did not mention the initial tooth size arch length discrepancies of the study group. The maxillary and mandibular intermolar widths increased in the nonextraction group and decreased in the extraction group. The intercanine and intermolar width findings are similar to the findings of this study, although the malocclusion types differed between the two studies.

On the basis of the concepts documented in the literature,^{10,29,30} one might have expected to find narrower arches after extraction. In contrast to all these findings, Kim and Gianelly³¹ suggested that the widths of both arches of the extraction subjects were 1–2 mm larger when compared with the arch widths of the nonextraction group at a standardized arch depth.

Another important consideration in arch widths is the tooth size arch length discrepancy. Studies of extraction vs nonextraction pretreatment variables have reported that the tooth size arch length discrepancy is the most significant factor influencing the extraction decision.^{29,32} However, tooth size arch length discrepancies have been considered not to have any effect on dental arch width changes in many studies.^{5,10,12,30,31,33} In this study, there was more crowding in the extraction group (–6.7 mm for the maxilla and –6.3 mm for the mandible) than in nonextraction group (–4.5 mm for the maxilla and –2.1 mm for the mandible). The results showed that after extraction treatment, lower posterior teeth moved mesially into narrower parts of the arch, indicating that anchorage requirements were kept moderate. In the nonextraction group, because of less tooth size arch length discrepancy, the crowding might be treated mostly by the movements of the anterior teeth. The results of this study confirm that extraction treatment does not result in narrower dental arches than nonextraction treatment.

CONCLUSIONS

- Intercanine arch widths increased both in the extraction and nonextraction Class I patients.

- In the extraction group, maxillary intermolar widths did not show any significant difference whereas the decreases in mandibular intermolar width were statistically significant.
- In the nonextraction group, maxillary intermolar widths increased significantly but there was no statistically significant change in the mandibular intermolar width.

REFERENCES

1. Steadman SR. Changes of intermolar and intercuspid distances following orthodontic treatment. *Angle Orthod.* 1961; 31:207–215.
2. Shapiro PA. Mandibular arch form and dimension. *Am J Orthod.* 1974;66:58–70.
3. Johnson KC. Cases six years postretention. *Angle Orthod.* 1977;47:210–221.
4. Little RM, Wallen TR, Riedel RA. Stability and relapse of mandibular anterior alignment-first premolar extraction cases treated by edgewise orthodontics. *Am J Orthod.* 1981; 80:349–365.
5. Gianelly AA. Arch width after extraction and nonextraction treatment. *Am J Orthod Dentofacial Orthop.* 2003;123:25–28.
6. Sadowsky C. The risk of orthodontic treatment for producing temporomandibular mandibular disorders: a literature overview. *Am J Orthod Dentofacial Orthop.* 1992;101:79–83.
7. Luecke PE III, Johnston LE Jr. The effect of maxillary first premolar extraction and incisor retraction on mandibular position: testing the central dogma of “functional orthodontics.” *Am J Orthod Dentofacial Orthop.* 1992;101:4–12.
8. McNamara JA Jr, Seligman DA, Okeson JP. Occlusion, orthodontic treatment, and temporomandibular disorders: a review. *J Orofac Pain.* 1995;9:73–90.
9. Johnson DK, Smith RJ. Smile esthetics after orthodontic treatment with and without extraction of four first premolars. *Am J Orthod Dentofacial Orthop.* 1995;108:162–167.
10. Paquette DE, Beattie JR, Johnston LE Jr. A long-term comparison of nonextraction and premolar extraction edgewise therapy in “borderline” Class II patients. *Am J Orthod Dentofacial Orthop.* 1992;102:1–14.
11. Beattie JR, Paquette DE, Johnston LE Jr. The functional impact of extraction and nonextraction treatments: a long-term comparison in patients with “borderline,” equally susceptible Class II malocclusions. *Am J Orthod Dentofacial Orthop.* 1994;105:444–449.
12. Luppnapornlarp S, Johnston LE Jr. The effects of premolar-extraction treatment: a long-term comparison of outcomes in “clearcut” extraction and nonextraction patients. *Angle Orthod.* 1993;63:257–272.
13. Livieratos FA, Johnston LE Jr. A comparison of one-stage and two-stage nonextraction alternatives in matched Class II samples. *Am J Orthod Dentofacial Orthop.* 1995;108:118–131.
14. Kahl-Nieke B, Fischbach H, Schwarze CW. Treatment and postretention changes in dental arch width dimensions—a long term evaluation of influencing cofactors. *Am J Orthod Dentofacial Orthop.* 1996;109:368–378.
15. De La Cruz AR, Sampson P, Little RM, Årtun J, Shapiro PA. Long-term changes in arch form after orthodontic treatment and retention. *Am J Orthod Dentofacial Orthop.* 1995; 107:518–530.
16. Strang R. The fallacy of denture expansion. *Angle Orthod.* 1949;19:12–17.
17. Riedel RA. Review of the retention problem. *Angle Orthod.* 1960;6:179–199.
18. Strang RHW. Factors associated with successful orthodontic treatment. *Am J Orthod.* 1952;38:790–800.
19. Walter DC. Comparative changes in mandibular canine and first molar widths. *Angle Orthod.* 1962;32:232–240.
20. Sondhi A, Cleall JE, BeGole EA. Dimensional changes in the dental arches of orthodontically treated cases. *Am J Orthod.* 1980;77:60–74.
21. Uhde M, Sadowsky C, BeGole EA. Long-term stability of dental relationships after orthodontic treatment. *Angle Orthod.* 1983;53:240–252.
22. Dahlberg G. *Statistical Methods for Medical and Biological Students.* London: George Allen and Unwin Ltd; 1940:122–132.
23. Bishara SE, Bayati P, Zaher AR, Jakobsen JR. Comparisons of the dental arch changes in patients with Class II, division 1 malocclusions: extraction vs nonextraction treatments. *Angle Orthod.* 1994;5:351–358.
24. Little RM. Stability and relapse of dental arch alignment. *Br J Orthod.* 1990;17:235–241.
25. Schulhof RJ, Lestrel PE, Walters R, Schuler R. The mandibular dental arch: part III. Buccal expansion. *Angle Orthod.* 1978;48(4):303–310.
26. Weinberg M, Sadowsky C. Resolution of mandibular arch crowding in growing patients with Class I malocclusions treated nonextraction. *Am J Orthod Dentofacial Orthop.* 1996;110:359–364.
27. Glenn G, Sinclair PM, Alexander RG. Nonextraction orthodontic therapy: posttreatment dental and skeletal stability. *Am J Orthod Dentofacial Orthop.* 1987;92:321–328.
28. Boley JC, Mark JA, Sachdeva RC, Buschang PH. Long-term stability of Class I premolar extraction treatment. *Am J Orthod Dentofacial Orthop.* 2003;124:277–287.
29. Bishara SE, Cummins DM, Zaher AR. Treatment and post-treatment changes in patients with Class II division 1 malocclusion after extraction and nonextraction treatment. *Am J Orthod Dentofacial Orthop.* 1997;111:18–27.
30. Shearn BN, Woods MG. An occlusal and cephalometric analysis of lower first and second premolar extraction effects. *Am J Orthod Dentofacial Orthop.* 2000;117:351–361.
31. Kim E, Gianelly AA. Extraction vs nonextraction: arch widths and smile esthetics. *Angle Orthod.* 2003;73:354–358.
32. Baumrind S, Korn EL, Boyd RL, Maxwell R. The decision to extract: part 1—interclinician agreement. *Am J Orthod Dentofacial Orthop.* 1996;109:297–309.
33. Ong HB, Woods MG. An occlusal and cephalometric analysis of maxillary first and second premolar extraction effects. *Angle Orthod.* 2001;71:90–102.