

Lip Shape and Position in Class II division 2 Malocclusion

Grant T. McIntyre^a; Declan T. Millett^b

ABSTRACT

Objective: To determine whether differences exist in the shape and position of the lips between Class II division 2 and Class I malocclusions.

Materials and Methods: Lateral cephalometric radiographs of subjects with Class II division 2 ($n = 30$) and Class I ($n = 30$) incisor relationships were scanned at 300 dpi to produce digital images. These were subsequently digitized in random order. Twenty-one landmarks characterizing the upper and lower lips and the maxillary and mandibular central incisors were digitized. Procrustes algorithms optimally superimposed the landmark configurations to standardize size, location, and orientation. Discriminant analysis of the principal components of shape determined the differences between the Class II division 2 and Class I groups.

Results: The shape and position of the upper and lower lips differed significantly between the Class II division 2 group and the Class I group ($P < .001$). Principal component (PC) 1 (46% of the variance) involved an increase in the thickness of the upper and lower lips in the Class II division 2 group. PC2 (11% of the variance) was characterized by a relatively higher lip line in the Class II division 2 group.

Conclusions: The shape and position of the lips differ between Class II division 2 and Class I malocclusions.

KEY WORDS: Class II division 2; Lip shape; Lip position; Cephalometry; Morphometry

INTRODUCTION

Class II division 2 malocclusion is characterized by the permanent mandibular incisors occluding posterior to the cingulum plateau of retroclined permanent maxillary incisors.¹ This gives rise to a reduced overjet and frequently an increased overbite. Classically, the permanent maxillary central incisors are retroclined and the maxillary lateral incisors are proclined and mesiolabially rotated. However, all four permanent maxillary incisors may be retroclined with or without facially displaced and proclined permanent maxillary canines.

The relationship of the labial soft tissues to the permanent maxillary incisors has been implicated as the

principal etiological factor in the development and relapse of Class II division 2 malocclusion.²⁻⁷ Specifically, the maxillary incisor retroclination is thought to result from increased resting lip pressure as a consequence of a combination of hyperactivity of the labial musculature and a higher resting lip line.^{5,7,8} Despite cephalometric studies confirming the higher resting lip line, electromyographic studies have not confirmed unanimously increased labial musculature activity in subjects with Class II division 2 malocclusions when compared with those with Class I malocclusion.⁹⁻¹¹

Furthermore, no previous study has investigated simultaneously lip shape and position as a factor in the development of Class II division 2 malocclusion. This is because shape data cannot be derived from linear and angular measurements.¹² Morphometric techniques overcome many of the limitations of conventional cephalometric measurements because they integrate geometric location and biologic homology allowing shape comparisons to be made.^{13,14}

The objective of this study is to determine whether differences exist in the shape and position of the lips between Class II division 2 and Class I malocclusions. The null hypothesis tested is that there are no differ-

^a Consultant, Orthodontic Department, Dundee Dental Hospital and School, Dundee, UK.

^b Professor, Department of Oral Health and Development, University Dental School and Hospital, Wilton, Cork, Ireland.

Corresponding author: Dr. Grant T. McIntyre, Orthodontic Department, Dundee Dental Hospital and School, 2 Park Place, Dundee DD1 4HR, UK
(e-mail: grant.t.mcintyre@tuht.scot.nhs.uk)

Accepted: October 2005. Submitted: May 2005.

© 2006 by The EH Angle Education and Research Foundation, Inc.

ences in the shape and position of the lips between Class II division 2 and Class 1 malocclusions.

MATERIALS AND METHODS

Of the 499 lateral cephalograms recorded at a university orthodontic clinic during 2001, 135 were excluded from this study for various reasons affecting the cephalometric visualization of the permanent maxillary central incisor form. The lateral cephalometric radiographs of three other subjects could not be located. The remaining 361 lateral cephalometric radiographs were stratified according to incisor relationship as defined by the British Standards Institute¹ and recorded in the clinical records by experienced orthodontists:

- Class I: The lower incisor edges lie on or below the cingulum plateau on the palatal surface of the upper incisors with a normal overjet.
- Class II division 1: The lower incisor edges lie palatal to the cingulum plateau of the upper incisors and the upper incisors are proclined or of normal inclination with an increased overjet.
- Class II division 2: The lower incisor edges lie palatal to the cingulum plateau of the upper incisors with the upper incisors being retroclined, the overjet is usually minimal but may be increased.
- Class III: The lower incisor edges lie labial to the cingulum plateau of the upper incisors.

The resultant groupings were as follows: Class I (n = 71); Class II division 1 (n = 139); Class II division 2 (n = 60); and Class III (n = 91). Full details regarding the selection of these groups are described elsewhere.¹⁵

Because this study evaluated lip shape and position in Class II division 2 malocclusion compared with Class 1 malocclusion, cephalograms of subjects with Class II division 1 and Class III malocclusions were excluded along with those from the study groups that showed poor definition of the labial soft tissues. Thirty Class II division 2 and 29 Class I cephalograms were excluded to leave 30 Class II division 2 and 42 Class I images. The 30 images of the Class II division 2 group and the 30 cephalograms which were randomly selected from the Class I group were scanned at 300 dpi to produce monitor-displayed digital cephalograms using a Heidelberg NewColor 4000 flatbed scanner (Heidelberg CPS GmbH, Bad Homburg, Germany, <http://www.hdcps.com/>) attached to a DELL Dimension XPS T550 computer and DELL D1626HT (UltraScan 1600HS Series) 21-inch Color Graphics Display monitor (DELL, Round Rock, Tex, <http://www.dell.com>).

Using tpsDIG32 (<http://life.bio.sunysb.edu/morph/>), each digital cephalogram was digitized on-screen in

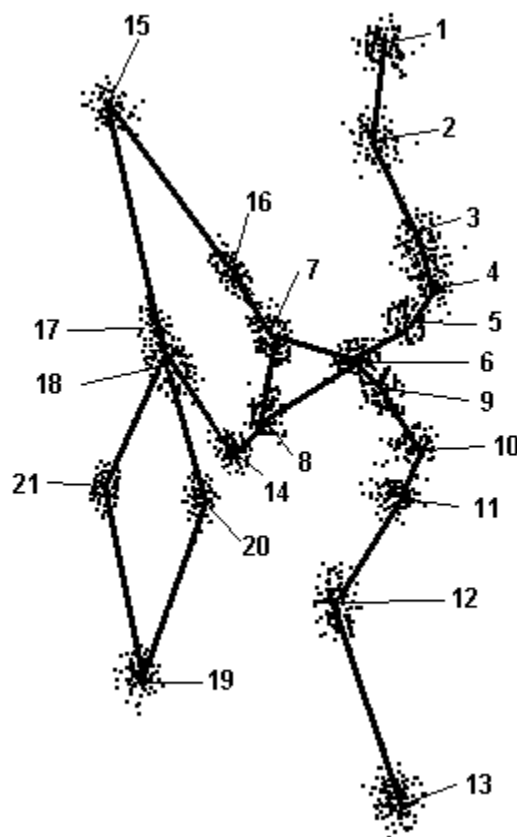


Figure 1. Shape variance.

random order under identical conditions with all sources of extraneous background lighting eliminated. Where any uncertainty existed as to incisor orientation or soft tissue contour, images were enlarged. The subject's study models were also consulted where necessary. Magnification was standardized during the recording, scanning, and digitizing of the radiographs.

The x-y coordinates of 21 landmarks (Figure 1; Table 1) representing the form of the most labially positioned maxillary and mandibular central incisors and the profile of the lips were digitized and exported for subsequent analysis. Twenty-five of the images were redigitized 1 month later to evaluate intraoperator reproducibility for individual landmarks.¹⁶

Discriminant Analysis of the Principal Components of Shape

Before comparing the dental and soft tissue morphology between the study groups, the landmark configurations of the whole sample were standardized using APS software (version 2.4, <http://www.cpod.com/monoweb/aps/aps.htm>). Using Procrustes algorithms, APS scaled, translated, and superimposed the centroids (the geometric midpoints) of the landmark configurations of the incisor-lip complex in one step. Con-

Table 1. Landmarks

Landmark Number	Definition
1	Junction of the nasal columella and philtrum of the upper lip
2	Deepest point on the concavity of the upper lip
3	Most anterosuperior landmark on the upper lip
4	Most anterior landmark on the upper lip
5	Most anteroinferior landmark on the upper lip
6	Stomion
7	Most incisal point of contact between upper lip and maxillary incisor
8	Most incisal point of contact between lower lip and maxillary incisor
9	Most anterosuperior landmark on the lower lip
10	Most anterior landmark on the lower lip
11	Most anteroinferior landmark on the lower lip
12	Deepest point on the concavity of the lower lip
13	Most anterior point on the soft tissue chin
14	Maxillary incisor crown tip
15	Maxillary incisor root apex
16	Maxillary incisor labial ACJ
17	Maxillary incisor palatal ACJ
18	Mandibular incisor crown tip
19	Mandibular incisor root apex
20	Mandibular incisor labial ACJ
21	Mandibular incisor lingual ACJ

currently, the configurations were iteratively rotated to minimize the squared differences between landmarks. By standardizing size, location, and orientation, this procedure produces the “best-fit” of the landmark configurations under test, allowing shape information to be calculated precisely. The resultant shape variance is demonstrated in Figure 1, where the individual observations are plotted as vectors from the landmark-specific means.

Statistical Analysis

The coefficient of reliability and a two-sample *t*-test were used to quantify random errors and systematic errors, respectively, in relation to landmark reproducibility. Following Procrustes superimposition, the Procrustes mean (essentially the mean shape) was computed separately for each test group. Calculating the displacement between each landmark and the Procrustes mean produced a matrix of Procrustes residuals for subsequent statistical analysis by a principal components of shape (PCS) analysis. Discriminant analysis of the PCS ordered the data set as linear combinations of the original variables. The shape components were then ordered by decreasing magnitude. Finally, multivariate regression and discriminant analysis calculated the best linear combination of the PCs differentiating between the test groups.

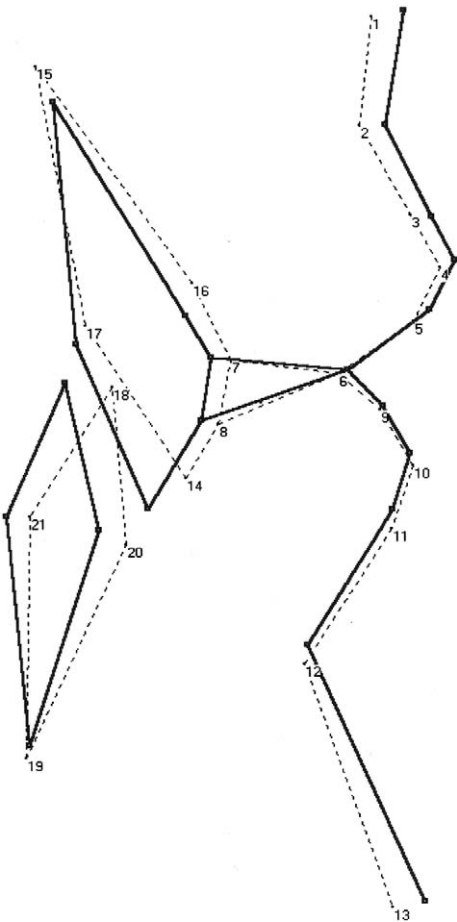


Figure 2. Discrimination between Class II division 2 and Class I malocclusions (solid line represents Class II division 2; dotted line represents Class I).

Table 2. Principal Components of Shape

Component	% Variance	R ² -value	F-value	P-value
2	57	0.682	55.787	***

*** *P* < .001.

RESULTS

Landmark Reproducibility

Random error values for all landmarks were above 0.95. None was associated with systematic error (*P* < .1). These have been suggested as acceptable thresholds.^{16,17}

There were highly significant differences in lip morphology and lip relationship to the permanent central incisors between the groups (*P* < .001; Figure 2; Table 2). The upper and lower lips were relatively thicker with more apical contact of the lower lip with the labial surface of the permanent maxillary central incisor (higher lip line) in the Class II division 2 group compared with the Class I group. The permanent mandib-

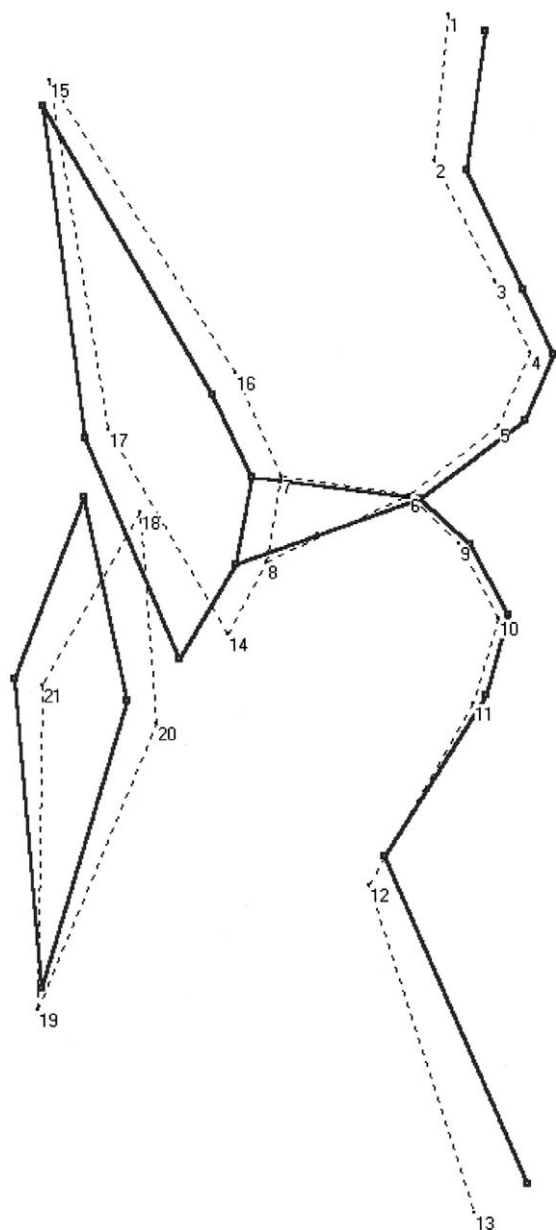


Figure 3. Principal component 1.

ular central incisors were observed to be more upright with respect to the skeletal base in the former group than in the latter (Figure 2). The retroclined permanent maxillary central incisors, which had longer clinical crowns with a reduced labiopalatal thickness, were relatively more extruded in the Class II division 2 group compared with the Class I group (Figure 2).

When the principal components (PC) were examined, PC1 and PC2 accounted for 57% of the total variance in the Class II division 2 group. PC1 (46% of the variance) involved thicker upper and lower lips (Figure 3). PC2 (11% of the variance) was characterized by relatively more apical contact of the upper and lower lips with the labial surface of the permanent

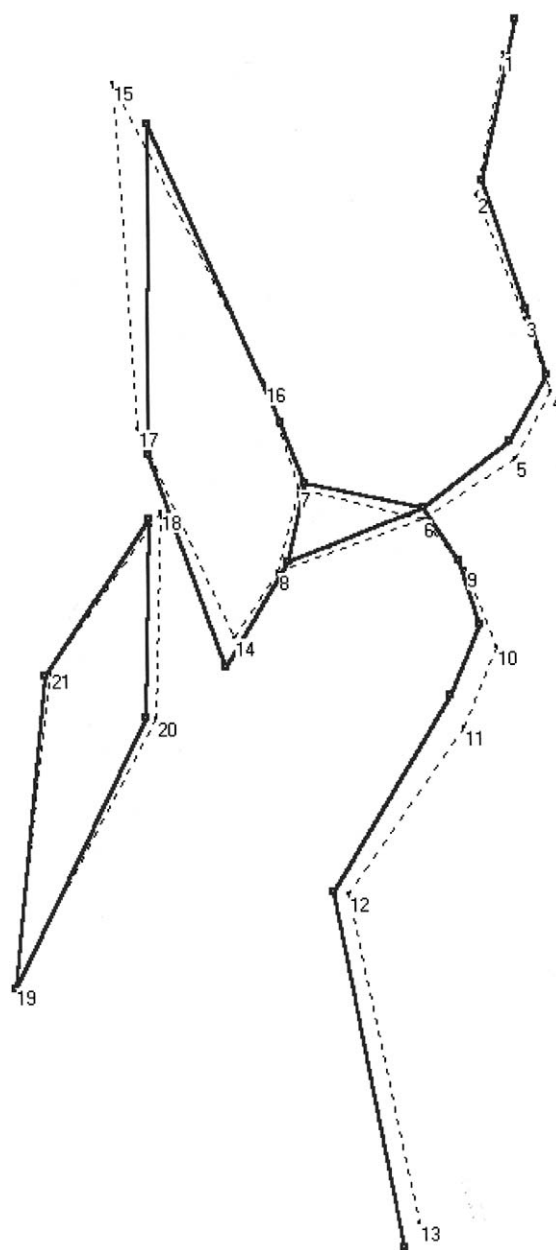


Figure 4. Principal component 2.

maxillary central incisor and greater coverage of the labial surface of the permanent maxillary central incisors by the lower lip (Figure 4).

DISCUSSION

Compared with Class I malocclusion, we identified that subjects with Class II division 2 malocclusion have a different lip shape and position. Shape is the information that remains when size, location, and orientation are removed from the morphological data.¹⁴ Although previous studies have sought to investigate shape changes occurring with growth,¹⁸ orthodontic treatment,¹⁹ and orthognathic surgery,²⁰ labiodental

shape has not been evaluated previously in Class II division 2 malocclusion. In this study, thicker lips were identified in the Class II division 2 group. A greater proportion of the labial surface of the permanent maxillary central incisor was also found to be in contact with the lower lip. This confirms the findings of previous cephalometric studies with respect to lower lip line height in this malocclusion group.^{2,3,7,8,21}

Lateral cephalograms with the lips at rest were used in this investigation to provide valid labial and related incisor assessments. Although residual perioral musculature activity exists at rest, this rather than intermittent activity determines incisor positions.²² Lip position at rest is also highly reproducible.²³ The most significant sources of bias in a cephalometric investigation result from sample selection and digitization, but every effort was made to minimize bias in our study by excluding images where the incisor inclination and related soft tissue profile were not clearly visible.

The lip shape and position factors, which we identified, in conjunction with the greater lower than upper lip pressure on the permanent maxillary incisors⁹ and the unfavorable crown-root ratio of the permanent maxillary central incisors,^{15,24} favor their retroclination as they erupt. However, because two-thirds of the root of the permanent maxillary incisor is mineralized before eruption begins,²⁵ the increased lip pressure acting on the labial surface is unlikely to be the main cause of the crown-root deviation identified in previous studies of Class II division 2 subjects.^{15,26–32} The den-toalveolar effects of the distinctive perioral soft tissues associated with Class II division 2 malocclusion not only involve the permanent maxillary incisors but also the permanent mandibular incisors, which were found to be retroclined. This finding is in accordance with that of Mills.⁵

Procrustes superimposition followed by the discriminant analysis of the PCS was used to investigate lip shape and position. Using this method, the findings of thicker upper and lower lips and a higher lip line accounted for 57% of the Class II division 2 variance. Factor analysis is another statistical method that would have reduced the quantity of shape data.³³ Although that statistical technique and the one adopted in our study operate differently, similar results are likely to have been found if factor analysis had been used. APS software using the discriminant analysis of the PCS, however, was used because it allowed visual demonstration of the differences between the test groups.

The shape and position of the lips in Class II division 2 malocclusion not only affects incisor inclinations but can also complicate orthodontic mechanotherapy and posttreatment stability. The latter is more complex

than correcting the centroid relationship by controlled incisor proclination.³⁴ The proportion of the labial surface of the permanent maxillary central incisor covered by the lower lip must also be reduced.^{7,34} Because the findings of this study and those reported previously¹⁵ indicate relative extrusion and a longer clinical crown of the permanent maxillary incisors in Class II division 2 malocclusion compared with Class 1 malocclusion, intrusion of the permanent maxillary incisors during fixed appliance treatment is a necessity during orthodontic mechanotherapy for individuals with Class II division 2 malocclusion.

A prediction tracing to simulate the effect of planned maxillary incisor torque and determine whether this would result in fenestration of the palatal cortex can be useful.^{15,35} Incorporating an outline of the lips and their change in position with tooth movement could also aid retention planning.

CONCLUSION

- The shape and position of the upper and lower lips differs between Class II division 2 and Class I malocclusions.

REFERENCES

1. British Standards Institute. *British Standard Incisor Classification. Glossary of Dental Terms BS 4492*. London, UK: British Standard Institute; 1983.
2. Ridley DR. Some factors concerned with the reduction of excessive overbite in Angle's Class II division 2 malocclusion. *Trans Br Soc Study Orthod*. 1960;118–140.
3. Nicol WA. The lower lip and the upper incisor teeth in Angle's Class II division 2 malocclusion. *Dent Pract*. 1963;14:179–182.
4. Posen AL. The influence of maximum perioral and tongue force on the incisor teeth. *Angle Orthod*. 1972;42:285–309.
5. Mills JRE. The problem of overbite in Class II, division 2 malocclusion. *Br J Orthod*. 1973;1:34–48.
6. Fletcher GGT. The retroclined upper incisor. *Br J Orthod*. 1975;2:207–216.
7. Luffingham JK. The lower lip and the maxillary central incisors. *Eur J Orthod*. 1982;4:263–268.
8. Karlson AT. Craniofacial characteristics in children with Angle Class II div. 2 malocclusion compared with extreme deep bite. *Angle Orthod*. 1994;64:123–130.
9. Lapatki BG, Mager AS, Schulte-Moenting J, Jonas IE. The importance of the level of the lip line and resting lip pressure in Class II division 2 malocclusion. *J Dent Res*. 2002;81:323–328.
10. Gould MS, Picton DC. A study of pressures exerted by the lips and cheeks on the teeth of subjects with Angle's Class II division 1, Class II division 2 and Class 3 malocclusions compared with those of subjects with normal occlusions. *Arch Oral Biol*. 1968;13:527–541.
11. Luffingham JK. Lip and cheek pressure exerted upon teeth in three adult groups with different occlusions. *Arch Oral Biol*. 1969;14:337–350.
12. Moyers RE, Bookstein FL. The inappropriateness of conventional cephalometrics. *Am J Orthod*. 1979;75:599–617.

13. Bookstein FL. On the cephalometrics of skeletal changes. *Am J Orthod.* 1982;82:177–198.
14. McIntyre GT, Mossey PA. Size and shape measurement in contemporary cephalometrics. *Eur J Orthod.* 2003;25:231–242.
15. McIntyre GT, Millett DT. Crown-root shape of the maxillary central incisor. *Angle Orthod.* 2003;73:710–715.
16. Stirrups DR. Guidance on presentation of cephalometry-based research studies. A personal perspective. *Br J Orthod.* 1993;20:359–365.
17. Houston WJB. The analysis of errors in orthodontic measurements. *Am J Orthod.* 1983;83:382–390.
18. Chen SY, Lestrel PE, Kerr WJ, McColl JH. Describing shape changes in the human mandible using elliptical Fourier functions. *Eur J Orthod.* 2000;22:205–216.
19. Lux CJ, Rubel J, Starke J, Conradt C, Stellzig PA, Komposch PG. Effects of early activator treatment in patients with class II malocclusion evaluated by thin-plate spline analysis. *Angle Orthod.* 2001;71:120–126.
20. Hajeer MY, Ayoub AF, Millett DT. Three-dimensional assessment of facial soft-tissue asymmetry before and after orthognathic surgery. *Br J Oral Maxillofac Surg.* 2004;42:396–404.
21. Schweitzer M, Pancherz H. The incisor-lip relationship in Herbst/multibracket appliance treatment of Class II, division 2 malocclusions. *Angle Orthod.* 2001;71:358–363.
22. Harradine NW, Kirschen RH. Lip and mentalis activity and its influence on incisor position—a quantitative electromyographic study. *Br J Orthod.* 1983;10:114–127.
23. Johnston DJ, Millett DT, Ayoub AF, Bock M. Are facial expressions reproducible? *Cleft Palate Craniofac J.* 2003;40:291–296.
24. Holttä P, Nystrom M, Evalahti M, Alaluusua S. Root-crown ratios of permanent teeth in a healthy Finnish population assessed from panoramic radiographs. *Eur J Orthod.* 2004;26:491–497.
25. Parkin SF. *Notes on Paediatric Dentistry.* Oxford, UK: Wright; 1991:201.
26. Bryant RM, Sadowsky PL, Hazelrig JB. Variability in three morphologic features of the permanent maxillary central incisor. *Am J Orthod.* 1984;86:25–32.
27. Nicol WA. The lower lip and the upper incisor teeth in Angle's Class II division 2 malocclusion. *Trans Br Soc Orthod.* 1963;81–84.
28. Robertson NRE, Hilton R. Feature of the upper central incisors in Class II, division 2. *Angle Orthod.* 1965;35:51–53.
29. Delivanis HP, Kuftinec MM. Variation in morphology of the maxillary central incisors found in Class II, division 2 malocclusions. *Am J Orthod.* 1980;78:438–443.
30. Williams A, Woodhouse C. The crown to root angle of maxillary central incisors in different incisal classes. *Br J Orthod.* 1983;10:159–161.
31. Harris EF, Hassankiadeh S, Harris JT. Maxillary incisor crown root relationships in different angle malocclusions. *Am J Orthod Dentofacial Orthop.* 1993;103:48–53.
32. Korda RA, Nikolidakis DK, Xagoraris MD, Athanasiou AE, Papadopoulos MA. Crown/root relations and root morphological characteristics of permanent maxillary central incisors in Class II, division 1 and 2 malocclusions. *Hell Orthod Rev.* 2000;3:89–96.
33. Doll GM, Zentner A, Klages U, Serogl HG. Relationship between patient discomfort, appliance acceptance and compliance in orthodontic therapy. *J Orofac Orthop.* 2000;61:398–413.
34. Selwyn-Barnett BJ. Rationale of treatment for Class II division 2 malocclusion. *Br J Orthod.* 1991;18:173–181.
35. Selwyn-Barnett BJ. Class II/division 2 malocclusion: a method of planning and treatment. *Br J Orthod.* 1996;23:29–36.