

Herbst Treatment of Class II division 1 Malocclusions in Retrognathic and Prognathic Facial Types

A Cephalometric Long-term Retrospective Study

Niko Bock^a; Hans Pancherz^b

ABSTRACT

Objective: The aim of this retrospective pilot study was to analyze and compare the short-term and long-term changes of Herbst treatment in Class II division 1 subjects of the retrognathic and prognathic facial type.

Materials and Methods: The subject material comprised 10 retrognathic (mean SNA = 74.5°, SNB = 70.4°, ML/NSL = 41.1°) and 16 prognathic (mean SNA = 86.7°, SNB = 81.5°, ML/NSL = 25.1°) Class II division 1 subjects treated with the Herbst appliance for an average period of 7 months. Lateral head films from before (T1), immediately after (T2), 12 months after (T3), and 39 months after (T4) Herbst treatment were analyzed with the SO-analysis (analysis of changes in sagittal occlusion) and standard cephalometrics.

Results: During the treatment period (T2–T1) the two facial type groups showed similar favorable changes for all variables. During the posttreatment periods of 12 months (T3–T2) and 39 months (T4–T2) recovering changes occurred. In the long-term, a tendency of more unfavorable growth changes was stronger (not significant) for retrognathic subjects than for prognathic subjects.

Conclusion: On a long-term basis, retrognathic subjects are prone to exhibit more unfavorable mandibular growth changes than prognathic subjects and, thus, might exhibit a greater risk for an occlusal relapse when a stable Class I occlusion is not attained after treatment.

KEY WORDS: Herbst; Retrognathic; Prognathic; Facial type

INTRODUCTION

Class II malocclusions of the retrognathic facial type are considered to be more difficult to treat successfully than those of the prognathic facial type.^{1–5} However, most of the statements made are based mainly on clinical experience and not on scientific evidence. Furthermore, in the literature, no investigations have been performed considering both the sagittal and vertical dimensions in the assessment of facial retrognathism and prognathism of subjects for a long period post-treatment. The existing studies only focus on either

sagittal⁴ (SNA and SNB angles) or vertical^{2,5–7} (“high-angle” and “low-angle”) aberrations. Hasund³ claimed, however, that a characterization of facial retrognathism and prognathism should include measurements in both the sagittal (SNA and SNB angles) and the vertical (ML/NSL angle) planes.

Therefore, the aim of this retrospective study was to compare the short-term and long-term results of Class II division 1 malocclusions treated with the Herbst appliance considering both the sagittal and vertical facial dimensions in subjects of the retrognathic and prognathic facial types. The following questions were of interest:

- Are the immediate treatment effects in retrognathic and prognathic subjects comparable?
- Are there differences between the two facial types on a long-term basis?

MATERIALS AND METHODS

The original Class II division 1 sample treated with the Herbst appliance,⁸ who had complete records and were followed for at least 3 years posttreatment, com-

^a Assistant Professor, Department of Orthodontics, University of Giessen, Giessen, Germany.

^b Professor Emeritus, Department of Orthodontics, University of Giessen, Giessen, Germany.

Corresponding author: Dr. Niko Bock, Department of Orthodontics, University of Giessen, Schlangenzahl 14, Giessen, 35392, Germany
(e-mail: niko.c.bock@dentist.med.uni-giessen.de)

Accepted: November 2005. Submitted: October 2005.

© 2006 by The EH Angle Education and Research Foundation, Inc.

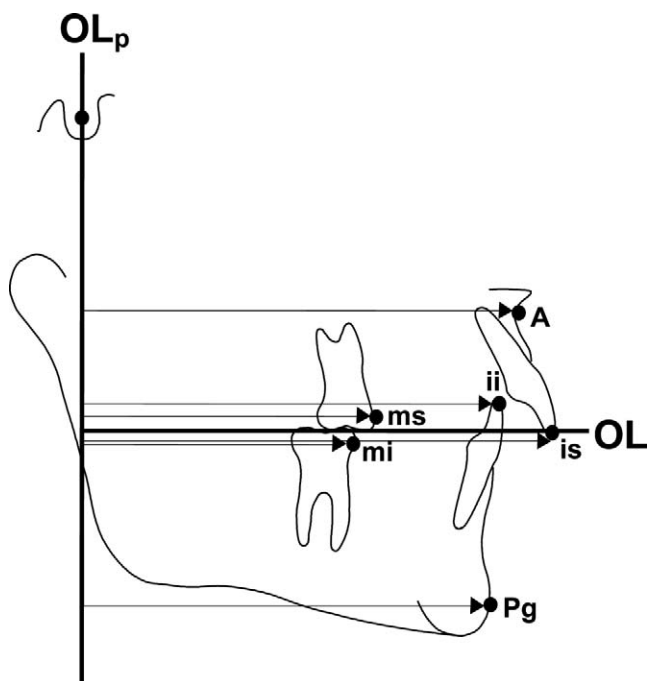


Figure 1. SO-analysis: measuring landmarks and measuring distances.

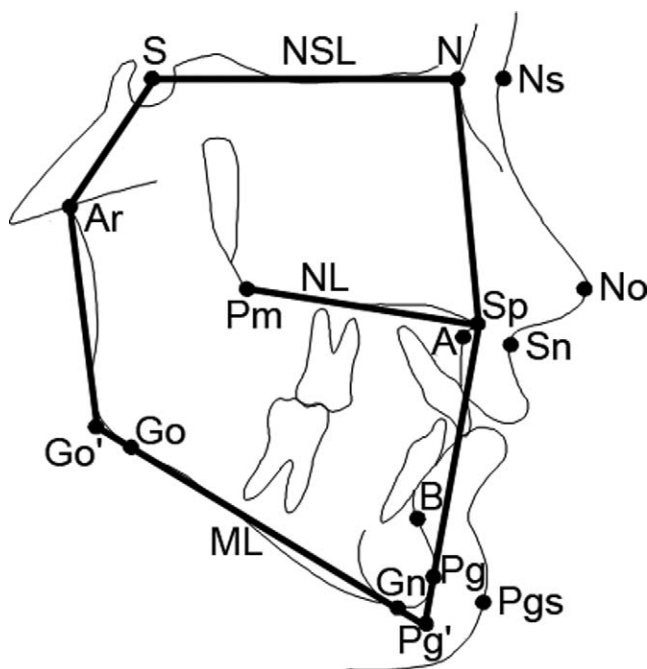


Figure 2. Standard cephalometrics: measuring landmarks and facial polygon.

prised 360 consecutive patients. Of these patients, 130 were treated at the Orthodontic Department at the University of Lund in Sweden, and 230 were treated at the Orthodontic Department at the University of Giessen in Germany.

The same treatment protocol was used for all pa-

tients. In the majority of subjects, the Herbst treatment phase was followed by a multibracket treatment phase for final tooth alignment. On the basis of the values published by Hasund,³ the patients were classified according to facial type, considering both sagittal and vertical characteristics: retrognathic facial type with $SNA \leq 76.0^\circ$, $SNB \leq 72.0^\circ$, and $ML/NSL \geq 36.5^\circ$; and prognathic facial type with $SNA \geq 83.0^\circ$, $SNB \geq 80.0^\circ$, $ML/NSL \leq 32.0^\circ$.

Thus, 26 of the 360 patients fulfilled the requirements for being assigned to the retrognathic or prognathic facial type group.

- Ten retrognathic subjects (five male and five female): mean $SNA 74.5^\circ$ (range 72.0° to 76.0°); mean $SNB 70.4^\circ$ (range 68.0° to 72.0°); and mean $ML/NSL 41.1^\circ$ (36.5° to 47.0°).
- Sixteen prognathic subjects (seven male and nine female): mean $SNA 86.7^\circ$ (83.0° to 90.0°); mean $SNB 81.5^\circ$ (80.0° to 84.0°); and mean $ML/NSL 25.1^\circ$ (16.5° to 32.0°).

Before treatment, all 26 subjects were either in the late mixed or permanent dentition. The overjet was at least 5 mm, and a unilateral or bilateral Class II molar relation exceeding 0.5-cusp width was present. None of the subjects showed a posterior crossbite or had missing permanent teeth. Five of the 10 retrognathic subjects had an open bite with a vertical overlap of the incisors⁹ before treatment, which was closed during treatment and remained closed during the posttreatment period in four of the five subjects. None of the prognathic subjects showed an open bite either before or after treatment.

The mean age of the subjects at the beginning of treatment was 15 years (range 11 to 18 years) in the retrognathic group and 13 years (range 11 to 16 years) in the prognathic group. The treatment growth period of the subjects was assessed with hand wrist radiographs.¹⁰ Selected maturity stages of the middle phalanx of the third finger and of the radius bone were utilized.¹¹

At the beginning of treatment, 30% of the retrognathic and 19% of the prognathic subjects were in the prepubertal peak of growth (prepeak), 10% of the retrognathic and 75% of the prognathic subjects were in the postpubertal peak of growth (postpeak), while 60% of the retrognathic and 6% of the prognathic subjects were at the end of the growth period.

At the end of the follow-up period, 3 years after Herbst treatment, 30% of the retrognathic and 6% of the prognathic subjects were postpeak and 70% of the retrognathic and 94% of the prognathic subjects were at the end of growth.

The subjects in both groups were treated with either a fixed banded or a cast splint Herbst appliance¹² for

Table 1. SO-Analysis: Records of 10 Retrognathic and 16 Prognathic Herbst Subjects^{a,b}

Variable, mm		Retrognathic Group				Prognathic Group			
		T1 Mean (SD)	T2 Mean (SD)	T3 Mean (SD)	T4 Mean (SD)	T1 Mean (SD)	T2 Mean (SD)	T3 Mean (SD)	T4 Mean (SD)
Overjet	is/OLp minus ii/OLp	8.8 (2.17)	-0.6 (2.11)	2.6 (0.84)	3.2 (0.64)	8.0 (3.00)	0.4 (1.78)	2.9 (0.60)	3.5 (0.71)
Molar relation	ms/OLp minus mi/OLp	+1.6 (2.84)	-4.4 (1.30)	-2.2 (1.78)	-1.5 (1.76)	+1.2 (1.29)	-4.5 (1.79)	-2.9 (0.86)	-2.4 (1.02)
Maxillary base	A/OLp	77.6 (5.43)	77.2 (5.31)	76.6 (4.61)	78.2 (5.96)	81.0 (5.13)	80.9 (5.74)	81.6 (5.85)	82.2 (5.56)
Mandibular base	Pg/OLp	79.0 (5.65)	80.2 (5.92)	79.0 (5.86)	80.0 (7.18)	84.0 (5.83)	85.7 (6.50)	85.9 (6.76)	86.7 (6.67)
Maxillary incisor	is/OLp	86.9 (5.88)	82.7 (5.90)	83.2 (4.76)	84.8 (5.73)	90.1 (5.93)	88.0 (6.27)	88.4 (6.79)	89.2 (6.36)
Mandibular incisor	ii/OLp	78.1 (5.23)	83.3 (6.24)	80.6 (4.95)	81.6 (5.67)	82.1 (5.77)	87.6 (6.41)	85.5 (6.86)	85.7 (6.14)
Maxillary molar	ms/OLp	56.3 (5.08)	54.3 (6.26)	54.6 (6.02)	56.5 (6.46)	57.1 (5.09)	55.3 (6.16)	56.7 (6.13)	57.9 (5.36)
Mandibular molar	mi/OLp	54.7 (7.08)	58.7 (7.08)	56.8 (7.16)	58.0 (7.69)	55.9 (5.39)	59.8 (5.88)	59.6 (6.23)	60.3 (5.58)

^a T1, before treatment; T2, after treatment; T3, 12 months after treatment; T4, 39 months after treatment; Aberrations of the cephalometric variables in Figure 1.

^b Plus (+) indicates a distal molar relation; minus (-) indicates a neutral or mesial molar relation.

a mean period of 7 months (range 5 to 11 months). Irrespective of the pretreatment overjet, the mandible was advanced to an incisal edge-to-edge position when placing the appliance. After Herbst treatment, 9 of the 10 subjects in the retrognathic group and 9 of the 16 subjects in the prognathic group received further treatment with a multibracket appliance and Class II elastics for an average period of 12 months (range 5 to 20 months). No further treatment was performed in the remaining eight subjects. The subjects were re-investigated, on average, 39 months (range 26 to 61 months for the retrognathic group, 24 to 49 months for the prognathic group) after Herbst treatment. Retention after active treatment was performed in 22 of the 26 subjects with a removable appliance (Activator, Hawley, or Positioner) in combination with a fixed lower cuspid-to-cuspid retainer (16 subjects). The average retention time was 27 months. Four subjects did not receive any retention.

Lateral head films in habitual occlusion from before (T1), after (T2), 12 months after (T3), and 39 months after (T4) Herbst treatment were analyzed for all subjects. The registrations from the roentgenograms were traced using matte acetate film. Linear and angular measurements were made to the nearest 0.5 mm and 0.5°, respectively. No correction was made for linear enlargement (which was approximately 7% in the median plane for the radiographic equipment used in Germany and Sweden).

To minimize the method error, the tracings and measurements were performed twice, with a time interval of approximately 2 weeks. The mean value of both measurements was used as the final measurement value. The SO-analysis (analysis of changes in sagittal

occlusion) of Pancherz¹ (Figure 1) and standard cephalometrics (Figure 2) were used for the assessment of treatment and posttreatment changes.

The arithmetic mean (Mean) and standard deviation (SD) were calculated for each variable. Because the data had a normal distribution (Kolmogorov-Smirnov test), the changes of the variables during the different examination periods were evaluated by using the *t*-test for paired samples. To compare group differences, the *t*-test for independent samples was used. The following levels of significance were set: $P < .001$, $P < .01$, and $P < .05$.

RESULTS

All 26 Class II subjects (retrognathic and prognathic) were treated successfully to a Class I dental arch relationship with the Herbst appliance.

Because significant ($P < .05$) gender differences were found for only three variables (changes in the positions of mandible, maxilla, and lower incisors) and exclusively in the prognathic group during the treatment period, the female and male subjects in both facial type groups were pooled.

SO-Analysis

The cephalometric records of the retrognathic and prognathic subjects at the different times of examination are shown in Table 1.

Changes during the treatment period T2-T1

Retrognathic and prognathic groups (Table 2). Both groups showed the following favorable changes contributing to overjet and Class II molar correction:

Table 2. SO-Analysis: Changes (D) During the Treatment (T2–T1) and Posttreatment (T3–T2, T4–T2) Periods in 10 Retrognathic and 16 Prognathic Herbst Subjects^{a,b}

	Variable, mm		Retrognathic Group				Prognathic Group				Group Difference Retrognathic-Prognathic		
			Mean D	SD	<i>t</i>	<i>P</i>	Mean D	SD	<i>t</i>	<i>P</i>	Mean D	<i>t</i>	<i>P</i>
Overjet	is/OLp (D) minus ii/OLp (D)	T2–T1	+9.4	2.77	+10.17	***	+7.6	2.91	+10.12	***	1.8	1.49	ns
		T3–T2	–3.2	1.86	–5.17	***	–2.5	1.83	–5.31	***	0.7	0.89	ns
		T4–T2	–3.8	2.14	–5.30	***	–3.1	1.80	–6.68	***	0.7	0.83	ns
Molar relation	ms/OLp (D) minus mi/OLp (D)	T2–T1	+6.0	2.07	+8.68	***	+5.7	1.94	+11.39	***	0.3	0.36	ns
		T3–T2	–2.2	1.46	–4.59	**	–1.6	1.54	–4.03	**	0.6	0.98	ns
		T4–T2	–2.9	1.13	–7.56	***	–2.1	2.21	–3.68	**	0.8	0.94	ns
Maxillary base	A/OLp (D)	T2–T1	+0.4	1.15	+1.11	ns	+0.1	1.14	+0.42	ns	0.3	0.62	ns
		T3–T2	+0.6	1.17	+1.54	ns	–0.7	1.24	–2.10	ns	1.3	2.49	*
		T4–T2	–1.0	2.15	–1.39	ns	–1.3	2.73	–1.84	ns	0.3	0.28	ns
Mandibular base	Pg/OLp (D)	T2–T1	+1.2	1.76	+2.04	ns	+1.7	2.35	+2.86	*	0.5	0.59	ns
		T3–T2	–1.2	2.74	–1.34	ns	+0.2	2.68	+0.25	ns	1.4	1.23	ns
		T4–T2	–0.2	3.23	–0.19	ns	+1.0	4.90	+0.77	ns	1.2	0.63	ns
Maxillary incisor	is/OLp (D) minus A/OLp (D)	T2–T1	+3.8	2.20	+5.16	***	+2.0	1.73	+4.44	***	1.8	2.22	*
		T3–T2	–1.1	1.72	–1.92	ns	+0.3	1.38	+0.76	ns	1.4	2.15	*
		T4–T2	–1.1	2.63	–1.22	ns	+0.1	1.48	+0.16	ns	1.2	1.36	ns
Mandibular incisor	ii/OLp (D) minus Pg/OLp (D)	T2–T1	+4.0	1.43	+8.38	***	+3.8	1.66	+8.91	***	0.2	0.28	ns
		T3–T2	–1.5	2.18	–2.03	ns	–2.3	1.74	–5.08	***	0.8	1.00	ns
		T4–T2	–1.5	3.23	–1.39	ns	–2.9	1.60	–7.04	***	1.4	1.43	ns
Maxillary molar	ms/OLp (D) minus A/OLp (D)	T2–T1	+1.6	2.07	+2.32	*	+1.7	1.19	+5.59	***	0.1	0.18	ns
		T3–T2	–0.9	0.99	–2.79	*	–0.7	1.19	–2.36	*	0.2	0.41	ns
		T4–T2	–1.2	0.88	–4.00	**	–1.3	1.28	–3.98	**	0.1	0.28	ns
Mandibular molar	mi/OLp (D) minus Pg/OLp (D)	T2–T1	+2.8	1.41	+6.01	***	+2.2	1.22	+6.91	***	0.6	1.20	ns
		T3–T2	–0.7	1.17	–1.73	ns	–0.4	1.22	–1.18	ns	0.3	0.60	ns
		T4–T2	–0.5	1.81	–0.79	ns	–0.5	2.10	–0.95	ns	0.0	0.05	ns

^a T1, before treatment; T2, after treatment; T3, 12 months after treatment; T4, 39 months after treatment; Aberrations of the cephalometric variables in Figure 1.

^b In the separate groups, plus (+) means favorable changes and minus (–) means unfavorable changes aiming at Class II correction.

*** $P < .001$; ** $P < .01$; * $P < .05$; ns, $P \leq .05$.

- The mandible was advanced (retrognathic group, $P > .05$ [not significant]; prognathic group $P < 0.05$);
- The upper incisors were retruded ($P < .001$);
- The lower incisors were protruded ($P < .001$);
- The upper molars were moved posteriorly (retrognathic group $P < .05$; prognathic group $P < .001$); and
- The lower molars were moved anteriorly ($P < .001$).

Group comparison (Table 2). The only significant group difference was a larger retrusion of the maxillary incisors in the subjects of the retrognathic group ($P < .05$).

Mechanism of overjet correction (Figures 3 and 4). The overjet was overcorrected to a frontal crossbite in most subjects in the retrognathic group and the prognathic group. The average reductions of overjet in the retrognathic group (9.4 mm) and in the prognathic group (7.6 mm) were statistically comparable. In the retrognathic group, overjet correction comprised 17% skeletal and 83% dental changes. In the prognathic group, the correction comprised 24% skeletal and 76% dental changes.

Mechanism of molar relation correction (Figures 5 and 6). The corrections of Class II molar relation in the

retrognathic group (6.0 mm) and in the prognathic group (5.7 mm) were statistically comparable. In the retrognathic group, Class II molar correction comprised 27% skeletal and 73% dental changes. In the prognathic group, the correction comprised 32% skeletal and 68% dental changes.

Changes during the posttreatment period T3–T2

Retrognathic and prognathic groups (Table 2). Both the retrognathic and prognathic groups showed the following recovering changes leading to an overjet increase and a change of the molar relation in a Class II direction: The lower incisors moved posteriorly (retrognathic group $P > .05$ [not significant]; prognathic group $P < .001$), and the upper molars moved anteriorly ($P < .05$).

Group comparison (Table 2). Maxillary base advancement and upper incisor protrusion were larger in the subjects of the prognathic group ($P < .05$).

Mechanism of overjet-recovery (Figures 3 and 4). The increases of overjet in the retrognathic group (3.2 mm) and in the prognathic group (2.5 mm) were statistically comparable. In the retrognathic group, overjet recovery comprised 19% skeletal and 81% dental

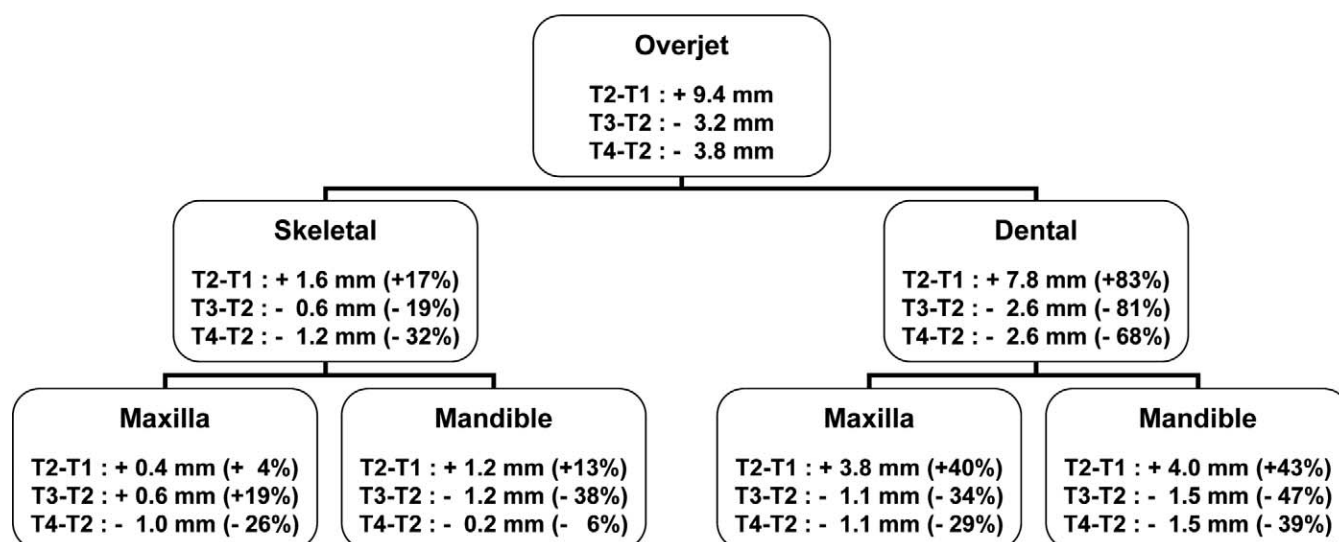


Figure 3. SO-analysis: skeletal and dental components contributing to overjet changes in the retrognathic group. Plus (+) means favorable changes aiming at overjet correction; minus (–), unfavorable changes aiming at overjet correction. T1 is before Herbst treatment; T2, after Herbst treatment; T3, 12 months after Herbst treatment; and T4, 39 months after Herbst treatment.

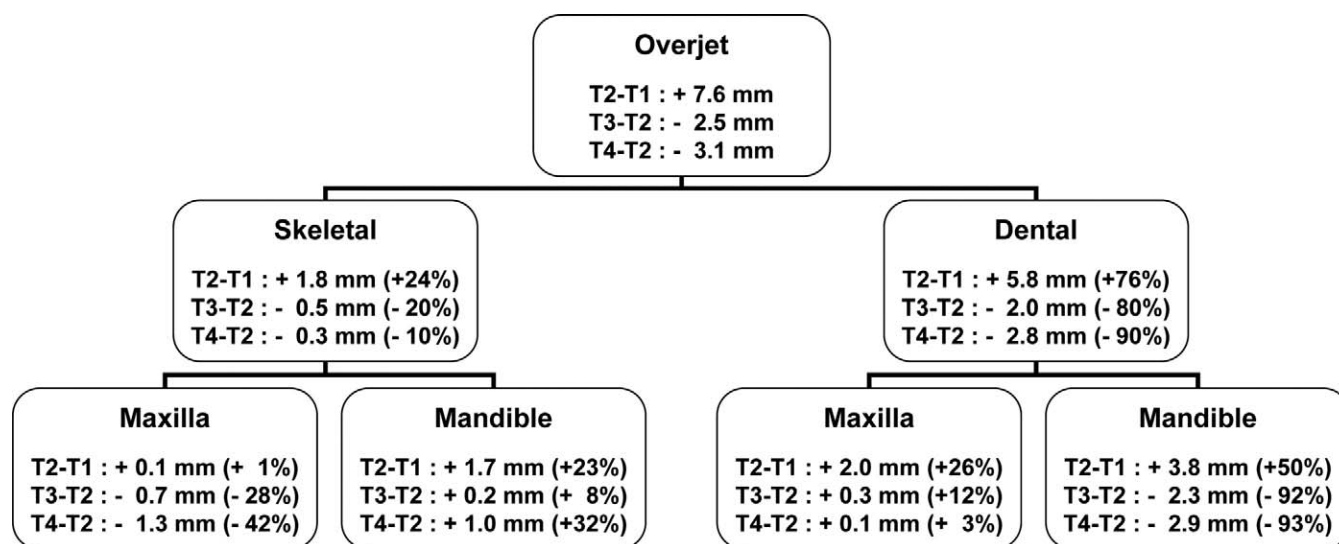


Figure 4. SO-analysis: skeletal and dental components contributing to overjet changes in the prognathic group. Plus (+) means favorable changes aiming at overjet correction; minus (–), unfavorable changes aiming at overjet correction. T1 is before Herbst treatment; T2, after Herbst treatment; T3, 12 months after Herbst treatment; and T4, 39 months after Herbst treatment.

changes. In the prognathic group, the recovery comprised 20% skeletal and 80% dental changes.

Mechanism of molar relation-recovery (Figures 5 and 6). The changes of molar relation in Class II direction in the retrognathic group (2.2 mm) and in the prognathic group (1.6 mm) were statistically comparable. In the retrognathic group, molar relation recovery comprised 27% skeletal and 73% dental changes. In the prognathic group, the recovery comprised 31% skeletal and 69% dental changes.

Changes during the posttreatment period T4–T2

Retrognathic and prognathic groups (Table 2). Both the retrognathic and prognathic groups showed the following recovering changes leading to an overjet increase and a change of the molar relation in Class II direction: The lower incisors moved posteriorly (retrognathic group $P > .05$ [not significant], prognathic group $P < .001$) and the upper molars moved anteriorly ($P < .01$).

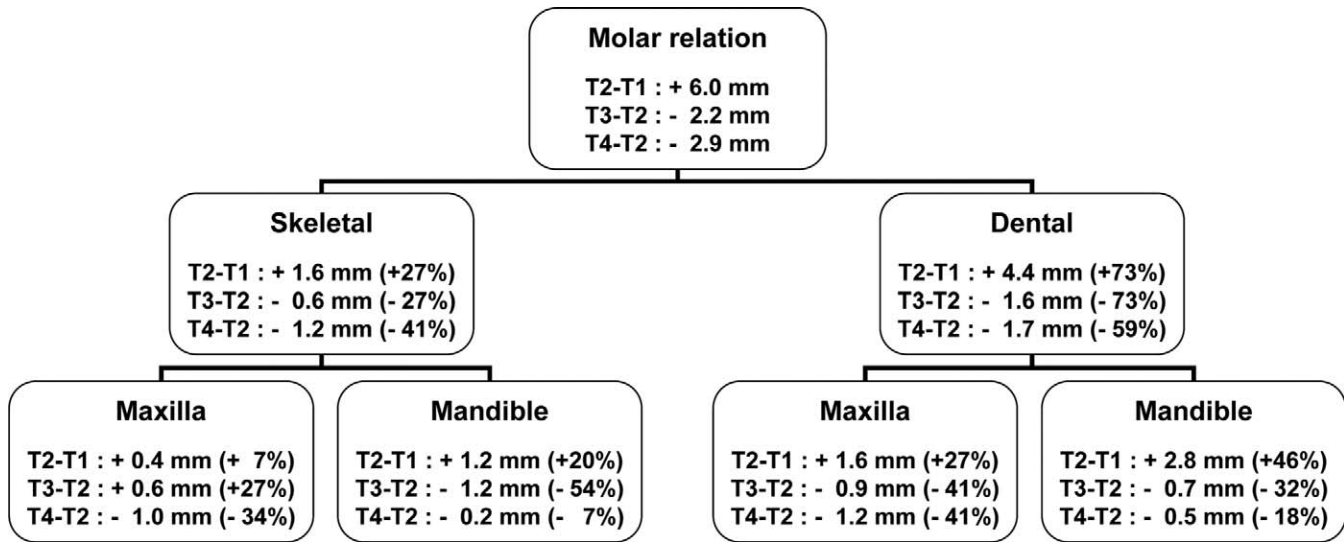


Figure 5. SO-analysis: skeletal and dental components contributing to molar relation changes in the retrognathic group. Plus (+) means favorable changes aiming at Class II molar correction; minus (-), unfavorable changes aiming at Class II molar correction. T1 is before Herbst treatment; T2, after Herbst treatment; T3, 12 months after Herbst treatment; and T4, 39 months after Herbst treatment.

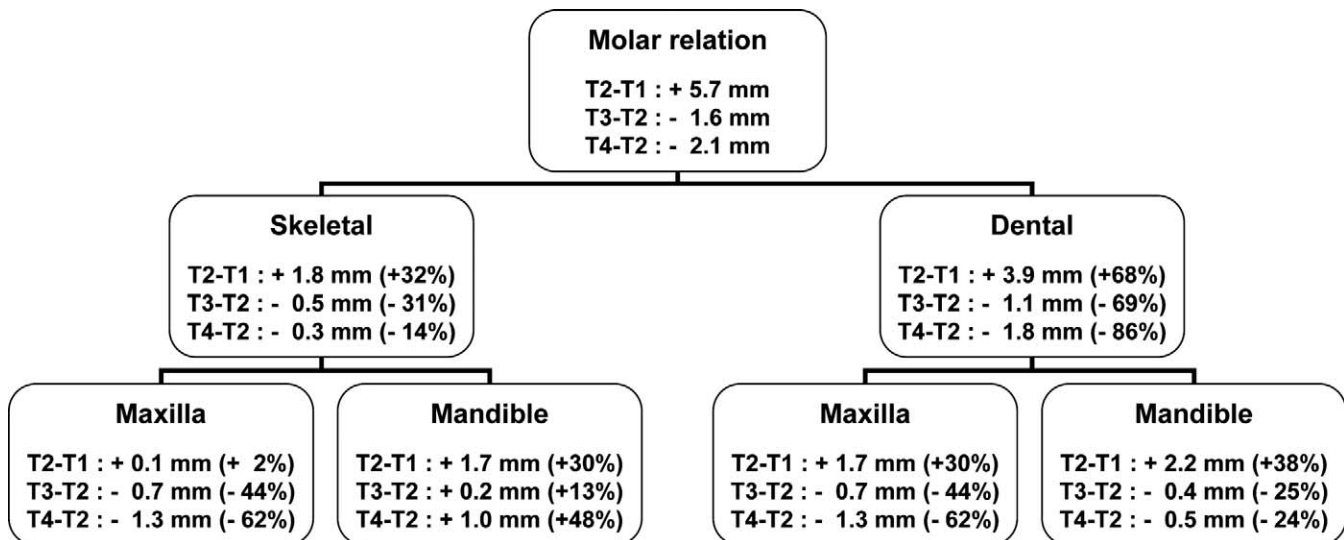


Figure 6. SO-Analysis: skeletal and dental components contributing to molar relation changes in the prognathic group. Plus (+) means favorable changes aiming at Class II molar correction; minus (-), unfavorable changes aiming at Class II molar correction. T1 is before Herbst treatment; T2, after Herbst treatment; T3, 12 months after Herbst treatment; and T4, 39 months after Herbst treatment.

Group comparison (Table 2). For all variables, no significant group difference could be found.

Mechanism of overjet recovery (Figures 3 and 4). The increases of overjet in the retrognathic group (3.8 mm) and in the prognathic group (3.1 mm) were statistically comparable. In the retrognathic group, overjet recovery comprised 32% skeletal and 68% dental changes. In the prognathic group, the recovery comprised 10% skeletal and 90% dental changes.

Mechanism of molar relation recovery (Figures 5 and 6). The changes of molar relation in Class II direction in the retrognathic group (2.9 mm) and in the

prognathic group (2.1 mm) were statistically comparable. In the retrognathic group, molar relation recovery comprised 41% skeletal and 59% dental changes. In the prognathic group, the recovery comprised 14% skeletal and 86% dental changes.

Standard Cephalometrics

The cephalometric records of the retrognathic and prognathic subjects at the different times of examination are shown in Table 3.

Table 3. Standard Cephalometrics: Records of 10 Retrognathic and 16 Prognathic Herbst Subjects^a

		Retrognathic Group				Prognathic Group			
		T1	T2	T3	T4	T1	T2	T3	T4
		Mean (SD)	Mean (SD)	Mean (SD)	Mean (SD)	Mean (SD)	Mean (SD)	Mean (SD)	Mean (SD)
Sagittal jaw relationship	SNA	74.4 (1.43)	74.0 (1.45)	73.5 (1.34)	73.8 (2.17)	86.7 (2.00)	85.7 (2.40)	85.6 (2.51)	85.2 (3.03)
	SNB	70.4 (1.16)	71.2 (1.41)	70.7 (1.28)	70.6 (2.22)	81.5 (1.57)	81.8 (2.10)	81.5 (2.53)	81.3 (3.08)
	ANB	4.0 (1.08)	2.8 (1.43)	2.8 (1.62)	3.2 (1.44)	5.2 (1.86)	3.9 (1.46)	4.0 (1.80)	3.9 (1.80)
Vertical jaw relationship	NL/NSL	12.4 (2.84)	12.8 (3.09)	13.0 (3.23)	12.5 (2.91)	5.8 (3.38)	6.1 (3.20)	6.3 (3.51)	6.5 (3.75)
	ML/NL	28.7 (4.38)	29.2 (5.15)	29.1 (5.36)	28.6 (5.35)	19.3 (3.80)	19.6 (3.74)	19.0 (3.51)	17.9 (4.00)
	ML/NSL	41.1 (3.26)	42.0 (3.76)	42.1 (4.22)	41.1 (4.73)	25.1 (4.35)	25.7 (4.60)	25.3 (4.53)	24.4 (5.48)
Gonial angle	Ar-Go-Gn	136.8 (5.29)	137.9 (5.83)	137.0 (6.00)	135.9 (6.27)	128.5 (3.97)	128.8 (3.63)	127.8 (4.18)	125.9 (4.06)
Profile convexity	N-A-Pg	174.5 (3.66)	177.4 (3.44)	177.5 (3.67)	177.1 (3.29)	172.2 (4.81)	175.1 (4.22)	174.9 (4.65)	175.2 (4.42)
	Ns-Sn-Pgs	157.7 (2.97)	160.9 (1.61)	159.9 (3.12)	161.0 (3.63)	158.0 (4.99)	160.6 (5.27)	159.6 (5.83)	159.5 (5.60)
	Ns-No-Pgs	129.9 (3.44)	132.1 (4.10)	131.1 (3.80)	130.7 (4.30)	128.7 (4.16)	130.3 (4.74)	129.5 (5.58)	128.4 (5.26)

^a T1, before treatment; T2, after treatment; T3, 12 months after treatment; T4, 39 months after treatment; Aberrations of the cephalometric variables in Figure 2.

Table 4. Standard Cephalometrics: Changes (D) During the Treatment (T2–T1) and Posttreatment (T3–T2, T4–T2) Periods in 10 Retrognathic and 16 Prognathic Herbst Subjects^{a,b}

			Retrognathic Group				Prognathic Group				Group Difference Retrognathic-Prognathic		
			Mean D	SD	<i>t</i>	<i>P</i>	Mean D	SD	<i>t</i>	<i>P</i>	Mean D	<i>t</i>	<i>P</i>
Sagittal jaw relationship	SNA	T2–T1	−0.4	0.62	−1.99	ns	−1.0	0.76	−5.11	***	+0.6	+1.95	ns
		T3–T2	−0.5	0.81	−2.01	ns	−0.2	0.90	−0.74	ns	−0.3	−1.01	ns
		T4–T2	−0.2	1.10	−0.54	ns	−0.5	1.57	−1.27	ns	+0.3	+0.53	ns
	SNB	T2–T1	+0.8	0.87	+2.91	*	+0.3	1.48	+0.77	ns	+0.6	+1.00	ns
		T3–T2	−0.5	1.09	−1.48	ns	−0.3	1.17	−1.13	ns	−0.2	−0.42	ns
		T4–T2	−0.6	1.62	−1.11	ns	−0.5	1.90	−0.99	ns	−0.1	−0.15	ns
	ANB	T2–T1	−1.2	1.08	−3.44	**	−1.3	1.27	−3.96	**	+0.1	+0.11	ns
		T3–T2	0.0	0.92	0.0	ns	+0.1	0.77	+0.32	ns	−0.1	−0.18	ns
		T4–T2	+0.4	1.08	+1.21	ns	0.0	0.88	−0.14	ns	+0.4	+1.15	ns
Vertical jaw relationship	NL/NSL	T2–T1	+0.4	0.69	+1.97	ns	+0.3	0.83	+1.59	ns	+0.1	+0.34	ns
		T3–T2	+0.2	0.59	+0.89	ns	+0.2	0.95	+0.83	ns	0.0	−0.08	ns
		T4–T2	−0.3	1.01	−0.89	ns	+0.4	1.16	+1.17	ns	−0.7	−1.39	ns
	ML/NL	T2–T1	+0.5	1.29	+1.17	ns	+0.3	1.13	+1.13	ns	+0.2	+0.34	ns
		T3–T2	−0.1	1.40	−0.27	ns	−0.6	1.12	−2.11	ns	+0.5	+0.94	ns
		T4–T2	−0.6	2.60	−0.65	ns	−1.7	1.56	−4.32	***	+1.2	+1.39	ns
	ML/NSL	T2–T1	+0.9	0.81	+3.50	**	+0.6	1.20	+2.07	ns	+0.3	+0.69	ns
		T3–T2	+0.1	1.32	+0.11	ns	−0.4	1.68	−0.92	ns	+0.5	+0.69	ns
		T4–T2	−0.9	2.07	−1.28	ns	−1.3	2.19	−2.37	*	+0.4	+0.50	ns
Gonial angle	Ar-Go'-Gn	T2–T1	+1.1	1.82	+1.81	ns	+0.3	2.00	+0.67	ns	+0.8	+0.93	ns
		T3–T2	−0.9	1.50	−1.80	ns	−1.0	1.45	−2.75	*	+0.1	+0.21	ns
		T4–T2	−2.0	2.02	−2.97	*	−2.9	2.00	−5.68	***	+0.9	+1.11	ns
Profile convexity	N-A-Pg	T2–T1	+2.9	2.53	+3.41	**	+2.9	1.96	+5.74	***	0.0	−0.03	ns
		T3–T2	+0.1	2.23	+0.19	ns	−0.2	1.38	−0.48	ns	+0.3	+0.42	ns
		T4–T2	−0.3	1.81	−0.46	ns	+0.1	1.81	+0.23	ns	−0.4	−0.50	ns
	Ns-Sn-Pgs	T2–T1	+3.2	2.43	+4.01	**	+2.6	2.18	+4.57	***	+0.6	+0.69	ns
		T3–T2	−1.0	2.42	−1.24	ns	−1.0	2.74	−1.37	ns	0.0	−0.03	ns
		T4–T2	+0.1	2.82	+0.05	ns	−1.1	2.79	−1.58	ns	+1.2	+1.01	ns
	Ns-No-Pgs	T2–T1	+2.2	2.08	+3.10	*	+1.6	1.88	+3.28	**	+0.6	+0.67	ns
		T3–T2	−1.0	2.88	−0.99	ns	−0.8	2.66	−1.11	ns	−0.2	−0.16	ns
		T4–T2	−1.4	2.99	−1.35	ns	−1.9	3.20	−2.29	*	+0.5	+0.47	ns

^a T1, before treatment; T2, after treatment; T3, 12 months after treatment; T4, 39 months after treatment; Aberrations of the cephalometric variables in Figure 2.

^b In the separate groups, plus (+) means favorable changes and minus (–) means unfavorable changes aiming at Class II correction.

*** $P < .001$; ** $P < .01$; * $P < .05$; ns, $P \geq .05$.

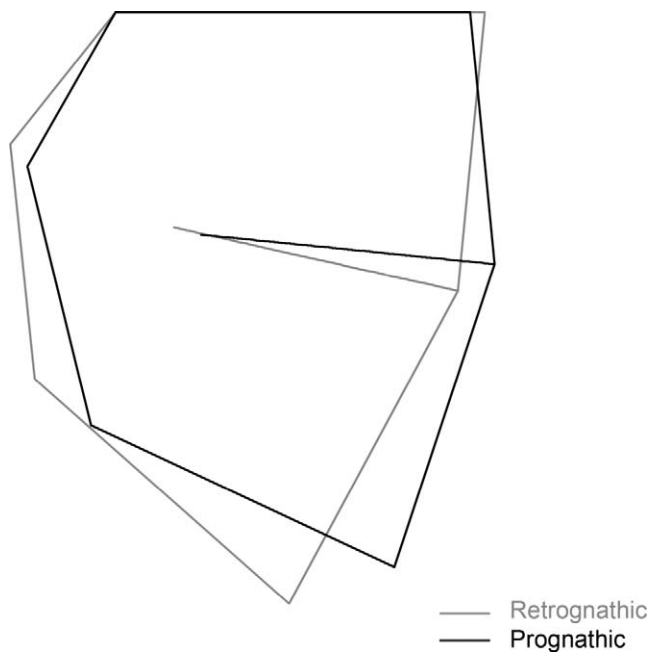


Figure 7. Facial polygons visualizing the skeletofacial morphology of the retrognathic and prognathic group before Herbst treatment.

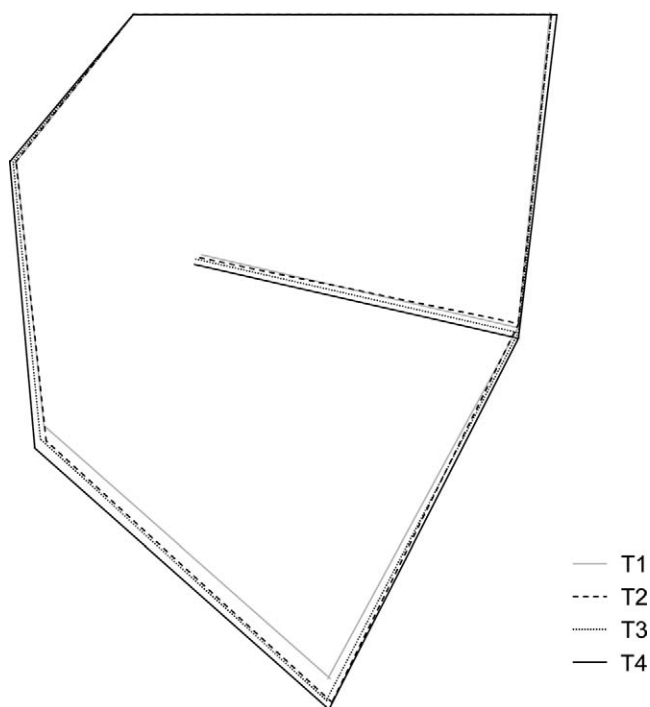


Figure 8. Facial polygons visualizing mean changes in skeletofacial morphology of 10 retrognathic subjects. T1 is before Herbst treatment; T2, after Herbst treatment; T3, 12 months after Herbst treatment; and T4, 39 months after Herbst treatment.

Changes during the treatment period T2–T1

Retrognathic and prognathic groups (Table 4). Both groups showed the following favorable changes in the sagittal dimension contributing to Class II correction:

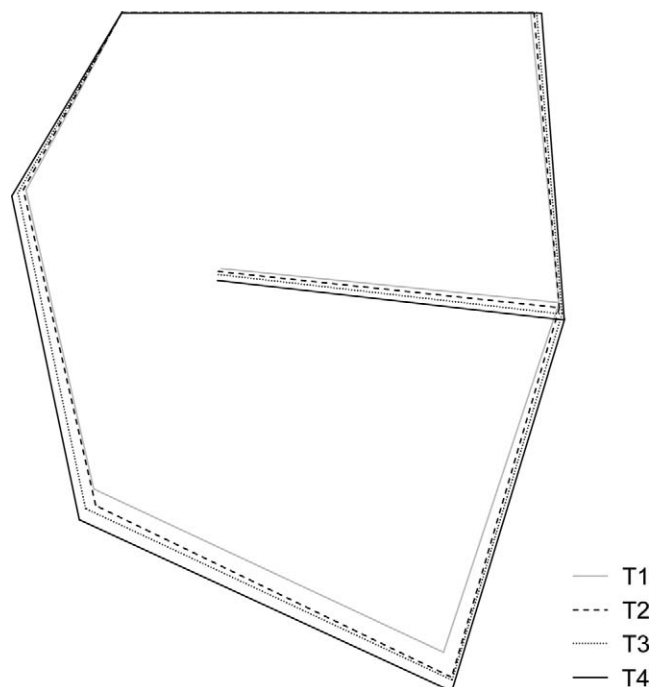


Figure 9. Facial polygons visualizing mean changes in skeletofacial morphology of 16 prognathic subjects. T1 is before Herbst treatment; T2, after Herbst treatment; T3, 12 months after Herbst treatment; and T4, 39 months after Herbst treatment.

- The SNA angle decreased (retrognathic group 0.4° , $P > .05$ [not significant]; prognathic group 1.0° , $P < .001$); and
- The SNB angle increased (retrognathic group 0.8° , $P < .05$; prognathic group 0.3° , $P > .05$ [not significant]), resulting in a decrease of the ANB angle (retrognathic group 1.2° , $P < .01$; prognathic group 1.3° , $P < .01$).

Regarding the vertical dimension, the angle ML/NSL increased (retrognathic group 0.9° , $P < .01$; prognathic group 0.6° , $P > .05$ [not significant]). Furthermore, the angles expressing facial profile convexity increased:

- Hard tissue profile (retrognathic group 2.9° , $P < .01$; prognathic group 2.9° , $P < .001$);
- Soft tissue profile excluding the nose (retrognathic group 3.2° , $P < .01$; prognathic group 2.6° , $P < .001$); and
- Soft tissue profile including the nose (retrognathic group 2.2° , $P < .05$; prognathic group 1.6° , $P < .01$).

Group comparison (Table 4). No significant group difference could be found for any of the variables.

Changes during the posttreatment period T3–T2

Retrognathic and prognathic groups (Table 4). The only significant change that could be found in this period was a decrease of the gonion angle (retrognathic

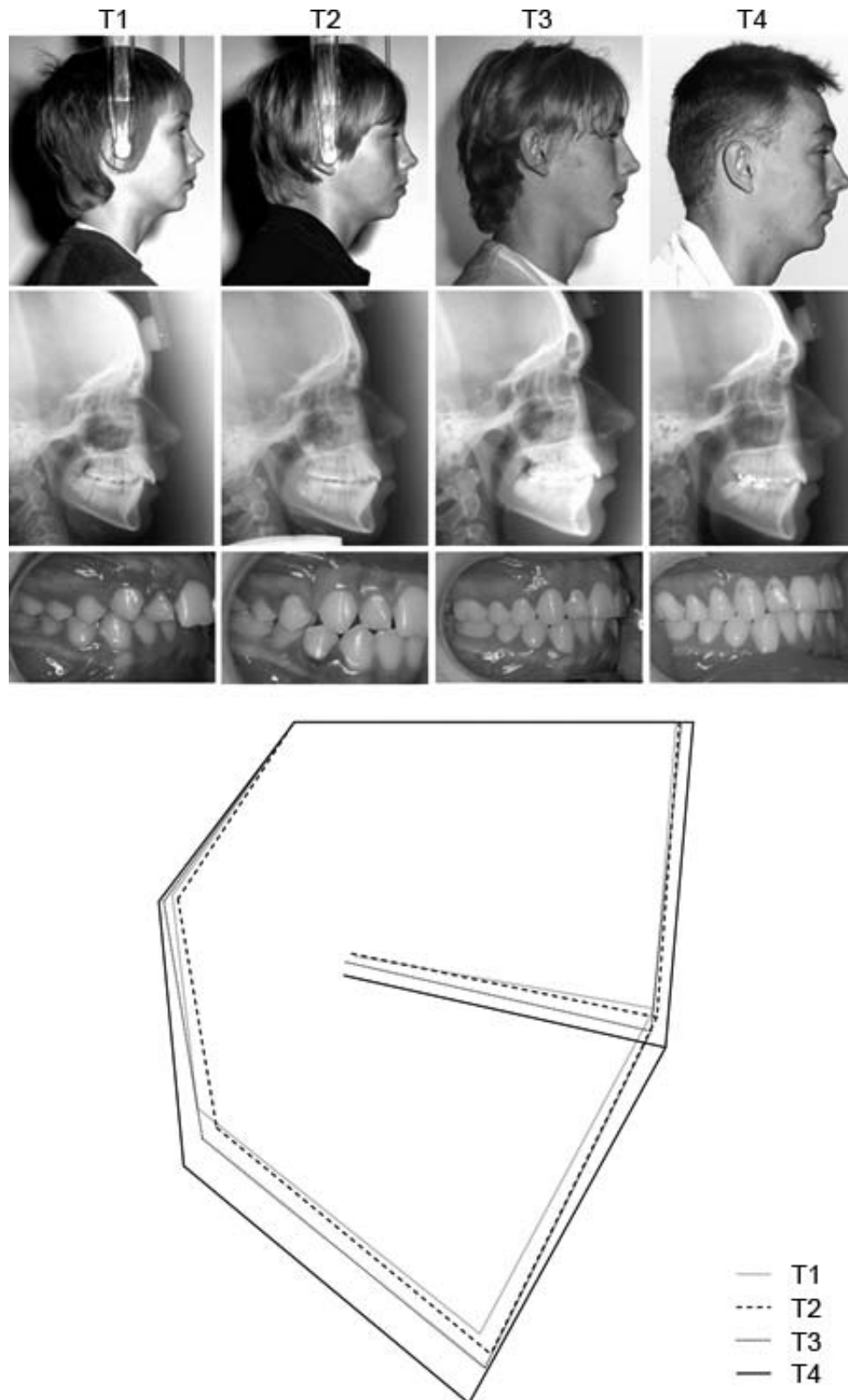


Figure 10. Case 1: a 12-year-old male of the retrognathic facial type. Extraoral photographs, lateral head films, intraoral photographs, and superimposed facial polygons. T1 is before Herbst treatment; T2, after 7 months of Herbst treatment; T3, 12 months after Herbst treatment; and T4, 37 months after Herbst treatment. Before treatment (T1) recordings: overjet = 9.0 mm, full Class II molar relation, SNA = 75.5°, SNB = 71.5°, and ML/NSL = 38.5°. Follow-up (T4) recordings: overjet = 4.0 mm, Class I molar relation, SNA = 74.0°, SNB = 71.5°, and ML/NSL = 40.0°.

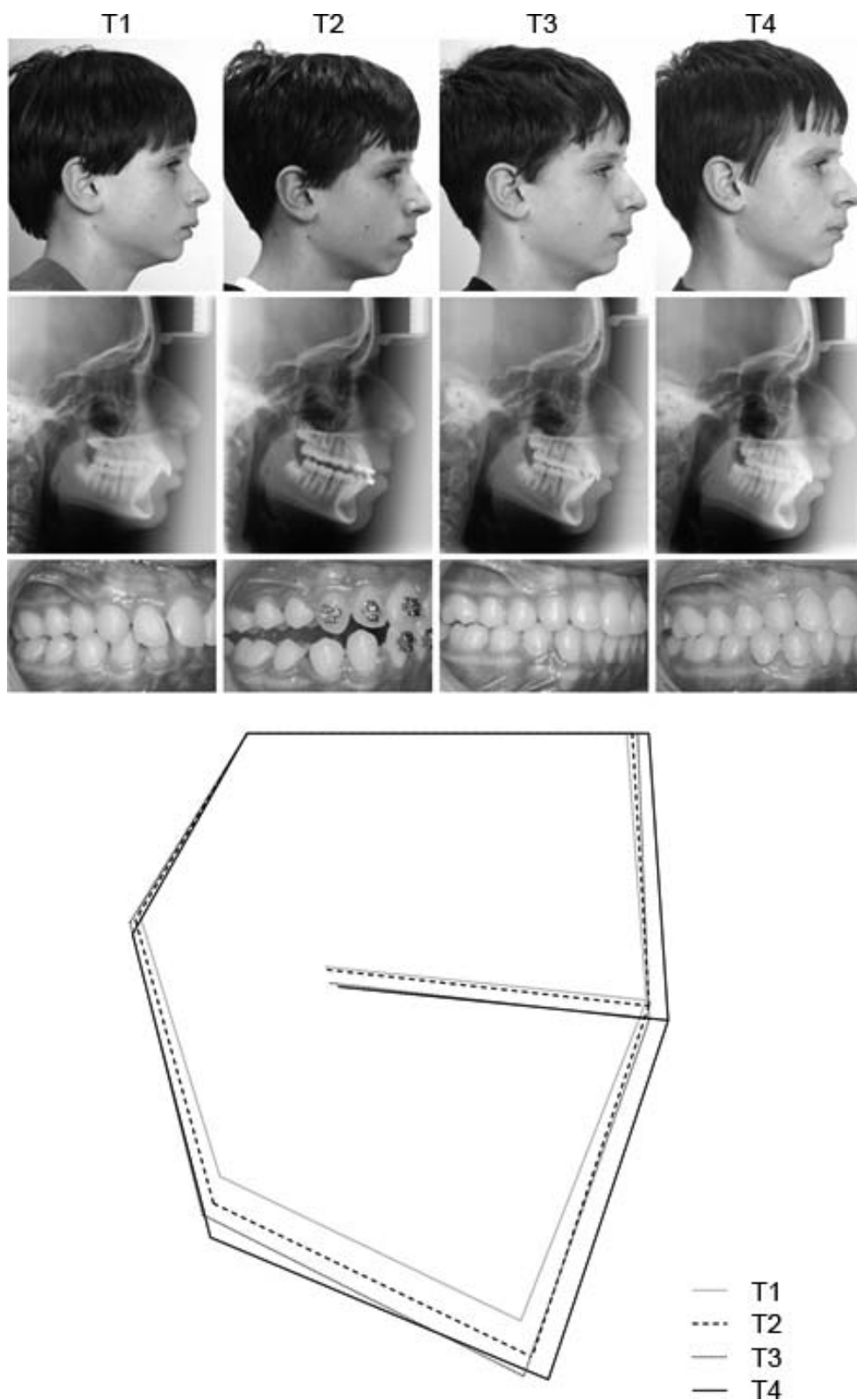


Figure 11. Case 2: a 14-year-old male of the prognathic facial type. Extraoral photographs, lateral head films, intraoral photographs, and superimposed facial polygons. T1 is before Herbst treatment; T2, after 7 months of Herbst treatment; T3, 12 months after Herbst treatment; and T4, 36 months after Herbst treatment. Before treatment (T1) recordings: overjet = 7.0 mm, half a cusp Class II molar relation, $SNA = 86.5^\circ$, $SNB = 80.0^\circ$, and $ML/NSL = 25.0^\circ$. Follow-up (T4) recordings: overjet = 4.0 mm, Class I molar relation, $SNA = 87.0^\circ$, $SNB = 80.5^\circ$, and $ML/NSL = 22.0^\circ$.

group 0.9° , $P > .05$ [not significant]; prognathic group 1.0° , $P < .05$).

Group comparison (Table 4). No significant group difference could be found for any of the variables.

Changes during the posttreatment period T4–T2

Retrognathic and prognathic groups (Table 4). In the sagittal dimension, no significant changes were seen for either group. In the vertical dimension, the following changes occurred: the angle ML/NL decreased (retrognathic group 0.6° , $P > .05$ [not significant]; prognathic group 1.7° , $P < .001$), and the angle ML/NSL decreased (retrognathic group 0.9° , $P > .05$ [not significant]; prognathic group 1.3° , $P < .05$). Furthermore, the gonion angle decreased (retrognathic group 2.0° , $P < .05$; prognathic group 2.9° , $P < .001$). In profile convexity, the soft tissue profile angle including the nose decreased (retrognathic group 1.4° , $P > .05$ [not significant]; prognathic group 1.9° , $P < .05$).

Group comparison (Table 4). No significant group difference could be found for any of the variables.

DISCUSSION

The general belief that Class II treatment in patients of the retrognathic facial type is more difficult than in patients of the prognathic facial type could not be verified with the results of this study, at least not when using the Herbst appliance and considering the immediate treatment effects.

In evaluating the results, it should be kept in mind that they are based on relatively small sample sizes with no controls. Therefore, this investigation must be considered a pilot study. It is planned to extend the investigation by using larger sample sizes matching the subjects with respect to age and gender.

During the treatment period T2–T1, all retrognathic and prognathic Class II subjects were treated successfully to an overcorrected sagittal dental arch relationship by the Herbst appliance. Class II correction was a result of both skeletal and dental components. Because both the retrognathic and the prognathic subjects showed comparable changes for most of the cephalometric variables (SO-analysis and standard cephalometrics), it can be hypothesized that the immediate success of Herbst treatment is independent of the facial type. This assumption is supported by Ruf and Pancherz⁶ who found Herbst treatment to be successful in both hypodivergent and hyperdivergent Class II subjects.

During the posttreatment period of 12 months (T3–T2) in both facial type groups, the occlusion settled¹³ to a stable Class I tooth interdigitation¹⁴ and the overjet recovered to a normal value. A stable cuspal interdigitation implies that unfavorable growth changes long-

term (after T3), as seen especially in the retrognathic subjects, can be buffered by the occlusion. This was confirmed by the fact that during the posttreatment period (T4–T2) no clinically significant relapse in the overjet and sagittal molar relationship occurred in any of the retrognathic and prognathic subjects.

When comparing the skeletal morphology of the retrognathic and the prognathic groups (Figure 7), the difference in sagittal and vertical posttreatment growth development can be identified in the superimposed facial polygons. Although the mandibular growth changes in the retrognathic subjects (Figures 8 and 10) obviously have a more vertical direction, the mandibular growth changes seen in the prognathic subjects (Figures 9 and 11) show a more anterior direction.

When comparing the findings of the two facial type groups, it should be kept in mind that the subjects were not comparable with respect to their growth periods at the beginning and at the end of treatment. This will certainly influence the amount of growth but not the growth pattern.¹⁵ However, the retrognathic subjects reacted equally well as the prognathic subjects. This was especially true for the period of active treatment. However, during the posttreatment period, the stability of the treatment results tended to be better in the prognathic group. Therefore, the influence of the difference in skeletal maturation on the treatment results probably was not very strong.

Furthermore, in previous investigations it was found that the amount and direction of temporomandibular joint growth changes (condyle and fossa) can be affected in a favorable sagittal direction only temporarily by Herbst treatment,¹⁶ and sagittal treatment changes are more pronounced in hyperdivergent than in hypodivergent subjects.

CONCLUSIONS

- On a short-term basis, successful Herbst therapy seems to be independent of the facial type.
- On a long-term basis, however, retrognathic subjects are prone to exhibit a tendency of more unfavorable mandibular growth changes than prognathic subjects and thus might exhibit a greater risk for an occlusal relapse when a stable Class I occlusion is not attained after treatment.

REFERENCES

1. Pancherz H. The mechanism of Class II correction in Herbst appliance treatment. A cephalometric investigation. *Am J Orthod.* 1982;82:104–113.
2. Bishara SE, Jakobsen JR. Longitudinal changes in three normal facial types. *Am J Orthod.* 1985;88:466–502.
3. Hasund A. *Klinische Kephalmetrie für die Bergen-Technik* [in German]. Bergen, Norwegen: Kieferorthopädische Abtei-

- lung des zahnärztlichen Instituts der Universität; 1973;51–58, 63–67.
4. Janson I. *Bionator-Modifikationen in der Kieferorthopädischen Therapie* [in German]. München: Hanser Verlag; 1987; 23–56.
 5. Zaher AR, Bishara SE, Jakobsen JR. Posttreatment changes in different facial types. *Angle Orthod.* 1994;64:425–436.
 6. Ruf S, Pancherz H. The mechanism of Class II correction during Herbst therapy in relation to the vertical jaw base relationship: a cephalometric roentgenographic study. *Angle Orthod.* 1997;67:271–276.
 7. Pancherz H, Michailidou C. Temporomandibular joint growth changes in hyperdivergent and hypodivergent Herbst subjects. A long-term roentgenographic cephalometric study. *Am J Orthod Dentofac Orthop.* 2004;126:53–161.
 8. Herbst E. *Atlas und Grundriss der Zahnärztlichen Orthopädie* [in German]. München: JF Lehmann's Verlag; 1910; 311–315.
 9. Moyers RE. *Handbook of Orthodontics*. Chicago, IL: Year Book Medical Publishers; 1973;292.
 10. Hägg U, Taranger J. Skeletal stages of the hand wrist as indicators of the pubertal growth spurt. *Acta Odontol Scand.* 1980;38:187–200.
 11. Pancherz H, Hägg U. Dentofacial orthopedics in relation to somatic maturation. An analysis of 70 consecutive cases treated with the Herbst appliance. *Am J Orthod.* 1985;88:273–287.
 12. Graber TM, Rakosi T, Petrovic AG. *Dentofacial Orthopedics with Functional Appliances*, 2nd ed. St Louis, MO: Mosby; 1997;336–366.
 13. Pancherz H, Hansen K. Occlusal changes during and after Herbst treatment: a cephalometric investigation. *Eur J Orthod.* 1986;8:215–228.
 14. Pancherz H. The nature of Class II relapse after Herbst appliance treatment. A cephalometric long-term investigation. *Am J Orthod Dentofac Orthop.* 1991;100:220–233.
 15. Pancherz H, Fackel U. The skeletofacial growth pattern pre- and post- dentofacial orthopaedics. A long-term study of Class II malocclusions treated with the Herbst appliance. *Eur J Orthod.* 1990;12:209–218.
 16. Pancherz H, Fischer S. Amount and direction of temporomandibular joint growth changes in Herbst treatment: a cephalometric long-term investigation. *Angle Orthod.* 2003;73:493–501.