

Uprighting Partially Impacted Permanent Second Molars

Monika Sawicka^a; Bogna Racka-Pilszak^a; Anna Rosnowska-Mazurkiewicz^b

Abstract: Impaction of the lower second molar is not a common problem, but it is very challenging for both orthodontist and oral surgeon. Treatment options depend on the degree of tooth inclination, the position of the third molars, and the desired type of movement, which may be surgical and/or orthodontic in nature. A good treatment alternative is surgical uncovering with orthodontically-assisted eruption. A case of successful uprighting using a 0.017 × 0.025-inch titanium molybdenum alloy (TMA) tip-back cantilever is presented. Different aspects of uprighting impacted second molars are discussed in light of the literature. The iatrogenic character of lower second molar impaction is emphasized.

Key Words: Molar uprighting; Second molar impactions; Tip-back cantilever

INTRODUCTION

The impaction of permanent teeth usually concerns the maxillary or mandibular third molars, maxillary canines or central incisors, and mandibular second premolars.¹ Eruption disturbances of mandibular second permanent molars are rather rare. The incidence of second molar impaction revealed by panoramic radiograph studies has been reported as 0.03%² to 0.04%³ of all impacted teeth.

The etiology of impaction is related to some disturbance of physiological mandibular growth and tooth development. The space for second permanent molars is obtained by resorption of the bone at the anterior border of the mandibular ramus and mesial migration of the first molar into the leeway space. The tooth bud of the second permanent molar develops with some mesial axial inclination and the ability for natural self-correction manifests as the remodeling changes occur.⁴

Disturbances of this natural process may lead to impaction and be associated with an arch length deficiency⁵ because of inadequate mandible growth. Excess space between the developing second molar and first molar may also result in impaction, probably be-

cause the second molar crown needs the first molar distal root for proper eruption.⁶ The most important iatrogenic factors include an incorrectly fitted band cemented on the first mandibular molar, previous orthodontic sagittal expansion,⁷ and prevention of the mesial shift of the first permanent molar caused by lip-bumper or lingual arch therapy. Sometimes the second molar gets impacted spontaneously, which is probably related to the third molar position.⁸

Advantages of impacted molar uprighting and extrusion are functional, periodontal, and restorative. Uprighting second molars allows avoidance of a shortening of the occlusal plane that may result from impacted tooth loss, especially in cases of unpredictable third molar position. Moreover, unopposed teeth have a tendency to erupt excessively. The periodontal benefit of molar uprighting is the elimination of the pseudopocket, which facilitates plaque control in the area.⁹ Because proper oral hygiene in the area of impacted teeth is difficult, caries may easily affect unerupted teeth. Uprighting of impacted molars, therefore, seems beneficial in caries prevention. Undiagnosed second molar impaction may damage the distal root of the first molar, as shown in the panoramic radiograph of a 24-year-old woman in Figure 1.

The best time to treat impacted mandibular second molars is between 11 and 14 years of age, when development of the second permanent molar roots is still incomplete. The treatment options depend on the degree of tooth inclination as well as the required tooth movement. The position of a slightly-tipped molar can be corrected by placing a brass wire separator between the teeth.¹⁰ A more severe inclination requires surgical methods or orthodontically-assisted eruption with or without surgical uncovering. Surgical methods

^a Research Assistant, Department of Orthodontics, Medical University of Gdansk, Gdansk, Poland.

^b Department Head, Department of Orthodontics, Medical University of Gdansk, Gdansk, Poland.

Corresponding author: Dr. Monika Sawicka, Department of Orthodontics, Medical University of Gdansk, Al. Zwyciestwa 42c, Gdansk, woj. Pomorskie 80-210, Poland (e-mail: msawicka@amg.gda.pl)

Accepted: March 2006. Submitted: January 2006.

© 2006 by The EH Angle Education and Research Foundation, Inc.

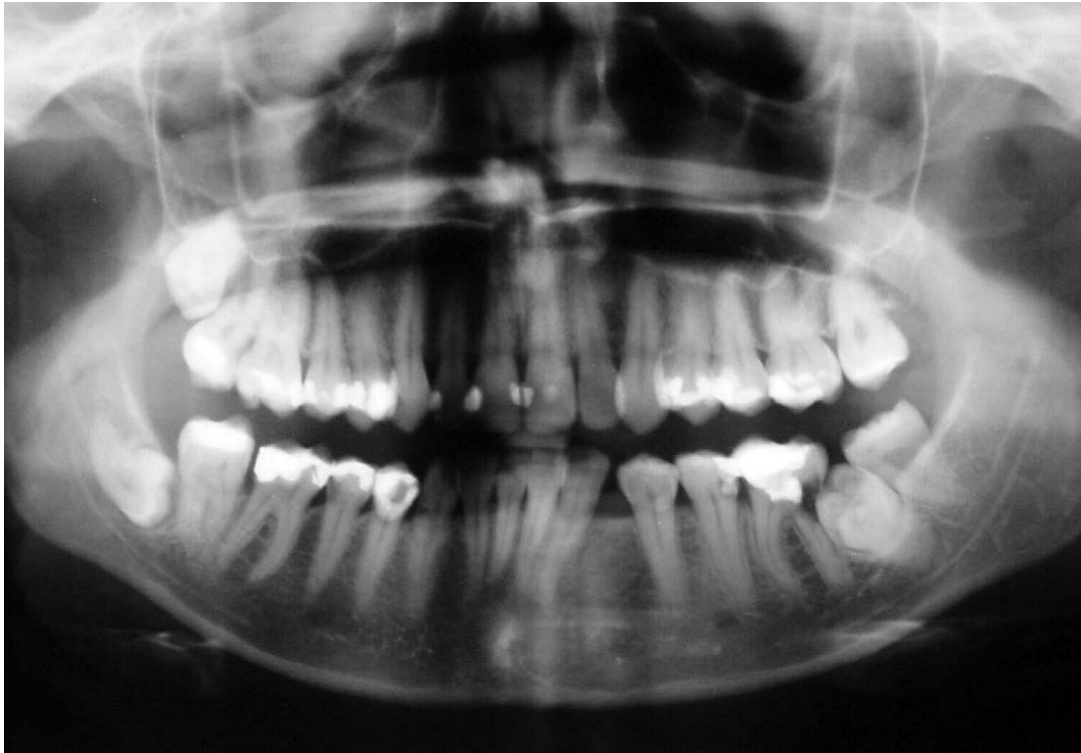


Figure 1. Panoramic radiograph of 24-year-old woman showing damage of first molar distal root by impacted left second molar.

include surgical repositioning with or without extraction of the third molar^{11–17} or extraction of the impacted second molar to allow either eruption of the third molar or transplanting the third molar to the second molar socket¹⁸

A good treatment option is orthodontically-assisted eruption with or without surgical uncovering. The general treatment approach is an attachment, if necessary, bonded to the surgically uncovered buccal or distobuccal surface and subsequently some uprighting force delivered by means of applying a NiTi-coil spring,¹⁹ superelastic NiTi wire,⁷ a variety of uprighting springs,^{20–25} or a sectional arch wire.²⁶

Some authors have suggested bracketing techniques after surgical exposure and the use of the NiTi wire for molar uprighting.^{8,27} Some appliances are located lingually and are therefore very useful in cases with limited buccal access.^{28,29} Placing titanium mini-screws in the retromolar area for molar uprighting was recommended by Giancotti et al.³⁰ This paper discusses the biomechanics of a simple tip-back cantilever³¹ and presents a successful orthodontic treatment that corrected a patient's partially impacted second mandibular molars.

Biomechanical Considerations

Molar uprighting may be secured by a pure rotation obtained by application of a pure couple force system

with a high moment-to-force ratio (so that the center of rotation is very close to the center of resistance). A long cantilever gives a high moment-to-force ratio, which results in a clinical effect very close to that of pure rotation. The magnitude of the moment required to rotate a molar has been suggested to be 800–1500 g/mm.^{31,32}

The cantilever produces effects on the tooth in three planes, mainly in the mesiodistal direction (distal crown tipping) and the vertical direction (molar extrusion). Determining the forces on teeth calls for defining the forces that are delivered to the cantilever inserted in the molar tube. The activation force (A) is directed to the occlusal and is opposed by the apically directed force (B) that the molar tube exerts on the wire. Mesial and distal aspects of the molar tube also exert forces (C and D) on the wire that oppose a counterclockwise rotation resulting from forces A and B (Figure 2). The forces acting on the teeth are of the same magnitude as, but of opposite direction to, the forces acting on the wire (Figure 3). Thus, the intrusive force is on the anterior segment and the extrusive force on the molar, and the couple distally rotates.⁹

CASE REPORT

A 14-year-old female presented with bilateral partial impactions of the lower second molars. Clinically, the patient had a Class I malocclusion with very mild

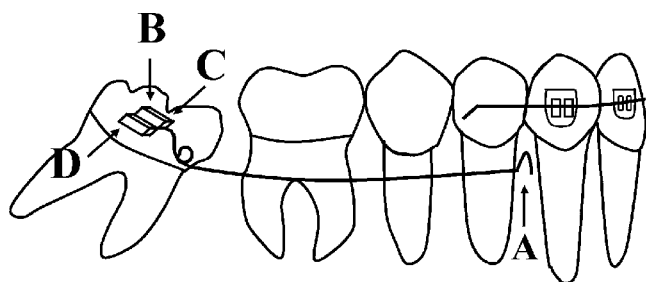


Figure 2. Forces delivered to the cantilever in the process of activation.

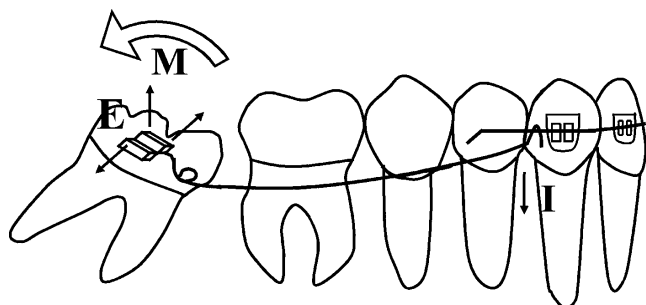


Figure 3. Forces acting on the teeth.

crowding in the anterior segment and distal rotation of both lower canines and the lower right first premolar. The cephalometric measurements were within the norm. The patient's dental development showed an

early permanent dentition with erupting upper second molars and malposition of the lower second molars. The distal cusps of the lower second molars were present in the mouth very close to the distal of the first molar.

A panoramic radiograph revealed the presence of all permanent teeth and a severe mesial inclination of both the lower second molars and developing third molars (Figure 4). Both mandibular second molars were obliquely impacted under the distal bulge of the first molars. The apex of the impacted molar roots was still incompletely formed. The third molar buds were located on top of the second molar distal roots.

The treatment plan was surgical-orthodontic in nature. The surgical procedure was performed in two stages. The first was the uncovering of the buccal aspect of the impacted tooth and bonding a tube to the exposed surface with Smart Bond (Gestenco International AB, Gothenburg, Sweden) adhesive. The second stage—germectomy of the third molars—was to be performed after orthodontic uprighting had been achieved. The orthodontic treatment plan involved the uprighting and extrusion of both second molars and fixed appliance therapy in the lower arch. The patient's parents did not agree to fixed appliance treatment in the upper arch.

One 0.017 × 0.025-inch titanium molybdenum alloy (TMA) cantilever was inserted into each second molar

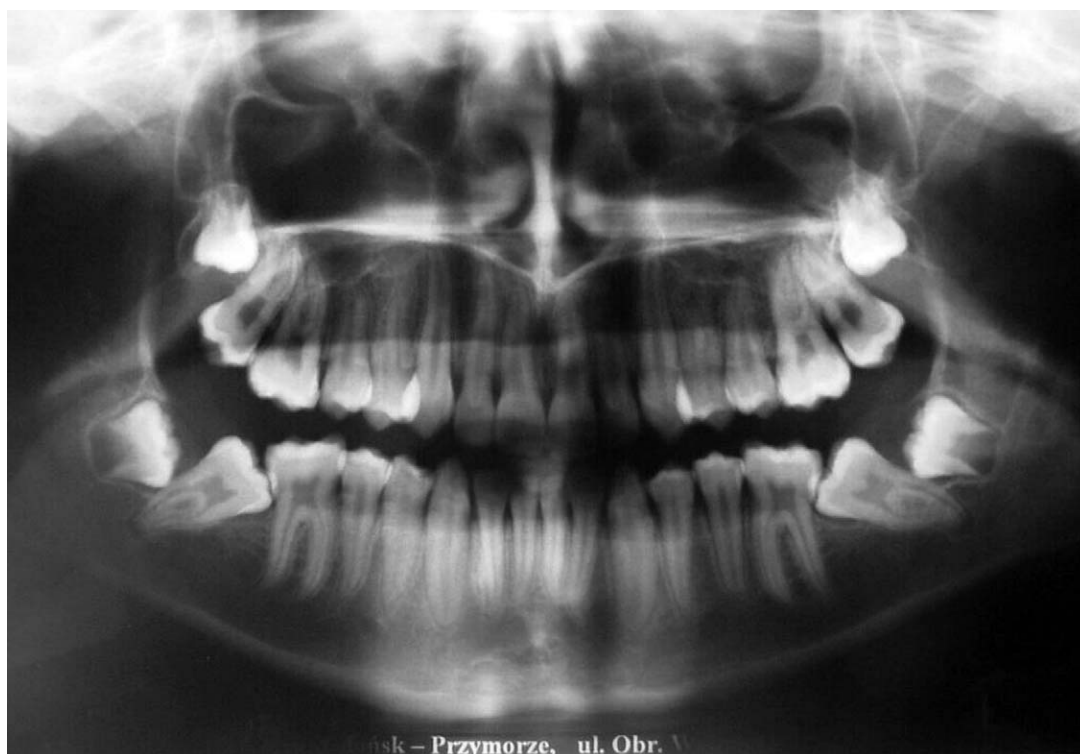


Figure 4. Pretreatment panoramic radiograph shows bilaterally impacted lower second molars.

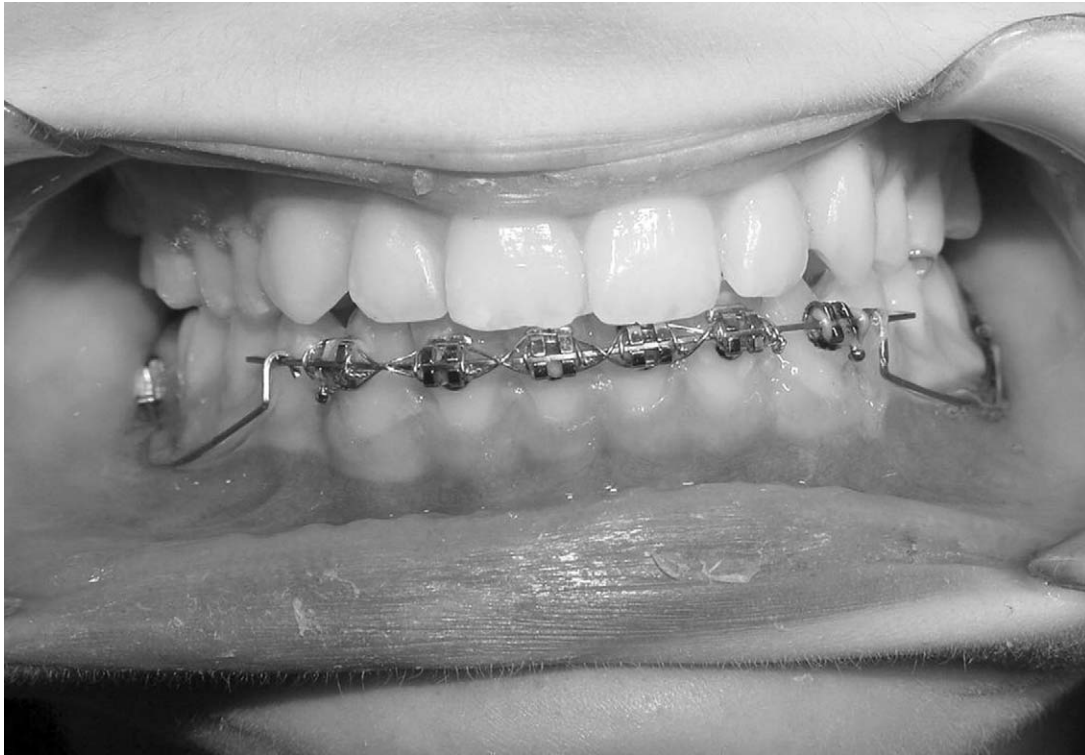

Figure 5. Intraoral photograph at insertion of tip-back uprighting springs.

buccal tube and hooked distally to the canines (Figure 5). Initially, a partial fixed appliance (0.018-inch slot) was used. The activation force measured by a dynamometer amounted to 50 g. The cantilever was 30 mm in length and delivered a moment of 1500 g/mm. The anchorage was secured by the anterior segment with a stiff wire (0.017 × 0.025-inch stainless steel) and a figure eight steel ligature wire was inserted between the canines and by the lingual retainer. The patient was scheduled for follow-ups every 2 weeks to control anchorage and the movements of the impacted teeth. The initial change of inclination was noticed 4 weeks after the application of the device. At this stage, a full fixed appliance was employed.

Later, some 5 months after the beginning of treatment, a satisfactory lower second molar inclination was achieved bilaterally (Figure 6A, B). Subsequently, germectomy of third molars was performed. A corrected inclination of the impacted molars was obtained (Figure 7A–C), and was confirmed on the posttreatment panoramic radiograph (Figure 8).

DISCUSSION

Correction of impaction of the lower second molar has not been adequately presented in the literature. This particular disturbance is rather difficult to prevent because of its multifactorial and often hypothetical etiology, yet a careful orthodontic treatment is required

according to the *primum non nocere* principle. Particular care is called for whenever doing a simple band cementation procedure or the more complex treatment of increasing arch length by distalizing lower first molars. An incorrectly fitted and/or cemented band on the lower first molar may cause second molar impaction and hinder the uprighting process, as is demonstrated in the panoramic radiograph of a 14-year-old girl (Figure 9).

Different treatment options are discussed in the literature. Generally, surgical repositioning and transplantation brings a higher risk of complications, such as pulp necrosis, ankylosis, or root resorption, and therefore should be applied only when orthodontic treatment is contraindicated.^{6,11} If surgical methods are a preferred treatment, it is important to know that surgical repositioning gives a better long-term prognosis than transplantation because the tooth is not removed from the socket. That helps the apical vessels to remain intact and prevents contamination of roots with saliva.¹⁵ Extraction of the impacted tooth to let the third molar erupt also has some disadvantages because of the long time interval between the extraction of the second molar (at age 12–14) and the eruption of the third molar (at age 17).⁶ As a result, the third molar may become tipped and impacted. However, Orton-Gibbs et al,³³ in a study of eruptive path of third molars after second mandibular molar extraction, reported

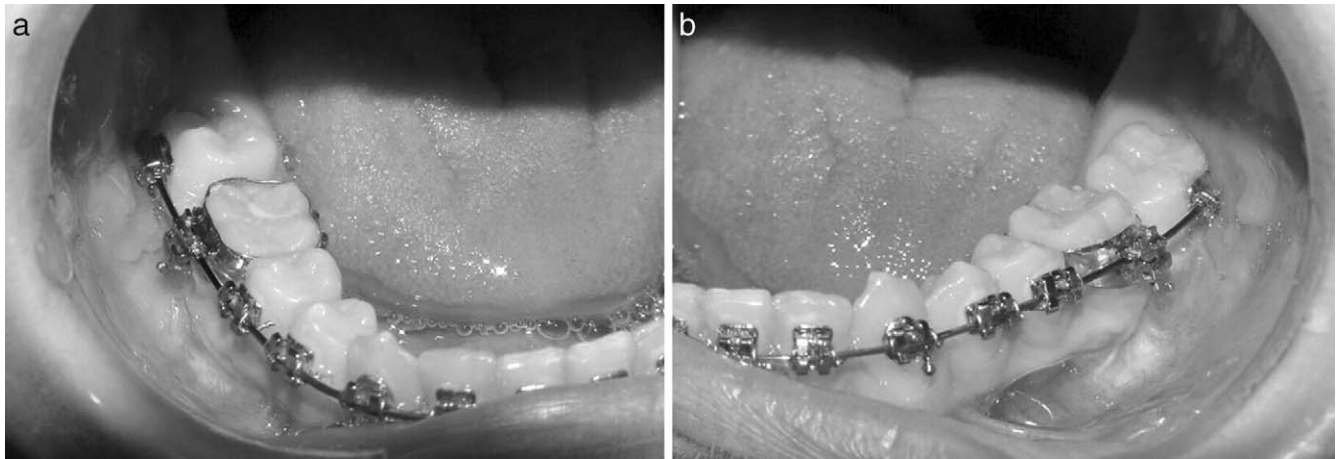


Figure 6. (A) and (B) Intraoral photographs after 5 months showing corrected inclination of lower second molars.

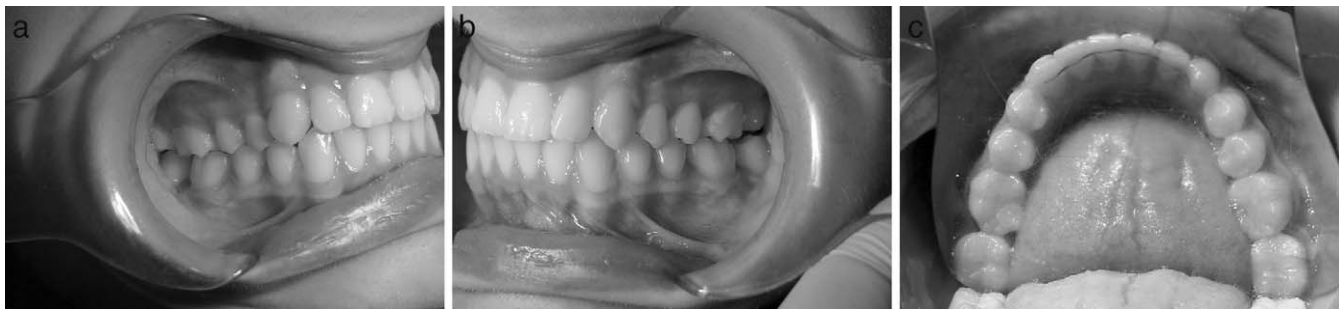

Figure 7. (A), (B), and (C). Posttreatment intraoral photographs showing corrected inclination of lower second molars.

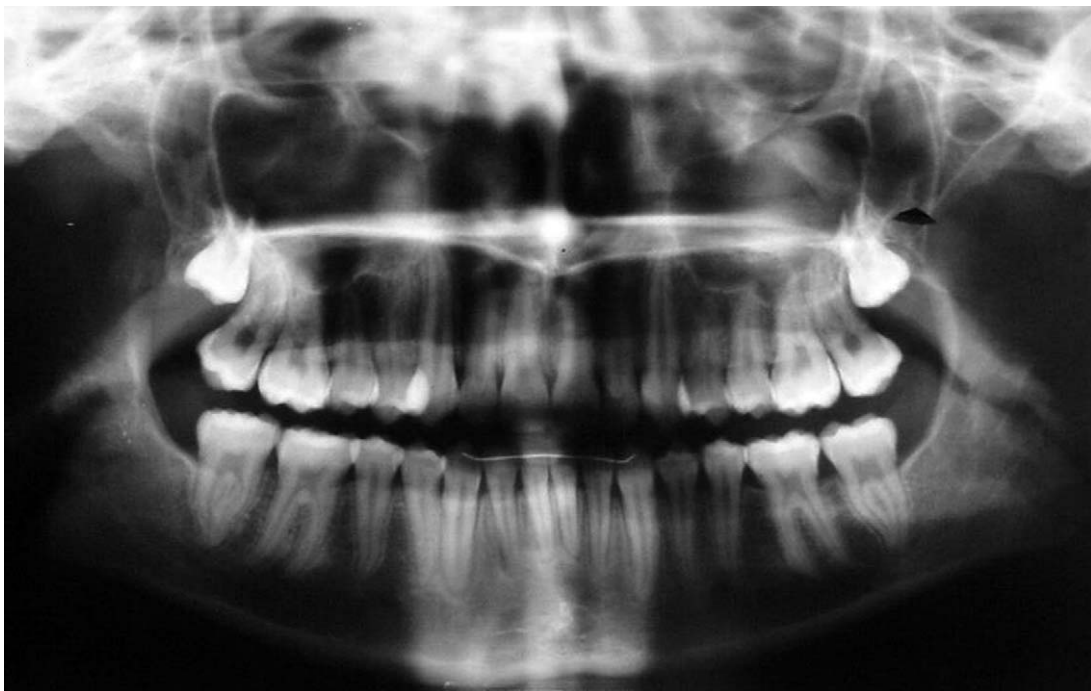


Figure 8. Posttreatment panoramic radiograph.

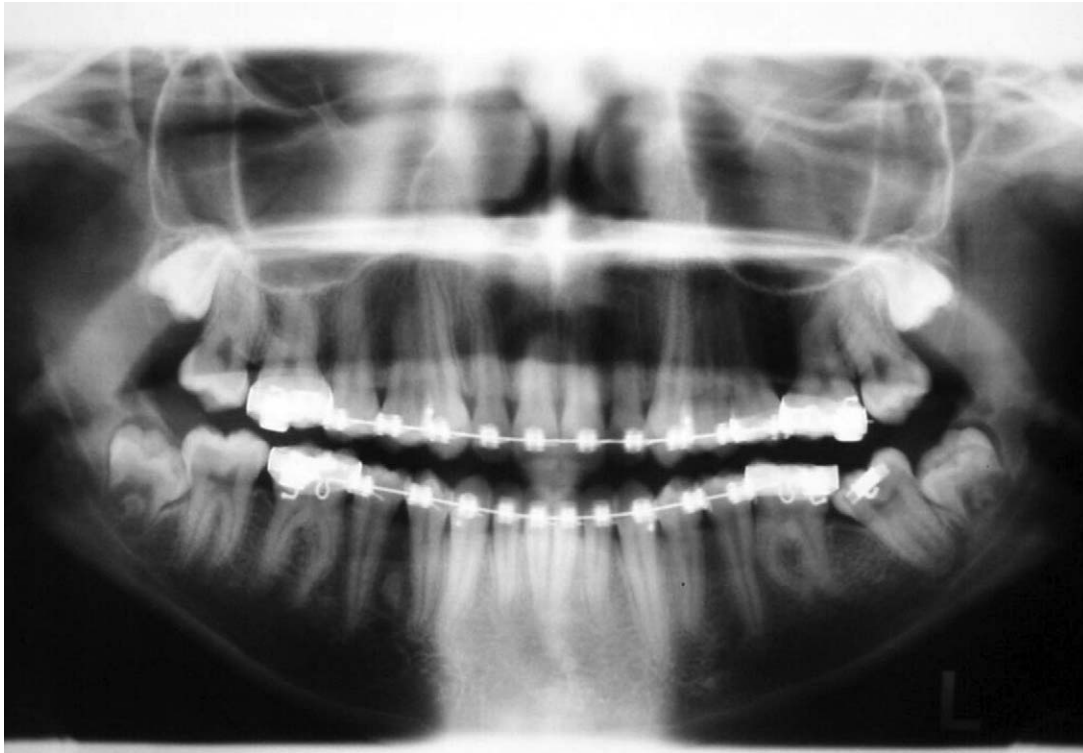

Figure 9. Panoramic radiograph showing impacted second molar crown blocked under the distal edge of incorrectly fitted band.

that none of these teeth became impacted and that all achieved the acceptable position, but suggested that this treatment option requires good case selection.

A less risky alternative is orthodontically assisted eruption with or without surgical uncovering; this depends on the degree of impaction. The choice of appliance should be based on proper evaluation of impacted molars and the developing third molar position. Other factors, such as the degree of impaction and desired type of movement, should also be considered when choosing an appliance.

Prior to orthodontic therapy, the need for third molar extraction should be evaluated.⁸ Frequently, the third molar position may impede the distal movement of the impacted molar, indicating the need for extraction. However, from a biomechanical perspective, sometimes it is better to leave the third molar bud to facilitate the second molar rotation.²⁴

In the case presented, the evaluation of the position of the third molar buds in the mandibular ramus and a subsequent biomechanical analysis allowed us to plan the timing of the germectomy after orthodontic uprighting.

The most often recommended appliance for molar uprighting and extrusion is a simple tip-back spring³¹ The length of the cantilever determines the moment-to-force ratio, and so the achieved movement. A short cantilever delivers more extrusion than a longer one.

Although some extrusion was indeed our aim, the cantilever wasn't planned short because a pure rotation of a tipped molar always increases its height and there is no need for an auxiliary extrusive force. Moreover, a longer cantilever gives a relatively low load/deflection rate leaving the force system with a high degree of constancy. Another important characteristic of the force system delivered by the cantilever is the constancy of the moment-to-force ratio, which results in more homogeneous tooth movement.³² The tip-back cantilever acts on the molar in three planes, so it is important to use the size wire that fills the slot in order to avoid lingual tipping of the molar. In the case presented, TMA wire (0.017 × 0.025-inch) in an 0.018-inch slot was used.

We started uprighting with a partial fixed appliance to allow the hook to move distally as the tooth uprighted. The anchorage secured by the anterior segment was controlled. When the initial change in inclination had taken place, the full fixed appliance was used.

CONCLUSION

- Second molar impaction is a very challenging disturbance that requires proper clinical, radiological, and biomechanical evaluation and a good appliance selection for successful treatment results.

REFERENCES

1. Aitasalo K, Lehtinen R, Oksala E. An orthopantomographic study of prevalence of impacted teeth. *Int J Oral Surg*. 1972; 1:117–120.
2. Grover PS, Norton L. The incidence of unerupted permanent teeth and related clinical cases. *Oral Surg Oral Med Oral Path*. 1985;59:420–425.
3. Mead S. Incidence of impacted teeth. *Int J Orthod*. 1930; 16:885–890.
4. Majourau A, Norton LA. Uprighting impacted second molars with segmented springs. *Am J Orthod Dentofacial Orthop*. 1995;107:235–238.
5. Varpio M. Disturbed eruption of the lower second molar: clinical appearance, prevalence and etiology. *J Dent Child*. 1988;55:114–118.
6. Shapira Y, Borell G, Nahlieli O, Kuftinec MM. Uprighting mesially impacted mandibular permanent second molars. *Angle Orthod*. 1998;68:173–178.
7. Eckhart JE. Orthodontic uprighting of horizontally impacted mandibular second molars. *J Clin Orthod*. 1998;32:621–624.
8. Kokich VG, Mathews DP. Surgical and orthodontic management of impacted teeth. *Dent Clin North Am*. 1993;37: 198–201.
9. Shellhart WC, Oesterle LJ. Uprighting molars without extrusion. *J Am Dent Assoc*. 1999;130:381–385.
10. Moro N, Murakami T, Tanaka T, Ohto C. Uprighting of impacted third molars using brass ligature wire. *Aust Orthod J*. 2002;18:35–38.
11. McAboy CP, Grumet JT, Siegel EB, Iacopino AM. Surgical uprighting and repositioning of severely impacted mandibular second molars. *J Am Dent Assoc*. 2003;134:1459–1462.
12. Ferrazzini G. Uprighting of a deeply impacted mandibular second molar. *Am J Orthod Dentofac Orthop*. 1989;96:168–171.
13. Peskin S, Graber TM. Surgical repositioning of teeth. *J Am Dent Assoc*. 1970;80:1320–1326.
14. Johnson JV, Quirk GD. Surgical repositioning of impacted second molar teeth. *Am J Orthod Dentofac Orthop*. 1987; 91:242–251.
15. Pogrel MA. The surgical uprighting of mandibular second molars. *Am J Orthod Dentofacial Orthop*. 1995;108:180–183.
16. Shipper G, Thomadakis G. Bone regeneration after surgical repositioning of impacted mandibular second molars: a case report. *Dent Traumatol*. 2003;19:109–114.
17. Fieldhouse J, Shields C. Surgical uprighting of an impacted mandibular second molar. *Dent Update*. 1997;24:320–322.
18. Apfel H. Transplantation of the unerupted third molar tooth. *J Oral Surg*. 1956;9:96.
19. Aksoy A, Aras S. Use of nickel titanium coil spring for partially impacted second molars. *J Clin Orthod*. 1998;32:479–482.
20. Rubin RM. Uprighting impacted molars. *J Clin Orthod*. 1977; 11:44–46.
21. Park DK. Australian uprighting spring for partially impacted second molars. *J Clin Orthod*. 1999;33:404–405.
22. Sander FG, Wichelhaus A, Schiemann C. Intrusion mechanics according to Burstone with the NiTi-SE-steel uprighting spring. *J Orofac Orthop*. 1996;57:210–223.
23. Roberts WW, Chacker FM, Burstone CJ. A segmental approach to mandibular molar uprighting. *Am J Orthod*. 1982; 81:177–184.
24. Melsen B, Fiorelli G, Bergamini A. Uprighting of lower molars. *J Clin Orthod*. 1996;30:640–645.
25. Orton HS, Jones SP. Correction of mesially impacted second and third molars. *J Clin Orthod*. 1987;21:176–181.
26. Kogod M, Kogod HS. Molar uprighting with the piggyback buccal sectional arch wire technique. *Am J Orthod Dentofacial Orthop*. 1991;99:276–280.
27. Going RE Jr, Reyes-Lois DB. Surgical exposure and bracketing technique for uprighting impacted mandibular second molars. *J Oral Maxillofac Surg*. 1999;57:209–212.
28. Warise TR, Galella SA. Controlled, rapid uprighting of molars: a surprisingly simple solution the pivot arm appliance. *J Gen Orthod*. 2000;11:9–19.
29. Lang R. Uprighting partially impacted molars. *J Clin Orthod*. 1985;19:646–650.
30. Giancotti A, Muzzi F, Santini F, Arcuri C. Miniscrew treatment of ectopic mandibular molar. *J Clin Orthod*. 2003;37: 380–383.
31. Romeo DA, Burstone CJ. Tip-back mechanics. *Am J Orthod*. 1977;72:414–421.
32. Fiorelli G, Melsen B. *Biomechanics in Orthodontics* 1.0 [CD-ROM]. Arezzo, Italy: Libra Ortodonzia, 1995.
33. Orton-Gibbs S, Crow V, Orton HS. Eruption of third permanent molars after the extraction of second permanent molars. Part 1: Assessment of third molar position and size. *Am J Orthod Dentofac Orthop*. 2001;119:226–238.