

Histological Evaluation of the Effects of Initially Light and Gradually Increasing Force on Orthodontic Tooth Movement

Ryo Tomizuka^a; Yoshinaka Shimizu^b; Hiroyasu Kanetaka^c; Akihiro Suzuki^d; Sachiko Urayama^e; Masayoshi Kikuchi^f; Hideo Mitani^g; Kaoru Igarashi^h

ABSTRACT

Objective: To investigate histologically the effect of initially light and gradually increasing force on tooth movement in the rat.

Materials and Methods: Cuboids made of neodymium-iron-boron magnets (experimental groups) or titanium (control group) were bonded to the lingual surface of the right and left maxillary first molars of 18-week-old male Wistar rats. The initial distances between materials were 1.0 mm generating 4.96 gf (experimental group 1) and 1.5 mm generating 2.26 gf (experimental group 2). In three groups, rats were killed 1, 3, 7, 10, or 14 days after treatment. Histological sections were prepared and stained with hematoxylin and eosin or for tartrate-resistant acid phosphatase (TRAP) activity. The number of TRAP-positive osteoclasts was counted, and the relative hyalinized area was measured on the pressure side of periodontal ligament.

Results: There were significant differences in the number of osteoclasts among the three groups ($P < .05$). On days 1 and 3, the numbers of osteoclasts in experimental group 2 were greater than in experimental group 1. There were significant differences in the relative hyalinized area between the control group and experimental group 1 ($P < .01$) and between experimental groups 1 and 2 ($P < .01$). On days 1 and 3, the hyalinized area in experimental group 1 was larger than in experimental group 2.

Conclusion: Initially light and gradually increasing force induced tooth movement without the lag phase and showed smooth recruitment of osteoclasts and inhibition of hyalinization.

KEY WORDS: Initially light force; Gradually increasing force; Tooth movement; Osteoclasts; Hyalinization; Rat

INTRODUCTION

Light continuous force results in a relatively smooth progression of tooth movement by frontal resorption.¹

However, traditional orthodontic appliances are not suitable for generating light force because of their material properties, and the force decreases as the tooth moves. We have reported the effect of initially light and gradually increasing force generated by magnets on tooth movement in a previous study.² Magnets generate initially light force that depends on the distance between magnets, and the force gradually increases as the magnets move closer to each other. Although application of initially heavy force followed by gradual

^a Assistant Professor, Division of Orthodontics and Dentofacial Orthopedics, Tohoku University Graduate School of Dentistry, Sendai, Japan.

^b Assistant Professor, Division of Oral and Craniofacial Anatomy, Tohoku University Graduate School of Dentistry, Sendai, Japan.

^c Assistant Professor, Division of Orthodontics and Dentofacial Orthopedics, Tohoku University Graduate School of Dentistry, Sendai, Japan.

^d Research Fellow, Division of Orthodontics and Dentofacial Orthopedics, Tohoku University Graduate School of Dentistry, Sendai, Japan.

^e Graduate PhD student, Division of Oral Dysfunction Science, Tohoku University Graduate School of Dentistry, Sendai, Japan.

^f Professor, Division of Oral and Craniofacial Anatomy, Tohoku University Graduate School of Dentistry, Sendai, Japan.

^g Professor Emeritus, Division of Orthodontics and Dentofacial Orthopedics, Tohoku University Graduate School of Dentistry, Sendai, Japan.

tistry, Sendai, Japan.

^h Professor, Division of Oral Dysfunction Science, Tohoku University Graduate School of Dentistry, Sendai, Japan.

Corresponding author: Dr Ryo Tomizuka, Division of Orthodontics and Dentofacial Orthopedics, Tohoku University Graduate School of Dentistry, 4-1 Seiryomachi, Aoba-ku, Sendai 980-8575, Miyagi, Japan (e-mail: ryotommy@mail.tains.tohoku.ac.jp)

Accepted: July 2006. Submitted: February 2006.

© 2007 by The EH Angle Education and Research Foundation, Inc.

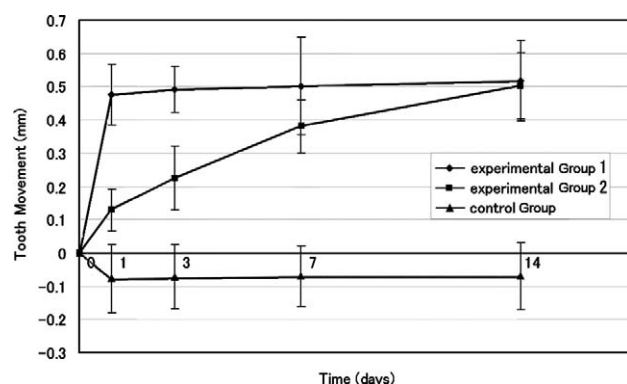


Figure 1. Time course of tooth movement in control group, experimental group 1 (initially heavy force was applied), and experimental group 2 (initially light force was applied).

increasing force (previous study experimental group 1) showed a lag phase in the initial stage, application of an initially light force followed by a gradually increasing force (previous study experimental group 2) induced tooth movement without a lag phase (Figure 1).

Orthodontic tooth movement is dependent on the ability of periodontal cells to react to the mechanical stimuli. For tooth movement, osteoclast recruitment and activation must be induced to remove bone from the area adjacent to the pressure side of the periodontal tissue.^{3,4} A correlation has been reported in young rats between the number of osteoclasts and the rate of tooth movement.⁵

On the other hand, hyalinization in periodontal tissue will limit tooth movement.⁶ Hyalinization not only inhibits the osteoclastic recruitment in the compressed area for frontal resorption, but also strongly induces the undermining resorption.⁷ This degenerative change is caused by excessive force for the periodontal tissue.⁸ Von Böhl et al⁶ showed that areas of hyalinization are associated with all applied force levels and also suggested that the development and removal of necrotic tissue is a continuous process during tooth displacement. Delay of the alveolar bone resorption was induced by the removal of hyalinized tissue and, moreover, is suggested to have a correlation with root resorption.⁹

Although the histology and biomechanics of many kinds of orthodontic forces have been described, the histological response to initially light and gradually increasing forces is not fully clarified. In a clinical investigation, Iwasaki et al¹⁰ concluded that effective tooth movement can be produced with lower forces. It was then hypothesized that smooth tooth movement by initially light and gradually increasing forces could be a result of less hyalinization and increased recruitment of osteoclasts in the compressed area without undermining resorption. The current study histologically

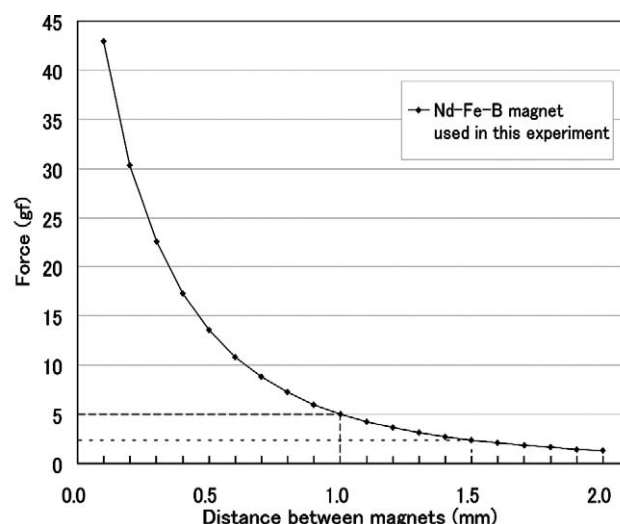


Figure 2. Force-distance curve of the cuboid neodymium-iron-boron magnets ($1.5 \text{ mm}^2 \times 0.7 \text{ mm}$) used in this experiment.

evaluated effects of the initially light and gradually increasing force on orthodontic tooth movement in rats.

MATERIALS AND METHODS

Design of Magnets

Cuboid neodymium-iron-boron magnets ($1.5 \text{ mm}^2 \times 0.7 \text{ mm}$, Seiko-Sangyo, Chiba, Japan) were prepared and coated with 24-carat gold to prevent corrosion. On the basis of the computer simulation results (Maxwell 3D, Ansoft, Pittsburgh, Pa), the cuboid magnets used in this experiment generated 4.96 gf and 2.26 gf at initial distances of 1.0 mm (experimental group 1) and 1.5 mm (experimental group 2) (Figure 2). The initial load in experimental group 2 was approximately half that in experimental group 1. Titanium cuboids ($1.5 \text{ mm}^2 \times 0.7 \text{ mm}$, Seiko-Sangyo) were used as control materials.

Animal Experiment

Forty-three 18-week-old male Wistar rats were used in this study. The rats were housed in cages (three rats per cage) in an air-conditioned and lighted environment according to the guidelines for Animal Research of Tohoku University. Before appliance placement, the rats were acclimatized for 1 week and were fed a diet of ground pellets with water. Body weight was recorded and oral and systemic conditions were monitored during the acclimatization and experimental periods.

Under general anesthesia induced by intra-abdominal injection of pentobarbital sodium salt (Tokyo Kasei

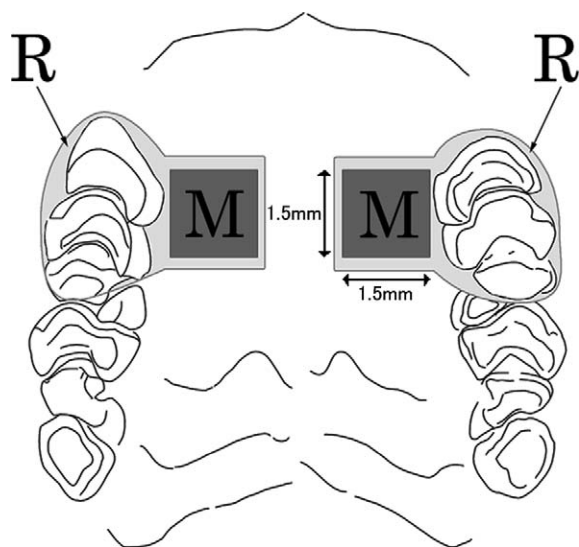


Figure 3. Schematic view of applied magnets in rat maxilla. Magnets were oriented to exert attractive force. M indicates magnet coated with gold; R, light-cured resin to bond magnet or titanium cuboid to the lingual surfaces of first molars and to coat the mesial and buccal surfaces of first molars.

Co Ltd, Tokyo, Japan), magnets or titanium cuboids were bonded to the lingual surface of the first molars with a light-cured resin adhesive (Transbond, 3M Unitek, Monrovia, Calif) in experimental or control rats, respectively (Figure 3). The initial distance between cuboids was 1.0 mm (experimental group 1, control group 1) or 1.5 mm (experimental group 2, control group 2). The two control groups were combined as one control group because there was no difference in tooth movement and histological responses between the two groups. Two maxillary first molars from each rat were involved; therefore, the total numbers of teeth per group was 40 for the control group, 22 for experimental group 1, and 24 for experimental group 2.

Histological Procedure

After 1, 3, 7, 10, or 14 days of treatment, the rats were killed with an overdose of pentobarbital sodium salt and perfused with 4% paraformaldehyde through the ascending aorta for 15 minutes. The upper jaws containing the first molars were excised as samples. The samples were decalcified in 10% EDTA solution for 45 days at room temperature. They were then dehydrated in a graded series of ethanol and embedded in paraffin. Periodontal tissues of the distopalatal root of the upper first molar were examined with a light microscope in serial 5- μ m cross sections 1.0 mm beneath the root furcation. Sections were stained with hematoxylin and eosin.

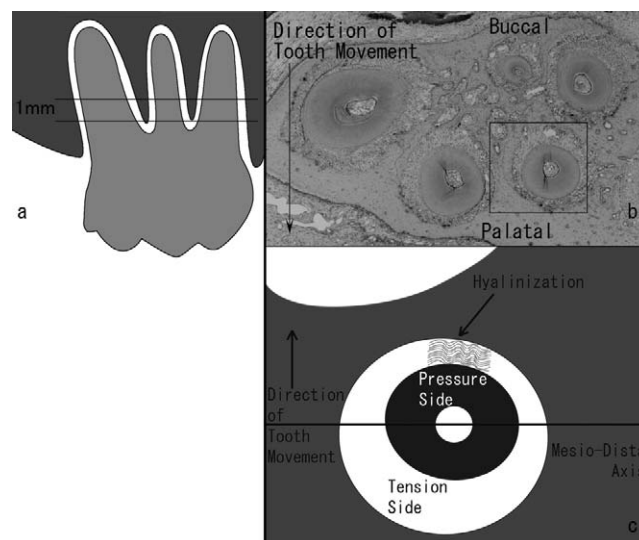


Figure 4. Evaluation of number of osteoclasts and hyalinized area. (a) Schematic view of sagittal slice of maxillary first molar. (b) Photomicrograph of horizontal section of roots in maxillary first molar. (c) Schematic view of the distopalatal root area was divided into a pressure side and a tension side according to the mesiodistal axis of the root. The osteoclasts on the alveolar bone surface were counted on the pressure side. The hyalinized areas of periodontal tissue were measured on the pressure side.

Tartrate-resistant Acid Phosphatase Staining

Tartrate-resistant acid phosphatase (TRAP) staining was performed to count the number of osteoclasts. After washing in 0.1 M acetate buffer (pH 5.0), histological sections were incubated with a mixture of naphtol AS-MX phosphate as substrate and red violet LB salt (Sigma, St Louis, Mo) diluted in 0.1 M acetate buffer (pH 5.0) containing 50 mM (+)-tartaric acid at 37°C for about 30 minutes. Sections were faintly counterstained with hematoxylin (WAKO, Osaka, Japan), mounted, and photographed.

Count of Osteoclasts

Osteoclasts were defined as TRAP-positive multinucleated cells on the bone surface or in bone resorptive lacunae facing the periodontal tissue. The distopalatal root area of the upper first molars was divided into a pressure side and a tension side according to the mesiodistal axis of the root (Figure 4). The osteoclasts were counted on the pressure side according to the method of Miyoshi et al.¹¹ Values for five sections, which were selected at four-section intervals, were then averaged for each rat according to the method of Igarashi et al.¹² The error of the measurement was determined to be 0.12 per area.

Evaluation of Hyalinized Areas in Periodontal Tissue

The hyalinization was defined as a homogeneous cell-free degenerative change of periodontal tissue.

The hyalinized areas of periodontal tissue were measured on the pressure side of the root, and the relative hyalinized area was calculated. These measurements were made by analyzing a microscopic image that was fed directly to a high-resolution monitor with a charge-coupled device camera. Scion Image Beta 4.0.02 image processing software (Scion Corporation, Frederick, Md) was used for the image analyses. Values for five sections, which were selected at four-section intervals, were then averaged for each rat. The error of the measurements was determined to be 0.74% for the relative hyalinized area. This was calculated by using the same formula as in the measurement of tooth movement.²

Statistical Analysis

Data were subjected to two-way analysis of variance (ANOVA) followed by Tukey multiple comparison test.

RESULTS

General Histological Findings

Rat weight in each group showed a gradual increase within normal limits. There were no significant differences between the weights of the groups by two-way ANOVA followed by Tukey multiple comparison test. Systemic and oral examination revealed no abnormal findings except for a slight local inflammation caused by the physical presence of the magnets.

In the control group, slight hyalinized tissue and a few osteoclasts were seen in the periodontal space after treatment. Osteoclasts were observed on the surface of alveolar bone facing the periodontal tissue and around the hyalinized tissue. No inflammatory cell infiltration was observed. In experimental group 2, slight hyalinization was observed with many osteoclasts on the surface of alveolar bone after treatment. In experimental group 1, extensive hyalinized area and many osteoclasts were seen on the pressure side on days 3 and 7 (Figure 5).

Number of Osteoclasts

Figure 6 shows the time course of changes in the number of osteoclasts on the pressure side in the control group and the two experimental groups. There were significant differences in the numbers of osteoclasts among the three groups ($P < .05$). The number of osteoclasts in the two experimental groups increased on days 3 and 7. In the two experimental groups, the number of osteoclasts reached a maximum on day 7 and decreased thereafter. In the control group, the number of osteoclasts showed no change during the experimental period. On days 1 and 3, the numbers of osteoclasts in experimental group 2 were greater than those in experimental group 1.

Hyalinized Area

Figure 7 shows the time course of changes in the relative hyalinized area on the pressure side in the control group and the two experimental groups. There were significant differences in the relative hyalinized area between the control group and experimental group 1 ($P < .01$) and between the experimental groups 1 and 2 ($P < .01$). The hyalinized area in experimental group 1 increased and reached a maximum on day 7 and decreased thereafter. In the control group and experimental group 2, the hyalinized area did not change during the experimental period. On days 3 and 7, the relative hyalinized area in experimental group 1 was larger than in experimental group 2.

DISCUSSION

Although it has been suggested that desirable orthodontic tooth movement requires the application of light continuous force, there exists certain limitation for traditional orthodontic appliances to generate such a force. We recently reported the possibility of applying initially light and gradually increasing force generated by a magnet to orthodontic treatments. In this report, the time course of tooth movement showed a smooth displacement without an apparent lag phase when such force was applied (Figure 1). This indicates that the application of initially light force will be more desirable than that of heavy initial force.²

Thilander et al⁷ have advocated the use of light orthodontic forces to increase the cellular activity in the surrounding tissues and reduce the risk of root resorption. Initially light and gradually increasing force may induce effective tooth movement with less damage to periodontal tissues in the initial stage. This effect could be confirmed in the number and activity of osteoclasts or the extent of hyalinized tissue by experimental orthodontic tooth movement.⁵ Present histological evaluations will explain smooth tooth displacement by such force without a lag phase in the initial stage.

It is well established that bone resorption by osteoclasts is crucial to orthodontic tooth movement.^{13,14} The osteoclasts related to tooth movement were suggested to originate from both periodontal tissue and bone marrow.^{15,16} In relation to its origin, alveolar bone resorption expresses the two features of frontal resorption and undermining resorption. Heavy force leads to undermining resorption of alveolar bone near the affected tooth, and light force is expected to induce the frontal resorption.¹ In orthodontic practice, the objective is to produce tooth movement as much as possible by frontal resorption. Tooth movement usually proceeds in a stepwise process because of hyalinized tissue and undermining resorption.¹ Recruitment of os-

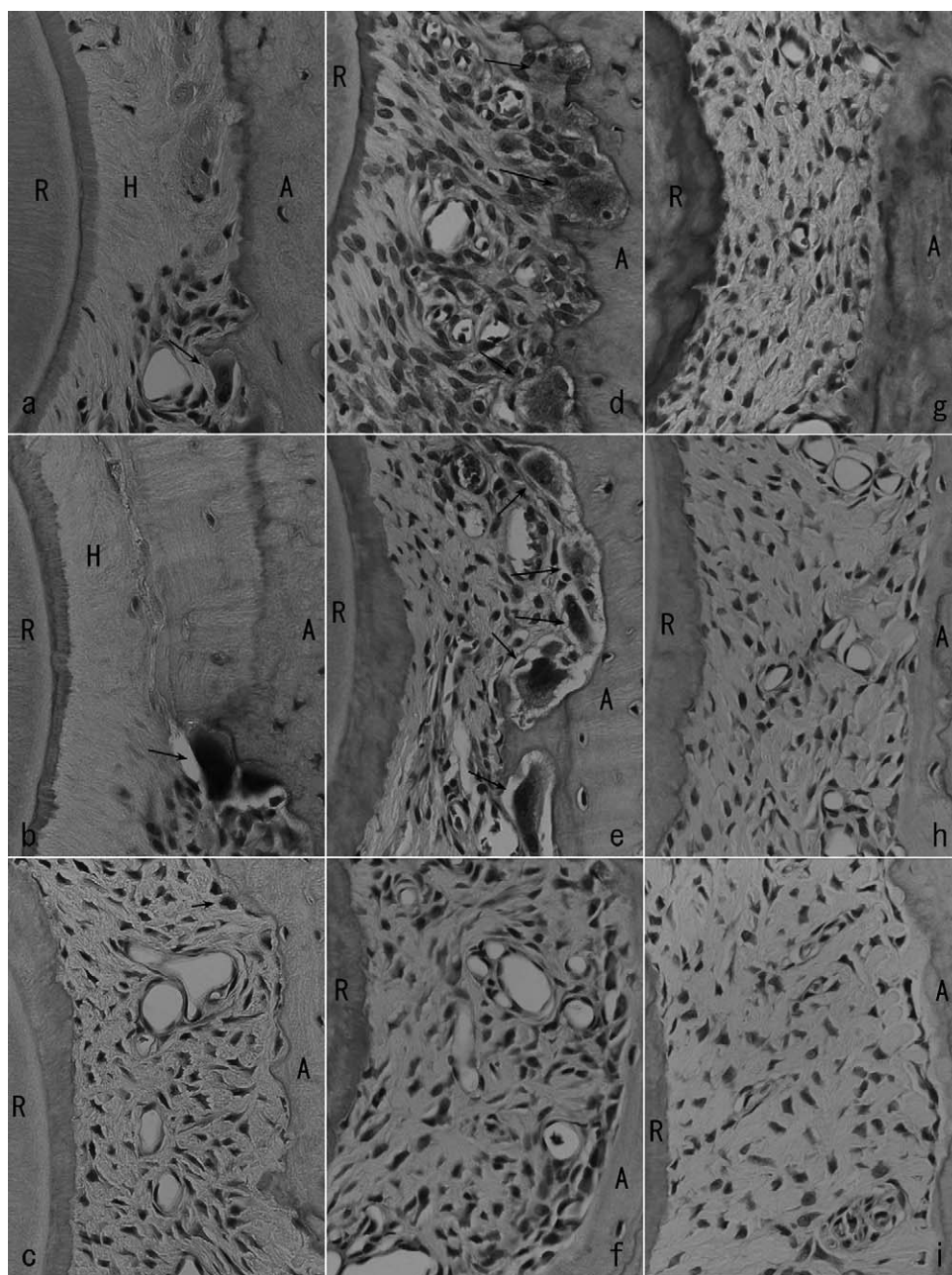


Figure 5. Photographs of the pressure side of the distopalatal root of the upper first molars in rats in the experimental groups. (a, b, c) Days 3, 7, and 14 in the experimental group 1. (d, e, f) Days 3, 7, and 14 in the experimental group 2. (g, h, i) Days 3, 7 and 14 in the control group. (a, b) Hyalinized area of the periodontal tissue and osteoclasts appeared on the periphery of hyalinized periodontal tissue. (d, e) Osteoclasts were observed on the bone surface. R indicates root; A, alveolar bone; and H, hyalinized area of the periodontal tissue. Osteoclasts are indicated by arrows.

teoclasts in the periodontal ligament in the initial stage by such a force system will be in relation with tooth movement without a stepwise process.

We hypothesized that this stepwise process may be solved by an application of initially light and gradually increasing force generated by magnets. In the present study, the number of osteoclasts on the pressure side under the lighter initial force was greater than those under the heavier initial force. Excessive compression

and hyalinization will be disadvantageous for the recruitment of osteoclasts in the periodontal tissue space, leading to a delay of alveolar bone resorption. This study suggested the possibility that controlling the force in the initial stage can result in tooth movement without the stepwise process and without hyalinization. Application to humans is a future issue.

The degeneration of periodontal tissues, such as seen in hyalinization, should be minimized in ortho-

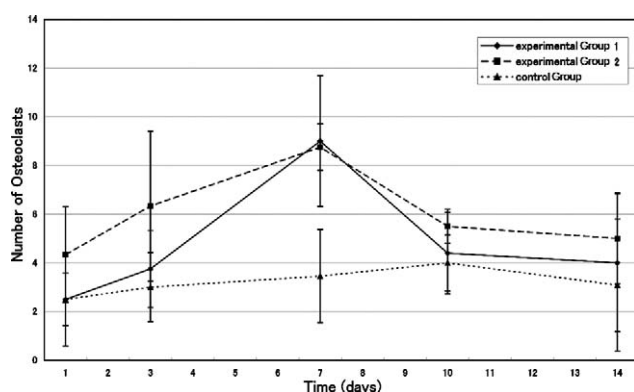


Figure 6. Time course of changes in the number of osteoclasts on the pressure side of the distopalatal roots of the upper first molars in rats in the two experimental groups. Error bar means standard deviation.

dontic tooth movement.^{7,17} Hyalinization is caused by excessive compression of the periodontal tissue.⁸ Many investigations have described the formation of a hyalinized area in the lag phase as a result of localized ischemia by excessive compression.^{8,14} Bone remodeling on the compressive side starts with the removal of hyalinized tissue, and, after the removal of hyalinized tissue, the rate of tooth movement increases.¹⁸ In clinical orthodontics, it is difficult to avoid pressure that produces at least some avascular areas in the periodontal tissue. In this study, the initially light and gradually increasing force caused less extensive hyalinization of the periodontal tissue. The formation of resorbed lacunae on the bone surface in the initial stage may have an advantage for the recruitment of osteoclasts and continuous bone resorption, despite a following increase in force. It is suggested that gradually increasing force may not necessarily be disadvantageous if an initial magnitude of the force is light enough but may rather promote tooth movement.

Clinically, not only is tooth movement more efficient when hyalinization of the periodontal tissue is avoided, but pain may be also lessened.¹ However, the experience of pain varies substantially among subjects.¹⁹ The relations between force magnitude and force application pattern and pain would be able to be investigated by probing into a pain-producing substance in this study model. Thus, the application of initially light and gradually increasing force might have two clinical advantages (ie, painless and shortened treatment).

CONCLUSION

- Initially light and gradually increasing force generated by magnets induces more osteoclast recruitments with less hyalinization and thereby effective tooth movement.

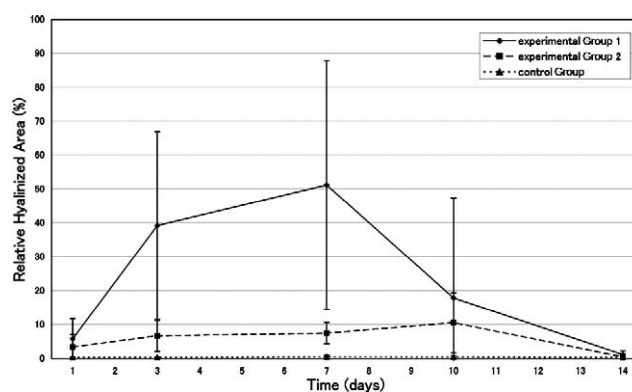


Figure 7. Time course of changes in the relative hyalinized area of the periodontal tissue on the pressure side of the distopalatal root of the upper first molar in rats in the two experimental groups. Error bar means standard deviation.

ACKNOWLEDGMENT

We wish to thank Mr Onodera Toshihiro (Tohoku University Graduate School of Dentistry) for technical assistance.

REFERENCES

- William RP, Henry WF. The biological basis of orthodontic therapy. In: William RP, Henry WF, eds. *Contemporary Orthodontics*. 3rd ed. St Louis, Mo: Mosby Inc; 2000:296–325.
- Tomizuka R, Kanetaka H, Shimizu Y, Suzuki A, Igarashi K, Mitani H. Effects of gradually increasing force generated by permanent rare earth magnet for orthodontic tooth movement. *Angle Orthod*. 2006;76(6):1004–1009.
- Melsen B. Biological reaction of alveolar bone to orthodontic tooth movement. *Angle Orthod*. 1999;69:151–158.
- King GJ, Keeling SD, Wronski TJ. Histomorphometric study of alveolar bone turnover in orthodontic tooth movement. *Bone*. 1991;12:401–409.
- Ren Y, Kuijpers-Jagtman AM, Maltha JC. Immunohistochemical evaluation of osteoclast recruitment during experimental tooth movement in young and adult rats. *Arch Oral Biol*. 2005;50:1032–1039.
- Von Böhl M, Maltha J, Von den Hoff H, Kuijpers-Jagtman AM. Changes in the periodontal ligament after experimental tooth movement using high and low continuous forces in beagle dogs. *Angle Orthod*. 2004;74:16–25.
- Thilander B, Rygh P, Reitan K. Tissue reactions in orthodontics. In: Graber TM, Vanarsdall RL Jr, Vig KWL, eds. *Orthodontics. Current Principles & Techniques*. 4th ed. St Louis, Mo: Elsevier Inc; 2005:145–219.
- Rygh P. Ultrastructural changes in pressure zones of human periodontium incident to orthodontic tooth movement. *Acta Odontol Scand*. 1973;31:109–122.
- Brudvik P, Rygh P. Root resorption beneath the main hyalinized zone. *Eur J Orthod*. 1994;16:249–263.
- Iwasaki LR, Haack JE, Nickel JC, Morton J. Human tooth movement in response to continuous stress of low magnitude. *Am J Orthod Dentofacial Orthop*. 2000;117:175–183.
- Miyoshi K, Igarashi K, Saeki S, Shinoda H, Mitani H. Tooth movement and changes in periodontal tissue in response to orthodontic force in rats vary depending on the time of day the force is applied. *Eur J Orthod*. 2001;23:329–338.
- Igarashi K, Mitani H, Adachi H, Shinoda H. Anchorage and retentive effects of a bisphosphonate (AHBUP) on tooth

- movements in rats. *Am J Orthod Dentofacial Orthop.* 1994; 106:279–289.
13. Reitan K. Tissue behavior during orthodontic tooth movement. *Am J Orthod.* 1960;46:881–900.
 14. Reitan K. Clinical and histologic observations on tooth movement during and after orthodontic treatment. *Am J Orthod.* 1967;53:721–745.
 15. Roberts WE, Ferguson DJ. Cell kinetics of the periodontal ligament. In: Norton LA, Burstone CJ, eds. *The Biology of Tooth Movement*. Boca Raton, Fla: CRC Press Inc; 1989: 55–70.
 16. Tsay TP, Chen MH, Oyen OJ. Osteoclast activation and recruitment after application of orthodontic force. *Am J Orthod Dentofacial Orthop.* 1999;115:323–330.
 17. Reitan K. Biomechanical principles and reactions. In: Graber TM, ed. *Current Orthodontics Concepts and Techniques*. Philadelphia, Pa: WB Saunders Co; 1969:56–159.
 18. Kavarizadeh A, Bourauel C, Zhang D, Gotz W, Jager A. Correlation of stress and strain profiles and the distribution of osteoclastic cells induced by orthodontic loading in rat. *Eur J Oral Sci.* 2004;112:140–147.
 19. Bergius M, Berggren U, Kiliaridis S. Experience of pain during an orthodontic procedure. *Eur J Oral Sci.* 2002;110:92–98.