

Orthodontic Treatment Acceleration with Corticotomy-assisted Exposure of Palatally Impacted Canines

A Preliminary Study

T. J. Fischer

ABSTRACT

Objective: To evaluate the effectiveness of a new surgical technique in the treatment of palatally impacted canines.

Materials and Methods: Six consecutive patients presenting with bilaterally impacted canines were compared. One canine was surgically exposed using a conventional surgical technique while the contralateral canine was exposed using a corticotomy-assisted technique.

Results: After tooth movement was completed, statistical comparisons of the two methods revealed a reduction of treatment time of 28–33% for the corticotomy-assisted canines. No significant differences were observed in final periodontal condition between the canines exposed by these two methods.

Conclusion: This preliminary study supports the concept that a corticotomy-assisted surgical technique helps reduce orthodontic treatment time for palatally impacted canines.

KEY WORDS: Impacted canines; Corticotomy

INTRODUCTION

One of the most difficult clinical problems for the orthodontist to correct is the palatally impacted canine. This condition requires the close teamwork of the oral surgeon and the orthodontist—initially to achieve access to the impacted tooth and then to use precise biomechanics to place the tooth in its proper position. Consequently, treatment times to completion can be extended. The purpose of this paper is to evaluate the effectiveness of a new surgical procedure in reducing treatment time for the correction of this complex orthodontic problem.

The maxillary canine is second only to the mandibular third molars in frequency of impaction. Reported impaction rates have varied from 0.9%¹ to 2.8%.² This condition occurs twice as frequently in women as men.¹ Maxillary palatal canine impaction is found in 85% of all impaction cases, whereas labial impaction

occurs 15% of the time.³ Finally, of all the maxillary palatal impactions 8–10% are bilateral.¹

The etiology of palatally impacted canines is not completely clear. The maxillary canine has the longest path of eruption from its point of origin, which may be a contributing factor.⁴ Some studies have shown a higher incidence of palatally impacted canines in cases with microdontic or missing laterals.⁵ Furthermore, a familial trend has been advanced that concludes that the impacted maxillary canine is a dental anomaly being a product of polygenic multifactorial inheritance.⁶

As palatally impacted canines seldom erupt without surgical intervention,⁷ the conventional treatment for these teeth usually includes surgical exposure followed by orthodontic traction. With severe palatal impactions, surgical intervention usually requires palatal reflection followed by removal of the bone overlying the canine crown. Only enough bone is removed to place an orthodontic attachment on the tooth. The surgical caveat is that the cemento-enamel junction of the impacted tooth not be exposed. Exposure of the cemento-enamel junction has shown to cause excessive loss of alveolar supporting bone.⁸

Recently, a surgical procedure in conjunction with orthodontic therapy has been popularized, which purports to reduce treatment times significantly. Although this procedure, termed corticotomy-assisted orthodon-

Instructor, Graduate Orthodontics, Harvard University, Boston, Mass.

Corresponding author: Dr Tom Fischer, 60 Timberlane, South Burlington, VT 05403 (e-mail: tfdmd@mac.com)

Accepted: July 2006. Submitted: June 2006.

© 2007 by The EH Angle Education and Research Foundation, Inc.

Presented at the March 2006 meeting of the Angle East organization in Washington, D.C.

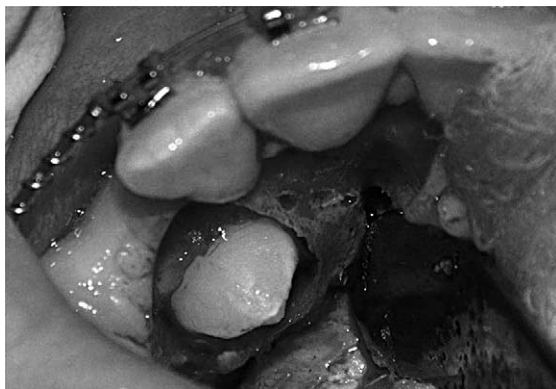

Figure 1. Conventional uncovering.

tics, was first described in 1893,⁹ it has only recently gained wide usage. This surgical technique includes gingival reflection followed by partial decortication of the cortical plates ending with primary flap closure. Significantly reduced treatment times have been reported using this procedure with reductions of 75% to 80% of routine treatment times.¹⁰

MATERIALS AND METHODS

For this preliminary study, a sample of six patients with bilateral palatally impacted maxillary canines was chosen from patients presenting for orthodontic treatment at the author's practice. The sample was set up to use each patient as his own control, thereby increasing the power of a small sample. The sample included four white girls and two white boys, with an age range of 11.1 to 12.9 years.

On all six patients, comprehensive orthodontic records were taken. Nonextraction treatment with preparation for surgical uncovering of both canines was begun in a standard manner. Simultaneous surgical exposure of both canines was accomplished for each patient by the same surgeon. By random selection, one canine had a conventional surgical uncovering procedure (Figure 1). On the other canine an additional corticotomy procedure was performed (Figure 2). This procedure included a series of circular holes made along the bone mesial and distal adjacent to the impacted tooth where possible. These holes were made with a 1½ mm round bur spaced approximately 2 mm apart and extended into the edentulous area into which the tooth was to be moved.

Each patient returned two weeks post surgery to have an orthodontic attachment placed on the impacted teeth. The orthodontist had no knowledge as to which canine had the corticotomy procedure. Upper study models were taken at this time to measure the distance from the incisal tip of each canine to its final position in the arch (Figure 3).

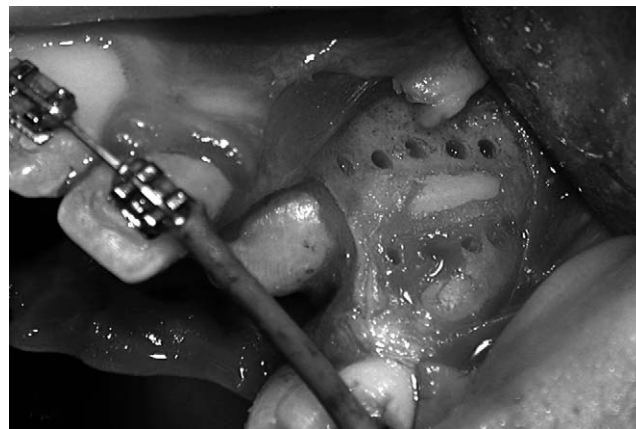

Figure 2. Corticotomy-assisted uncovering.

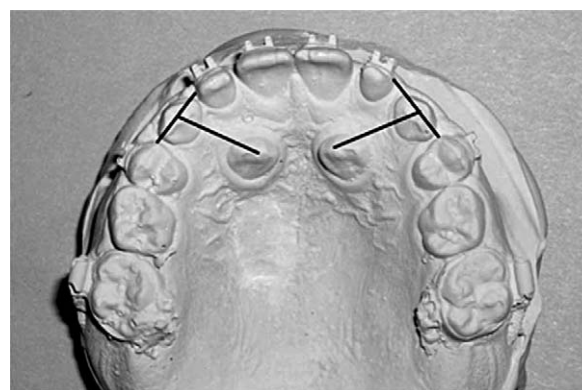


Figure 3. Measured distance.

Orthodontic traction was applied to both canines in a similar manner utilizing 60 g of force in accordance with current clinical recommendations.¹¹ Patients were seen at four- to six-week intervals. When a canine was close to its proper position, the intervals were shortened to two weeks. All patients were treated until the tips of both canine crowns were brought into proper position in the dental arch. At that point, treatment duration for each canine was compared to its contralateral tooth. Periodontal probing of both canines was compared once both teeth were in their final resting position. Additionally, periapical radiographs of contralateral canines were taken one year after treatment to compare the bone levels of the conventional and corticotomy canines to each other. All patients were treated successfully to completion (Figures 4–7).

RESULTS

In all six patients, the treatment time was reduced in the corticotomy-assisted canine impactions. As compared to the noncorticotomy canines, the reduction in treatment time ranged from 28% to 33%. Furthermore, the velocity, ie, distance/time, of each ca-

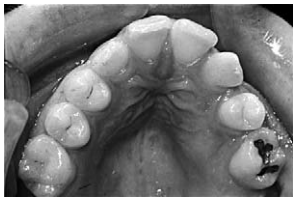

Figure 4. Patient #3. Initial preparation.

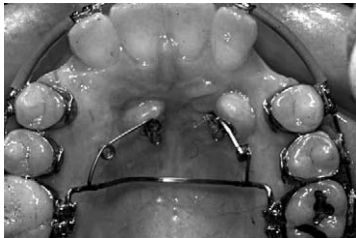

Figure 5. Patient #3. Initial traction.

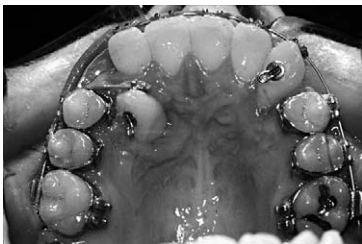

Figure 6. Patient #3. Thirty-four weeks later with corticotomy canine moving faster than conventional canine.

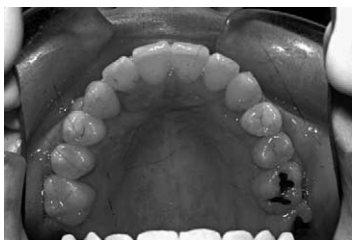

Figure 7. Patient #3. At appliance removal.

nine was calculated and all corticotomy-assisted canines had a significantly higher tooth movement velocity than the contralateral conventionally exposed palatal canine (Table 1 and Figure 8). A paired *t*-test was performed and revealed a significant difference between the conventional and the corticotomy canines on all patients at the .001% level (Tables 2a through 2c).

Periodontal probing records showed no clinical difference between the corticotomy-assisted canines and their contralateral teeth. Comparison of bone levels on periapical radiographs revealed no clinical difference between the conventional and the corticotomy canines (Figure 9).

Table 1. Distance, Time, and Velocity of Canines in Patients With Corticotomy and Conventional Exposure

Patient #	Corticotomy Exposure			Conventional Exposure		
	Distance, mm	Time, wk	Velocity, mm/wk	Distance, mm	Time, wk	Velocity, mm/wk
1	10.0	40	0.25	11.5	60	0.19
2	12.5	44	0.28	12.5	62	0.20
3	12.0	38	0.32	11.0	58	0.19
4	12.5	48	0.26	12.0	68	0.18
5	14.0	52	0.27	15.0	78	0.19
6	11.5	54	0.21	12.0	74	0.16

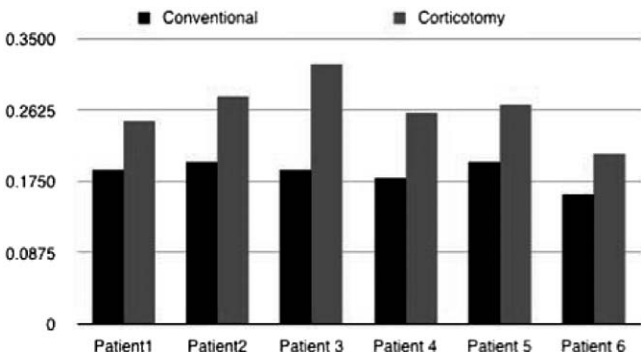


Figure 8. Velocity of canine movement (mm/wk).

Table 2a. Paired *t*-Test: Sample Statistics^a

Exposure	Mean	SD	SEM
Corticotomy	.2650	.03619	.01478
Conventional	.1867	.01506	.00615

^a SEM indicates standard error of the mean. N = 6.

Table 2b. Paired *t*-Test: Sample Correlations^a

Exposure	Correlation	Significance
Conventional and corticotomy	.697	.124

^a N = 6.

Table 2c. Paired *t*-Test: Sample Test^a

Exposure	Mean	SD	SEM	<i>t</i>	df	Significance (2-tailed)
Conventional and corticotomy	.0783	.02787	.01138	6.885	5	<i>P</i> = .001***

^a SEM indicates standard error of the mean; df, degrees of freedom. N = 6.

DISCUSSION

In evaluating the rates of canine movement, extrapolation of the velocities reveals that the corticotomy-assisted canines moved at a rate of 1.06 mm/month vs 0.75 mm/month for the conventional canines. These velocities are clinically significant as well as sta-

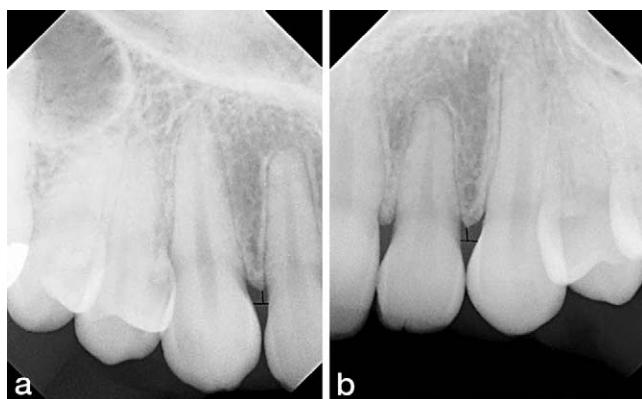


Figure 9a. Corticotomy (periapical). **Figure 9b.** Conventional (periapical).

tistically significant. Given that the corticotomy procedure reduces the bone mass around the canine tooth and reduces the bone in its way, less cellular resorption would be required, perhaps allowing faster tooth movement.

In 1982 McDonald and Yap⁸ showed that more bone removed during conventional uncovering yielded greater bone loss after treatment was completed. Although the corticotomy procedure removes more bone than the conventional procedure, no clinical difference in bone support or periodontal health was seen between the two groups in this study. This may be explained in the manner of bone removal. The corticotomy procedure done was not a true osteotomy, with a block of bone removed. The procedure only perforated the bone, leaving the original bony architecture intact. This allowed the resorption/deposition cellular process to proceed within the existing architecture.

In this study, final canine tooth position was determined to be when the tip of the canine crown was positioned ideally in the dental arch as viewed from the occlusal plane. All 12 of the canines evaluated needed root torque to finalize their position ideally. However, this study did not compare the velocities of torquing movements between the two groups, as it proved impossible to measure initial root positions accurately. Given the positive associations derived using a small sample size in this preliminary study, further

studies with larger sample sizes would be indicated to increase the power of the statistical results.

CONCLUSIONS

- The results demonstrated that under the same conditions the corticotomy-assisted approach produced faster tooth movement in all six patients.
- Additionally, this surgical procedure did not produce any significant difference in the periodontal health of the canine.

ACKNOWLEDGMENTS

Thanks to Dr Judy Christensen, University of Vermont, for assistance with statistical tests. Also, thanks to Drs Sheldon Peck, Samir Bishara, and David DeFranco for their invaluable suggestions.

REFERENCES

1. Dachi SF, Howell FV. A survey of 3,874 routine full mouth radiographs. *Oral Surg Oral Med Oral Pathol.* 1961;14:1165–1169.
2. Thilander B, Myrberg N. The prevalence of malocclusion in Swedish school children. *Scand J Dent Res.* 1973;81:12–20.
3. Ericson S, Kurol J. Radiographic examination of ectopically erupting maxillary canines. *Am J Orthod Dentofacial Orthop.* 1987;91:483–492.
4. Coulter J, Richardson A. Normal eruption of the maxillary canine quantified in three dimensions. *Eur J Orthod.* 1997;18:449–456.
5. Becker A, Zilbermann Y, Shtyer A. Root length of lateral incisors adjacent to palatally displaced maxillary cuspids. *Angle Orthod.* 1984;54:218–225.
6. Peck S, Peck L, Kataja M. The palatally displaced canine as a dental anomaly of genetic origin. *Angle Orthod.* 1994;64:249–256.
7. Jacoby H. The etiology of maxillary canine impactions. *Am J Orthod.* 1983;84:125–132.
8. McDonald F, Yap W. The surgical exposure and application of direct traction of unerupted teeth. *Am J Orthod.* 1982;89:331–340.
9. Fitzpatrick B. Corticotomy. *Aust Dent J.* 1980;25:255–258.
10. Wilcko WM, Wilcko T, Bouquet JE, Ferguson DJ. Rapid orthodontics with alveolar reshaping: two case reports of de-crowding. *Int J Periodontics Restorative Dent.* 2001;21:9–19.
11. Bishara SE. Clinical management of impacted maxillary canines. *Semin Orthod.* 1998;4:87–98.