

Dental Status and Orthodontic Treatment Needs of an 11-Year-Old Female Resident of Athens, 430 BC

Manolis J. Papagrigorakis^{a,b}; Philippos N. Synodinos^c; Effie Baziotopoulou-Valavani^d

ABSTRACT

This report presents the skeletal and dental features of “Myrtis”, an 11-year-old female resident of ancient Athens back in 430 BC. Her skeleton was unearthed in an archaeological excavation of a mass burial pit located in the outskirts of Kerameikos’ ancient cemetery of Athens. “Myrtis” is believed to have been one of the numerous hapless victims of the Plague of Athens.

Her skull was found in relatively intact condition bearing her complete dentition corresponding to the mixed dentition stage. A complete dental and orthodontic diagnosis of Myrtis was conducted based on clinical examination, study of panoramic radiographs, and lateral cephalometric analysis of her skull. No significant dental pathology was reported pertaining to deciduous or permanent teeth of “Myrtis”. A Class II skeletal and dental malocclusion was observed. The ectopic labial eruption of the maxillary canines mesially to their retained deciduous predecessors, the ectopic distally directed eruption of a lower first premolar, and a unilaterally missing lower third molar were among the most interesting dental findings reported.

KEY WORDS: Ancient Greek; Craniofacial morphology; Dental occlusion; Lateral cephalometric radiograph; Panoramic radiograph

INTRODUCTION

Recording and meticulously studying the dental and facial characteristics of ancient peoples is undoubtedly of outstanding importance for many scientific fields, since it provides data that may help towards identifying and understanding the underlying mechanisms of growth, development, and evolution of humankind. Certain fields of medicine, anthropology, and even genetics and molecular biology are clearly implicated in such matters and can benefit from relevant studies.

Specifically with regard to the dental and craniofacial characteristics of ancient Greek populations, only scarce pieces of information have been provided in the literature.¹⁻⁵ Conclusions from these studies are drawn

with reservations, owing to severe restrictions on their methodology. These methodological problems included their averaging characteristics of populations spanning over several centuries,⁵ inadequate sampling methodology,¹ and the absence of any classification/subdivision according to important features of the studied subjects such as their age, gender,⁴ and site of residence. These restrictions resulted from the lack of adequate archaeological skeletal material and the lack of respective awareness of the archeologists in the excavations conducted in the past.

Especially evident in these studies is the lack of information pertaining to young populations. In this paper, the dental status and the craniofacial characteristics of an 11-year-old girl are presented. This child was a resident of Athens, and died in the late years of the 5th century BC. The child’s gender and age were determined by anthropological examination. The child was named “Myrtis” by the archaeologists in charge of the excavations that led to the discovery of her skeleton. “Myrtis” represents an ancient Greek female name.

The skeleton of “Myrtis” was included in a mass burial pit that was unearthed in an excavation conducted on the outskirts of the Kerameikos’ ancient cemetery of Athens and dated, through archaeological site documentation, to around 430 BC, namely the

^a Orthodontist, Assistant Professor, Department of Orthodontics, Dental School, University of Athens, Athens, Greece.

^b Director, Museum of Craniofacial Evolution and Dental History, Dental School, University of Athens, Athens, Greece.

^c Orthodontist, Department of Orthodontics, Dental School, University of Athens, Athens, Greece.

^d Archaeologist, Third Ephorate of Prehistoric and Classical Antiquities, Ministry of Culture, Athens, Greece.

Corresponding author: Dr Manolis J Papagrigorakis, 2 Thivon str, 11527 Goudi/Athens, Greece (e-mail: demon@otenet.gr)

Accepted: February 2007. Submitted: January 2007.

© 2008 by The EH Angle Education and Research Foundation, Inc.

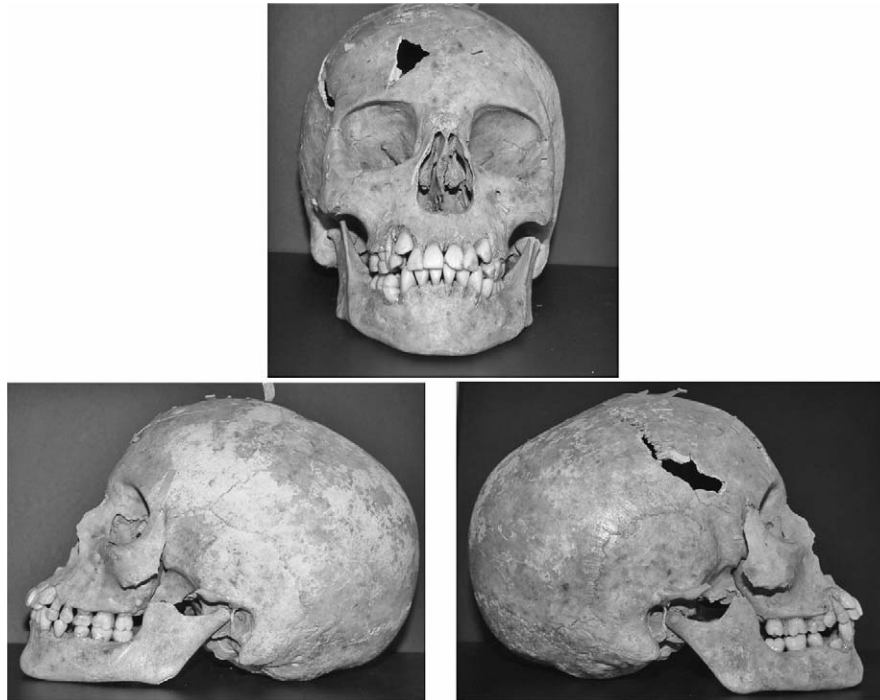


Figure 1. Frontal and right and left lateral view of the skull of “Myrtis.”

time of the outbreak of the Plague of Athens.⁶ This fact, in addition to certain characteristics of the excavation, led to the assumption that the mass grave included victims of the Plague that devastated the city while besieged by the Spartans during the Peloponnesian War.⁶ Thus, the required skeletal material was provided for the investigation and possible identification of ancient microbial DNA that was implicated in the cause of the Plague of Athens,⁷ subsequently resulting in the formation of further working hypotheses on the same topic.⁸⁻⁹ In addition to these projects, the fact that intact skulls of victims were included in the same sample of the mass grave facilitates the investigation of both individualized and summarized views of specific cranial and dental features that characterized the population of ancient Athens of 430 BC—a historical period known as the Golden Age of Pericles.

The subject presented in this paper was selected from the mass grave for more extensive dental and orthodontic investigation of specific features relevant to the craniofacial complex, since the skull was intact and bore all the anatomical reference points and complete dentition. All these factors are necessary for a concise elucidation of aspects relevant to facial and dental growth and development. In this paper only the skeletal and dental features of “Myrtis” will be presented. The skull of “Myrtis” will be subjected to total facial reconstruction, including its soft tissues, in a future study.

CASE REPORT

Dental and Skeletal Characteristics of “Myrtis”

As shown in the respective figures and radiographic images (Figures 1 through 4), at the time of her death “Myrtis” was in the late mixed dentition stage with only a few deciduous teeth remaining in the upper dental arch, namely the maxillary deciduous second molars and the maxillary deciduous canines. No signs of dental pathology were evidenced (pertaining to caries, attrition of occlusal surfaces, alveolar bone loss) with the exception of a carious lesion located in the occlusal surface of the deciduous maxillary left second molar and some recession and fenestration of the buccal surface of the alveolar crest in the area of the mandibular anterior teeth. In addition to the above, a small fracture of the mesial incisal edge of the crown of the maxillary left central incisor, which might have occurred post mortem, was also observed.

The midlines of the upper and lower dental arches coincided. A slight increase in overjet was evident, while the overbite was rather normal. A bilateral Class II molar and canine relationship was present (Figure 2).

The Class II relationship of the canines, had they been fully erupted, would have been the result of the ectopic eruption pathway of both upper permanent canines buccal and mesial to their retained predecessors. The abnormal eruption path of the maxillary ca-

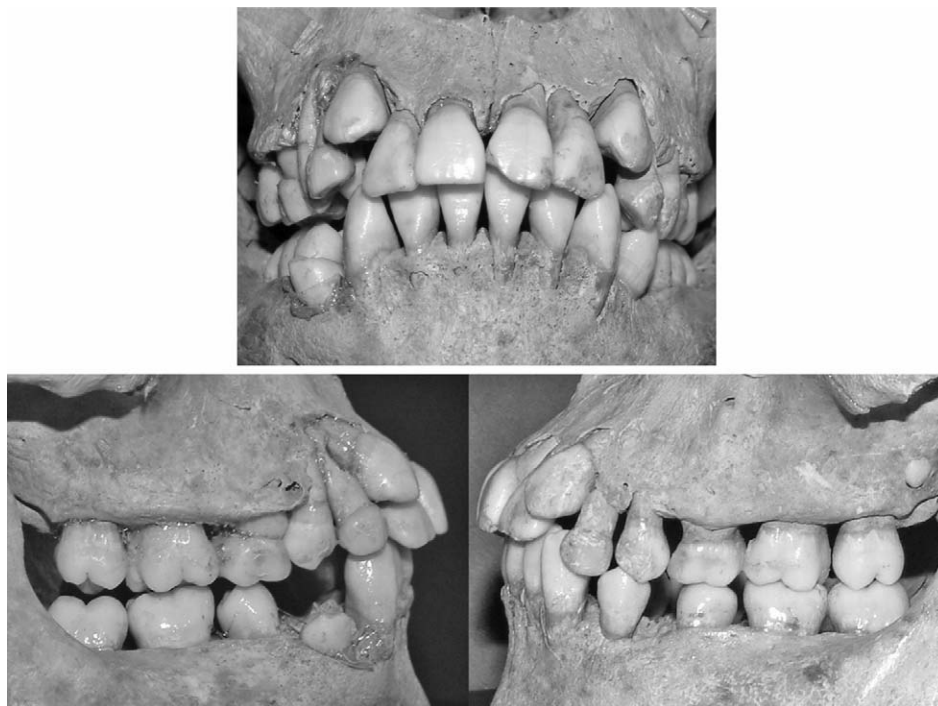


Figure 2. Close up frontal and right and left lateral view of the dentition of "Myrtis" in occlusion.

nines would probably have resulted in an unfavorable effect on "Myrtis" smile, according to modern-day standards. Although diastemata were observed mesially to both permanent lower second premolars, the physiological mesial movement of the lower permanent first molars to a Class I relationship with their counterparts was prevented by the unfavorable distal eruption of the permanent lower second premolars into the leeway space of their deciduous predecessors, while the respective first premolars were also distally inclined. Thus, a Class II orthodontic anomaly was established.

All four permanent second molars had fully erupted, having reached their occlusal line where they met with their counterparts. On the other hand, the lower right first premolar had not yet erupted and its crown was just emerging over the alveolar crest.

A slight buccal rotation of both permanent lower central incisors overlapped the distal of their respective permanent lower lateral incisors; in addition there was slight overlapping between the crowns of the permanent upper central incisors. Both permanent lower second molars were rotated mesially and buccally.

By the study of the panoramic radiograph (Figure 4), it is evident that the roots of the deciduous upper second molars had almost completely resorbed, while the roots of the deciduous upper canines appeared to be rather intact. The emerging permanent lower right first premolar was inclined to the distal and appeared to meet the mesial surface of the respective second

premolar, while some juxtaposition of the radiographic image between the apical root parts of the first premolar and the canine was also evident with no signs of resorption. The developing buds of three third molars were clearly outlined, having almost completed the ossification of their crowns. No sign of a developing lower left third molar was evident.

Macroscopically, a symmetrical development of the craniofacial complex was present (Figure 1). The panoramic image of the mandible was also symmetrically outlined (Figure 4).

The lateral cephalometric radiograph revealed a skeletal Class II relationship attributed to the protruding maxilla (Figures 5 and 6). The cranial base angle was normal, whereas the mandibular plane angle (SN to GoGn), the mandibular plane to palatal plane angle, and the anterior lower facial height to the anterior upper facial height ratio were increased in size when compared to the mean modern day samples of white populations. Also, an increased labial inclination of the upper central incisor was noted, resulting in a decreased interincisal angle. Interestingly, the angles formed between the functional occlusal plane and either the palatal plane or the AB line were normal.

The hypothetical orthodontic treatment plan of choice that would have been applied to "Myrtis", if she were alive today, would aim at normalizing her occlusion, while controlling her anterior facial height. In such a case, fixed orthodontic appliances would have been utilized to all the permanent teeth of both arches, prob-

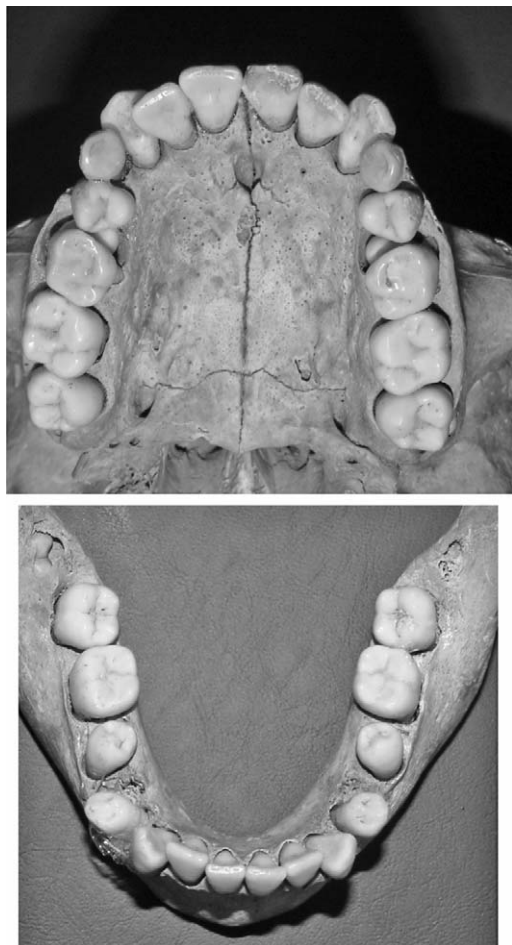


Figure 3. Occlusal view of the upper and lower dental arch of "Myrtis."

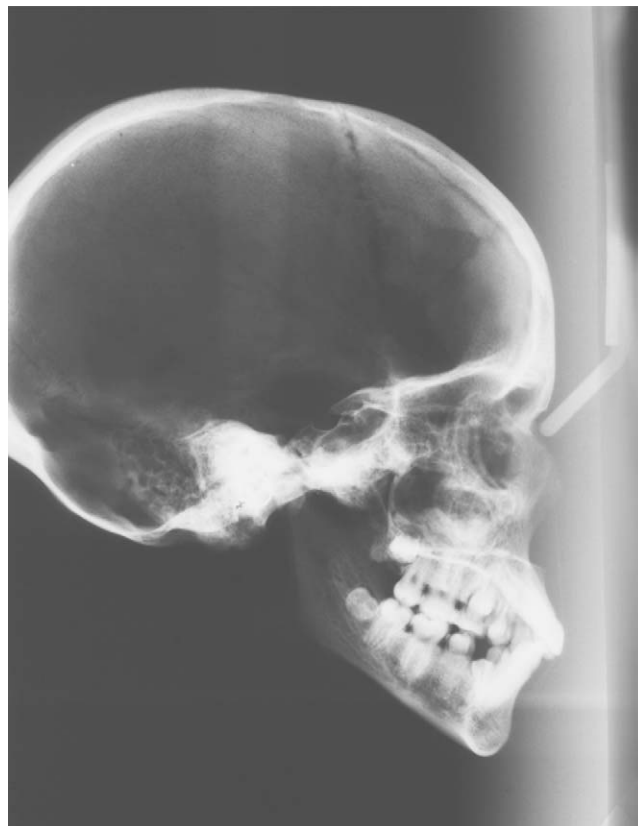

Figure 5. Lateral cephalometric radiograph of "Myrtis."

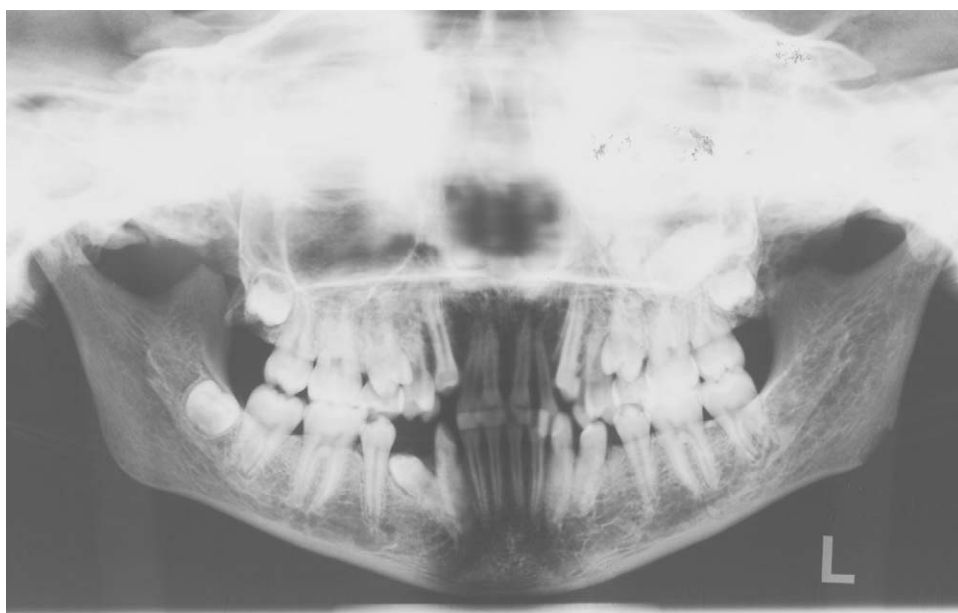

Figure 4. Panoramic radiograph of "Myrtis."

SKELETAL MEASUR.

SNA: 88,2
 Lande angle (FH-NA): 96,3
 SNB: 82
 Facial angle (FH-NPog): 89,6
 SNPog: 81,5
 NSBa: 123,8
 ANB: 6,2
 Wits ABO (mm): -4,6
 SN-PP: 9,6
 GoGn-SN: 38,9
 MP-PP: 26,4
 Y-axis: 58,5
 Gonial angle: 135,7
 UFH \ TFH: 45,6
 LFH \ TFH: 54,4

DENTAL MEASUR.

U1-FH: 121,2
 U1-SN: 113,2
 U1-PP: 122,8
 U1-APog: 39,4
 U1 to APog (mm): 9,3
 PP-FOP: 15,5
 AB-FOP: 97,4
 L1-FOP: 74,9
 L1-APog: 23,9
 L1 to APog (mm): 3,2

SOFT-TISSUE MEASUR.

Labionasal angle: N/A
 Up. lip to E-Plane: N/A
 Low. lip to E-Plane: N/A
 Z-angle (Merrifield): N/A
 H-angle: N/A

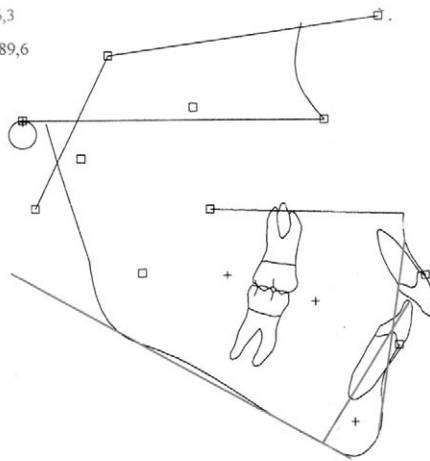


Figure 6. Tracing and analysis of the lateral cephalometric radiograph of "Myrtis" (utilized software: Viewbox 3.0).

ably with a distal and high-pull extraoral force in addition. Thus, the establishment of a Class I molar relationship would be facilitated in addition to providing the necessary space for the orthodontic movement of the upper canines into their correct place in the dental arch (following the extraction of their retained deciduous predecessors) and the palatal uprighting of the upper incisors. In typical modern day orthodontic treatment, the lower right first premolar also would have attained its normal position in the dental arch through the implementation of fixed appliances, following either its spontaneous eruption or eruption after a surgically assisted forced eruption technique.

CONCLUSIONS

As evidenced by the clinical and radiographic examination of the skull of "Myrtis", an 11-year-old female resident of Athens back in 430 BC, the following observations were made pertaining to her dental and craniofacial characteristics:

- Limited dental pathology;
- Class II molar and canine relationship;

- Coincidence of dental arch midlines;
- Ectopic buccal and mesial eruption of the permanent upper canines and ectopic distal eruption of the lower right first premolar;
- Retained deciduous upper canines;
- Missing germ of lower left third molar;
- Macroscopically symmetrical craniofacial complex;
- Class II jaw relationship owed to protruding maxilla;
- Hyperdivergent skeletal profile;
- Increased anterior lower facial height;
- Labial inclination of the upper central incisors, resulting in a slightly increased overjet and a decreased interincisal angle.

Although "Myrtis" was in definite need of orthodontic treatment by the time she was taken ill by the Plague of Athens, the lack of medical support was unfortunately (and fatally) proven to be more important.

REFERENCES

1. Angel JL. A racial analysis of the Ancient Greeks: an essay on the use of morphological types. *Am J Phys Anthropol.* 1944;2:297–300.
2. Angel JL. Skeletal change in ancient Greece. *Am J Phys Anthropol.* 1946;4:69–97.
3. Angel JL. Race, type and ethnic group in ancient Greece. *Hum Biol.* 1946;18:1–32.
4. Argyropoulos E, Sassouni V, Xeniotou A. A comparative cephalometric investigation of the Greek craniofacial pattern through 4,000 years. *Angle Orthod.* 1989;59:195–204.
5. Papagrigorakis MJ. *Craniofacial Morphology in Ancient Greeks* [master's thesis]. Department of Orthodontics and Facial Orthopedics, University of Bergen, Norway; 1993.
6. Baziotopoulou-Valavani EA. Mass burial from the cemetery of Kerameikos. In: Stamatopoulou M, Yeroulanou M, eds. *Excavating Classical Culture. Recent Archaeological Discoveries in Greece. Studies in Classical Archaeology I.* BAR International Series 1031. Oxford, England: Archaeopress; 2002:187–201.
7. Papagrigorakis MJ, Yapijakis C, Synodinos PN, Baziotopoulou-Valavani E. DNA examination of ancient dental pulp incriminates typhoid fever as a probable cause of the Plague of Athens. *Int J Infect Dis.* 2006;10:206–214.
8. Papagrigorakis MJ, Yapijakis C, Synodinos PN, Baziotopoulou-Valavani E. (Letter to the Editor). Insufficient phylogenetic analysis may not exclude candidacy of typhoid fever as a probable cause of the Plague of Athens (reply to Shapero et al). *Int J Infect Dis.* 2006;10:335–336.
9. Papagrigorakis MJ, Synodinos PN, Yapijakis C. Ancient typhoid epidemic reveals possible ancestral strain of *Salmonella enterica* serovar Typhi. *Infect Genet Evol.* 2007;7:126–127.