

Effects of Hyperbaric Oxygen during Experimental Tooth Movement

Sila Gokce^a; A. Osman Bengi^b; Erol Akin^c; Seniz Karacay^d; Deniz Sagdic^e; Mehmet Kurkcu^e; Hasan Suat Gokce^f

ABSTRACT

Objective: To determine the effects of hyperbaric oxygen (HBO) on bone remodeling during orthodontic tooth movement.

Materials and Methods: Twenty-four male, adult Sprague Dawley rats were randomly divided into two groups. HBO was administered in the first group, and the second group served as a control. The mandibular first molars were moved mesially by means of Ni-Ti closed coil springs in all groups.

Results: Results were evaluated histomorphometrically and the parameters of trabecular bone volume (BV/TV), trabecular bone number (Tr.N), and trabecular separation (Tr.Sep) were evaluated at the interradicular bone area of the mandibular first molars. Increases in BV/TV and Tr.N and decreases in Tr.Sep revealed the osteoblastic activity of HBO. HBO application caused an increase in bone apposition and osteoblastic activity or a decrease in osteoclastic activity.

Conclusions: HBO enhanced the bone formation during experimental tooth movement. Therefore, the findings of this study support our hypothesis that osteoblastic activity might be modulated by changes in the environmental oxygen tension.

KEY WORDS: Hyperbaric oxygen; Rat; Tooth movement; Bone remodeling; Osteoblastic activity

INTRODUCTION

Hyperbaric oxygen therapy (HBO) is the inhalation of 100% oxygen inside a hyperbaric chamber that is pressurized to greater than 1 atmosphere absolute (ATA; 760 mm Hg). HBO delivers oxygen quickly and

systemically in high concentrations to injured areas. The increased pressure changes the normal cellular respiration process and causes oxygen to dissolve in the plasma. HBO is beneficial because it stimulates the growth of new blood vessels and results in a substantial increase in tissue oxygenation that can arrest certain types of infections, and enhance wound healing. HBO is typically administered at 1 to 3 ATA. While the duration of an HBO session is typically 90 to 120 minutes, the duration, frequency, and cumulative number of sessions have not been standardized.¹⁻³

HBO is appropriate for use in several surgical conditions as evidence-based therapy. These are gas gangrene, crush injuries, compartment syndromes and acute traumatic ischemias, enhancement of healing in selected problem wounds, exceptional blood loss anemia, necrotizing soft-tissue infections, refractory osteomyelitis, soft-tissue radionecrosis and osteoradionecrosis, compromised skin grafts and flaps, thermal burns, and intracranial abscesses.^{4,5}

The following mechanisms have been identified that serve to enhance the healing of treatment conditions: hyper-oxygenation, vasoconstriction, bactericidal/bacteriostatic effect, angiogenesis and neovascularization, and direct pressure.^{1,2,4}

HBO increases dissolved oxygen in the blood and results in a high partial pressure of oxygen (PaO₂). An

^a Research Scientist, Department of Orthodontics, Gulhane Military Medical Academy, Dental Sciences Center, Ankara, Turkey.

^b Associate Professor, Department of Orthodontics, Gulhane Military Medical Academy, Dental Sciences Center, Ankara, Turkey.

^c Professor and Department Chair, Department of Orthodontics, Gulhane Military Medical Academy, Dental Sciences Center, Ankara, Turkey.

^d Assistant Professor, Department of Orthodontics, Gulhane Military Medical Academy, Dental Sciences Center, Ankara, Turkey.

^e Assistant Professor, Department of Maxillofacial Surgery, Faculty of Dentistry, Cukurova University, Adana, Turkey.

^f Assistant Professor, Department of Prosthodontics, Gulhane Military Medical Academy, Dental Sciences Center, Ankara, Turkey.

Corresponding author: Dr Sila Gokce, Gulhane Military Medical Academy, Dental Science Center, Department of Orthodontics, Etlik 06018 Ankara, Turkey (e-mail: silagokce@yahoo.com).

Accepted: April 2007. Submitted: February 2007.

© 2007 by The EH Angle Education and Research Foundation, Inc.

increase of PaO_2 affects the oxygen tension in regenerating tissue, which promotes collagen and adenosine-triphosphate (ATP) synthesis, capillary ingrowth, and osteoblastic and osteoclastic activity.^{6,7} The stimulation of osteogenesis by HBO has been reported in animal experiments and clinical treatments.⁸⁻¹¹

Oxygen tension has a triggering role in bone remodeling.¹² The increase in oxygen tension causes cellular differentiation to osseous tissue, whereas decreased oxygen tension results in cartilage formation.¹³ There is a parallelism between the increase in oxygen tension and increase in osteoblastic and osteoclastic activity.³ HBO treatment causes a significant increase in bone formation such that lamellar bone develops in the chamber canal.¹⁴ There is also an acceleration in bone healing and an increase in the amount of new bone formation with HBO. HBO is beneficial to and accelerates the union of autogenous free bone grafts and the tissue incorporation of commercially pure (c.p.) titanium implants in free autogenous bone grafts.^{15,16}

HBO treatment is intermittent, and Po_2 returns to pre-existing levels within 10 minutes after treatment. The extremely high dose of oxygen during actual hyperbaric treatment is followed by a return to the hypoxic state with lactate build-up between treatments. Tissue macrophages migrate to the area and secrete a variety of biochemical messengers, including a chemotactic wound angiogenesis factor, in response to the high lactate levels that exist in the wound space.¹⁴ Therefore, angiogenesis is increased in the hypoxic area (injury area) by HBO. Neovascularization supplies more oxygen to the central area of the wound. This increased oxygen tension promotes osteogenesis, and all of these phenomena accelerate the healing of bone.¹⁵

HBO has been suggested to have a regulatory role in bone remodeling. However, its role in remodeling during orthodontic tooth movement is not fully understood. Therefore, the aim of this study was to evaluate the effects of HBO on bone tissue during experimental tooth movement.

MATERIALS AND METHODS

The experiment was carried out according to the guidelines for the use of experimental animals of Gulhane Military Medical Academy (Decision No. 04/36). The study comprised 24 adult, male Sprague Dawley rats of approximately the same age with an average weight of 250 grams. The rats were randomly divided into two equal groups and fed a standard pellet diet with tap water ad libitum. The animals were adapted to a 12-hour/12-hour light/dark cycle.

The rats were anesthetized with a xsilazine hydrochloride (10 mg/kg) and ketamine hydrochloride (90

mg/kg) combination before the application of the springs. The same chemicals were also used at a lethal dose prior to sacrifice. An orthodontic force was administered to all groups. Ni-Ti closed coil springs (0.305×0.915 mm), exerting 80 grams of reciprocal force, were applied bilaterally between the mandibular first molars and incisors. A prophylactic antibiotic, colicillin (0.1 mL/kg), was administered once to prevent infection that could be caused by trauma during application of the springs. The force was measured with a gauge and the springs were not reactivated during the experiment.

In the first group, HBO was administered for 60 minutes at 2.5 ATA, twice a day, with 80 grams of orthodontic force. In the second group only orthodontic force was administered. The rats were monitored during the experiment and were sacrificed on the seventh day of the experiment. The mandibles were dissected and placed in 0.1 M phosphate-buffered 2.5% glutaraldehyde solution for fixation.

Bone Histomorphometry

Histological sections were prepared according to the "Cutting-Grinding Technique."¹⁷ The mandibles were dehydrated using increasing ethanol concentrations. After dehydration, specimens were exposed to plastic infiltration using an increasing mixture of ethanol-methyl methacrylate. The plastic infiltrated tissue slices were placed in embedding molds, Technovit 7.200 VLC (Heraeus-Kulzer GmbH & Co KG, Hanau, Germany) was added, and the final polymerization process was accomplished.

The polymerized tissue blocks were prepared with a band saw to 100 μm thickness, transferred to micro-grinding system, and a tissue thickness of 10–20 μm was obtained. The sections were agitated in 10% H_2O_2 for 5 minutes, rinsed in water, wiped dry, and stained in toluidine blue. All sections were evaluated using an Olympus light microscope, and $\times 4$ images were transferred to a computer and the WinTAS (Trabecular Analyze System, version 1.2.9) program (Figures 1 and 2).

Three different measurements in the interradicular area of the first molars (cervical, middle, and apical) were performed. Measurements were repeated twice and the mean values calculated. All measurements and calculations were done following the American Society for Bone and Mineral Research nomenclature and guidelines.¹⁸ Trabecular bone volumes (BV/TV), trabecular bone numbers (Tr.N), and trabecular separations (Tr.Sep) were measured using the software package developed for bone histomorphometry.

Statistical Method

The statistics were performed by using an SPSS 10.0 (SPSSFW, SPSS Inc, Chicago, Ill) statistical

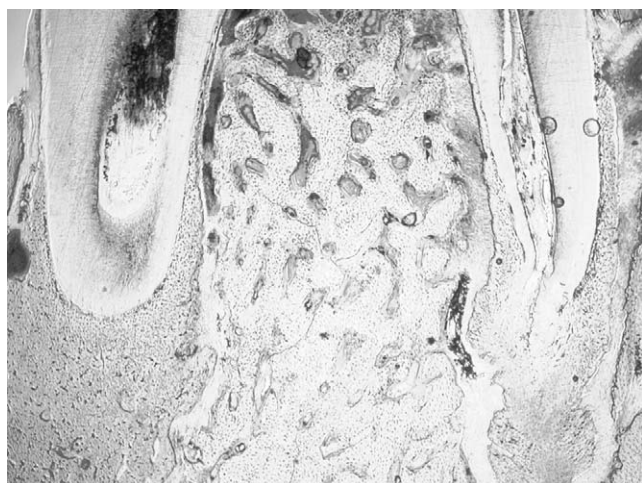


Figure 1. Histological section of HBO group.

package. Descriptive statistics were shown as mean \pm standard deviation (Table 1). The differences between HBO group and control group were determined with independent samples *t*-test. $P \leq .05$ was evaluated as statistically significant.

RESULTS

For the first 12–36 hours, following the insertion of springs and application of force, there was a reduction in the amount of pellets that the rats consumed. However, the consumption returned to its normal values afterwards.

In the HBO group the mean BV/TV was $30.539 \pm 6.141\%$, the mean Tr.N was 27.104 ± 6.319 and the mean Tr.Sep was $42.301 \pm 6.224 \mu\text{m}$. In the control group, the mean BV/TV was $17.695 \pm 10.638\%$, the mean Tr.N was 19.331 ± 7.210 and the mean Tr.Sep was $59.550 \pm 14.177 \mu\text{m}$.

Statistically significant differences were observed in all parameters when the HBO group was compared with the control group. When the outcomes of the TAS analysis were interpreted, compared to control group, the increase in BV/TV was 72.59% in the HBO group. In the Tr.N parameter there was an increase of 40.20% in the HBO group compared to the control group. When the Tr.Sep values of the HBO group were compared with the control group, the decreases in Tr.Sep were 28.97% against the control group. Increase in the BV/TV ($P < .0001$) and Tr.N ($P < .001$), and decrease in the Tr.Sep ($P < .0001$) were statistically significant (Table 2).

DISCUSSION

The effect of HBO is still under investigation. It is known that it can promote the healing phase of an

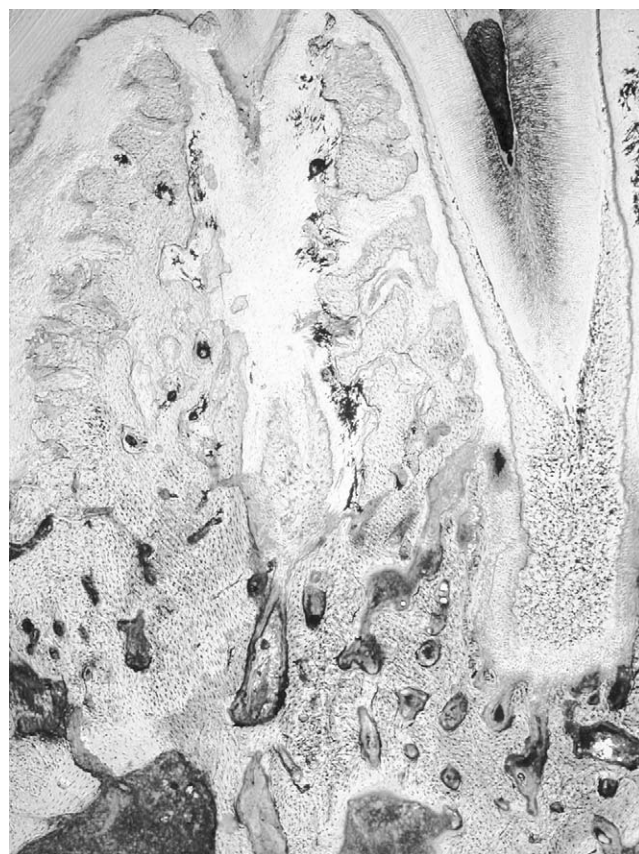


Figure 2. Histological section of control group.

ischemic wound, but its effects are doubtful for normal wounds.

HBO's effects on bone have been investigated by several researchers. There is controversy about the interaction of HBO and fracture healing. Previous investigations suggest a triggering role for oxygen tension (an environmental factor) in bone remodeling. Correspondingly, abrupt changes in oxygen availability within the periodontium have been suggested to have a regulatory role in alveolar bone remodeling during tooth movement,¹² similar to that seen in bone growth or fracture healing. Here we created an experimental situation that simulates the movement of teeth in the

Table 1. Descriptive Statistics of BV/TV, Tr.N, and Tr.Sep for HBO and Control Groups

		Mean	SD
BV/TV	HBO	30.539	6.141
	Control	17.695	10.638
Tr.N	HBO	27.104	6.319
	Control	19.331	7.210
Tr.Sep	HBO	42.301	6.224
	Control	59.550	14.177

^a BV/TV indicates trabecular bone volume; Tr.N, trabecular bone number; Tr.Sep, trabecular separation; HBO, hyperbaric oxygen.

Table 2. Comparison of Between-Group Differences for BV/TV, Tr.N, and Tr.Sep^a

	Mean Difference	Standard Error Difference	<i>t</i>	<i>P</i> >	Significance
BV/TV	12.844	2.747	4.676	.0001	****
Tr.N	7.773	2.144	3.626	.001	***
Tr.Sep	-17.249	3.462	-4.982	.0001	****

^a BV/TV indicates trabecular bone volume; Tr.N, trabecular bone number; Tr.Sep, trabecular separation.

*** *P* < .001, **** *P* < .0001.

bone, where bone remodeling is accelerated, in the presence of oxygen tension.

Since the short cycle in female rats causes hormonal variations, our study was carried out with male rats.¹⁹ In previous studies, an orthodontic force was exerted by closed coil springs between the molars and incisors or elastics between the first and second molars of the rat.²⁰⁻²³ The mechanics used for force application creates retention points and causes gingival inflammation.²⁰⁻²⁵ As a result, mediators that are effective in bone resorption and osteoclastic activity are excreted.²⁶ The application of force mechanics may lead to the risk of trauma, edema, and infection. To eliminate these probabilities, one dose of prophylactic antibiotic was administered to all rats.

Duration, frequency, and cumulative number of sessions for HBO have not been standardized and various protocols have been used by several investigators. In rabbits, 20 HBO sessions with a protocol of 60 minutes at 2.4 ATA, 100% inspired oxygen flow twice a day were performed before free bone grafting, and 10 sessions were performed after the bone grafting.¹⁶ In a similar study by the same group, HBO treatment was performed for 60 minutes at 2.4 ATA once a day for 20 days.¹⁵ Again in rabbits, 18 HBO sessions with a protocol of 90 minutes at 2.5 ATA once a day were performed together with distraction. This protocol caused an increase in osteoblastic activity at the distraction osteogenesis site when applied before the operation.¹⁰ In a study on rats by Okubo et al¹¹ HBO was performed for 60 minutes at 2 ATA, once a day for 3, 7, or 21 days. Based on these investigations, we selected a protocol for the HBO sessions of 60 minutes, 2.5 ATA, twice a day for 7 consecutive days.

We found an increase in BV/TV and Tr.N when we moved the teeth in the presence of HBO. This showed the increased capacity of bone formation with HBO. This is important since moving teeth alters the balance in that area, and formation of new bone in the resorption areas is normally a long process. The positive effects of HBO on bone have been shown in several studies. In one study, HBO was applied at 2.5–2.8 ATA for 90–120 minutes to patients with osteoradio-

necrosis (ORN).⁸ The patients had 5–10 preoperative and 5–7 postoperative sessions. Surgical therapy consisted of decortication of the affected bone, which was subsequently covered with a free periosteal transplant from the tibia. HBO had facilitated the healing phase.

HBO is a promising adjunct to surgery in the treatment of mandibular and maxillary ORN and chronic osteomyelitis. This was shown in a study where patients with ORN were given 2.4 ATA of HBO for 60 minutes once a day, 20–40 sessions before the operation, and 14–20 sessions after the operation.⁹

HBO also assists in the prognosis of dental procedures. When c.p. titanium implants are placed in a free autogenous bone graft, HBO increases bone-to-implant contacts in the grafted bone. Therefore, HBO treatment is beneficial for the tissue incorporation of c.p. titanium implants when placed in free autogenous bone grafts.¹⁵ Sawai et al¹⁵ investigated the effects of HBO therapy on autogenous free bone grafts transplanted from the iliac crest to the mandibles of rabbits. One week after grafting, osteoid formation in the experimental group was much greater than in the control group, and unions between the host bone and the graft were observed at 2 weeks. These results indicated that HBO accelerates the union of autogenous free bone grafts. The results of this study are in accord with our observations relating the increase of bone volume and osteoblastic activity.

We observed that there was a decrease in Tr.Sep in the HBO group. This reinforces the argument that HBO affects the rate of bone resorption. This could be through the stimulation of the osteoblastic cells or inhibition of osteoclastic cells. Tuncay et al¹² investigated ambient hypoxic and hyperoxic effects on osteoblast function, where osteoblast-enriched cultures from fetal rat calvariae were exposed to atmospheres of hypoxia (10% O₂) and hyperoxia (90% O₂) and assayed for media pH, pO₂, pCO₂, cellular proliferation, alkaline phosphatase (AP) activity, and collagen synthesis.

The results of this study showed that in low ambient oxygen tension, cellular proliferation increases, whereas the AP activity, collagen synthesis, media pO₂ and pCO₂ decrease. In contrast, in hyperoxic conditions cellular proliferation is suppressed with concomitant increases in AP activity, collagen synthesis, pO₂, and pCO₂. These findings are in conjunction with earlier reports suggesting a role for oxygen in bone remodeling. Our observations on the effects of HBO on bone remodeling also point to the same conclusions.

HBO also has effects on recombinant human bone morphogenetic protein-2 (rhBMP-2), which is a potent osteogenic protein. Okubo et al¹¹ implanted rhBMP-2 into the calf muscle of rats. Under HBO conditions, the new bone formation was significantly increased, and

cartilage was present at the outer edge of the implanted material. These results suggest that HBO accelerated the activity and rate of osteoinduction by rhBMP-2. HBO itself also increases lamellar bone formation.¹³ While increased oxygen tension results in cellular differentiation toward osseous tissue, decreased oxygen tension results in cartilage formation.¹⁶ These findings again substantiate the fact that HBO has an osteoinductive effect that increases the remodeling activity of bone.

The beneficial effects of HBO on soft tissue and wound healing have been introduced by various investigations.^{1,2,8-10,12,14,15} A few investigations suggested that the simultaneous use of antibiotics with HBO increases the bactericidal effect (synergic effect).^{1,2} In our study, although we administered one dose of prophylactic antibiotic to all rats, the amount of trauma, edema, and infection was markedly lower in the HBO group when compared with the control group.

CONCLUSIONS

- HBO enhanced the bone formation during experimental tooth movement.
- The findings of this study support our hypothesis that osteoblastic activity might be modulated by changes in the environmental oxygen tension.

ACKNOWLEDGMENTS

This research was supported by Gulhane Military Medical Academy, Department of Research and Development as a PhD thesis (44/2004), and the histomorphometric evaluation of the research was conducted at Cukurova University Laboratories, Turkey.

REFERENCES

- Gordillo GM, Sen CK. Revisiting the essential role of oxygen in wound healing. *Am J Surg*. 2003;186(3):259–263.
- Gottrup F. Oxygen in wound healing and infection. *World J Surg*. 2004;28(3):312–315.
- Tibbles PM, Edelsberg JS. Hyperbaric-oxygen therapy. *N Engl J Med*. 1996;334(25):1642–1648.
- Kindwall EP. A history of hyperbaric medicine. In: Kindwall EP, Whelan H, eds. *Hyperbaric medicine practice*. Flagstaff, AZ: Best Publishing Co. 1999:1–20.
- MacFarlane C, Cronje FJ. Hyperbaric oxygen and surgery. *S Afr J Surg*. 2001;39(4):117–121.
- Niinikoski J, Hunt TK. Oxygen tensions in healing bone. *Surg Gynecol Obstet*. 1972;134(5):746–750.
- Stern BD, Glimcher MJ, Mechanic GL, Goldhaber P. Studies of collagen degradation during bone resorption in tissue culture. *Proc Soc Exp Biol Med*. 1965;119:577–583.
- Aitasalo K, Niinikoski J, Grenman R, Virolainen E. A modified protocol for early treatment of osteomyelitis and osteoradionecrosis of the mandible. *Head Neck* 1998;20(5):411–417.
- David LA, Sandor GK, Evans AW, Brown DH. Hyperbaric oxygen therapy and mandibular osteoradionecrosis: a retrospective study and analysis of treatment outcomes. *J Can Dent Assoc*. 2001;67(7):384.
- Muhonen A, Peltomaki T, Knuuti J, Raitakari O, Happonen RP. Osteoblastic activity of the rabbit temporomandibular joint during distraction osteogenesis assessed by [18F] fluoride positron emission tomography. *Eur J Oral Sci*. 2002;110(2):144–148.
- Okubo Y, Bessho K, Fujimura K, Kusumoto K, Ogawa Y, Iizuka T. Effect of hyperbaric oxygenation on bone induced by recombinant human bone morphogenetic protein-2. *Br J Oral Maxillofac Surg*. 2001;39(2):91–95.
- Tuncay OC, Ho D, Barker MK. Oxygen tension regulates osteoblast function. *Am J Orthod Dentofacial Orthop*. 1994;105(5):457–463.
- Shaw JL, Bassett CA. The effects of varying oxygen concentrations on osteogenesis and embryonic cartilage in vitro. *J Bone Joint Surg Am*. 1967;49(1):73–80.
- Nilsson P, Albrektsson T, Granstrom G, Rockert HO. The effect of hyperbaric oxygen treatment on bone regeneration: an experimental study using the bone harvest chamber in the rabbit. *Int J Oral Maxillofac Implants*. 1988;3(1):43–48.
- Sawai T, Niimi A, Johansson CB, Sennerby L, Ozeki K, Takahashi H, Albrektsson T, Ueda M. The effect of hyperbaric oxygen treatment on bone tissue reactions to c.p. titanium implants placed in free autogenous bone grafts. A histomorphometric study in the rabbit mandible. *Clin Oral Implants Res*. 1998;9(6):384–397.
- Sawai T, Niimi A, Takahashi H, Ueda M. Histologic study of the effect of hyperbaric oxygen therapy on autogenous free bone grafts. *J Oral Maxillofac Surg*. 1996;54(8):975–981.
- Donath K. *Preparation of Histologic Sections*. Norderstedt, Germany: EXAKT-Kulzer; 1995:1–6.
- Parfitt AM, Drezner MK, Glorieux FH, Kanis JA, Malluche H, Meunier PJ, Ott SM, Recker RR. Bone histomorphometry: standardization of nomenclature, symbols, and units. Report of the ASBMR Histomorphometry Nomenclature Committee. *J Bone Miner Res*. 1987;2(6):595–610.
- Haruyama N, Igarashi K, Saeki S, Otsuka-Isoya M, Shinoda H, Mitani H. Estrous-cycle-dependent variation in orthodontic tooth movement. *J Dent Res*. 2002;81(6):406–410.
- Kvinnslund S, Heyeraas K, Ofjord ES. Effect of experimental tooth movement on periodontal and pulpal blood flow. *Eur J Orthod*. 1989;11(3):200–205.
- Rygh P, Bowling K, Hovlandsdal L, Williams S. Activation of the vascular system: a main mediator of periodontal fiber remodeling in orthodontic tooth movement. *Am J Orthod*. 1986;89(6):453–468.
- Yamasaki K. The role of cyclic AMP, calcium, and prostaglandins in the induction of osteoclastic bone resorption associated with experimental tooth movement. *J Dent Res*. 1983;62(8):877–881.
- Yamasaki K, Shibasaki Y, Fukuhara T. Behavior of mast cells in periodontal ligament associated with experimental tooth movement in rats. *J Dent Res*. 1982;61(12):1447–1450.
- Otero RL, Parodi RJ, Ubios AM, Carranza FA Jr, Cabrini RL. Histologic and histometric study of bone resorption after tooth movement in rats. *J Periodontal Res*. 1973;8(5):327–333.
- Rygh P. Ultrastructural changes in tension zones of rat molar periodontium incident to orthodontic tooth movement. *Am J Orthod*. 1976;70(3):269–281.
- Wennstrom JL, Lindhe J, Sinclair F, Thilander B. Some periodontal tissue reactions to orthodontic tooth movement in monkeys. *J Clin Periodontol*. 1987;14(3):121–129.