

## Maxillary Protraction Effects on Anterior Crossbites

*Repaired Unilateral Cleft Versus Noncleft Prepubertal Boys*

Haichao Jia<sup>a</sup>; Weiran Li<sup>b</sup>; Jiuxiang Lin<sup>b</sup>

### ABSTRACT

**Objective:** To test the hypothesis that there is no difference between the effects of maxillary protraction on anterior crossbites in repaired unilateral cleft lip and palate (UCLP) and noncleft prepubertal boys.

**Materials and Methods:** Eighteen operated UCLP boys with anterior crossbite (aged  $9.54 \pm 1.21$  years) were the experimental subjects. Eighteen noncleft boys with similar malocclusion (aged  $9.75 \pm 1.46$  years) were selected as a control group. A Hyrax appliance and reverse headgear were applied. Lateral cephalometric radiographs were taken before and after the treatment. Computerized cephalometric analysis and statistics were carried out.

**Results:** There were no significant differences in anterior movement of point A between the two groups ( $P > .05$ ). ANB increased by  $3.82^\circ$  and A-Pg (FH) increased by 5.89 mm in the UCLP group. ANB increased by  $2.68^\circ$  and A-Pg (FH) increased by 3.66 mm in the noncleft group. The change of sagittal skeletal intermaxillary relationships was significantly larger in the UCLP group than in the noncleft group ( $P < .05$ ). The change of lower lip in the UCLP group was less than in the noncleft group ( $P < .05$ ).

**Conclusions:** The hypothesis is rejected. The changes of sagittal skeletal intermaxillary relationship and mandibular clockwise rotation were larger in the operated UCLP patients than in the noncleft subjects. The amount of the lower lip retrusion was significantly less in the UCLP patients.

**KEY WORDS:** Crossbite; Cleft lip and palate; Maxillary protraction

### INTRODUCTION

Midface deficiency is often found in children after surgery of complete unilateral cleft lip and palate (UCLP). Normalization of the intermaxillary relationship is important to dentofacial appearance and self-confidence. Correction of crossbite is an important goal for the postoperative cleft patient.<sup>1</sup>

Many studies have reported that the anterior cross-

bite of postoperative patients with cleft and the noncleft can be treated successfully by maxillary protraction. This procedure was reported to improve the intermaxillary relationship by accelerating maxillary growth, mandibular rotation in a clockwise direction, augmentation of facial height, forward movement of maxillary dentition, and lingual tipping of the lower incisors.<sup>2-8</sup>

The effect of maxillary protraction between the postoperative UCLP patients and the noncleft patients may be different, however. Sarnas and Rune<sup>9</sup> reported that the mean net effect in anterior displacement of the maxilla (SNA) was larger in the cleft lip and palate patients than in the noncleft patients. Jia et al<sup>10</sup> reported that there was no difference in anterior movement of point A between UCLP and noncleft patients. These studies pooled boys and girls or mixed up various types of cleft together. What is the difference in the effect of maxillary protraction between the postoperative patient with UCLP and the noncleft patient?

The objective of the study is to compare the treat-

<sup>a</sup> Assistant Professor, Department of Orthodontics, School of Stomatology, Capital Medical University, Beijing, China. Formerly Postgraduate student, Department of Orthodontics, School and Hospital of Stomatology, Peking University.

<sup>b</sup> Professor, Department of Orthodontics, School and Hospital of Stomatology, Peking University, Beijing, China.

Corresponding author: Dr Jiuxiang Lin, Department of Orthodontics, School and Hospital of Stomatology, Peking University, Beijing, No. 22 Zhong Guan Cun Southern Street, Beijing 100081, China (e-mail: jxlin@pku.edu.cn)

Accepted: September 2007. Submitted: May 2007.

© 2008 by The EH Angle Education and Research Foundation, Inc.

ment effects of maxillary protraction on the anterior crossbite in boys with a surgically repaired UCLP and a noncleft before puberty.

## MATERIALS AND METHODS

### Sample Selection

A prospective controlled trial was carried out on two groups in this study. All patients in the UCLP and noncleft groups were treated at the Department of Orthodontics, School of Stomatology, Peking University, during the years 2003 to 2005.

### UCLP Group

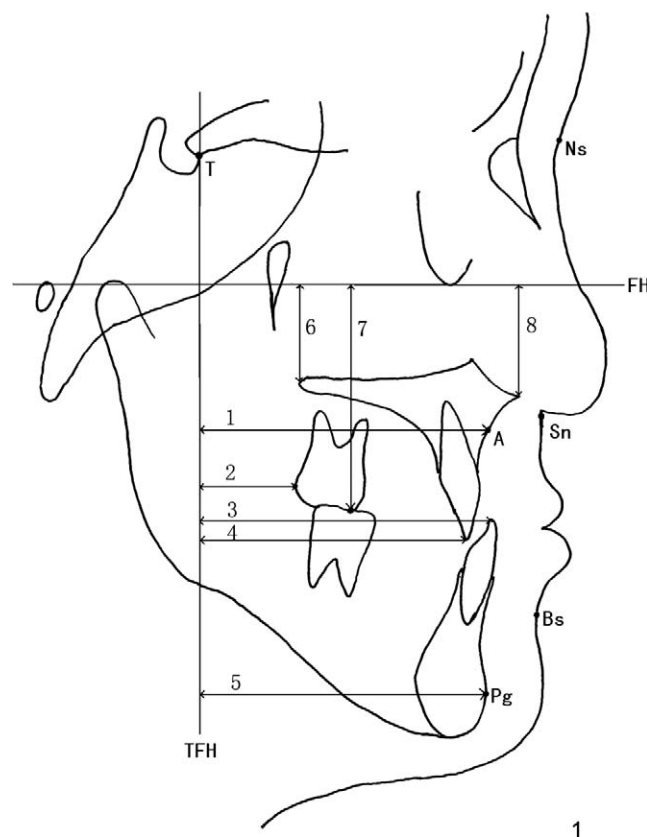
Twenty boys with anterior crossbite with a postoperative UCLP were chosen as the study subjects. Two subjects refused to participate because of the remoteness of their home. Therefore, the UCLP group consisted of 18 boys. The mean age at the time of first observation was  $9.54 \pm 1.21$  years. Inclusion criteria were (1) anterior crossbite with operated UCLP, (2) Fishman's skeletal maturity indicator (SMI)<sup>11</sup> 1-3, (3) concave profile with  $-4^\circ < ANB < 0^\circ$ , and (4) no previous orthodontic treatment. The patients had lip surgery at the age of 6 months and palate surgery at the age of 2 to 3 years.

### Noncleft Group

Eighteen boys with anterior crossbite comprised the noncleft group. These patients came from another clinical trial occurring at the same time on maxillary protraction treating anterior crossbite without a cleft. The data were consecutive. The mean age at the time of first observation was  $9.75 \pm 1.5$  years. The inclusion criteria were (1) Angle's Class III malocclusion with anterior crossbite, (2) SMI 1-3, (3) concave profile with  $-4^\circ < ANB < 0^\circ$ , and (4) no previous orthodontic treatment. All patients or their parents gave informed consent.

### Treatment Protocol

The Hyrax appliance and a reverse headgear were used in the treatment. The protraction force was 450 to 500 g on each side and directed  $10^\circ$  downward and forward in relation to the occlusion plane. Patients were instructed to wear the face mask for 12 hours per day. The maxillary protraction stopped after achieving about 2 mm of positive overjet, occluding posterior teeth, and at least 6 months of treatment. The mean treatment time in the UCLP group was  $9.2 \pm 1.6$  months, and in the noncleft group, it was  $8.2 \pm 3.3$  months. There was no statistically significant difference between the two groups ( $P > .05$ ).



**Figure 1.** Coordinate analysis. (1) A-TFH. (2) U6-TFH. (3) L1-TFH. (4) U1-TFH. (5) Pg-TFH. (6) PNS-FH. (7) U6-FH. (8) ANS-FH.

### Cephalometric Analysis

The first lateral cephalogram was taken a half month prior to the initiation of maxillary protraction (T0). The second radiogram was taken after protraction treatment (T1). The radiographic enlargement was 11.1%.

Cephalometric analysis included a general and a coordinate analysis (Figure 1). The outlines of the first radiogram were traced on acetate paper. Point porion (P) and orbitale (Or) were drawn on the first cephalogram, transferred to the second cephalogram, and dotted by superimposition on the stable structures of the cranial base, as suggested by Bjork et al.<sup>12</sup> The coordinate analysis is based on a reference system consisting of horizontal (FH) and vertical (TFH) lines. Point T, the superior point of the anterior wall of the sella turcica at the junction with tuberculum sellae, was used as the origin.<sup>12,13</sup> The Frankfort horizontal plane of the first radiogram was used as the best estimate for the FH, and the line perpendicular to this plane through point T was TFH.<sup>14</sup> Calculations were performed by means of a computerized cephalometric system HUAZHENG (Department of Orthodontics, School of Stomatology, Peking University).

**Table 1.** Comparison of Dentofacial Morphology Between the Unilateral Cleft Lip and Palate (UCLP) and Noncleft Groups Before Treatment (N = 18)

Variable	UCLP		Noncleft		<i>t</i>	<i>P</i>
	Mean	SD	Mean	SD		
Maxillomandibular sagittal relations						
SNA, °	74.65	3.06	78.31	3.89	−3.14	.004**
SNB, °	76.85	3.51	80.36	4.20	−2.72	.010**
ANB, °	−2.19	2.18	−2.04	1.95	−2.22	.829
A-TFH, mm	54.64	3.05	58.37	3.55	−3.38	.002**
Pg-TFH, mm	53.63	5.49	59.77	6.66	−2.96	.006**
A-Pg (FH), mm	0.73	4.27	−1.40	4.27	1.47	.150
Ptm-A (FH), mm	41.98	2.80	44.18	2.02	−2.70	.011*
Ar-Pg, mm	101.99	6.23	104.89	6.15	−1.4	.169
Maxillomandibular vertical relations						
MP/SN, °	38.96	4.32	38.21	5.32	0.46	.645
PP/SN, °	12.10	3.38	9.04	3.11	2.83	.008**
N-ANS, mm	52.47	3.80	54.82	3.77	−1.86	.072
N-Me, mm	117.23	6.63	119.27	7.27	−0.88	.386
ANS-Me, mm	64.83	4.19	64.12	4.43	0.49	.625
ANS-FH, mm	21.59	3.24	23.15	2.90	−1.48	.149
PNS-FH, mm	19.74	3.07	23.26	2.78	−3.51	.001**
Dental relations						
Overjet, mm	−5.45	2.46	−3.30	1.88	−2.95	.006**
Overbite, mm	3.59	2.34	4.05	2.18	−0.61	.545
U1/SN, °	96.90	6.70	106.59	7.78	−3.95	<.001**
L1/MP, °	83.15	5.13	83.45	4.36	−0.19	.854
U1/L1, °	140.98	8.70	131.87	8.14	3.19	.003**
U1-TFH, mm	53.47	4.11	60.74	3.38	−5.63	<.001**
L1-TFH, mm	59.03	4.34	64.01	3.30	−3.76	.001**
U6-TFH, mm	18.97	3.25	21.97	3.37	−2.64	.013*
U6-FH, mm	42.44	3.53	44.06	3.34	−1.37	.179
L6-MP, mm	30.17	1.60	29.55	2.23	0.96	.346
Soft tissue						
S-Ns-Sn, °	78.59	3.31	85.11	3.35	−5.79	<.001**
S-Ns-Bs, °	80.44	3.43	84.31	2.87	−3.62	.001**
Sn-Ns-Bs, °	−1.85	3.16	0.81	2.44	−2.79	.009**
UL-EP, mm	−2.81	2.92	−0.79	2.30	−2.31	.027*
LL-EP, mm	3.49	3.12	3.79	2.45	−0.32	.753
LL-UL (EP), mm	6.31	2.28	4.58	2.01	2.41	.021*
UL-U1, mm	15.53	3.50	15.84	2.10	−0.33	.746
LL-L1, mm	15.40	2.70	15.10	2.48	0.34	.734

\*  $P < .05$ ; \*\*  $P < 0.01$ .

## Statistical Analysis

A paired *t*-test was performed to assess the T1–T0 changes in the two treatment groups. An independent samples *t*-test was carried out to compare the craniofacial starting forms at T0 and the T1–T0 changes between the two groups. The data were analyzed with SAS 8.0. Statistical significance was tested at the  $P < .05$  and  $P < .01$  levels.

## RESULTS

### Pretreatment Dentofacial Morphology

A comparison of dentofacial morphology between the UCLP and noncleft groups before treatment is

shown in Table 1. There was no statistically significant difference in the sagittal intermaxillary relationship expressed by the angle ANB and distance A-Pg (FH) between the two groups ( $P > .05$ ). The upper jaw (angle SNA, distance A-TFH) was significantly more retrognathic ( $P < .01$ ), and the mean sagittal length of the upper jaw (Ptm-A [FH]) was significantly shorter in the UCLP group than in the noncleft group.

The mandible expressed by SNB and Pg-TFH was significantly more retrognathic in the UCLP group than in the noncleft group ( $P < .01$ ). The maxillary incisors were significantly more retroclined (U1/SN), and negative overjet was larger in the UCLP than in the noncleft group ( $P < .01$ ). The upper lip (UL-EP) was significantly more retrusive in the UCLP group. There was

**Table 2.** Changes of Dentofacial Morphology in the Unilateral Cleft Lip and Palate (UCLP) and Noncleft Groups During Protraction Treatment (N = 18)

Variable	UCLP (T1-T0)			Noncleft (T1-T0)			UCLP vs Noncleft	
	Mean	SD	P	Mean	SD	P	t	P
<b>Maxillomandibular sagittal relations</b>								
SNA, °	1.50	1.32	<.001**	1.42	1.11	<.001**	0.20	.843
SNB, °	-2.31	2.06	<.001**	-1.32	1.04	<.001**	-1.78	.084
ANB, °	3.82	1.60	<.001**	2.68	0.75	<.001**	2.67	.012*
A-TFH, mm	2.34	0.95	<.001**	2.12	0.69	<.001**	0.79	.434
Pg-TFH, mm	-3.57	2.74	<.001**	-1.61	1.54	.001**	-2.57	.015*
A-Pg (FH), mm	5.89	2.58	<.001**	3.66	1.51	<.001**	3.10	.004**
Ptm-A (FH), mm	1.68	0.83	<.001**	1.34	1.11	<.001**	1.05	.299
Ar-Pg, mm	0.62	1.68	.208	1.60	1.86	.003**	-1.64	.111
<b>Maxillomandibular vertical relations</b>								
MP/SN, °	2.86	2.14	<.001**	1.47	1.56	.001**	2.18	.037*
PP/SN, °	-0.42	2.95	.560	-1.02	1.54	.015*	0.76	.455
N-ANS, mm	1.52	2.09	.007**	0.71	1.32	.043*	1.37	.179
N-Me, mm	5.52	2.64	<.001**	3.49	1.41	<.001**	2.81	.008**
ANS-Me, mm	4.56	1.83	<.001**	3.43	2.79	<.001**	1.43	.163
ANS-FH, mm	1.25	1.53	.003**	0.88	1.44	.023*	0.73	.469
PNS-FH, mm	1.47	1.70	.002**	1.65	2.02	.004**	-0.28	.783
<b>Dental relations</b>								
Overjet, mm	6.63	2.62	<.001**	6.65	1.73	<.001**	-0.02	.982
Overbite, mm	-2.12	2.72	.004**	-1.29	1.99	.017*	-1.03	.309
U1/SN, °	3.24	5.18	.017*	3.95	3.69	<.001**	-0.46	.646
L1/MP, °	-3.75	4.90	.005**	-5.18	3.68	<.001**	0.95	.349
U1/L1, °	-2.35	8.32	.248	-0.35	4.63	.770	-0.85	.401
U1-TFH, mm	3.25	2.09	<.001**	4.29	1.73	<.001**	-1.60	.118
L1-TFH, mm	-2.94	2.07	<.001**	-2.59	1.48	<.001**	-0.58	.565
U6-TFH, mm	3.02	2.07	<.001**	3.09	1.38	<.001**	-0.10	.920
U6-FH, mm	3.50	1.54	<.001**	1.94	2.70	.009**	2.11	.043*
L6-MP, mm	1.58	1.19	<.001**	1.74	0.95	<.001**	-0.45	.654
<b>Soft tissue</b>								
S-Ns-Sn, °	2.04	2.91	.036*	0.97	1.13	.002**	0.16	.871
S-Ns-Bs, °	-1.12	1.84	<.001**	-1.01	1.55	.014*	-1.85	.074
Sn-Ns-Bs, °	4.31	2.32	<.001**	1.97	1.76	<.001**	1.65	.108
UL-EP, mm	2.13	2.60	.003**	1.56	1.46	<.001**	0.80	.429
LL-EP, mm	0.74	2.71	.264	-1.37	1.86	.008**	2.67	.012*
LL-UL (EP), mm	-1.39	2.59	.036*	-2.88	1.56	<.001**	2.05	.048*
UL-U1, mm	-1.16	3.06	.128	-2.28	1.66	<.001**	1.34	.188
LL-L1, mm	1.98	2.84	.009*	0.54	1.65	.193	1.82	.078

\*  $P < .05$ ; \*\*  $P < .01$ .

a significantly worse nasal-lip-chin relationship (LL-UL [EP]) and a more concave profile (Sn-Ns-Bs) in the UCLP group than in the noncleft group ( $P < .01$ ).

### Changes of Dentofacial Morphology After Orthodontic Treatment

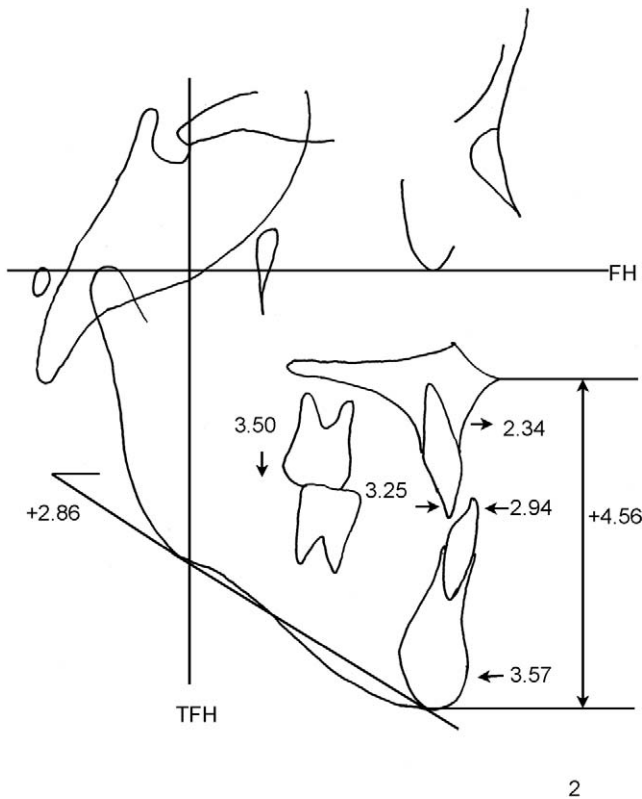
The changes of skeletal and soft tissue after maxillary protraction treatment are shown in Table 2 and Figures 2 and 3.

### Skeletal Change

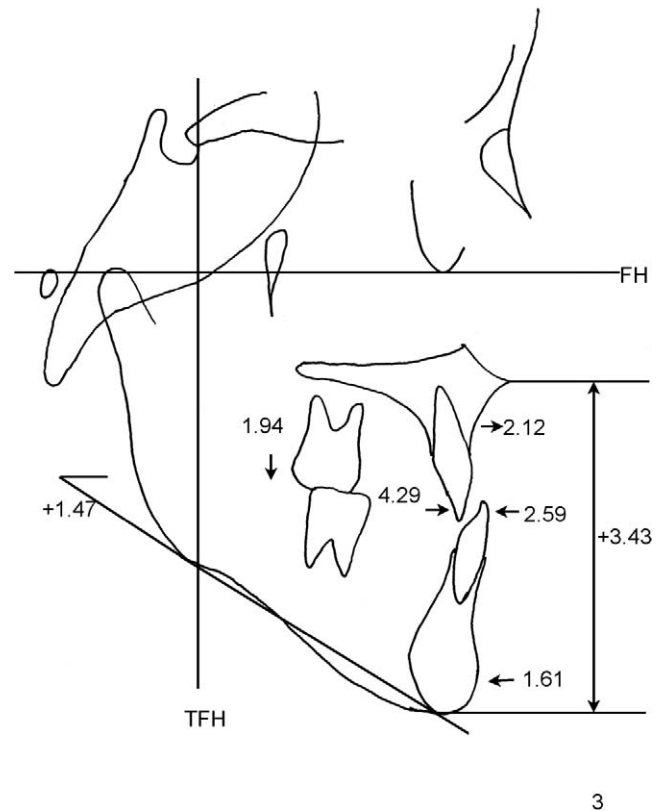
After treatment, a significant increase in the SNA angle ( $P < .01$ ) and A-TFH distance ( $P < .05$ ) showed that the maxilla moved forward in the two groups, and

the difference between the two groups was not statistically significant ( $P > .05$ ). The sagittal skeletal intermaxillary relationship was significantly improved in the two groups and was especially greater in the UCLP group by a mean increase of the angle ANB and the distance A-Pg (FH). The mean change of intermaxillary relationship was evaluated by A-Pg (FH).

The change of backward rotation of the mandible contributed to 61% in the UCLP group (Pg-TFH decreased 3.57 mm and A-Pg [FH] increased 5.89 mm,  $3.57/5.89 = 0.61$ ). The change of backward rotation of the mandible contributed to 44% in the noncleft group (Pg-TFH decreased 1.61 mm and A-Pg [FH] increased 3.66 mm,  $1.61/3.66 = 0.44$ ). The mandibular plane angle and the upper molar height (U6-FH) in-



**Figure 2.** Skeletal and dental changes in the unilateral cleft lip and palate group.



**Figure 3.** Skeletal and dental changes in the noncleft group.

creased significantly in the two groups and was significantly greater in the UCLP group ( $P < .05$ ; Table 2).

### Soft Tissue Change

The soft tissue profile improved significantly along with an increase of the skeletal profile convexity in the two groups ( $P < .01$ ), and no significant difference in the changes (angle S-Ns-Sn, S-Ns-Bs, and Sn-Ns-Bs) were found between the two groups ( $P > .05$ ). The relationship of the upper and lower lip expressed by the distance LL-UL (EP) showed that the change in the UCLP group was less than in noncleft group ( $P = .048$ ). No significant change of the upper lip thickness (UL-U1) occurred ( $P > .05$ ), and a significant increase ( $P < .01$ ) was found in the lower lip (LL-L1) in the UCLP group. A significant decrease of the thickness ( $P < .05$ ) occurred in the upper lip (UL-U1), and no significant change of thickness ( $P > .05$ ) was found in the lower lip (LL-L1) in the noncleft group (Table 2).

## DISCUSSION

### About the Method

Many factors may affect the outcome of maxillary protraction. To decrease the sex difference, only male

patients were included in the study. An ANB angle between  $-4^\circ$  and  $0^\circ$  indicated that the skeletal deformity of the patient was mild to moderate. A study evaluating skeletal maturity as an indicator for the time of maxillary protraction showed that treatment effects could be more pronounced in younger patients.<sup>15</sup> Thus, not only the chronological age but also the skeletal age were taken into account in the study. The skeletal age during SMI 1-3 showed that all patients were before puberty in the two groups. Conditions for protraction therapy, such as type of intraoral appliance, timing of treatment, force duration, magnitude, direction, and sites of appliance, can affect the outcome.<sup>16</sup> Thus, the treatment was similar in the two groups in this study.

Not only was the cephalometric analysis based on conditional values, but a stable cranial reference system was appropriate for the longitudinal evaluation of skeletal changes. The structures of the cranial base, such as the contour of the anterior wall of the sella turcica, the anterior contours of the middle cranial fossae, and the contour of the cribriform plate and the bilateral fronto-etmoidal, were proven to be stable by Bjork et al.<sup>12</sup> Point T was proven to be a stable point by Bjork et al.<sup>12</sup> and Viazis.<sup>13</sup> The elimination of the S-N line as a reference line implied the exclusion of nasion from the analysis.



### Dentofacial Morphology Before Treatment Between the UCLP and Noncleft Groups

Although the intermaxillary relationships in both the UCLP and the noncleft groups were similar before the treatment, the maxilla was more retrognathic and mandible less prominent in the UCLP group. The negative overjet was larger in the UCLP group than in the noncleft group because of the more upright upper incisor in the UCLP group. A more retrusive nose and upper lip in the UCLP group showed a more concave profile and a worse lip relationship. These characteristics of the UCLP group were in agreement with the report by Semb.<sup>1</sup>

### Maxillary Changes After Protraction

The amount of maxillary advancement is important to evaluate the effects of maxillary protraction. After protraction, the upper jaws moved forward and the length increased in two groups. The mean value of SNA increased  $1.50^\circ$  and A-TFH increased 2.34 mm in the UCLP group. The maxillary changes in the UCLP group were in accordance with the findings of other studies.<sup>4,17</sup> SNA increased  $1.42^\circ$  and A-TFH increased 2.12 mm in the noncleft group. The change of maxilla in the noncleft group was similar to reports in which the amount of maxillary forward movement was about 2 mm in late mixed dentition.<sup>6-8,15,18,19</sup> No statistically significant difference in the sagittal change of maxilla between the two groups was found ( $P > .05$ ). This indicated that the reaction of the hard tissue to maxillary protraction in mild or moderate skeletal III malocclusion of the UCLP patients before puberty was similar to that of the noncleft patients. The result was not in agreement with the study of Sarnas and Rune,<sup>9</sup> in which the angle SNA increase was a mean of  $0.2^\circ$  in seven CLP cases (aged 6–9 years) and  $1.0^\circ$  in 10 noncleft cases (aged 8–13 years). The result was in agreement with the study of Jia et al.<sup>10</sup> The variation may be attributable to differences in severity of the skeletal discrepancy, differences in face types, and heterogeneous and small samples.

### Changes in the Intermaxillary Relationship After Protraction in the Two Groups

The study pertaining to the maxillary protraction therapy of cleft lip and palate patients showed that the result was limited to a downward and backward rotation of the mandible<sup>2-4</sup> and secondarily to anterior maxillary repositioning.<sup>5</sup> The present data support the studies that show an increase of the mandibular plane angle and N-Me and a decrease of Pg-TFH. The study showed that the differential effects of face mask therapy in UCLP patients as opposed to noncleft patients

resulted from a significant downward and backward rotation of the mandible but not forward movement of the maxilla. Contraction of the repaired upper lip and palate might prevent forward movement of the maxilla by face mask and maxillary expansion, resulting in enhanced clockwise rotation of the mandible. Mandibular rotation may be due to a combination of vertical maxillary movement, eruption of the molar, and a retraction force on the chin.

There was no significant difference in the changes of vertical maxillary movement (PNS-FH) and height of the lower first molar (L6-MP) between the two groups, except for the position of the molars (U6-FH). Thus, the increased mandibular downward and backward rotation in the UCLP group after treatment may be caused by more upper first molar extrusion (U6-FH;  $P < .05$ ). The maxilla in the operated cleft palate and lip patient is deficient not only in anteroposterior and lateral growth but also in vertical growth.<sup>20</sup> The vertical growth of the dentoalveolar structures was disturbed by the scar adjacent to the alveolar process, with the vertical discrepancy of the face accentuated.

The freeway space was markedly increased in the UCLP subjects when compared with noncleft subjects.<sup>21,22</sup> There was a negative correlation between the freeway space and the maxillary height.<sup>22</sup> Reduced face height, overclosure of the jaws, and an accentuated concave profile are characteristics frequently observed in cleft patients when the teeth are occluded. The greater extrusion of the upper molars and the greater clockwise rotation of the mandible may be compensatory for the maxillary vertical growth discrepancy in the UCLP patient. This favored the improvement of the intermaxillary relationship and facial esthetics in the cleft lip and palate patients.

### Comparison of Soft Tissue Changes

In this study, many soft tissue changes such as forward movement of the upper lip and retraction of the lower lip, accompanied by backward movement of soft tissue pogonion and downward movement of mentum, contributed to the soft tissue profile improvement in the patients of both groups. The result was similar to the other reports.<sup>14,23-25</sup>

There was a significant difference in the changes of the upper and lower lips between the two groups. The relationship of upper and lower lips was improved significantly in the two groups and especially more significantly in the noncleft group. A significant decrease occurred in the upper lip thickness in the noncleft group, while the distance did not change significantly in the UCLP group. The lower lip moved back relative to the E line, and the thickness did not change significantly in the noncleft group. Otherwise, the distance

from the lower lip to the E line did not change significantly, and the thickness of the lower lip increased in the UCLP group.

Many studies have reported that not only anterior teeth but also other variables, such as initial lip strain, muscle tonicity, and lip thickness, strongly influence the form and position of the lips, especially in patients with cleft lip and palate.<sup>25,26</sup> Such factors may modify the soft tissue response to treatment-induced changes of the underlying hard tissue structures. In the UCLP group, the LL-EP distance showed little change in the UCLP group. This was in accordance with the study by Tindlund and Rygh.<sup>24</sup> The soft tissues of the upper lip are short and posteriorly displaced. These patients constantly strain to obtain bilabial closure, resulting in hypertrophy of the lower lip musculature. The typical deformity was a hypertrophied, superiorly displaced, and forward rotated lower lip.<sup>27</sup> Correction of hard tissue did not completely ameliorate the soft tissue component of the cleft lip lower lip deformity in the UCLP group. Perhaps the lower lip in the UCLP group could fit the hard tissue changes over a longer time, or the abnormal lip form should be corrected by secondary operations in the lower lip. In the noncleft group, the lower lip moved backward following retraction of the lower incisors. The thickness of the lower lip did not change significantly, which might have resulted from normal lip strain and muscle tonicity.

## CONCLUSIONS

- The amount of maxillary anterior movement in the operated UCLP patients was similar to that of the noncleft patients after maxillary protraction performed before puberty.
- The intermaxillary relationship was improved significantly by maxillary protraction in the operated UCLP and noncleft patients. The amount of clockwise mandibular rotation in the operated UCLP patients was larger than in the noncleft patients.
- The soft tissue profile was improved significantly in the operated UCLP and noncleft patients. The amount of lower lip retrusion was significantly less in the operated UCLP patients.

## REFERENCES

1. Semb G. A study of facial growth in patients with unilateral cleft lip and palate treated by Oslo CLP team. *Cleft Palate Craniofac J.* 1991;28:1–21.
2. Tindlund RS, Rygh P, Bøe OE. Orthopedic protraction of the upper jaw in cleft lip and palate patients during the deciduous and mixed dentition periods in comparison with normal growth and development. *Cleft Palate Craniofac J.* 1993;30:182–194.
3. Tindlund RS. Skeletal response to maxillary protraction in patients with cleft lip and palate before 10 years. *Cleft Palate Craniofac J.* 1994;31:295–308.
4. Tindlund RS, Rygh P. Maxillary protraction: different effects on facial morphology in unilateral and bilateral cleft lip and palate patients. *Cleft Palate Craniofac J.* 1993;30:208–221.
5. Buschang PH, Porter C, Genecov E, Genecov D, Saylor KE. Face mask therapy of preadolescents with unilateral cleft lip and palate. *Angle Orthod.* 1994;64:145–150.
6. Westwood PV, McNamara JA Jr, Baccetti T, Franchi L, Sarver DM. Long-term effects of Class III treatment with rapid maxillary expansion and facemask therapy followed by fixed appliances. *Am J Orthod Dentofacial Orthop.* 2003;123:306–320.
7. Ngan P, Yiu C, Hu A, Hägg U, Wei SH, Gunel E. Cephalometric and occlusal changes following maxillary expansion and protraction. *Eur J Orthod.* 1998;20:237–254.
8. Vaughn GA, Mason B, Moon HB, Turley PK. The effects of maxillary protraction therapy with or without rapid palatal expansion: a prospective, randomized clinical trial. *Am J Orthod Dentofacial Orthop.* 2005;128:299–309.
9. Sarnas KV, Rune B. Extraoral traction to the maxilla with face mask: a follow-up of 17 consecutively treated patients with and without cleft lip and palate. *Cleft Palate J.* 1987;24:95–103.
10. Jia HC, Li WR, Lin JX. Effect of maxillary protraction in patients with unilateral cleft lip and palate and anterior cross-bite. *Zhonghua Kou Qiang Yi Xue Za Zhi.* 2006;41:723–727.
11. Fishman LS. Radiographic evaluation of skeletal maturation: a clinically oriented method based on hand-wrist films. *Angle Orthod.* 1982;52:88–112.
12. Bjork A, Skieller V. Normal and abnormal growth of the mandible: a synthesis of longitudinal cephalometric implant studies over a period of 25 years. *Eur J Orthod.* 1983;5:1–46.
13. Viazis AD. The cranial base triangle. *J Clin Orthod.* 1991;25:565–570.
14. Ngan P, Hägg U, Yiu C, Merwin D, Wei SH. Soft tissue and dentoskeletal profile changes associated with maxillary expansion and protraction headgear treatment. *Am J Orthod Dentofacial Orthop.* 1996;109:38–49.
15. Suda N, Ishii-Suzuki M, Hirose K, Hiyama S, Suzuki S, Kuroda T. Effective treatment plan for maxillary protraction—is the bone age useful to determine the treatment plan? *Am J Orthod Dentofacial Orthop.* 2000;118:55–62.
16. Kim JH, Viana MG, Graber TM. The effectiveness of protraction face mask therapy: a meta-analysis. *Am J Orthod Dentofacial Orthop.* 1999;115:675–685.
17. Chen KF, So LL. Sagittal skeletal and dental changes of reverse headgear treatment in Chinese boys with complete unilateral cleft lip and palate. *Angle Orthod.* 1996;66:363–372.
18. Kapust AJ, Sinclair PM, Turley PK. Cephalometric effects of face mask/expansion therapy in Class III children: a comparison of three age groups. *Am J Orthod Dentofacial Orthop.* 1998;113:204–212.
19. Baccetti T, McGill JS, Franchi L, McNamara JA Jr, Tollaro I. Skeletal effects of early treatment of Class III malocclusion with maxillary expansion and face-mask therapy. *Am J Orthod Dentofacial Orthop.* 1998;113:333–343.
20. Ross RB. The clinical implication of facial growth in cleft lip and palate. *Cleft Palate J.* 1970;7:37–47.
21. Graber TM. A cephalometric analysis of the developmental pattern and facial morphology in cleft palate. *Angle Orthod.* 1949;19:91–100.
22. Kanegae H. Changes in maxillofacial structure and mandibular rest position following the maxillary lateral expansion in unilateral cleft lip and cleft palate patients. *Nippon Kyosei Shika Gakkai Zasshi.* 1988;47:621–645.
23. Kilicoglu H, Kirlic Y. Profile changes in patients with Class

- III malocclusion after Delaire mask therapy. *Am J Orthod Dentofacial Orthop.* 1998;113:453–462.
24. Tindlund RS, Rygh P. Soft tissue profile changes during widening and protraction of the maxilla in patients with cleft and palate compared with normal growth and development. *Cleft Palate Craniofac J.* 1993;30:454–468.
25. Chen KF, So LL. Soft tissue profile changes of reverse headgear treatment in Chinese boys with complete unilateral cleft lip and palate. *Angle Orthod.* 1997;67:31–38.
26. Oliver BM. The influence of lip thickness and strain on upper lip response to incisor retraction. *Am J Orthod.* 1982;82:141–149.
27. Pensler JM, Mulliken JB. The cleft lip lower-lip deformity. *Plast and Reconstr Surg.* 1988;82:602–610.