

Change in Grafted Secondary Alveolar Bone in Patients with UCLP and UCLA

A Three-Dimensional Computed Tomography Study

Kyu-Ry Kim^a; Sukwha Kim^b; Seung-Hak Baek^c

ABSTRACT

Objective: To evaluate changes in the grafted bone after secondary alveolar bone graft (ABG) with iliac bone using 3-dimensional computed tomography (3D-CT).

Materials and Methods: The sample consisted of 10 patients with unilateral cleft lip and palate (UCLP) and 5 patients with unilateral cleft lip and alveolus (UCLA) (mean age = 10 years). 3D-CT data (Sensation 10, Siemens, Munchen, Germany), which was obtained 1 month before (T0), 3 months after (T1), and 12 months (T2) after ABG, were used to measure the height, labiolingual thickness (LLT), and volume of the grafted bone using V-Works 4.0 program (Cybermed Inc, Seoul, Korea). All of the UCLA patients showed the lingual process in the cleft area at T0, but the UCLP did not.

Results: During T1–T2, there was a significant decrease in height of the upper part of the grafted bone; however, volumes of both the upper and lower parts were decreased. Unilateral cleft type and presence of ULI in the cleft area did not affect the change in height and volume of the grafted bone. The resorption amount (RA) was significantly larger in the lower part than in the upper part, while the resorption rate (RR) exhibited an opposite result. In addition, there was significantly more RA in the labial side in UCLA than UCLP ($P < .05$). There was no correlation between the initial cleft width and changes in height, LLT, and volume of the grafted bone.

Conclusion: Overpacking and/or excessive condensation of the grafted bone is not necessary in UCLA with the lingual process because of the greater chance of resorption on the labial side of the grafted bone.

KEY WORDS: Alveolar bone graft; 3D-CT; Height; Labiolingual thickness; Volume

INTRODUCTION

The alveolar bone graft (ABG) is an essential procedure in the overall management of patients with cleft bony defect. The objectives of ABG are to stabilize the upper dental arch, to give a bony support for the teeth

adjacent to the cleft area, to support the lip and the nose, and to close the residual oronasal fistula.^{1,2}

Although a number of treatment protocols have been established for ABG according to donor site and surgical timing,^{3–5} early secondary ABG with the particulate cancellous bone and marrow (PCBM) from the anterior crest of the iliac bone (ACI) is preferable because of the abundant amount of bone material and good bone induction ability,⁶ and it is known not to induce the iatrogenic effects on the maxillary growth.^{2,7} However, it has been reported to have various success rates, ranging from partial improvement to complete correction.^{1,2,7}

The vertical levels of the cleft bony defect and the grafted bone at the site of ABG have been evaluated traditionally by 2-dimensional (2D) radiograph, such as periapical, occlusal, and panoramic radiographs.^{2,6–9} However, the inability to assess the volume, labiolingual morphology, density, and architecture of the grafted bone are main disadvantages inherent to this meth-

^a Resident, Department of Orthodontics, School of Dentistry, Seoul National University, Seoul, South Korea.

^b Professor, Department of Plastic Surgery, College of Medicine, Seoul National University, Seoul, South Korea.

^c Associate Professor, Department of Orthodontics, School of Dentistry, Dental Research Institute, Seoul National University, Seoul, South Korea.

Corresponding author: Dr Seung-Hak Baek, Department of Orthodontics, School of Dentistry, Dental Research Institute, Seoul National University, Yeonkum-dong #28, Jongro-ku, Seoul, South Korea 110-768, South Korea
(e-mail: drwhite@unitel.co.kr)

Accepted: September 2007. Submitted: July 2007.

© 2008 by The EH Angle Education and Research Foundation, Inc.

Table 1. Demographic data^a

	UCLA (n = 5)	UCLP (n = 10)	Total (n = 15)
Gender			
Male	3	8	11
Female	2	2	4
Subtotal	5	10	15
Upper lateral incisor			
Absence	3	8	11
Presence	2	2	4
Subtotal	5	10	15
Lingual process ^b			
Absence	0	10	10
Presence	5	0	5
Subtotal	5	10	15

^a UCLA indicates unilateral cleft lip and alveolus; UCLP, unilateral cleft lip and palate.

^b The lingual process is a process that is present in the lingual side of the cleft bony defect (see Figure 1).

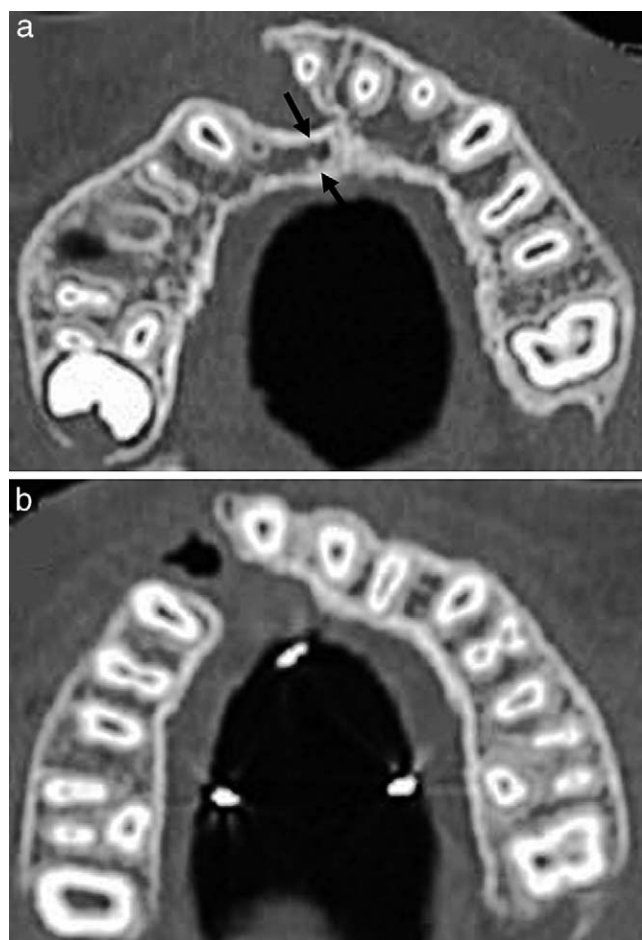


Figure 1. Cases with presence (A) and absence (B) of the lingual process in the cleft area. Black arrow indicates the lingual process.

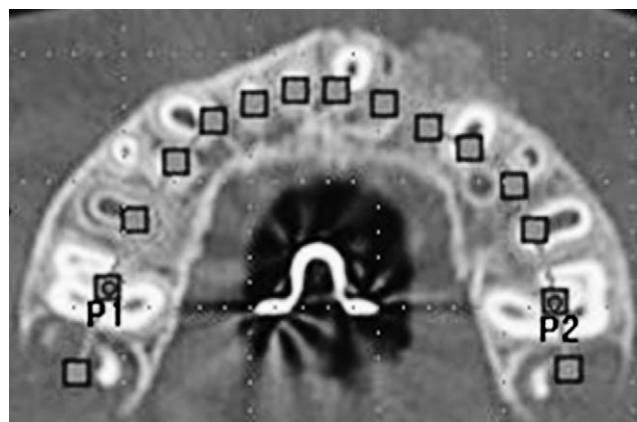


Figure 2. Construction of the labiolingual midpoints in the alveolar bone in plane 1.

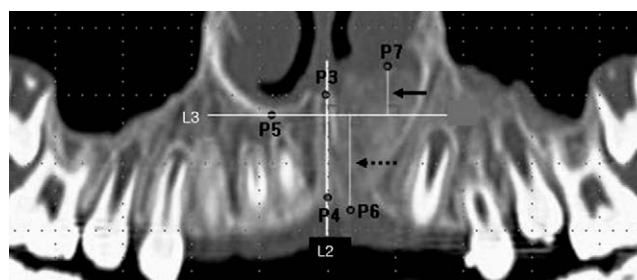


Figure 3. Measurements of the height of the grafted bone at 3 months (T1) and 12 months (T2) after alveolar bone graft. The solid line arrow indicates the upper height and the dotted line arrow indicates the lower height.

od. In addition, it is difficult to investigate change in the aforementioned variables because of limited reproducibility before and after ABG.

Recently, 3-dimensional computed tomography (3D-CT) has been used for clinical evaluation and follow-up assessment of ABG using linear measurements in various planes and volumetric analysis.^{2,6,10-16} Compared with 2D conventional radiography, 3D-CT offers better accuracy and improved quality of image without superimposition of the anatomic structure. For individual treatment planning, 2-D images were not reliable in all cases. Therefore, to overcome the disadvantages of reproducibility in 2D analysis of ABG, it is essential to use 3D-CT analysis with the proper reference points, lines, and planes.

Because a number of factors are involved with the success or failure of ABG, a prospective study is needed to remove surgeon-related, surgical timing-related, donor site-related, and cleft type-related biases. Most previous studies^{12,14-16} using 3D-CT have simply compared postoperative grafted bone volume with the preoperative alveolar bony defect. In addition, there have been few studies concerning 3-D changes of height and labiolingual thickness in the cleft bony defect and the grafted bone using 3D-CT.

Table 2. Definition of reference points, lines, planes, and measurement variables

Reference Point	Definition
P1	The midpoint of the trifurcation area of the upper right first molar
P2	The midpoint of the trifurcation area of the upper left first molar
P3	The upper midpalatal suture point
P4	The lower midpalatal suture point
P5	The lowest point in the inferior floor of the nasal cavity in the noncleft area
P6	The lowermost point of the grafted bone in relation to L3
P7	The uppermost point of the grafted bone in relation to L3
P8	The most protrusive point in the distal half of the labial cortical plate in the upper central incisor of the cleft side
P9	The most protrusive point in the mesial half of the labial cortical plate in the upper canine of the cleft side
P10	The most convex point in the labial margin of the grafted bone
P11	The most convex point in the lingual margin of the grafted bone
P12	The midpoint of the apex area of the upper right first molar
P13	The midpoint of the apex area of the upper left first molar
Plane 1	The slice of the axial view that included P1 and P2 and parallel to the maxillary occlusal plane
Plane 2	The slice of the axial view that included P12 and P13 and parallel to the maxillary occlusal plane
L1	The line connecting the labiolingual midpoints of the alveolar bone from the upper right second molar area to the left one
L2	The midpalatal suture line that connected P3 to P4
L3	The horizontal reference line perpendicular to L2 and passing P5
L4	The connection line between P1 and P2
L5	The labial side reference line that connected P8 to P9
L6	The line that was a tangent to the greater segment and perpendicular to L5
L7	The line that was a tangent to the lesser segment and perpendicular to L5
Upper height	The distance from P7 to L3 (mm)
Lower height	The distance from P6 to L3 (mm)
Labial thickness	The distance from P10 to L5 (mm)
Lingual thickness	The distance from P11 to L5 (mm)
Total volume	The volume of alveolar bony defect or grafted bone (mm ³)
Upper volume	The volume of alveolar bony defect or grafted bone above L3 (mm ³)
Lower volume	The volume of alveolar bony defect or grafted bone below L3 (mm ³)
Resorption amount	variables at T2 – variables at T1
Resorption rate	(variables at T1 – variables at T2)/variables at T1

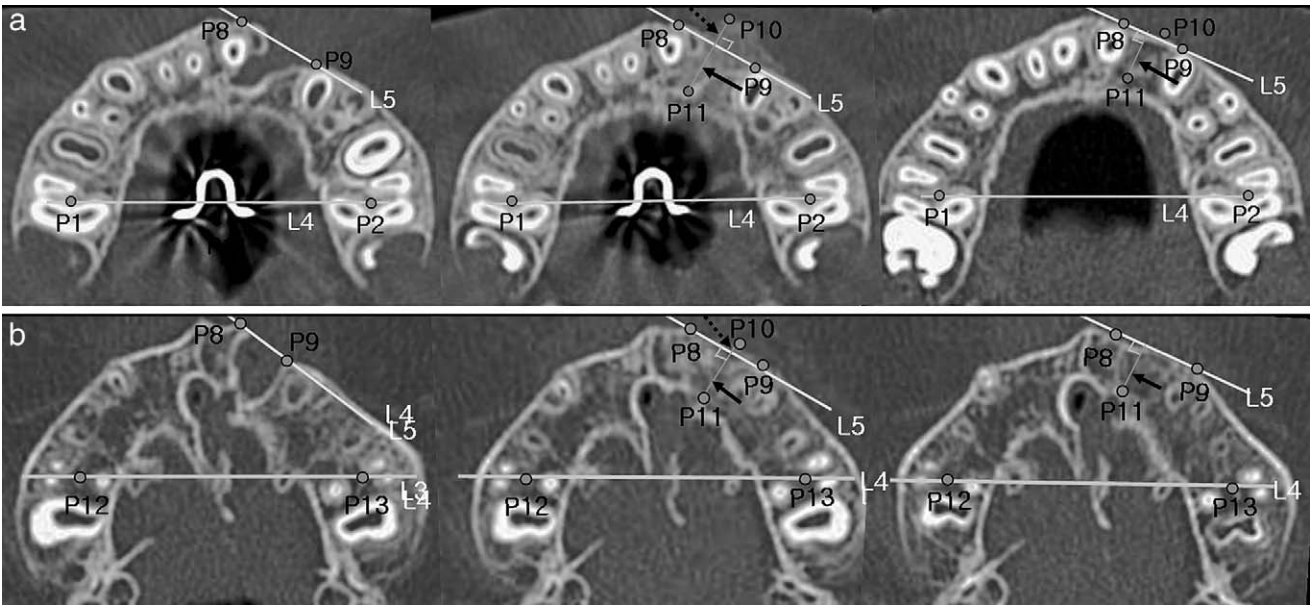


Figure 4. Measurement of the labiolingual thickness of the grafted bone in plane 1 (A) and plane 2 (B) at 1 month before (T0), 3 months after (T1), and 12 months after (T2) alveolar bone graft. The solid line arrow indicates the lingual thickness and the dotted line arrow, the labial thickness.

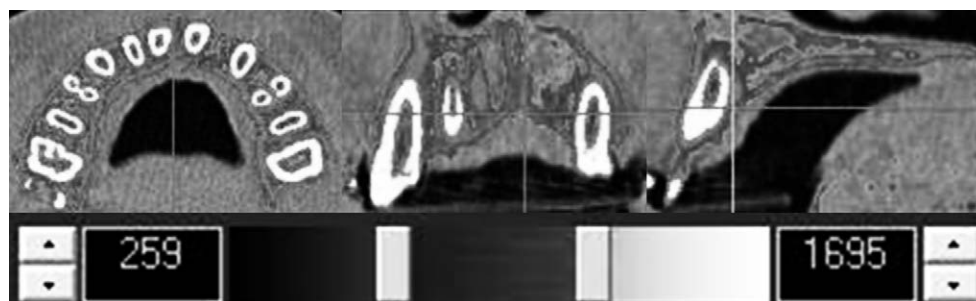


Figure 5. Example of a density display with different color using V-Works 4.0 program (Cybermed Inc, Seoul, Korea).

The purposes of this prospective study were to evaluate the outcome and follow-up of early secondary ABG with PCBM from ACI in unilateral cleft lip and alveolus (UCLA) and unilateral cleft lip and palate (UCLP) by estimating the change of height, labiolingual thickness, and volumes using 3D-CT and to investigate the factors affecting the results of ABG.

MATERIALS AND METHODS

Inclusion and exclusion criteria of the sample in this study were as follows. Patients with UCLA or UCLP were included, but patients with bilateral cleft lip and palate (BCLP) were excluded because they had a wide range in severity of the cleft on both sides, and it was impossible to compare cleft areas with noncleft ones. None of the subjects had other known syndromes. After presurgical expansion of the upper arch had been carried out with a removable expansion appliance, the upper arch was stabilized by a 0.9-mm lingual arch of stainless steel wire 1 or 2 weeks before ABG and were removed 3 months after ABG. All of the subjects received the early secondary ABG with PCBM taken from the ACI to eliminate biases related to surgical timing and donor site. Procedures were done by one surgeon with experience in the field of cleft surgery to exclude surgeon-related biases.

The sample consisted of 10 UCLP patients and 5 UCLA patients (11 males and 4 females; mean age = 10 years) (Table 1). No patient dropped out from the treatment protocol. The upper lateral incisor in the cleft area existed in 4 patients (Table 1). The lingual process in the cleft bony defect was present all UCLA patients (Table 1, Figure 1A); However, not all UCLP patients had the lingual process (Table 1, Figure 1B).

3D-CT (Sensation 10, Siemens, Munchen, Germany) was used to evaluate the height, labiolingual thickness, and volume of the cleft bony defect and the grafted bone. Scans were obtained 1 month before (T0), 3 months after (T1), and 12 months after ABG (T2) because the volume of the grafted bone tended to decrease between 3 and 12 months.¹² CT scans were taken with the axial plane parallel to the maxillary

occlusal plane and with a 0.75-mm slice thickness from the nasal cavity to the maxillary occlusal plane. The obtained axial data were processed and transformed into 3D views using V-Works 4.0 program (Cybermed Inc, Seoul, Korea).

Height

The height is shown in Figures 2 and 3 and Table 2. In Plane 1, the labiolingual midpoints of the alveolar bone were subsequently constructed from the right upper second molar area to the left one to make Line 1 (L1). In the panoramic view based on L1, the vertical reference line (L2) and the horizontal reference line (L3) were drawn. The lower height was measured from the lowermost point (P6) to L3 and the upper height was measured from the uppermost point (P7) to L3.

Labiolingual Thickness

The labiolingual thickness is shown in Figure 4 and Table 2. In Plane 1, the posterior reference line (L4) and the labial side reference line (L5) were drawn. The labial and lingual thicknesses were measured from the labial point (P10) to L5 and from the lingual point (P11) to L5, respectively. The labial and lingual thicknesses in the higher axial section (Plane 2) were measured using the same method.

Volume

Volume is shown in Figures 5 and 6 and Table 2. The areas with different density could be displayed with different colors using V-Works 4.0 program (Cybermed Inc, Seoul, Korea). At T0, the cleft bony defect area could be demarcated according to difference in density and consideration of the alveolar bone outline of the noncleft site. At T1 and T2, the grafted bone area could be defined according to different density.¹⁵ The volume was calculated by V-works 4.0 program after demarcation of the area in the axial (Figure 6A), coronal (Figure 6B), and sagittal planes (Figure 6C) in 3D data. Axial planes were parallel to the maxillary occlusal plane and measured with 0.75-mm slice thick-

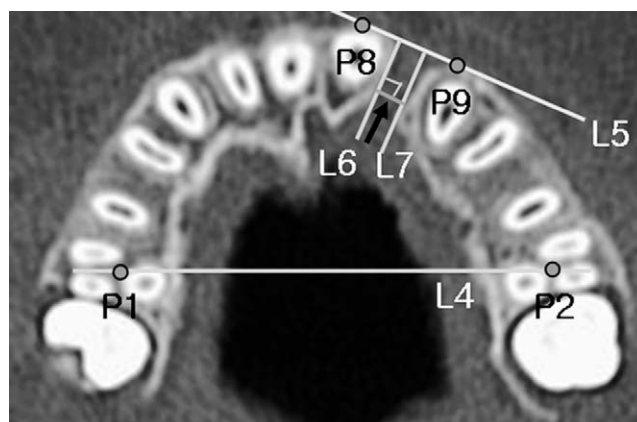
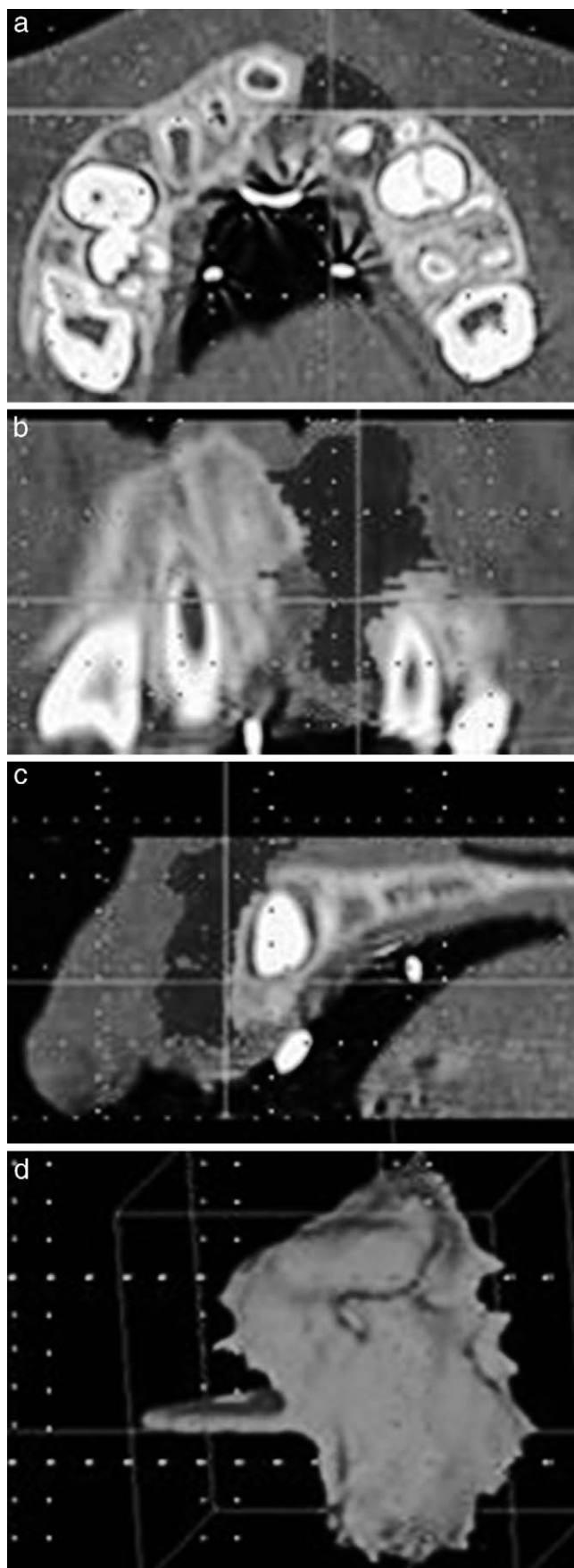


Figure 7. Measurement of the mesio-distal width (arrow) in plane 1 at 1 month before (T0) alveolar bone graft.

ness from the nasal cavity to the maxillary occlusal plane. The total volume (Figure 6D) was divided into the upper and lower sections relative to L3.

Initial mesio-distal width

The initial mesio-distal width is shown in Figure 7 and Table 2. At T0, the initial mesio-distal width of the cleft bony defect was measured as the shortest distance between lines of the greater (L6) and lesser (L7) segments at plane 1 (Mean = 3.24 mm; SD = 1.80 mm).

Measurements were taken by a single operator. All of the variables of the 5 patients were reassessed again after 4 weeks by the same operator to evaluate intraoperator variability and by another operator to evaluate interoperator variability. Wilcoxon signed rank test demonstrated that there was no statistically significant difference in intraoperator and interoperator measures, respectively (both $P > .05$). For statistical analyses, the Mann-Whitney test, Wilcoxon signed rank test, and linear regression analysis were used.

RESULTS

Vertical Height

There was no significant difference in upper and lower heights at T1 and T2 and at resorption amount (RA) between UCLA and UCLP patients, respectively (Table 3). However, the upper height of the grafted bone was significantly decreased from T1 to T2 compared with the lower height in UCLP patients and the total sample ($P < .01$, Table 3).

←

Figure 6. Measurements of the grafted bone volume using V-Works 4.0 program (Cybermed Inc) in the axial (A), coronal (B,) and sagittal planes (C).

Table 3. Comparison of the grafted bone height between UCLA and UCLP patients and between upper part and lower parts^a

Height (mm)	UCLA (n = 5)		UCLP (n = 10)		Sig	Total (n = 15)	
	Mean	SD	Mean	SD		Mean	SD
Upper part							
T1	2.66	2.80	3.70*	4.75	NS	3.35**	4.12
T2	−0.72	6.10	1.78*	6.44	NS	0.95**	6.22
T2 − T1	−3.38	4.38	−1.92**	2.33	NS	−2.41**	3.08
Lower part							
T1	13.46	4.78	11.30	5.23	NS	12.02	5.02
T2	14.22	4.54	12.39	5.43	NS	13.00	5.07
T2 − T1	0.76	1.30	1.09	2.10	NS	+0.98	1.83

^a Mann-Whitney test was performed to compare the grafted bone height between UCLA and UCLP patients, and Wilcoxon signed rank test was performed to compare the grafted bone height between upper and lower parts. UCLA indicates unilateral cleft lip and alveolus; UCLP, unilateral cleft lip and palate; T2 - T1, resorption amount (RA); (+), increase of height; (-), decrease of height; Sig, significance; NS, not statistically significant.

* Statistically significant difference between upper and lower parts ($P < .05$).

** Statistically significant difference between upper and lower parts ($P < .01$).

Table 4. Comparison of the grafted bone height according to presence or absence of the upper lateral incisor in the cleft area^a

Height (mm)	Upper Lateral Incisor				Sig
	Presence (n = 4)		Absence (n = 11)		
	Mean	SD	Mean	SD	
Upper part					
T1	4.38	4.85	2.98**	4.02	NS
T2	2.55	4.49	0.36**	6.84	NS
T2 – T1	–1.83	1.45	–2.62**	3.53	NS
Lower part					
T1	9.83	1.94	12.82	5.61	NS
T2	10.80	3.08	13.80	5.52	NS
T2 – T1	0.98	1.91	0.98	1.90	NS

^a Mann-Whitney test was performed to compare the grafted bone height between UCLA and UCLP patients, and Wilcoxon signed rank test was performed to compare the grafted bone height between upper and lower parts. T1 indicates 3 months after alveolar bone graft; T2, 12 months after alveolar bone grafts; T2 - T1, resorption amount (RA); (+), increase of height; (-), decrease of height; Sig, significance; NS, not statistically significant.

** Statistically significant difference between upper and lower parts ($P < .01$).

The presence or absence of the upper lateral incisor (ULI) in the cleft area did not affect the height or RA of the upper and lower parts (Table 4). However, in the patients who did not have ULI, the upper height of the grafted bone was significantly decreased from T1 to T2 compared with the lower height ($P < .01$, Table 4).

Labiolingual Thickness

The labiolingual thickness (LLT) of the grafted bone tended to decrease in both labial and lingual sides during T1-T2. Although the grafted amount in the labial side was not different between UCLA and UCLP patients, there was more resorption of the labial side of

UCLA patients than UCLP ones in plane 2 ($P < .01$, Table 5). However, in the lingual side, the grafted amount and the resorption amount showed an opposite tendency even though there was no significant difference between UCLA and UCLP patients.

During T0-T1, in the total sample, changes of the lingual thickness were more in plane 2 than in plane 1 ($P < .05$, Table 5). However, there was no statistically significant difference in changes of the labial and the lingual thickness during T1-T2 between planes 1 and 2. These findings mean that the PCBM was grafted more in the higher level (plane 2) than the lower level (plane 1) during T0-T1 and remained relatively stable at both levels during T1-T2.

In patients in whom ULI was missing, the grafted bone amount of the lingual side in the cleft bony defect was significantly larger in plane 2 than plane 1 ($P < .01$, Table 6). Although there was no significant difference in changes of the LLT between the presence and absence of ULI in Planes 1 and 2, changes of LLT during T0-T1 and T1-T2 tended to be more in patients in whom ULI was missing (Table 6).

Volume

There was no significant difference in the amount (RA) and rate of resorption (RR) of the upper and lower parts of the grafted bone volume between UCLA and UCLP patients (Table 7). However, there was an opposite tendency in RA and RR between the upper and lower parts of the grafted bone volume. The absolute value, RA, was significantly larger in the lower part than in the upper ($P < .05$, Table 7) while the relative value, RR, was larger in the upper part than in the lower ($P < .01$, Table 7). And in UCLP patients, RR was significantly larger in the upper part than in the lower ($P < .01$, Table 7).

Table 5. Comparison of change in the labiolingual thickness of the grafted bone between UCLA and UCLP patients and between planes 1 and 2^a

Change in Labiolingual Thickness (mm)	UCLA (n = 5)		UCLP (n = 10)		Sig	Total (n = 15)	
	Mean	SD	Mean	SD		Mean	SD
Plane 1							
Labial thickness							
T1 – T0	9.46	4.45	10.38	5.37	NS	10.05	4.90
T2 – T1	–2.10	1.37	–0.81	2.27	NS	–1.27	2.04
Lingual thickness							
T1 – T0	8.03	2.65	7.41	4.22	NS	7.58*	3.73
T2 – T1	–0.90	0.46	–1.39	1.06	NS	–1.25	0.94
Plane 2							
Labial thickness							
T1 – T0	14.00	5.42	13.74	5.26	NS	13.81	5.31
T2 – T1	–2.16	1.29	–0.64	0.60	0.019**	–1.15	1.16
Lingual thickness							
T1 – T0	6.42	4.30	8.78	4.78	NS	9.30	4.09
T2 – T1	–0.92	0.86	–1.38	1.36	NS	–1.36	1.33

^a Mann-Whitney test was performed to compare the change in the labiolingual thickness of the grafted bone between UCLA and UCLP patients, and Wilcoxon signed rank test was performed to compare the change in the labiolingual thickness of the grafted bone between planes 1 and 2. UCLA indicates unilateral cleft lip and alveolus; UCLP, unilateral cleft lip and palate; T0, 1 month before alveolar bone graft; T1, 3 months after alveolar bone graft; T2, 12 months after alveolar bone grafts; T1 – T0, grafted amount; T2 – T1, resorption amount (RA); (+), increase of thickness; (–), decrease of thickness. Sig, significance; NS, not statistically significant.

* Statistically significant difference between planes 1 and 2 ($P < .05$).

** Statistically significant difference between UCLA and UCLP patients ($P < .01$).

Presence of the ULI in the cleft area did not affect RA and RR of the upper, lower, and total volume of the grafted bone (Table 8). However, in the patients with missing ULI, RA was significantly larger in the lower part than the upper ($P < .05$, Table 8) and RR was significantly smaller in the lower part than the upper ($P < .01$, Table 8).

Initial mesio-distal width

The initial mesio-distal width of the cleft bony defect did not show any correlation with the height, LLT, and volume of the grafted bone (Table 9).

DISCUSSION

Resorption of the grafted bone could occur because of excessive tension in the mucoperiosteal flap resulting in inadequate coverage in the early stage^{1,2} and absence of physiologic stress because of congenital missing ULI in the later stage.^{12,17} Because the alveolar bone can only exist when teeth are present, Kearns et al¹⁸ attempted to overcome the issue of missing teeth adjacent to the cleft by placing implants into the grafted area. Sufficient labiolingual thickness of the alveolar bone might be important for proper implant installation and normal eruption of the upper canine in the grafted bone areas. Arctander et al¹⁵ found that a longer interval between the bone graft and implant

placement was associated with a greater likelihood of alveolar bone resorption. The eruption path of the upper canine could be influenced by the amount of bone in the labiolingual direction and the presence of the ULI, which could guide the eruption path.

In the present study, the upper height of the grafted bone was significantly decreased compared with the lower height during T1–T2 ($P < .01$, Table 3). However, eruption of the upper canine during T1–T2 can introduce functional stress to the lower part of grafted bone and prevent resorption of the lower height in the grafted bone or can result in increased vertical growth of the alveolar bone.^{1,2,7,19} On the contrary, presence of ULI did not affect the upper and lower height of the grafted bone (Table 4) because ULI had a decreased bone-induction ability when it was almost erupted or already erupted at the bone graft stage.

Although Tai et al¹³ insisted that it was difficult to distinguish the grafted bone from the surrounding alveolar bone in volumetric analysis of cleft patients 1 year after surgery, the results of the present study indicated that it was clearly possible to discern between grafted and surrounding bone because there was a sharp difference of bone density between the grafted bone and the alveolar bone adjacent to the grafted bone until the T2 stage. Our findings were in accord with those of Arctander et al.¹⁵

There was an opposite tendency with respect to RA

Table 6. Comparison of change in the labiolingual thickness of the grafted bone according to the presence or absence of the upper lateral incisor in the cleft area^a

Change in Labiolingual Thickness (mm)	Upper Lateral Incisor				Sig
	Presence (n = 4)		Absence (n = 11)		
	Mean	SD	Mean	SD	
Plane 1					
Labial thickness					
T1 – T0	8.50	4.69	10.47	5.09	NS
T2 – T1	–3.30	1.51	–0.72	1.84	NS
Lingual thickness					
T1 – T0	6.45	6.43	7.83**	3.45	NS
T2 – T1	–0.40	0.57	–1.44	0.91	NS
Plane 2					
Labial thickness					
T1 – T0	11.95	5.35	14.51	5.12	NS
T2 – T1	–1.13	0.74	–1.15	1.26	NS
Lingual thickness					
T1 – T0	5.00	5.79	9.08	3.85	NS
T2 – T1	–0.93	1.07	–1.34	1.29	NS

^a Mann-Whitney test was performed to compare change in the labiolingual thickness of the grafted bone according to the presence or absence of the upper lateral incisor in the cleft area and Wilcoxon signed rank test was performed to compare change in the labiolingual thickness of the grafted bone between planes 1 and 2. T0 indicates 1 month before alveolar bone graft; T1, 3 months after alveolar bone graft; T2, 12 months after alveolar bone grafts; T1 – T0 means grafted amount; T2 – T1, resorption amount (RA); (+), increase of thickness; (–), decrease of thickness; Sig, significance; NS, not statistically significant.

** Statistically significant difference between planes 1 and 2 ($P < .01$).

and RR of the grafted bone volume between the upper and lower parts of the bone graft (Table 7). The reason for these results could be an opposite direction of resorption in grafted bone between the upper and lower parts, eruption of the upper lateral incisor or canine

Table 8. Comparison of change in the grafted bone volume according to presence or absence of the upper lateral incisor in the cleft area^a

Change in Volume (mm ³)	Upper Lateral Incisor				Sig
	Presence (n = 4)		Absence (n = 11)		
	Mean	SD	Mean	SD	
Upper part					
RA	−246.23	232.26	−140.40*	176.28	NS
RR	78.14	12.68	69.87**	24.44	NS
Lower part					
RA	−206.54	95.42	−337.67	318.97	NS
RR	36.22	13.76	45.56	23.53	NS

^a Mann-Whitney test was performed to compare change in the volume of the grafted bone according to the presence or absence of the upper lateral incisor in the cleft area and Wilcoxon signed rank test was performed to compare change in the grafted bone volume between upper and lower parts. RA indicates resorption amount (T2 – T1); RR, resorption rate $\{(T1 - T2)/T1\} \times 100$; (+), increase of volume; (–), decrease of volume; Sig, significance; NS, not statistically significant.

* Statistically significant difference between upper and lower parts ($P < .05$).

** Statistically significant difference between upper and lower parts ($P < .01$).

into or adjacent to the grafted bone, and effect of gravity on the grafted bone particle (PCBM) during healing.

In this study, unilateral cleft type (UCLA vs UCLP) and presence of ULI in the cleft area did not affect the change in height and volume of the grafted bone (Tables 3, 4, 7, and 8). However, the finding that more resorption of the grafted bone occurred in the UCLA patients than in the UCLP patients during T1–T2, in spite of similar amounts of grafted bone in plane 2 ($P < .05$, Table 5), means unilateral cleft type might affect the change in labiolingual thickness of the grafted bone. The lingual process in UCLA patients could play a role to support packing and/or condensation of the grafted bone. Therefore, the reason why there was

Table 7. Comparison of change in the grafted bone volume between UCLA and UCLP patients and between upper and lower parts^a

Change in Volume (mm ³)	UCLA (n = 5)		UCLP (n = 10)		Sig	Total (n = 15)	
	Mean	SD	Mean	SD		Mean	SD
Upper part							
RA	−157.71	232.42	−174.08	179.03	NS	−168.62*	190.01
RR	73.36	5.67	71.43**	26.90	NS	72.07**	21.80
Lower part							
RA	−483.40	432.96	−212.35	105.64	NS	−302.70	279.69
RR	50.08	24.85	39.56	19.78	NS	43.07	21.31

^a Mann-Whitney test was performed to compare change in the grafted bone volume between UCLA and UCLP patients, and Wilcoxon signed rank test was performed to compare change in the grafted bone volume between upper and lower parts. UCLA indicates unilateral cleft lip and alveolus; UCLP, unilateral cleft lip and palate; RA, resorption amount (T2 – T1); RR, resorption rate, $\{(T1 - T2)/T1\} \times 100$; (+), increase of volume; (–), decrease of volume; Sig, significance; NS, not statistically significant.

* Statistically significant difference between upper and lower parts ($P < .05$).

** Statistically significant difference between upper and lower parts ($P < .01$).

Table 9. Correlation between the initial mesio-distal width of the bony cleft defect and the amount and rate of resorption of the grafted bone^a

Model	Unstandardized Coefficients Beta	Standard Error	Standardized Coefficients Beta	Sig
RA of upper height				
(Constant)	-1.721	1.733		NS
Width	-0.211	0.471	-0.124	NS
RA of lower height				
(Constant)	1.483	1.026		NS
Width	-0.155	0.278	-0.153	NS
RA of labial thickness at plane 1				
(Constant)	-1.235	0.635		NS
Width	0.027	0.172	0.044	NS
RA of lingual thickness at plane 1				
(Constant)	-1.873	0.655		NS
Width	0.199	0.178	0.297	NS
RA of labial thickness at plane 2				
(Constant)	0.470	1.009		NS
Width	-0.542	0.274	-0.496	NS
RA of lingual thickness at plane 2				
(Constant)	-0.657	0.542		NS
Width	-0.194	0.152	-0.391	NS
RA of total volume				
(Constant)	343.702	210.075		NS
Width	28.942	57.022	0.139	NS
RR of total volume				
(Constant)	49.660	10.844		NS
Width	-0.102	2.943	-0.010	NS
RA of upper volume				
(Constant)	-135.429	107.211		NS
Width	-10.224	29.101	-0.097	NS
RR of upper volume				
(Constant)	60.847	11.845		NS
Width	3.458	3.215	0.286	NS
RA of lower volume				
(Constant)	-225.592	156.694		NS
Width	-23.751	42.532	-0.153	NS
RR of lower volume				
(Constant)	47.293	12.010		NS
Width	-1.301	3.260	-0.110	NS

^a Linear regression analysis was done. RA indicates resorption amount (T2 - T1); RR, resorption rate $\{(T1 - T2)/T1\} \times 100$; Sig, significance; NS, not significant.

more resorption in the labial thickness of the grafted bone of UCLA patients seems to be overpacking and/or excessive condensation of the grafted bone, which could result in a limited blood supply to the center area of the grafted bone.

In this study, initial cleft width did not show any significant correlation with the change of height, LLT, and volume of ABG in UCLA and UCLP patients (Table 9). It was in accord with other studies^{9,20} that reported that

presurgical cleft width had little or no impact on the success of ABG. Excessively large cleft width can affect the survival of osteoprogenitor cells in the center of the grafted area because revascularization is more likely to fail.^{9,21} Therefore, proper arch expansion before ABG could guarantee an easy surgical manipulation of the flap and, eventually, would not diminish the probability of ABG success. However, in aspects of variability of the mesio-distal width through the axial levels according to height, further study considering this point will be necessary.

Abyholm et al¹⁹ explained the poor ABG results in BCLP patients because of wide and large cleft bony defect and mobile premaxilla. Therefore, the reasons why there was no significant difference in changes of the height and volume of the bone graft between the UCLA and UCLP patients in this study might be the fact that this study did not include BCLP patients and that all UCLA and UCLP patients wore a lingual arch to stabilize the maxillary arch. The reason for removing the lingual arch at the T1 stage was that conventional orthodontic treatment usually started to align the maxillary anterior teeth at that time. To prevent constriction of the bone grafted area, a widened archwire and/or open coil spring was used in the maxillary arch.

The lack of significant findings could be attributable to the small size of samples and inherent variability. Therefore, further studies of an increased number of patients with a longer follow-up period will be necessary.

CONCLUSIONS

- Unilateral cleft type and presence of ULI in the cleft area did not affect the change in height and volume of the grafted bone.
- Initial mesio-distal width of the cleft bony defect was not correlated with change in the height, labiolingual thickness, and volume of the grafted bone in unilateral cleft patients.
- Overpacking and/or excessive condensation of the grafted bone would not be necessary in UCLA patients with the lingual process because of more likelihood of resorption in the labial side of the grafted bone.

REFERENCES

1. Enemark H, Krantz-Simonsen E, Schramm JE. Secondary bone grafting in unilateral cleft lip and palate patients. *Int J Oral Surg*. 1985;14:2-10.
2. Bergland O, Semb G, Abyholm F. Elimination of the residual alveolar cleft by secondary bone grafting and subsequent orthodontic treatment. *Cleft Palate J*. 1986;23:175-205.
3. Bahr W, Coulon JP. Limits of the mandibular symphysis as a donor site for bone grafts in early secondary cleft palate osteoplasty. *Int J Oral Maxillofac Surg*. 1996;25:389-393.

4. Freihofer HP, Borstlap WA, Kuijpers-Jagtman AM, Voorsmit RA, van Damme RA, Heidbüchel KL, Borstlap-Engels VM. Timing and transplant materials for closure of alveolar clefts. A clinical comparison of 296 cases. *J Craniomaxillofac Surg.* 1993;21:143–148.
5. Witsenburg B, Freihofer HPM. Autogenous rib graft for reconstruction of alveolar bone defects in cleft patients: long-term follow-up results. *J Craniomaxillofac Surg.* 1990;18:55–62.
6. Borstlap WA, Heidbüchel KLWM, Freihofer PM, Kuijpers-Jagtman AM. Early secondary bone grafting of alveolar cleft defects. *J Craniomaxillofac Surg.* 1990;18:201–205.
7. Enemark H, Sindet-Pedersen S, Bundgaard M. Long-term results after secondary bone grafting of alveolar clefts. *J Oral Maxillofac Surg.* 1987;45:913–919.
8. Kindelan JD, Nashed RR, Bromige MR. Radiographic assessment of secondary autogenous alveolar bone grafting in cleft lip and palate patients. *Cleft Palate Craniofac J.* 1997;34:195–198.
9. Long RE, Spangler BE, Yow M. Cleft width and secondary alveolar bone graft success. *Cleft Palate Craniofac J.* 1995;32:420–427.
10. Lee C, Crepeau RJ, Williams HB, Schwartz S. Alveolar cleft bone grafts: results and imprecisions of the dental radiograph. *Plast Reconstr Surg.* 1995;96:1534–1538.
11. Rosenstein SW, Long RE Jr, Dado DV, Vinson B, Alder ME. Comparison of 2-D calculations from periapical and occlusal radiographs versus 3-D calculations from CAT scans in determining bone support for cleft-adjacent teeth following early alveolar bone grafts. *Cleft Palate Craniofac J.* 1997;34:199–205.
12. Honma K, Kobayashi T, Nakajima T, Hayasi T. Computed tomographic evaluation of bone formation after secondary bone grafting of alveolar clefts. *J Oral Maxillofac Surg.* 1999;57:1209–1213.
13. Tai CC, Sutherland IS, McFadden L. Prospective analysis of secondary alveolar bone grafting using computed tomography. *J Oral Maxillofac Surg.* 2000;58:1241–1249.
14. Van der Meij AJ, Baart JA, Prah-Andersen B, Valk J, Kostense PJ, Tuinzing DB. Bone volume after secondary bone grafting in unilateral and bilateral clefts determined by computed tomography scans. *Oral Surg Oral Med Oral Pathol Oral Radiol Endod.* 2001;92:136–141.
15. Arctander K, Kolbenstvedt A, Aaløkken TM, Abyholm F, Frøslie KF. Computed tomography of alveolar bone grafts 20 years after repair of unilateral cleft lip and palate. *Scand J Plast Reconstr Surg Hand Surg.* 2005;39:11–14.
16. Feichtinger M, Mossbock R, Karcher H. Evaluation of bone volume following bone grafting in patients with unilateral clefts of lip, alveolus and palate using a CT-guided three-dimensional navigation system. *J Craniomaxillofac Surg.* 2006;34:144–149.
17. Schultze-Mosgau S, Nkenke E, Schlegel AK, Hirschfelder U, Wiltfang J. Analysis of bone resorption after secondary alveolar cleft bone grafts before and after canine eruption in connection with orthodontic gap closure or prosthodontic treatment. *J Oral Maxillofac Surg.* 2003;61:1245–1248.
18. Kearns GMB, Perrot DH, Sharma A, Kaban LB, Vargervik K. Placement of endosseous implants in grafted alveolar clefts. *Cleft Palate Craniofac J.* 1997;34:520–525.
19. Abyholm FE, Bergland O, Semb G. Secondary bone grafting of alveolar clefts. A surgical/orthodontic treatment enabling a non-prosthodontic rehabilitation in cleft lip and palate patients. *Scand J Plast Reconstr Surg.* 1981;15:127–140.
20. Van der Meij AW, Baart JA, Prah-Andersen B, Kostense PJ, van der Sijp JR, Tuinzing DB. Outcome of bone grafting in relation to cleft width in unilateral cleft lip and palate patients. *Oral Surg Oral Med Oral Pathol Oral Radio Endol.* 2003;96:19–25.
21. Keese E, Schmelzle R. New findings concerning early bone grafting procedures in patients with cleft lip and palate. *J Cranio Maxillofac Surg.* 1995;23:296–301.