

## **Maxillary Canine-First Premolar Transposition in the Permanent Dentition**

**Hasan Babacan<sup>a</sup>; Banu Kiliç<sup>b</sup>; Altuğ Bıçakçı<sup>a</sup>**

### **ABSTRACT**

Maxillary canine premolar transposition is the most frequently reported transposition type, which many orthodontists face. Although correcting the transposed tooth order is not advised after the eruption of the permanent tooth, several articles published in the last decade demonstrated nonextraction treatment of transposition using fixed mechanics. This article describes the nonextraction treatment of a complete transposition between a maxillary left canine and a first premolar, using similar mechanics as suggested earlier. The correct tooth order was established with a functional Class I canine and molar relationship at the end of treatment. Although triangular cortical bone resorption at the vestibule of the canine root was detected on computed tomography at the end of treatment, spontaneous regeneration of bone tissue at the resorption area was present on the postretention computed tomography scan.

**KEY WORDS:** Transposition; Permanent dentition; Computed tomography; Bone resorption

### **INTRODUCTION**

Tooth transposition is the positional interchange of two adjacent teeth, or the development or eruption of a tooth in a position occupied normally by a nonadjacent tooth.<sup>1</sup> Several theories such as a genetic origin, trauma, and interchange of the position of the developing tooth buds, lack of deciduous canine root resorption, early loss of primary teeth, and prolonged retention of primary teeth have been proposed to explain the phenomenon. A genetic origin, however, is reported as the main etiologic factor.<sup>1-5</sup>

Transposition occurs much more commonly in the maxilla than the mandible. Unilateral transposition is more common than bilateral transposition and the left side is more involved.<sup>6-8</sup> Among the many types of transpositions, maxillary canine-premolar transposition is clearly the most frequent type, so it has been the one most often reported.<sup>3,6-9</sup> It is called a complete transposition if both the crown and the entire root structure of the involved teeth are found parallel in their transposed position. It is called an incomplete

transposition if the transposition is of the crown, but not the root apex.<sup>6,7</sup>

In this article, a patient with a complete transposition of the maxillary canine and first premolar (MxC.P1) is reported and her treatment results are discussed.

### **Diagnosis and Etiology**

The clinical examination of a 12-year-old girl revealed an Angle Class II molar relationship in the permanent dentition with a complete transposition of the maxillary left canine and premolar. The facial analysis reflected a normal upper lip relationship, posture, and tonicity. The patient had a convex profile and a pleasant smile (Figure 1). Both the upper and lower dental midlines were shifted 1.5 mm to the right of the facial midline. Both of the maxillary lateral incisors were in crossbite with the mandibular incisors. The maxillary left premolars had erupted palatally. The left maxillary deciduous canine was present in the arch, and the left permanent canine was displaced facially and fully erupted to the buccal between the premolars. The first premolar was tipped distally and rotated mesiopalatally as described by Shapira and Kuftinec.<sup>7</sup> Since the anomaly was camouflaged by a functional deciduous canine, her chief complaint was crowding of the upper arch. A moderate mandibular arch length discrepancy was noted (Figure 2).

The panoramic radiograph showed that all permanent teeth, including the third molars, were present with unilateral complete transposition of the upper left canine with the first premolar (Figure 3). Computed

<sup>a</sup> Assistant Professor, Department of Orthodontics, University of Cumhuriyet, Sivas Turkey.

<sup>b</sup> Private practice, Kayseri, Türkiye.

Corresponding author: Dr Hasan Babacan, Cumhuriyet Üniversitesi, Dişhekimliği Fakültesi, Ortodonti AD, 58140 Sivas Türkiye (e-mail: babacanhasan@yahoo.com)

Accepted: October 2007. Submitted: September 2007.

© 2008 by The EH Angle Education and Research Foundation, Inc.

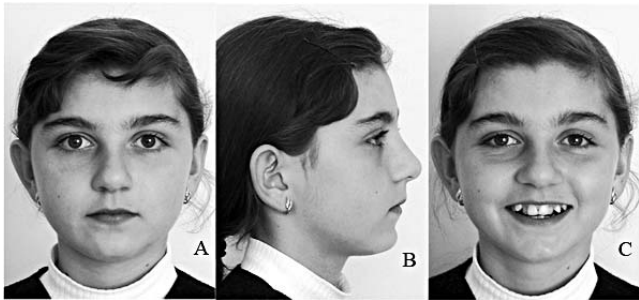


Figure 1A–C. Pretreatment facial photographs.

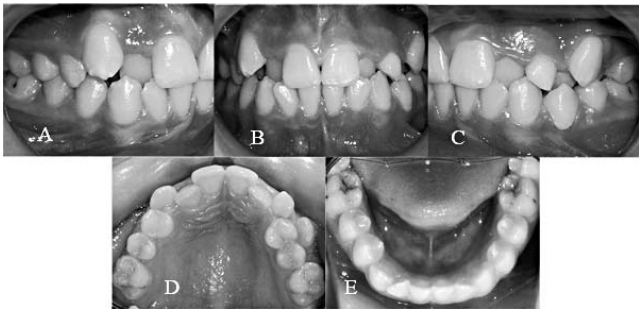


Figure 2A–E. Pretreatment intraoral photographs.

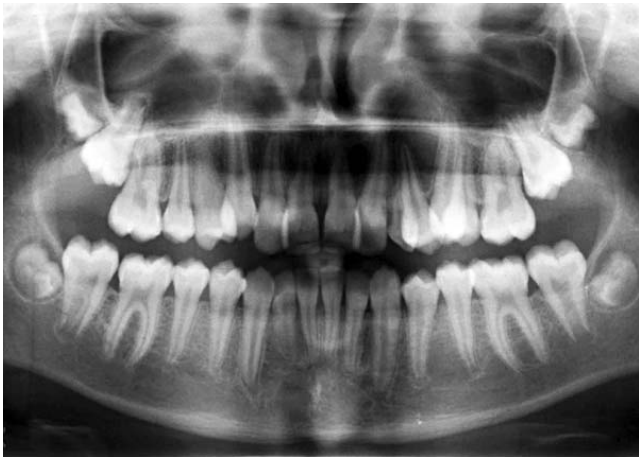

Figure 3. Pretreatment panoramic radiograph.

tomography (CT) scans were used to obtain more detailed information about the transposition. It showed that the canine root was between the left premolars (Figure 4).

Cephalometric analysis (Figure 5, Table 1) showed a Class II skeletal pattern with a mild mandibular arch length deficiency. The maxillary incisors were inclined palatally, and the mandibular incisors were proclined.

**Treatment Objectives**

- The treatment objectives were:
- Establishing a functional Class I molar and canine relationship without extractions;

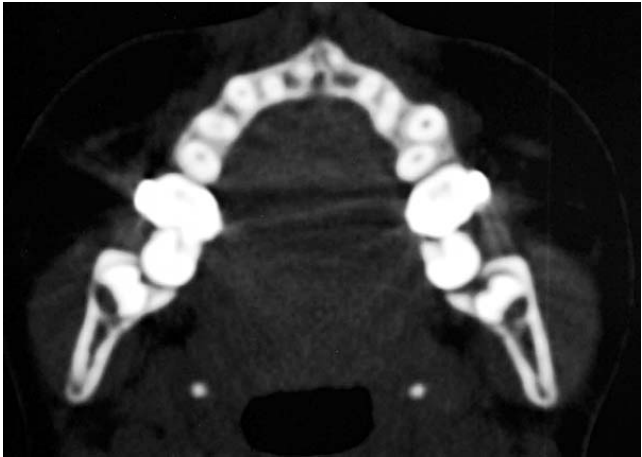


Figure 4. Pretreatment computed tomography scan.

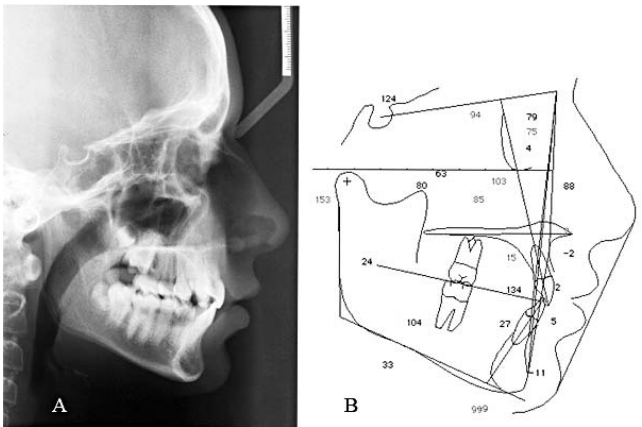


Figure 5A,B. Pretreatment cephalometric radiograph and tracing.

**Table 1.** Cephalometric Summary

Measurements	Initial	Normal	Final	Normal
SNA, degree	79	82	77	82
SNB, degree	75	80	74	80
ANB, degree	4	2	3	2
GoGN-N, degree	33	32	35	32
ANS-Me, mm	64	62	71	62
Co-Pt A, mm	85	88	84	90
Co-Gn, mm	104	110	110	114
Mx 1-SN, degree	94	104	97	104
IMPA, degree	99	90	92	90
Mx 1-Mn 1, degree	134	130	136	130
Nasolabial angle, degree	101	115	105	115

- Correcting the transposition and establishing the natural tooth order;
- Creating an ideal overbite and overjet and correcting the incisor inclinations, crossbites, midlines, and root inclinations and angulations; and
- Establishing a Class I skeletal relationship.

## Treatment Alternatives

The treatment alternatives were extracting the upper first premolar and finishing the case in a Class II molar relationship, alignment of the involved teeth in their transposed position, correcting the transposition orthodontically and establishing natural tooth order without extraction.

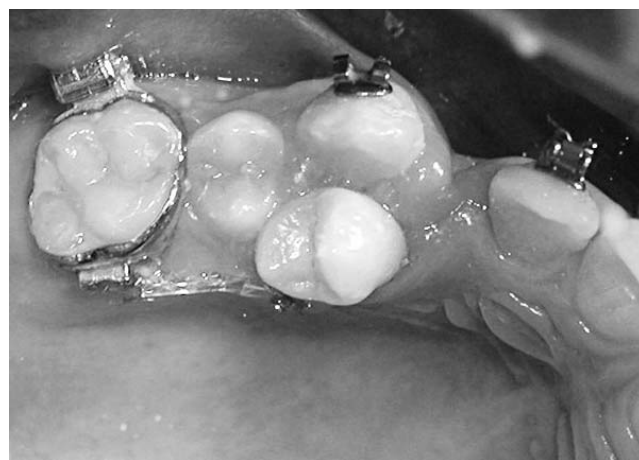It is not advised to attempt to correct transposed teeth in the permanent dentition because of the potential risk of damaging the teeth or supporting structures. Therefore, alignment of the involved teeth in their transposed position seems to be the best alternative. However, a recent trend in the management of MxC.P1 is orthodontic movement of the teeth into their normal anatomical position.<sup>13,14,18,19</sup> Because of the patient's willingness, and the space of the deciduous canine providing the space necessary for nonextraction orthodontic alignment procedures, orthodontic management of transposition was decided.

## Treatment Progress

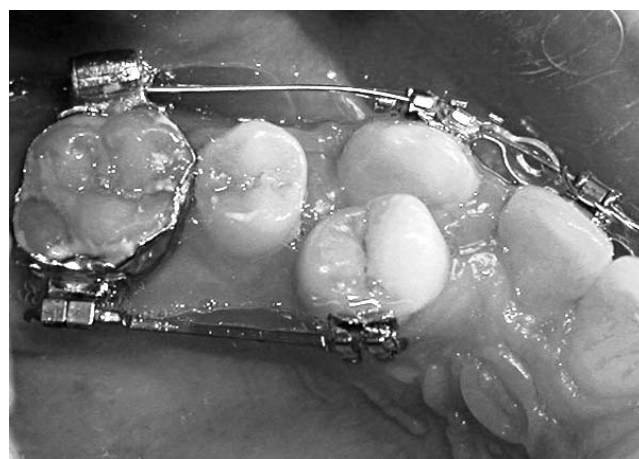Orthodontic treatment was initiated with a cervical headgear. When a Class I molar relationship was established, the maxillary left primary canine was extracted, and the maxillary teeth were fully banded and bonded (except for all second molars and the left premolars and canine) with a 0.018 × 0.025-inch straight wire appliance. The patient was asked to wear a removable acrylic splint, 24 hours a day, to free the occlusion to permit correction of the crossbites.

Tooth movement was started with light forces and rest intervals. The inner bow of the cervical headgear was used to control the root position of the left first molar and anchorage. A button was bonded to the mesial surface of the maxillary left first premolar. The tooth was rotated 90° through the palatal bone with elastic chains to allow the left canine to be moved mesially (Figure 6). Two solid stops were soldered to the left molar band palatally and a lingual and a 0.017 × 0.025-inch TMA power arm was connected to the maxillary left first premolar to obtain palatal root torque. This would prevent any damage to the roots, during mesial tipping of the canine with elastic chains (Figure 7). A 150-g superelastic nickel-titanium alloy open coil spring between the maxillary left second premolar and the canine was inserted. When the crown of the canine was mesially inclined, the first premolar root was forced to move distally with the power arm.

Eighteen months after initiation of treatment, the mandibular teeth were bonded with a 0.018-inch straight wire appliance after slight stripping in the anterior region. Although the crowns of the premolar and canine were corrected, the roots were still transposed. Root positions were controlled using information



**Figure 6.** Initial fixed appliance therapy. First premolar rotated 90° and canine tipped mesially.



**Figure 7.** Power arm placed between first molar and premolar.

gained from CT scans and periapical and panoramic radiographs (Figures 8 and 9). Once root uprighting of the left first premolar was complete and some space was created distal to the maxillary left canine, the rotation of the premolar was corrected with a power chain (Figure 10). After the maxillary arch was leveled with NiTi arches, an upper 0.017 × 0.025-inch TMA arch wire with a T loop was used to correct the root torque of the maxillary left canine. The final 10 months of treatment were spent aligning the roots of the left canine and first premolar. Fixed appliances were removed after 35 months of orthodontic treatment. After the removal of bands and brackets, Essix retainers were placed in both the mandible and maxilla to maintain the orthodontic correction.

## Treatment Results

Facial photographs show a pleasant smile. Her profile convexity was decreased, but the upper and lower



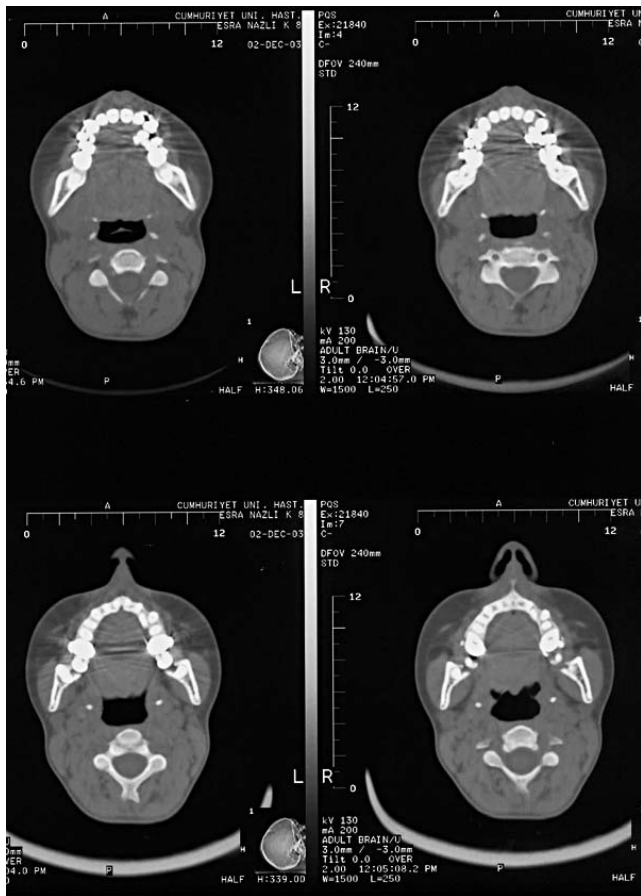


Figure 8. Computed tomography scan.

lips were slightly retruded with respect to the tip of the nose and chin (Figure 11). The transposition was corrected and natural tooth order was established. The dental midlines, crossbites, and crowding were corrected. A functional Class I molar and canine relationship was established, and an ideal overjet and overbite were achieved (Figure 12).

Cephalometric analysis (Figure 13, Table 1) showed slight changes in the skeletal values. The upper incisor angle to the SN plane increased and the lower incisor angle to the mandibular plane decreased. The superimposition showed the downward rotation of the maxilla and mandible due to the growth (Figure 14).

The posttreatment panoramic radiograph reflects good parallelism of roots with normal structures in the periodontium and surrounding tissues. The periapical radiograph shows the premolar tooth's apical root contour flattened (Figure 15). The CT scan shows the triangular bone resorption at the vestibular cortical bone of the maxillary left canine (Figure 16).

Although the treatment objectives were achieved at the end of the treatment, the cortical bone resorption at the maxillary left canine underwent major damage to the surrounding tissues. The patient was recalled

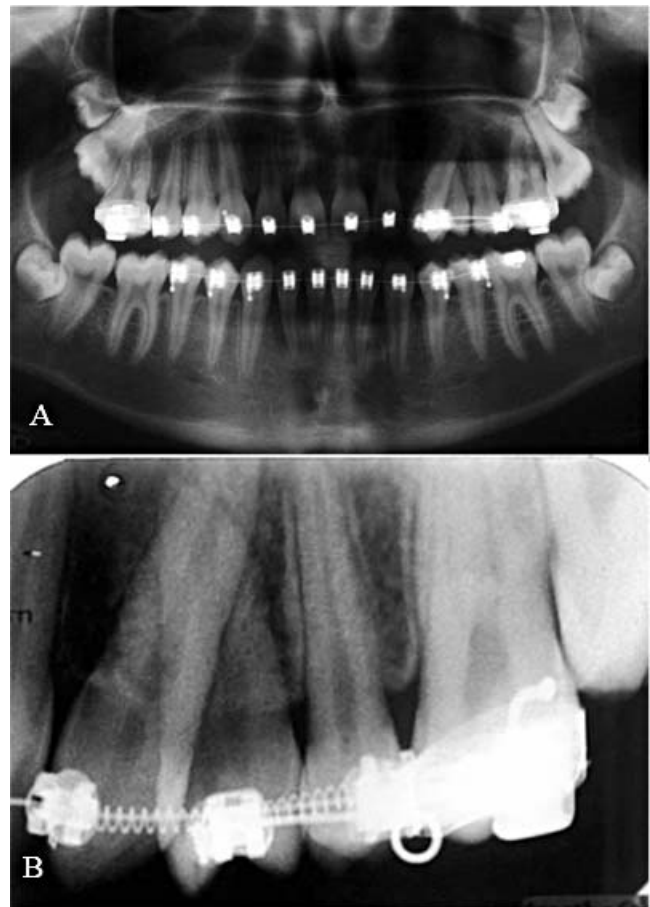


Figure 9A,B. Panoramic and periapical radiographs after 18 months of treatment. Note the roots of canine and first premolar still crossing.

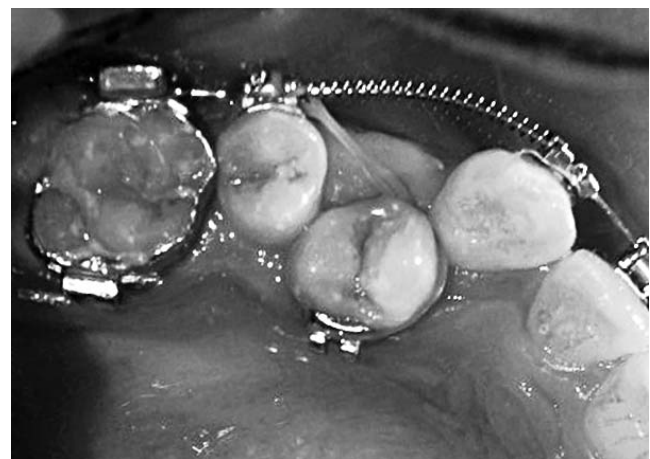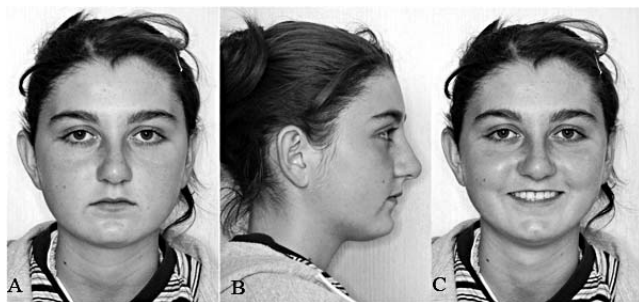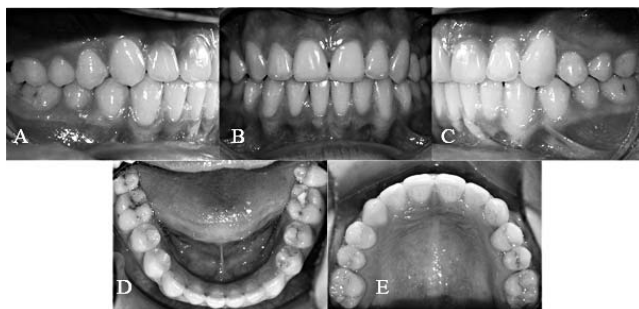


Figure 10. Correction of premolar rotation.

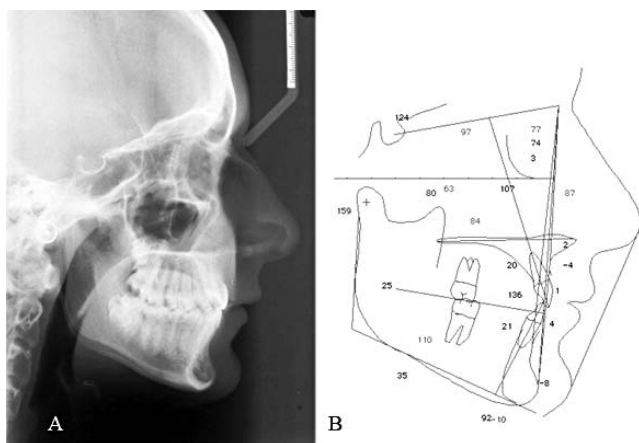
for postretention control 1 year later and a new CT scan was taken to view the prognosis of the bone resorption (Figure 17). Surprisingly the cortical bone was restructured and a regular cortical contour was observed.



**Figure 11A–C.** Posttreatment facial photographs.



**Figure 12A–E.** Posttreatment intraoral photographs. Note the gingival recession of 1 mm occurred on vestibule surface of maxillary left canine.

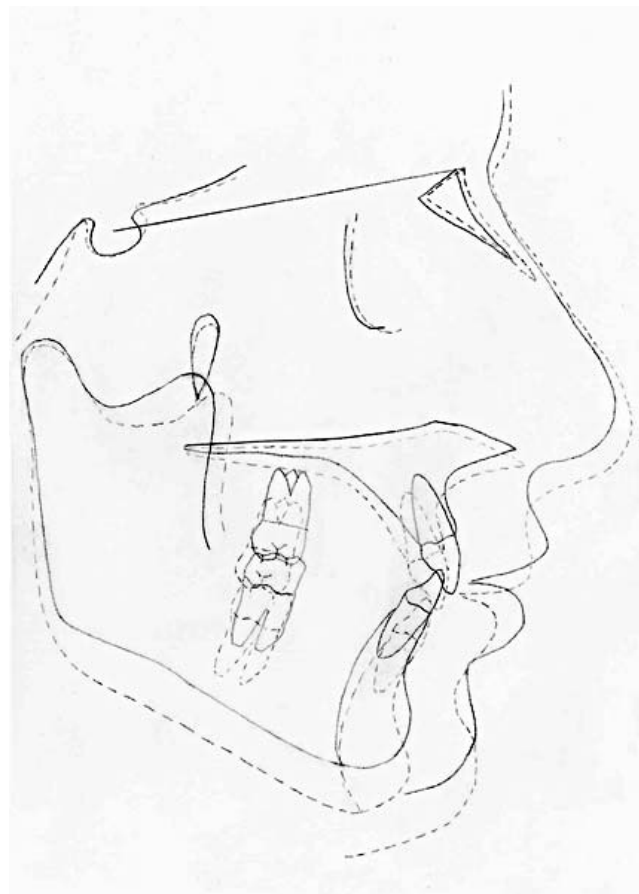


**Figure 13A,B.** Posttreatment cephalometric radiograph and tracing.

## DISCUSSION

The maxillary left canine first premolar transposition is clearly the most frequently reported maxillary transposition type that many orthodontists face.<sup>5,8,10,11</sup> Although transpositions are associated with increased frequency of other dental anomalies, supporting a genetic etiology,<sup>1</sup> there are no other dental anomalies here. The etiology of this transposition case is unclear.

There are three different treatment approaches for treating a MxC.P1 transposition. Extraction treatment could be an alternative for this case. This treatment approach is preferred when a severe arch length de-

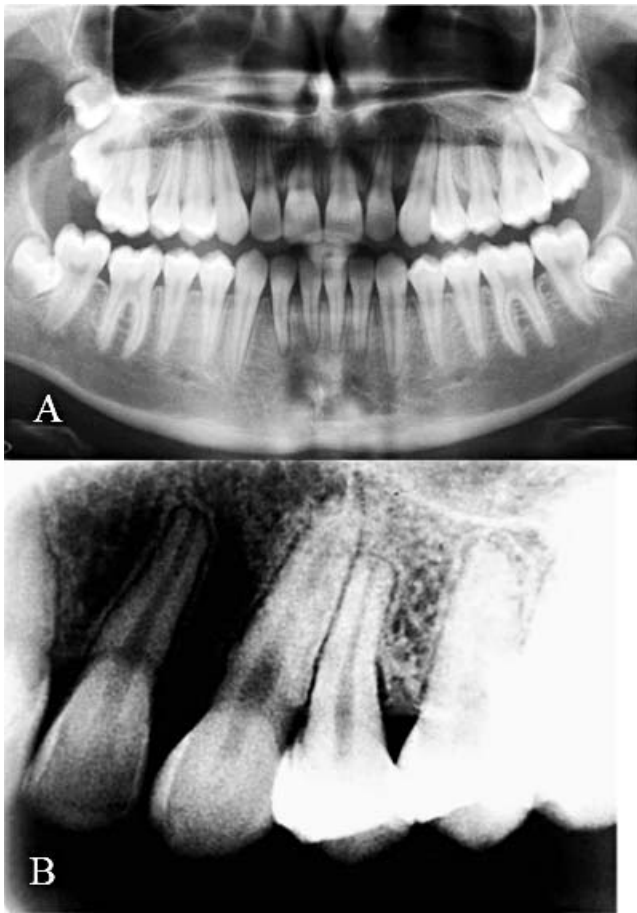


**Figure 14.** Initial (solid line) and final (dotted line) cephalometric tracings superimposed on SN at sella.

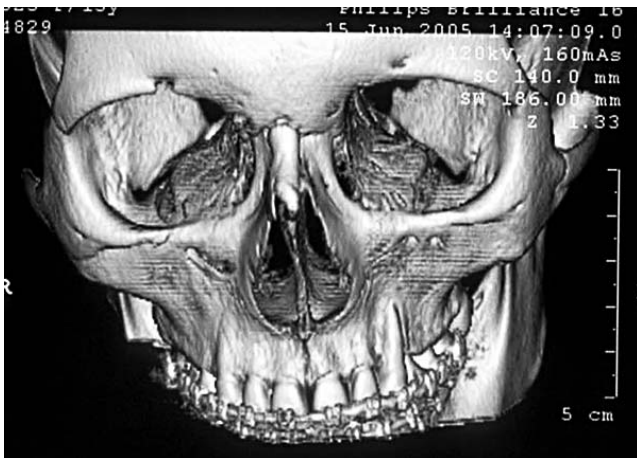ficiency exists, but removing the retained deciduous canine provided the space necessary for nonextraction orthodontic alignment procedures. In addition, a more prognathic profile would have been expected if the maxillary first premolar was extracted.

In this case, after overall consideration of the facial profile, the facial mid third convexity, the smile height, and the cephalometric and dental cast analyses, a nonextraction treatment was considered. Therefore, keeping the transposed order of the teeth or recreating the natural tooth order was presented as the two treatment alternatives to the patient. These options are a matter of great controversy mainly because the treatment becomes longer and more difficult if the option is recreating the natural tooth order. However, when the option to keep the transposed tooth order is elected, one relies on variables such as the different root prominence, the different height of the gingival scallops, and the shape and size of the premolar.<sup>12,13</sup> Other aspects that need to be considered are prolonged treatment time, esthetics or function, stability, biological sacrifice or damage, mechanical device needed, professional preference, and experience.<sup>14</sup> Addition-





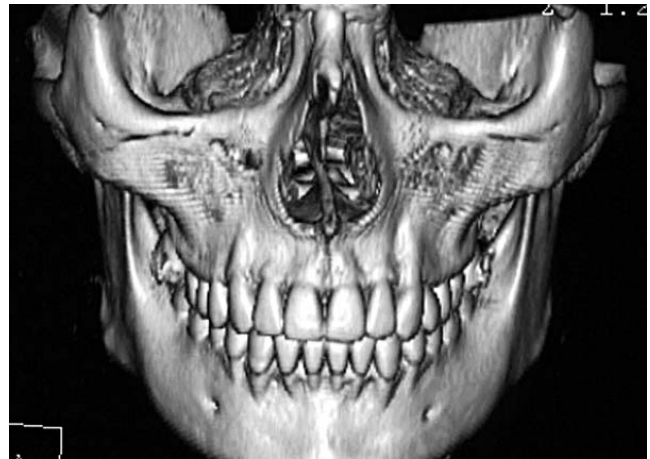**Figure 15A,B.** Posttreatment panoramic and periapical radiographs.



**Figure 16.** Computed tomography image just before debonding.

ally, patient cooperation is an important factor that affects the treatment results.

As a general rule, it is not advisable to correct a transposed tooth order because of insufficient buccopalatal width of bone support when two adjacent teeth are moving in different directions, especially after eruption.<sup>1,8,15-17</sup> Although keeping the transposed order



**Figure 17.** Postretention CT scan.

of the teeth is suggested in MxC.P1, recent case reports<sup>13,14,18,19</sup> have demonstrated nonextraction reposition of transposed teeth. We restored the natural tooth order using similar mechanics as described in these articles. We also used CT to consider the root positions in detail. Authors have suggested similar fixed mechanics in restoring the natural tooth order in maxillary transpositions.

The process of reposition of transposed teeth was described in this way: move one of the transposed teeth palatally to allow free movement of the other transposed tooth on the buccal alveolar bone as much as possible. Then, correct the palatally displaced teeth.<sup>13,14,18,19</sup> This approach was also suggested to correct maxillary canine lateral transpositions because of the esthetic problems caused by color, shape, and size of the canine.<sup>20-22</sup> Although the alveolar bone width is insufficient to move two teeth in different directions, outcomes of this approach encouraged others to use the same model for treatment of MxC.P1 transpositions.

Many recent reports<sup>13,14,19</sup> showed recession at the gingival margins of the repositioned canines because of the long journey of canine through the buccal dense compact bone. We used similar mechanics for the treatment of MxC.P1 transposition, and similar gingival recession occurred at the gingival margin of the canine (Figure 12). Regular radiographs showed only supporting interdental bone. CT scans, however, showed the surrounding bone in detail. Although the gingival recessions were presented as an esthetic problem, the regular supporting bone was noted in these recent reports.<sup>13,14,19</sup> The CT scan (Figure 16) showed the labial triangular bone resorption, which is a more severe problem than the esthetics. Although the gingival recession might be considered as a predictor of labial cortical bone loss, the CT scans showed that the area of bone loss is bigger than expected. Labial cortical

bone resorption was also detected at the right canine, which did not move a long distance through cortical bone. This was most probably because of the long treatment duration.

The other problem in restoring the natural tooth order was the prolonged treatment due to difficulties in root movement and because of the potential risk of forcing the premolar root against the canine root. We used fixed biomechanics to control the tooth movement, but it seems that safe movement does not exist and torque is probably one of the most detrimental factors. The total duration of the force is considered to be a crucial factor to influence root resorption.<sup>22,23</sup> Bocchieri and Braga<sup>18</sup> corrected a bilateral MxC.P1 transposition in the late mixed dentition without extraction, and they reported mild root resorption at the maxillary first premolars. Kuroda and Kuroda<sup>13</sup> presented non-extraction treatment of MxC.P1 transposition in an adult patient and pointed out the root resorption at the adjacent incisors and canine. Maia and Maia<sup>14</sup> also reported the nonextraction management of a bilateral MxC.P1 transposition with congenitally missing lateral incisors. They showed a small degree of root resorption on the canines and central incisors, and a small loss of alveolar crest height. Although we made a great effort to prevent root resorption, root contour irregularities occurred at the maxillary left premolar at the end of treatment (Figure 15A,B).

## CONCLUSIONS

When treating transpositions, especially MxC.P1, many factors that affect the treatment results must be considered, such as esthetics, occlusion, treatment period, patient comfort, patient cooperation, and periodontal support. Age is the noticeable factor beyond the factors listed above, which is directly correlated with the tissue regeneration. This patient's final records presented the proper finishing of the treatment in a Class I dental relationship with canine protected occlusion. Although a severe vertical bone defect was observed at the end of treatment, postretention CT scans showed the bone tissue regenerated 1 year after the treatment.

## REFERENCES

1. Peck L, Peck S, Attia Y. Maxillary canine—first premolar transposition, associated dental anomalies and genetic basis. *Angle Orthod.* 1993;63:99–109.
2. Ely NJ, Sherriff M, Cobourne MT. Dental transposition as a disorder of genetic origin. *Eur J Orthod.* 2006;28:145–151.
3. Chattopadhyay A, Srinivas K. Transposition of teeth and genetic etiology. *Angle Orthod.* 1996;66:147–152.
4. Turkkahraman H, Sayin MO, Yilmaz HH. Maxillary canine transposition to incisor site. *Angle Orthod.* 2005;75:284–287.
5. Joshi MR, Bhatt NA. Canine transposition. *Oral Surg Oral Med Oral Pathol.* 1971;31:49–54.
6. Shapira Y, Kuflinec MM. Tooth transposition—review of the literature and the treatment considerations. *Angle Orthod.* 1989;59:271–276.
7. Shapira Y, Kuflinec MM. Maxillary tooth transpositions: characteristics features and accompanying dental anomalies. *Am J Orthod Dentofacial Orthop.* 2001;119:127–134.
8. Peck S, Peck L. Classification of maxillary tooth transpositions. *Am J Orthod Dentofacial Orthop.* 1995;10:505–517.
9. Yilmaz HH, Turkkahraman H, Sayin MO. Prevalence of tooth transpositions and associated dental anomalies in a Turkish population. *Dentomaxillofac Radiol.* 2005;34:32–35.
10. Peck S, Peck L, Kataja M. Mandibular lateral incisor-canine transposition, concomitant dental anomalies, and genetic control. *Angle Orthod.* 1998;68:455–456.
11. Joshi MR, Gaitonde SS. Canine transposition of extensive degree: case report. *Br Dent J.* 1996;121:121–122.
12. Kokich VG, Nappen DL, Shapiro PA. Gingival contour and clinical crown length. *Am J Orthod Dentofacial Orthop.* 1984;86:89–94.
13. Kuroda S, Kuroda Y. Nonextraction treatment of upper canine-premolar transposition in an adult patient. *Angle Orthod.* 2005;75:472–477.
14. Maia FA, Maia NG. Unusual orthodontic correction of bilateral maxillary canine-first premolar transposition. *Angle Orthod.* 2005;75:262–272.
15. Sato K, Yokozeki M, Takagi T, Moriyama K. An orthodontic case of transposition of the upper right canine and first premolar. *Angle Orthod.* 2002;72:275–278.
16. Nestel E, Walsh JS. Substitution of a transposed premolar for a congenitally absent lateral incisor. *Am J Orthod Dentofacial Orthop.* 1988;93:395–399.
17. Demir A, Basciftci FA, Gelgor IE, Karaman AI. Maxillary canine transposition. *J Clin Orthod.* 2002;36:35–37.
18. Bocchieri A, Braga G. Correction of a bilateral maxillary canine-first premolar transposition in the late mixed dentition. *Am J Orthod Dentofacial Orthop.* 2002;121:120–128.
19. Filho LC, Cardoso MA, An TL, Bertoz FA. Maxillary canine-first premolar transposition. *Angle Orthod.* 2007;77:167–175.
20. Maia FA. Orthodontic correction of a transposed maxillary canine and lateral incisor. *Angle Orthod.* 2000;70:339–348.
21. Shapira Y, Kuflinec MM. A unique treatment approach for maxillary canine-lateral incisor transposition. *Am J Orthod Dentofacial Orthop.* 2001;119:540–545.
22. Levander E, Malmgren O. Evaluation of the risk of root resorption during orthodontic treatment: a study of upper incisors. *Eur J Orthod.* 1988;10:30–38.
23. Linge B, Linge L. Patient characteristics and treatment variables associated with apical root resorption during orthodontic treatment. *Am J Orthod Dentofacial Orthop.* 1991;99:35–43.