

## Distal Movement of Maxillary Molars Using Miniscrew Anchorage in the Buccal Interradicular Region

Kazuyo Yamada<sup>a</sup>; Shingo Kuroda<sup>b</sup>; Toru Deguchi<sup>b</sup>; Teruko Takano-Yamamoto<sup>c</sup>; Takashi Yamashiro<sup>d</sup>

### ABSTRACT

**Objective:** To quantify the treatment effects of interradicular miniscrew anchorage and to confirm the validity of the clinical usage of interradicular miniscrews in the distal movement of maxillary molars in nonextraction treatment.

**Materials and Methods:** Twenty-four maxillary molars were moved to the distal using miniscrews placed in the interradicular space between the second premolar and the first molar at an oblique angle of 20 to 30 degrees to the long axis of the proximal tooth. The teeth were evaluated as to how the molars were moved to the distal with the use of lateral cephalograms and dental casts.

**Results:** Maxillary molars were moved to the distal by 2.8 mm with distal tipping of 4.8 degrees and intruded by 0.6 mm. Maxillary incisors were moved to the distal by 2.7 mm with palatal tipping of 4.3 degrees. Molar extrusion and/or consequent mandibular rotation was not observed in any patient.

**Conclusion:** Miniscrews placed in the maxillary interradicular space provide successful molar distal movement of 2.8 mm without patient compliance and with no undesirable side effects such as incisor proclination, clockwise mandibular rotation, or root resorption. (*Angle Orthod.* 2009;79:78–84.)

**KEY WORDS:** Miniscrew; Anchorage; Maxilla; Molar distalization

### INTRODUCTION

The use of skeletal anchorage systems has become a new orthodontic treatment strategy over the past de-

cade.<sup>1–10</sup> Skeletal orthodontic anchorage systems provide stationary anchorage for various tooth movements without the need for active patient compliance and with no undesirable side effects.

Recently, titanium miniscrews have gradually gained acceptance for use in stationary anchorage because they provide clinical advantages such as minimal anatomic limitation on placement, lower medical cost, and simpler placement with less-traumatic surgery.<sup>4–10</sup> Half of patients who experienced screw insertion did not feel pain at any time after placement, and most patients reported minimal discomfort due to swelling, speech difficulty, and difficulty in chewing.<sup>7</sup> On the other hand, miniscrews provide the following disadvantages and risks: damage to anatomic structures such as dental roots, nerves, and blood vessels; the possibility of screw breakage on placement and removal; and screw failure with peri-implant inflammation. Success rates of miniscrews are reported as 80% to 95%.<sup>7,11,12</sup>

Placement of miniscrews in the buccal interradicular bone is one of the most common approaches used to provide skeletal anchorage.<sup>6–10</sup> The interradicular space is a potentially advantageous region for insertion because the miniscrew would cause fewer com-

<sup>a</sup> Graduate Student (PhD), Department of Orthodontics and Dentofacial Orthopedics, Okayama University Graduate School of Medicine, Dentistry and Pharmaceutical Sciences, Okayama, Japan.

<sup>b</sup> Assistant Professor, Department of Orthodontics and Dentofacial Orthopedics, Okayama University Graduate School of Medicine, Dentistry and Pharmaceutical Sciences, Okayama, Japan.

<sup>c</sup> Professor and Department Chair, Division of Orthodontics and Dentofacial Orthopedics, Tohoku University Graduate School of Dentistry, Sendai, Japan.

<sup>d</sup> Professor and Department Chair, Department of Orthodontics and Dentofacial Orthopedics, Okayama University Graduate School of Medicine, Dentistry and Pharmaceutical Sciences, Okayama, Japan.

Corresponding author: Dr Shingo Kuroda, Department of Orthodontics and Dentofacial Orthopedics, Okayama University Graduate School of Medicine, Dentistry and Pharmaceutical Sciences, Okayama, Japan 2-5-1 Shikata-Cho, Okayama, 700-8525 Japan  
(e-mail: shinkrd@md.okayama-u.ac.jp)

Accepted: March 2008. Submitted: February 2008.

© 2009 by The EH Angle Education and Research Foundation, Inc.

**Table 1.** Distal Tooth Movement of 24 Maxillary Molars<sup>a</sup>

Maxillary Molar	Anterior-Posterior Jaw Relationship at Pretreatment	Side	Upper Molar Cusp to PTV (U6/PTV)		Upper Molar Root to PTV (U6 Root/PTV)		Distal Tooth Movement, mm	
			Pre	Post	Pre	Post	Cusp	Root
1	Class II	R	31.5	28.5	30.0	28.6	3.0	1.4
2	Class II	L	28.9	26.2	27.4	25.8	2.7	1.6
3	Class III	R	29.4	28.0	29.1	28.7	1.4	0.4
4	Class III	L	25.1	24.4	24.4	24.1	0.7	0.3
5	Class II	R	35.6	35.3	32.6	31.8	0.3	0.8
6	Class II	L	31.8	31.0	29.3	27.9	0.8	1.4
7	Class III	R	33.9	32.3	31.6	31.0	1.6	0.6
8	Class III	L	28.6	25.9	25.5	24.6	2.7	0.9
9	Class I	R	33.1	26.8	28.8	28.5	6.3	0.3
10	Class I	L	30.6	24.1	26.4	24.3	6.5	2.1
11	Class I	R	28.5	24.6	26.8	25.7	3.9	1.1
12	Class I	L	28.5	24.6	26.8	25.7	3.9	1.1
13	Class II	R	31.0	27.6	31.6	29.1	3.4	2.5
14	Class II	L	28.8	26.0	28.8	27.7	2.8	1.1
15	Class III	R	36.2	31.2	34.2	30.4	5.0	3.8
16	Class III	L	33.4	30.4	30.0	28.7	3.0	1.3
17	Class II	R	24.7	21.1	22.6	21.0	3.6	1.6
18	Class II	L	21.0	20.2	18.5	19.5	0.8	-1.0
19	Class I	R	36.2	35.3	34.4	34.8	0.9	-0.4
20	Class I	L	31.1	29.7	31.7	28.8	1.4	2.9
21	Class II	R	33.0	29.4	32.7	30.8	3.6	1.9
22	Class II	L	31.1	28.0	31.6	29.5	3.1	2.1
23	Class I	R	25.5	23.8	31.7	31.5	1.7	0.2
24	Class I	L	23.9	20.3	28.9	28.0	3.6	0.9
Average			30.1	27.3	29.0	27.8	2.8	1.2
SD			3.7	3.8	3.4	3.0	1.6	0.7

<sup>a</sup> L indicates left; PTV, XXX; R, right; SD, standard deviation; U6, XXX.

plications related to soft tissue irritation, especially if placed through the attached gingiva. However, miniscrews inserted into the interradicular space should obstruct on tooth movement when adjacent teeth are moved in an anterior-posterior direction.

Maxillary molar distal movement is often required to treat patients with Class II malocclusion. Several techniques have been proposed to move maxillary molars to the distal, such as extraoral traction,<sup>13-15</sup> Schwarz plate-type appliances,<sup>16</sup> Wilson distalizing arches,<sup>17,18</sup> removable spring appliances,<sup>19-21</sup> distal jet appliances,<sup>22</sup> intermaxillary elastics with sliding jigs,<sup>23,24</sup> and pendulum appliances.<sup>25,26</sup> However, these conventional techniques often are accompanied by unwanted side effects of flaring or mesial movement of the anterior teeth.

In contrast, the miniscrews provide sufficient anchorage for incisor retraction in Class II treatment without unwanted orthodontic side effects. With Class II treatment in premolar extraction cases, we previously showed that miniscrew anchorage could provide more effective incisor retraction than the traditional anchorage method in which a headgear and a transpalatal arch were used.<sup>8</sup> Apart from premolar extraction cases, these devices could provide special benefit in non-extraction cases in terms of retracting all dentition

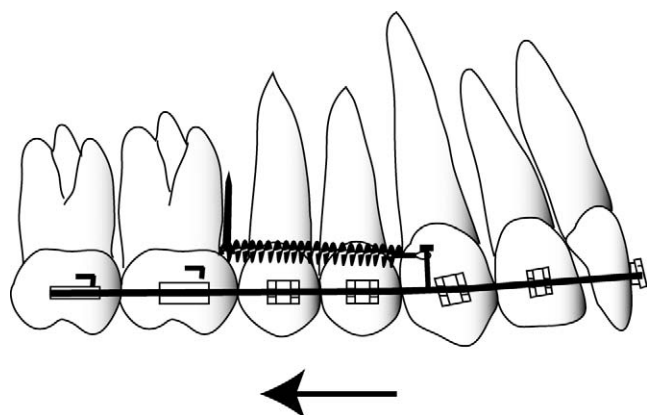
without producing adverse reciprocal movement.<sup>9,10</sup> However, few reports have analyzed in detail maxillary molar distal movement resulting from insertion of miniscrews into the interradicular area.

The aims of this study were to quantify the treatment effects of interradicular miniscrew anchorage and to confirm the validity of its clinical usage for distal movement of the maxillary molars in nonextraction cases.

## MATERIALS AND METHODS

Our study focused on 24 maxillary molars in 12 patients (1 male, 11 females; mean age, 28.2 years; standard deviation [SD], 11.3 years). Five of these had Class II malocclusion, four had Class I bimaxillary protrusion, and 3 had Class III malocclusion with severe mandibular excess (Table 1). All Class III cases were indicated for maxillary molar distal movement for improvement of the flared incisors during presurgical orthodontic treatment. Between October 2003 and July 2006, all subjects underwent surgery at a university hospital for placement of titanium screw anchorage for edgewise treatment.

Before placement, the advantages and disadvantages of treatment were explained to each patient and to his or her parents when an implant anchor was con-



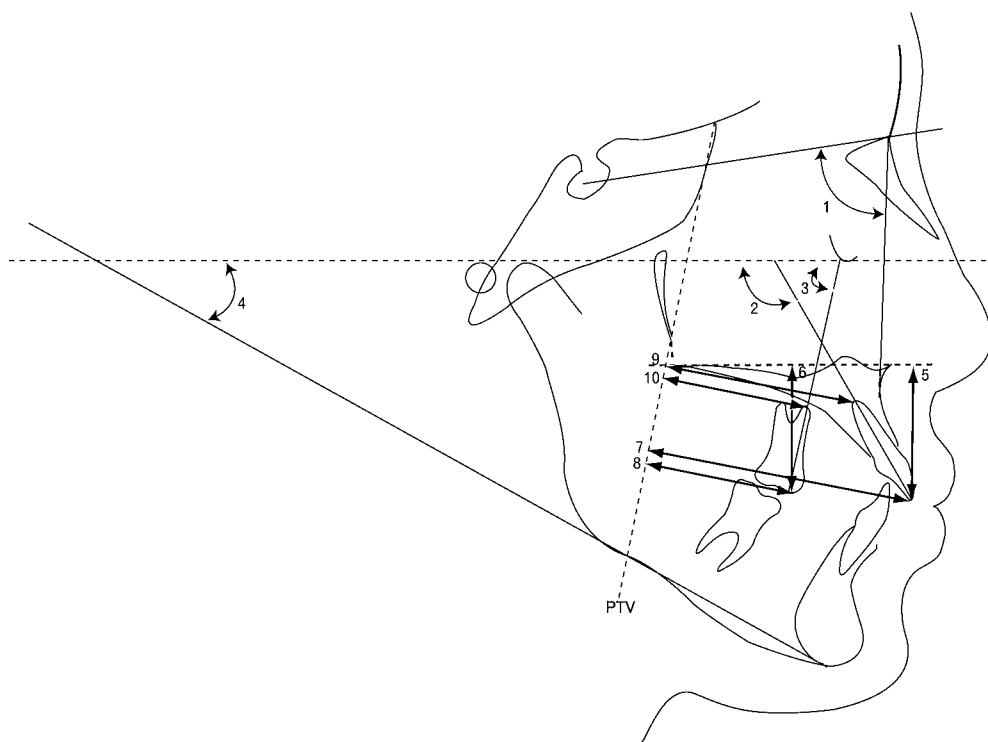
**Figure 1.** The schema about molar distal movement achieved with the miniscrew.

sidered desirable for orthodontic treatment. All subjects gave informed consent after having received a full explanation of the goals and structure of the present study. The Ethical Review Board of the university hospital approved this study.

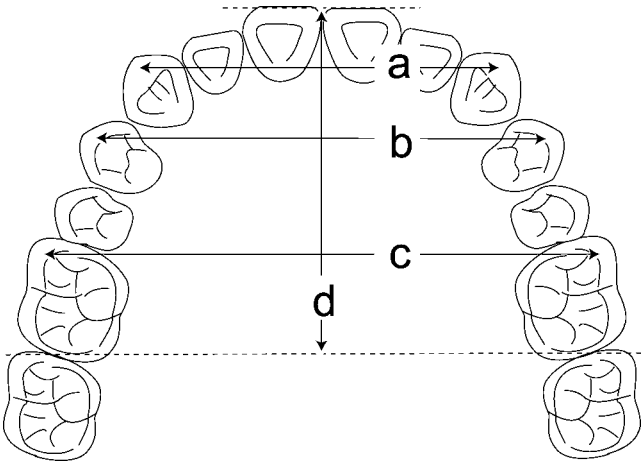
Two types of titanium screws (screw A [AbsoAnchor; Dentos Inc, Taegu, Korea]: diameter, 1.3 mm; length, 8 mm; screw head, 3 mm; and screw B [Gebrüder; Martin GmbH & Co, KG, Tuttlingen, Germany]: diameter, 1.5 mm; length, 9 mm) were used for absolute anchorage. With the subject under local

anesthesia, the screws were inserted by one of two orthodontists after leveling and aligning. No mucoperiosteal incision or flap was made; screw holes were made with a 1.0 mm round bar and a twist drill at 500 rpm with continuous normal saline solution irrigation. Screws then were placed through the attached gingiva via a self-tapping method with continuous irrigation. Each screw was inserted 5 or 6 mm into the alveolar bone at an angle of 20 to 30 degrees to the long axis of the proximal tooth, and the head of the screw was adjusted to at least 2 mm above the mucosa. After placement, a dental radiograph was taken to evaluate the distance between the screw and the root.

Loading of screws began 4 weeks after placement. A 0.018 inch slot, preadjusted edgewise appliance was used in all patients. The orthodontic load was applied by elastic chains or nickel-titanium (Ni-Ti) closing coil springs, estimated at 200 g. A 0.016 × 0.022 inch stainless steel wire was used during distal movement. Force was applied backward and upward as parallel to the occlusal plane as possible (Figure 1). Pretreatment and posttreatment lateral cephalograms were used for analysis. Five angular and nine linear measurements were taken to evaluate skeletal and dental changes before and after orthodontic treatment (Figure 2). Pretreatment and posttreatment panoramic and dental radiographs were used to evaluate root resorp-



**Figure 2.** Angular and linear measurements. 1, SNA; 2, U1 to FH plane; 3, U6 to FH plane; 4, FH to mandibular plane; 5, Upper incisal edge to palatal plane (U1/PP); 6, Upper molar cusp to palatal plane (U6/PP); 7, Upper incisal edge to PTV (U1/PTV); 8, Upper molar cusp to PTV (U6/PTV); 9, Upper incisal root to PTV, pterygoid vertical plane. (U1 root/PTV); 10, Upper molar root to PTV (U6 root/PTV).



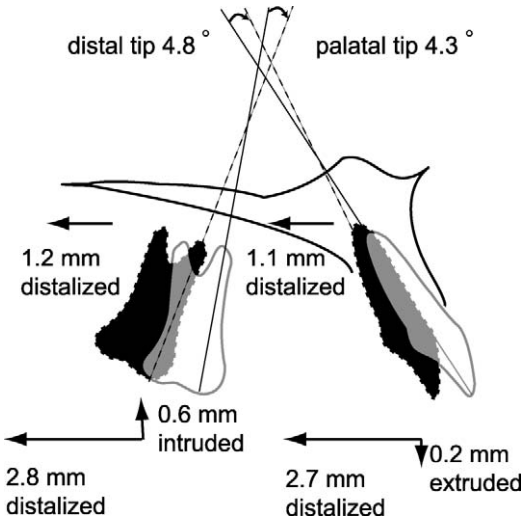
**Figure 3.** Cast analysis. (a) Intercanine width (ICW). (b) Interpremolar width (IPW). (c) Intermolar width (IMW). (d) Coronal arch length.

tion in the maxillary incisor and the first molar. Four linear measurements and an arch length discrepancy were evaluated on dental casts to compare changes before and after treatment (Figure 3).

The Wilcoxon signed rank test was used to compare cephalometric measurements and cast analysis changes before and after treatment. A probability of  $P < .05$  was considered significant. Analyses were carried out with statistical analysis software (StatView, SAS Institute Inc, Chicago, Ill).

RESULTS

Study results are shown in Table 2. Mean treatment duration for molar distalization was 8.4 months (SD, 4.2 months). The crown of the maxillary molars was moved to the distal 2.8 mm (SD, 1.6 mm) with distal tipping of 4.8 degrees (SD, 4.5 degrees), and it intruded 0.6 mm (SD, 1.0 mm) based on the palatal plane. The root apex of maxillary molars was moved to the



**Figure 4.** The schema about comparison of pretreatment and posttreatment changes on cephalometric analysis. Solid lines present a mean schematic illustration of pretreatment changes, and dotted lines indicate a mean schematic illustration of posttreatment changes.

distal 1.2 mm (SD, 0.7 mm). The crowns of maxillary incisors were moved to the distal 2.7 mm (SD, 2.1 mm) with palatal tipping of 4.3 degrees (SD, 7.7 degrees); it extruded 0.2 mm (SD, 1.4 mm) based on the palatal plane (Table 2, Figure 4). The root apex of the maxillary incisor was moved to the distal 1.1 mm (SD, 1.7 mm). The mandibular plane angle was unchanged. When pretreatment and posttreatment radiographs were evaluated, the maxillary incisor showed slight root resorption (0.2 mm; SD, 0.3 mm), but the buccal roots of the maxillary first molar showed no significant root resorption after treatment (Table 3).

During cast analysis, no significant differences were seen in terms of coronal arch width and coronal arch length of canines and first molars (Table 4). The first premolar coronal arch width was increased by approx-

**Table 2.** Comparison of Pretreatment and Posttreatment Changes in Cephalometric Analysis

Cephalometric Variables		Pretreatment		Posttreatment		T1-T2		P Value	
		T1		T2					
		Mean	SD <sup>a</sup>	Mean	SD	Mean	SD		
Angular, degree	SNA	80.5	3.7	80.3	3.7	0.1	0.4	.308	
	U1-FH	117.3	10.2	113.0	10.6	4.3	7.7	.084	
	U6-FH	84.3	4.5	79.5	5.6	4.8	4.5	.005	**
	Mp-FH	29.2	4.1	29.5	4.5	−0.3	0.8	.266	
Linear, mm	Upper incisal edge to palatal plane (U1/PP)	31.2	3.1	31.4	3.9	−0.2	1.4	.754	
	Upper molar cusp to palatal plane (U6/PP)	26.7	2.4	26.1	2.2	0.6	1.0	.050	*
	Upper incisal edge to PTV (U1/PTV)	61.7	5.4	59.0	4.9	2.7	2.1	.006	**
	Upper molar cusp to PTV (U6/PTV)	30.1	3.7	27.3	3.8	2.8	1.6	.002	**
	Upper incisal root to PTV (U1 root/PTV)	47.1	3.2	46.0	3.1	1.1	1.7	.033	*
	Upper molar root to PTV (U6 root/PTV)	29.0	3.4	27.8	3.0	1.2	0.7	.002	**

<sup>a</sup> SD indicates standard deviation.  
\*  $P < .05$ ; \*\*  $P < .01$ , Wilcoxon signed rank test.

**Table 3.** Comparison of Pretreatment and Posttreatment Changes in Root Length<sup>a</sup>

Variable		Pretreatment		Posttreatment		T1-T2		P Value	
		T1		T1					
		Mean	SD	Mean	SD	Mean	SD		
Linear (mm)	U1	25.0	1.7	24.8	1.6	0.2	0.3	.028	*
	U6RM	18.3	1.9	18.3	1.9	0.0	0.0	.068	
	U6RD	19.1	1.3	19.1	1.3	0.0	0.0	.068	
	U6LM	18.2	1.9	18.1	1.9	0.0	0.0	.068	
	U6LD	19.5	1.1	19.5	1.1	0.0	0.0	.180	

<sup>a</sup> D indicates buccal distal root; L, left; M, buccal medial root; R, right; SD, standard deviation; U1, XXX; U6, XXX.

\*  $P < .05$ , Wilcoxon signed rank test.

**Table 4.** Comparison of Pretreatment and Posttreatment Changes in Cast Analysis

Variable	Pretreatment		Posttreatment		T1-T2		P Value
	T1		T1				
	Mean	SD	Mean	SD	Mean	SD	
Inter canine width	35.9	2.6	36.3	1.9	−0.4	1.7	.388
Inter premolar width	43.7	3.0	45.2	1.4	−1.5	2.0	.041
Inter molar width	54.0	3.4	54.9	2.2	−0.9	2.6	.477
Coronal arch length	30.1	3.6	30.0	3.6	0.1	1.0	.500
Arch length discrepancy	−1.3	2.7	0.0	0.0	−1.3	2.7	.128

\*  $P < .05$ , Wilcoxon signed rank test.

imately 1.5 mm. An arch length discrepancy of -1.3 mm was improved after treatment.

## DISCUSSION

In the present study, we quantified the treatment effects of interradicular miniscrew anchorage and confirmed the validity of its clinical usage for the distal movement of maxillary molars in nonextraction cases. Park et al<sup>9</sup> previously reported that the maxillary first molars were moved to the distal by 1.64 mm with statistical significance in their study of group distal movement using miniscrew anchorage. However, only four subjects were studied, and in one of them, the miniscrew was placed in the palate. In addition, investigators did not address the root resorption, which is one of the side effects of molar distal movement that causes great concern. Therefore, a study in which a larger sample was used was necessary to investigate in detail the distal tooth movement of maxillary molars achieved with miniscrew anchorage placed in the buccal region.

In the present study, the maxillary first molar was moved to the distal by approximately 3 mm in cephalometric evaluations, and the acquired space was used to eliminate crowding and to retract incisors. Because canine and first molar coronal arch widths and lengths were stable during orthodontic treatment, the available arch length could be increased by molar dis-

tal movement without lateral expansion of the maxillary arch or maxillary incisor proclination.

In addition, distal movement of the molar often results in its extrusion and subsequent clockwise mandibular rotation in orthodontic mechanics.<sup>24-26</sup> However, in the present study, the mandibular plane angle was stable during treatment. Detailed observation revealed that the molar intruded by 0.6 mm, together with its distal movement. This suggests that clockwise rotation of the mandible could be prevented by intrusive force provided to the maxillary molars through the miniscrew. Subjects in the present study had various anterior-posterior skeletal relationships, but all had been given nonextraction treatment. The mandibular molars were not moved mesially and did not intrude; therefore, the authors believe that mandibular tooth movement did not influence mandibular position in the vertical dimension of this study. Park et al<sup>9</sup> also reported that the mandibular plane angle was stable during their group distal movement of maxillary dentition with the use of miniscrews. Hence, in nonextraction cases, miniscrew anchorage placed in the interradicular area might be more efficient for molar distal movement than traditional orthodontic methods.

Interradicular miniscrews have been shown to provide stationary anchorage for various types of orthodontic tooth movement.<sup>6-10</sup> However, miniscrews inserted into the interradicular space should not interfere



with tooth movement when adjacent teeth are moved in an anterior-posterior direction. It is likely that extensive molar distal movement is difficult to achieve with interradicular miniscrews because the screws would come in contact with the surrounding root during tooth movement. We previously reported that proximity of miniscrews to the root is a major risk factor for the failure of screw anchorage.<sup>27</sup>

To avoid close screw proximity to the surrounding root, we chose as the insertion site the buccal interradicular space between the maxillary second premolar and the first molar because several reports have indicated that the interradicular space is widest in the maxillary buccal region.<sup>27,28</sup> In the present study, miniscrews with a 1.3 or 1.5 mm diameter were placed at 20 to 30 degrees to the long axis of the proximal tooth. In previous reports, distances between the mesiodistal central grooves of proximal teeth were calculated with a panoramic radiograph or three-dimensional computed tomography and were defined as interradicular distances.<sup>28–30</sup> Therefore, the interradicular distance might be longer than 3 mm in the buccal root area around screws that are placed at an oblique angle. Because of the implantation methods used, the maxillary molars in this study could be moved to the distal by approximately 3 mm without screw contact with the proximal root. In addition, Deguchi et al<sup>29</sup> reported that miniscrews placed at 30 degrees to the tooth axis had a 1.5 times greater contact area with the surrounding cortical bone than did those placed perpendicular to the tooth axis. This suggests that inserting miniscrews at an oblique angle might contribute to their stability.

Root resorption was observed statistically in the maxillary incisors; however, this was minor and was not a matter for clinical consideration. Miniscrew anchorage not only prevents flaring of maxillary incisors, an undesirable side effect of molar distal movement, but could cause significant distal movement of the incisors. No significant root resorption was achieved in the maxillary molars through significant molar distal movement. This suggests that the mechanism and the force system used in the present study were biologically adequate.

The anterior palate is a favored site for screw placement because it has an adequate bone mass; this conveys a low risk of damage to anatomic structures such as dental roots, nerves, and blood vessels. During the past two decades, a pendulum appliance combined with palatal implant anchorage has been introduced to move the maxillary first molar distally.<sup>31–33</sup> In these cases, a reaction force caused by molar distal movement is canceled out by implant anchorage, and the molars are moved to the distal by more than 5 mm without undesirable side effects on the anterior teeth and premolars. Disadvantages of palatal implant anchorage

include the requirement for a complicated design and device, such as a pendulum appliance, to load the distal movement force onto the teeth, and with the need for complicated procedures to place and remove the implant.<sup>34</sup>

The miniplate may also contribute any amount of group maxillary molar distal movement. Sugawara et al<sup>35</sup> reported that the maxillary first molars were moved to the distal by approximately 4 mm at the crown level with miniplate anchorage. However, the disadvantage of this technique is the requirement of a mucoperiosteal incision or flap surgery when the plates are placed and removed. Therefore, surgical invasiveness is not minor, and the medical cost is high.<sup>9</sup> For patients, desirable orthodontic treatment should provide a sufficient treatment effect with the use of a simple and straightforward device. Therefore, we recommend the use of miniscrew anchorage devices placed in the interradicular area for maxillary molar distal movement. However, long-term stability after treatment for molar distal movement achieved with skeletal anchorage devices in nonextraction cases is unknown. This is a topic for future study in implant orthodontics.

## CONCLUSIONS

- Miniscrews placed in the maxillary buccal interradicular space between the second premolar and the first molar at an oblique angle were useful for moving maxillary molars distally in nongrowing patients.
- Molar distal movement was achieved without active patient compliance or with no undesirable side effects such as incisor proclination, clockwise mandibular rotation, or root resorption.

## REFERENCES

1. Roberts WE, Helm FR, Marshall KJ, Gongloff RK. Rigid endosseous implants for orthodontic and orthopedic anchorage. *Angle Orthod.* 1989;59:247–256.
2. Umemori M, Sugawara J, Mitani H, Nagasaka H, Kawamura H. Skeletal anchorage system for open-bite correction. *Am J Orthod Dentofacial Orthop.* 1999;115:166–174.
3. Creekmore TD, Eklund MK. The possibility of skeletal anchorage. *J Clin Orthod.* 1983;17:266–269.
4. Kuroda S, Katayama A, Takano-Yamamoto T. Severe anterior open-bite case treated using titanium screw anchorage. *Angle Orthod.* 2004;74:558–567.
5. Kuroda S, Sugawara Y, Yamashita K, Mano T, Takano-Yamamoto T. Skeletal Class III oligodontia patient treated with titanium screw anchorage and orthognathic surgery. *Am J Orthod Dentofac Orthop.* 2005;127:730–738.
6. Kyung HM, Park HS, Bae SM, Sung JH, Kim IB. Development of orthodontic micro-implants for intraoral anchorage. *J Clin Orthod.* 2003;37:321–328.
7. Kuroda S, Sugawara Y, Deguchi T, Kyung HM, Takano-Yamamoto T. Clinical use of miniscrew implants as orthodontic anchorage: success rates and postoperative discomfort. *Am J Orthod Dentofacial Orthop.* 2007;131:9–15.
8. Kuroda S, Yamada K, Deguchi T, Kyung HM, Takano-Ya-

- mamoto T. Class II camouflage treatment with mini-screw anchorage in adult patients: a comparison with traditional orthodontic mechanics outcomes. *Am J Orthod Dentofac Orthop*. In press.
9. Park HS, Lee SK, Kwon OW. Group distal movement of teeth using micro screw implant anchorage. *Angle Orthod*. 2005;75:602–609.
  10. Park HS, Kwon TG, Sung JH. Nonextraction treatment with micro screw implants. *Angle Orthod*. 2004;74:539–549.
  11. Cheng SJ, Tseng IY, Lee JJ, Kok SH. A prospective study of the risk factors associated with failure of mini-implants used for orthodontic anchorage. *Int J Oral Maxillofac Implants*. 2004;19:100–106.
  12. Park HS, Jeong SH, Kwon OW. Factors affecting the clinical success of screw implants used as orthodontic anchorage. *Am J Orthod Dentofacial Orthop*. 2006;130:18–25.
  13. Poulton DR. The influence of extraoral traction. *Am J Orthod*. 1967;53:8–18.
  14. Armstrong MM. Controlling the magnitude, direction, and duration of extraoral force. *Am J Orthod*. 1971;59:217–243.
  15. Mills CM, Holman RG, Graber TM. Heavy intermittent cervical traction in class II treatment: a longitudinal cephalometric assessment. *Am J Orthod*. 1978;74:361–379.
  16. Schwarz AM. *Gebissregelung Mit Platten*. 5th ed. Wien, Innsbruck: Urban & Schwarzenberg; 1947.
  17. Muse DS, Fillman MJ, Emmerson WJ, Mitchell RD. Molar and incisor changes with Wilson rapid molar distal movement. *Am J Orthod Dentofacial Orthop*. 1993;104:556–565.
  18. McSherry PF, Bradley H. Class II correction-reducing patient compliance: a review of the available techniques. *J Orthod*. 2000;27:219–225.
  19. Locatelli R, Bednar J, Dietz VS, Gianelly AA. Molar distal movement with superelastic NiTi wire. *J Clin Orthod*. 1992;26:277–279.
  20. Erverdi N, Koyutürk O, Küçükkeles N. Nickel-titanium coil springs and repelling magnets: a comparison of two different intra-oral molar distal movement techniques. *Br J Orthod*. 1997;24:47–53.
  21. Gianelly AA, Bednar J, Dietz VS. Japanese NiTi coils used to move molars distally. *Am J Orthod Dentofacial Orthop*. 1991;99:564–566.
  22. Carano A, Testa M. The distal jet for upper molar distal movement. *J Clin Orthod*. 1996;30:374–380.
  23. Jones RD, White JM. Rapid Class II molar correction with an open-coil jig. *J Clin Orthod*. 1992;26:661–664.
  24. Haydar S, Uner O. Comparison of Jones jig molar distal movement appliance with extraoral traction. *Am J Orthod Dentofacial Orthop*. 2000;117:49–53.
  25. Fuziy A, Rodrigues de Almeida R, Janson G, Angelieri F, Pinzan A. Sagittal, vertical, and transverse changes consequent to maxillary molar distal movement with the pendulum appliance. *Am J Orthod Dentofacial Orthop*. 2006;130:502–510.
  26. Bussick TJ, McNamara JA Jr. Dentoalveolar and skeletal changes associated with the pendulum appliance. *Am J Orthod Dentofacial Orthop*. 2000;117:333–343.
  27. Kuroda S, Yamada K, Deguchi T, Hashimoto T, Kyung HM, Takano-Yamamoto T. Root proximity is a major factor for screw failure in orthodontic anchorage. *Am J Orthod Dentofacial Orthop*. 2007;131(4 suppl):S68–S73.
  28. Poggio PM, Incorvati C, Velo S, Carano A. “Safe zones”: a guide for miniscrew positioning in the maxillary and mandibular arch. *Angle Orthod*. 2006;76:191–197.
  29. Deguchi T, Nasu M, Murakami K, Yabuuchi T, Kamioka H, Takano-Yamamoto T. Quantitative evaluation of cortical bone thickness with computed tomographic scanning for orthodontic implants. *Am J Orthod Dentofacial Orthop*. 2006;129:721.e7–e12.
  30. Schnelle MA, Beck FM, Jaynes RM, Huja SS. A radiographic evaluation of the availability of bone for placement of mini-screws. *Angle Orthod*. 2004;74:832–837.
  31. Gelgor IE, Buyukyilmaz T, Karaman AI, Dolanmaz D, Kalayci A. Intraosseous screw-supported upper molar distal movement. *Angle Orthod*. 2004;74:838–850.
  32. Kircelli BH, Pektaş ZO, Kircelli C. Maxillary molar distal movement with a bone-anchored pendulum appliance. *Angle Orthod*. 2006;76:650–659.
  33. Onçağ G, Seçkin O, Dinçer B, Arian F. Osseointegrated implants with pendulum springs for maxillary molar distal movement: a cephalometric study. *Am J Orthod Dentofacial Orthop*. 2007;131:16–26.
  34. Arcuri C, Muzzi F, Santini F, Barlattani A, Giancotti A. Five years of experience using palatal mini-implants for orthodontic anchorage. *J Oral Maxillofac Surg*. 2007;65:2492–2497.
  35. Sugawara J, Kanzaki R, Takahashi I, Nagasaka H, Nanda R. Distal movement of maxillary molars in nongrowing patients with the skeletal anchorage system. *Am J Orthod Dentofacial Orthop*. 2006;129:723–733.