

Case Report

Location and Presence of Permanent Teeth in a Complete Bilateral Cleft Lip and Palate Population

Richard Michael Halpern^a; James Noble^b

ABSTRACT

Objective: To describe the location and presence of permanent teeth in nonsyndromic complete bilateral cleft lip and palate patients from the Manitoba Centre for Craniofacial Difference.

Materials and Methods: Records of 1570 patients dating back to 1958 were assessed in this retrospective chart review.

Results: Thirty-eight patients met the inclusion criteria, providing 76 cleft site teeth: A tooth on each side of the cleft was considered to have developed from a single lateral incisor tooth bud. The pattern M was assigned when a tooth was found mesial to the cleft, D when distal, MD when mesial and distal and AB if none was found. Pattern M was noted 9.2% of the time; D, 47.4%; MD, 5.3%; and AB, 38.2%. Teeth outside the cleft site: In the maxilla, agenesis occurred in 11.9% of second premolars and 10.5% of central incisors. In the mandible, agenesis occurred in 4.0% of second premolars, 2.6% of lateral incisors, 2.6% of central incisors, and 2.6% of second molars.

Conclusions: The lateral incisor was most commonly found distal to the cleft. Agenesis of the lateral incisor and teeth outside the cleft were more common than in noncleft populations. (*Angle Orthod.* 2010;80:591–596.)

KEY WORDS: Bilateral cleft lip and palate; Tooth agenesis

INTRODUCTION

While research has characterized dental anomalies in nonsyndromic complete unilateral cleft lip and palate (CUCLP) patients,^{1–4} no investigations have specifically assessed location and presence of permanent teeth in a nonsyndromic complete bilateral cleft lip and palate (CBCLP) population. Comparing and interpreting previous studies is difficult because of the inclusion

of mixed cleft samples,⁵ the lack of well-defined criteria for tooth determination especially around the cleft area,⁶ not specifying exclusion criteria such as related syndromes associated with dental agenesis,^{7,8} and not specifying the completeness of the cleft.^{9,10} Further, reports on complete CLP patients do not mention excluding patients with Simonart's bands.

The purpose of this study was to describe the variation in location and presence of permanent teeth in nonsyndromic CBCLP patients from the Manitoba Centre for Craniofacial Difference (MCCD).

MATERIALS AND METHODS

Ethics approval was obtained for this study from the University of Manitoba Health Research Ethics Board. A retrospective chart review including cleft coordinator; pediatric, oral surgery, and plastic surgery notes; medical reports; and hospital microfilm archives of the 1570 patients seen by the MCCD dating back to 1958 was undertaken to identify patients categorized as having a CBCLP. Charts were assessed for the following inclusion criteria:

- At least one clear panoramic radiograph
- Clinical photograph before lip surgery
- Patient of the Winnipeg Children's Hospital Dental Clinic

^a Clinical Instructor, Department of Preventive Dental Science, Division of Pediatric Dentistry, University of Manitoba, Winnipeg, Canada; Candidate for Master of Science in Anatomy, Department of Anatomical Sciences and Neurobiology, University of Louisville School of Medicine, Louisville, Kentucky; Private practice dentist, Manitoba, Canada.

^b Clinical Instructor, Department of Preventive Dental Science, Division of Orthodontics, University of Manitoba, Winnipeg, Canada; Staff Orthodontist, Bloorview Kids Rehab, Toronto, Ontario, Canada; Orthodontist, Manitoba Centre for Craniofacial Difference, Children's Hospital, Winnipeg, Manitoba; Private practice orthodontist, Don Mills, Toronto, Ontario, Canada.

Corresponding author: Dr Richard Michael Halpern, Department of Surgical/Hospital Dentistry, University of Louisville School of Dentistry, 501 South Preston Street, Louisville, KY 40292

(e-mail: Richard_Halpern@Hotmail.com)

Accepted: July 2009. Submitted: May 2009.

© 2010 by The EH Angle Education and Research Foundation, Inc.

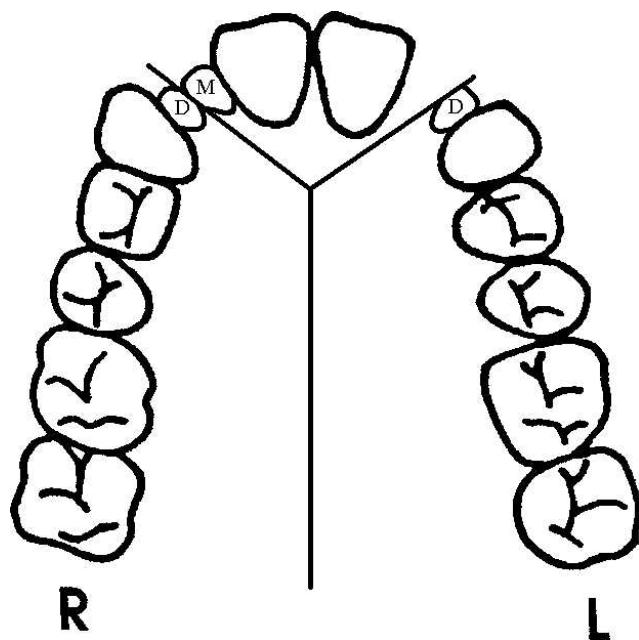


Figure 1. Patient's right cleft site demonstrating pattern MD and patient's left cleft site demonstrating pattern D of lateral incisor location.

The exclusion criteria were

- Simonart's bands
- Underlying anodontia-, hypodontia-, or cleft-associated syndromes¹¹

For the patients identified, the following information was entered into an MS Excel spreadsheet: gender, date of birth, and underlying health condition or syndrome. Two hundred eight patients were documented to have some involvement of bilateral clefting spanning from forme fruste to complete bilateral cleft without Simonart's bands.¹² Patients with underlying anodontia-, hypodontia- or cleft-associated syndromes associated with CLP, noted by dental charts and genetic reports, were excluded to prevent observations in this study from being skewed.¹¹ It was not possible to identify racial backgrounds of this population because patients included were of mixed racial backgrounds and not asked to disclose this on their information sheets.

Available clinical photographs from the Pediatric Dental Clinic of the Winnipeg Children's Hospital taken on initial presentation of the infant were used to clarify discrepancies between departmental reports on whether clefting was complete. Patients with Simonart's bands were considered to have incomplete clefting and were excluded.¹³ If completeness was questionable, the patient was excluded.

Radiographs of these patients from the pediatric and orthodontic dental charts were then assessed, if available. The first panoramic or anterior radiographs taken at this center are usually taken around a child's

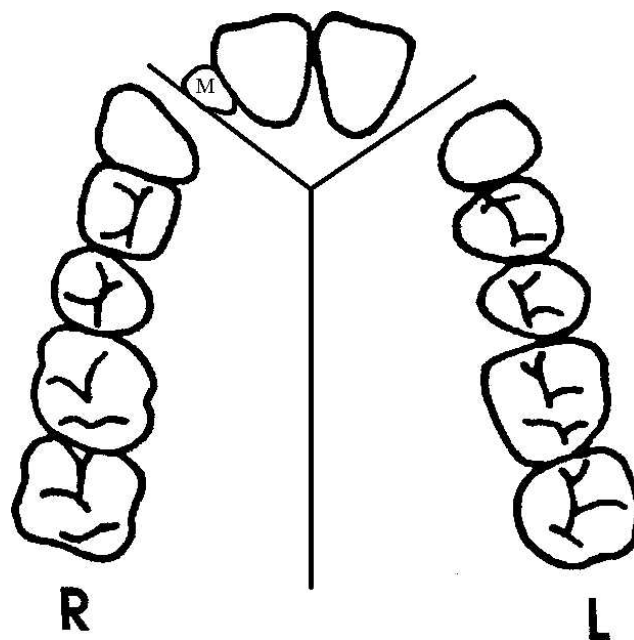


Figure 2. Patient's right cleft site demonstrating pattern M and patient's left cleft site demonstrating pattern AB of lateral incisor location.

sixth birthday or earlier depending on patient cooperation. Information recorded included types and dates of radiographs, presence and location of lateral incisors and all supernumerary teeth, whether mesial or distal to the cleft sites, and agenesis of other permanent teeth. While supplemental periapical, occlusal, or anterior oblique radiographs were available for many patients, as per previous study methods,¹⁴ patients without at least one panoramic radiograph were excluded.

The presence of maxillary anterior teeth and the location of these teeth, either distal or mesial to the cleft sites, were accepted without regard for tooth morphology.⁴ Teeth present were classified as mesial or distal to the cleft site. Permanent teeth on each side of the cleft site were considered to have developed from a single lateral incisor tooth bud. The pattern M was assigned when a tooth was found only mesial to the cleft, D when only distal, MD when mesial and distal, and AB if none was found¹ (Figures 1 and 2).

Tooth agenesis outside the cleft site was determined when no radiopacity¹⁵ was noted at the expected location at the same time as the ipsilateral or contralateral teeth had reached or passed Nolla stage 2.¹⁶ If the ipsilateral and contralateral teeth were absent, the adjacent tooth in the series was assessed for calcification. Third molars were not assessed as a result of patient age. Patients with insufficient or indistinguishable radiographs and incomplete records were excluded.

All information was recorded by the first author, and all radiographs were subsequently reviewed by the second

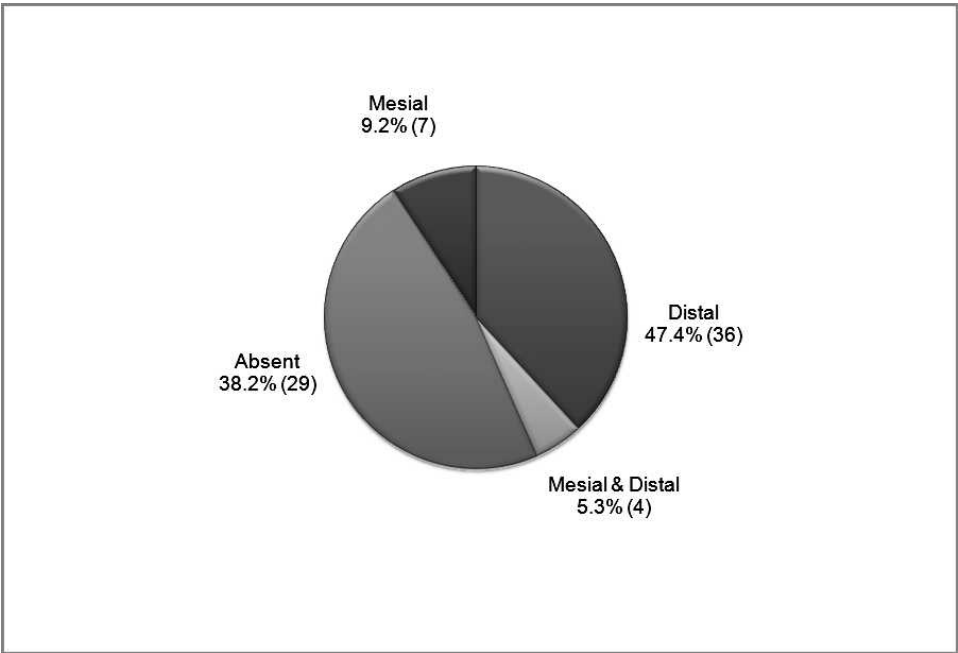


Figure 3. Location of lateral incisor development relative to all cleft sites.

author. Method reliability for identification of missing and supernumerary teeth and location of teeth relative to cleft site was conducted by the investigators through random selection of a subsample of eight patients, 6 months after the initial identification in which all radiographic observations were found to be identical.^{3,4}

RESULTS

A total of 38 patients born between 1980 and 2002 met the inclusion criteria, providing 76 cleft sites; 29 were male (76.3%) and 9, female (23.7%). The average age was 16 years 9 months, with a range of 5 years 10 months to 27 years 11 months. The youngest patient with agenesis of a tooth outside the cleft site was 12 years 9 months old.

The agenesis of permanent teeth is summarized by location in Table 1. When considering all cleft and noncleft sites, 26 patients (68.4%) were missing at least one tooth. Nine patients (23.7%) were missing only one tooth, 10 (26.3%) were missing two teeth, three (7.9%) were missing three teeth, and four (10.5%) were missing four teeth. Twenty-eight patients (73.7%) were found to have at least one missing or supernumerary permanent tooth. Two of these 28 were missing teeth and had supernumerary teeth, 24 had teeth missing but no supernumeraries, and two had supernumerary teeth but none missing.

Permanent Teeth in Cleft Site

Figure 3 summarizes the locations where lateral incisors were found at all cleft sites. At the 76 cleft sites,

pattern M was noted 9.2% of the time; D, 47.4%; MD, 5.3%; and AB, 38.2%. At the 38 rightside cleft sites, pattern M was noted 5.3% of the time; D, 52.6%; MD, 5.3%; and AB, 36.8%. At the 38 leftside cleft sites,

Table 1. Agenesis of Permanent Dentition

Tooth No. (FDI)	Frequency of Agenesis, % (n)
17	0 (0)
16	0 (0)
15	13.2 (5)
14	0 (0)
13	0 (0)
12	36.8 (14)
11	13.2 (5)
21	7.9 (3)
22	39.5 (15)
23	0 (0)
24	0 (0)
25	10.5 (4)
26	0 (0)
27	0 (0)
37	2.6 (1)
36	0 (0)
35	5.3 (2)
34	0 (0)
33	0 (0)
32	2.6 (1)
31	2.6 (1)
41	2.6 (1)
42	2.6 (1)
43	0 (0)
44	0 (0)
45	2.6 (1)
46	0 (0)
47	2.6 (1)

pattern M was noted 13.2% of the time; D, 42.1%; MD, 13.2%; and AB, 39.5%. Only four patients had supernumerary teeth; all were found distal to the cleft site.

Permanent Teeth in Noncleft Site

Considering only teeth outside the cleft, 13 patients (34.2%) were missing at least one tooth. Table 1 summarizes specific tooth agenesis. Pairs of dental agenesis outside the cleft region were noted in five patients (13.2%): one missing two maxillary second premolars, one missing two mandibular and one maxillary second premolar, one missing both maxillary second premolars and both mandibular lateral incisors, one missing both mandibular central incisors and one missing both mandibular second molars. No supernumerary teeth were detected outside the cleft site.

DISCUSSION

There have been previous studies assessing dental anomalies in patients with CLP; however, it is difficult to draw direct comparisons. Thirty-one percent of patients classified as CLP have Simonart's bands,^{17,18} so dental findings are difficult to compare. While some researchers have grouped, or not differentiated between, cleft types and have not excluded patients with syndromes or Simonart's bands,^{8,19} others have excluded or separated patients having Simonart's bands from those with complete CLP.^{13,17,20,21} They have also failed to specify cleft severity and precisely how radiographic assessments were determined.^{7,8} This has made it impossible to determine the particular patterns of agenesis, supernumerary teeth, and relative locations of teeth at the cleft site in patients with nonsyndromic CBCLP but without Simonart's bands.²²

Other researchers have found it difficult to obtain an adequate sample size of patients with a specific cleft type.¹⁷ Of the 1570 patients registered with the MCCD, only 38 met our selection criteria, providing 76 cleft sites. Dental radiographs were commonly destroyed 8 years after patients' last appointment with the Children's Hospital Dental Clinic; this visit was often around their 18th birthday. No models were available to assess the size and shape of the dentition. Surgical reports indicating the extraction of developing permanent lateral incisors during alveolar bone grafts and all requests for orthodontic extractions were reviewed when available. To decrease error in data collection, two independent examiners were utilized.¹ Due to the wide variety of methodology, classification, grouping, and inclusion criteria, there are limitations in making direct comparisons of our findings with respect to hypodontia and location of cleft site teeth with those in the literature.²

We considered the maxillary lateral incisor to be a tooth mesial or distal to the cleft site with any

morphology between the permanent central incisor and canine. Agenesis of the maxillary lateral incisor was noted if no permanent tooth was found between the central incisor and canine. We found that 61.8% of lateral incisors were present. This is more than that reported by Tsai et al¹ and Ribeiro et al⁴ in nonsyndromic patients with CUCLP (50.2%–51.8%), considerably more than that reported by Cassolato et al² (27%) and substantially lower than the 97.8%–99.0% reported in noncleft populations.^{23,24} This is consistent with research indicating that as cleft severity increases, the prevalence of anomalies such as hypodontia increases.^{4,10}

The finding that cleft-side permanent lateral incisors were more frequently located distal to the cleft are in agreement with previous studies.^{1,4} This study found lateral incisors distal in 83.0% of cleft sites. This is more than the 76.5% found distal in a nonsyndromic CUCLP population.⁴ In the permanent dentition, the most common pattern was D (46%), followed by AB (38.2%), M (9.2%), and MD (5.3%). Studies by Ferenczy²⁵ and Wei et al²⁶ found that the lateral incisor dental lamina is not found exclusively in the premaxillary segment. This is consistent with the results we have seen. Several authors explain that the dental lamina of the lateral incisor is thought to split, resulting in what some authors describe as supernumerary teeth.^{6,7}

Cleft site supernumerary teeth were found in 10.5%. This is more than the 0.73% of patients having a cleft site supernumerary tooth in a nonsyndromic CUCLP population¹ and 1–3% of noncleft patients who have supernumerary teeth.^{23,27} This is not consistent with studies indicating that as cleft severity increases, the prevalence of supernumerary teeth decreases.⁴

The higher frequencies seen in this study are not consistent with previous studies.^{4,6} Two of the four patients with supernumerary teeth had only one extra tooth. This value is lower than the 86% reported in noncleft populations.²⁷ The remaining two patients with supernumerary teeth had two extra teeth. Investigators of noncleft populations have reported that 12–23% of patients with supernumerary teeth have two extra teeth.²⁷ A comparison of our results of agenesis with that of noncleft patients and cleft-sided CUCLP patients are summarized in Tables 2 and 3, respectively.

The most commonly missing teeth in this population were the maxillary lateral incisors (38.2%), the maxillary second premolars (11.9%), the maxillary central incisors (10.5%), and the mandibular second premolars (4.0%). This is similar to the order found in the nonsyndromic CUCLP study by Ribeiro et al,⁴ with maxillary lateral incisors missing in 49.8% of patients, followed by the maxillary second premolars (5.91%), then the mandibular second premolars (2.71%). These patterns differ from those of a noncleft population: mandibular second premolars (2.09%), followed by

Table 2 Comparison of Agenesis in Complete Bilateral Cleft Lip and Palate with Noncleft Population in Two Studies

Teeth ^a	Current Study, %	Polder et al, ²⁸ %
Mx 2nd molars	0.00	0.03
Md 2nd molars	2.63	0.06
Mx 1st molars	0.00	0.04
Md 1st molars	0.00	0.01
Mx 2nd premolars	11.84	1.08
Md 2nd premolars	3.95	2.09
Mx 1st premolars	0.00	0.14
Md 1st premolars	0.00	0.07
Mx canines	0.00	0.07
Md canines	0.00	0.02
Mx lateral incisors	38.16	1.17
Md lateral incisors	2.63	0.13
Mx central incisors	10.53	0.01
Md central incisors	2.63	0.18

^a Mx indicates maxillary; Md, mandibular.

maxillary lateral incisors (1.17%), and maxillary second premolars (1.08%).²⁸

A total of 68.4% of patients were missing at least one tooth, and 23.7% had at least one missing tooth outside the cleft site. This result is supported by a nonsyndromic CUCLP study by Ribeiro et al,⁴ who found hypodontia outside the cleft area in 20.7% of patients in the cleft-sided arch. These rates are considerably higher than the 3.5–10.1% of noncleft patients found with hypodontia.^{27,29} Noncleft site supernumerary teeth were not found in this population, which is consistent with nonsyndromic CUCLP research.¹

CONCLUSIONS

- The lateral incisor was most commonly found distal to the cleft site and supernumerary teeth present may derive from the lateral tooth bud.
- Agenesis of lateral incisors was less common than in CUCLP and more common than in noncleft populations.
- Agenesis of teeth outside the cleft site was more common in this population than in CUCLP and noncleft populations.
- The most commonly missing teeth were the maxillary lateral incisors, the maxillary second premolars, the maxillary central incisors, and then the mandibular second premolars.

Table 3. Comparison of Agenesis of Premolars in Patients with Complete Bilateral and Cleft-Sided Unilateral Clefts in Three Studies

Teeth ^a	Current Study, %	Cassolato et al ²	Ribeiro et al ⁴
Mx 2nd premolars	11.84	12.07	11.82
Md 2nd premolars	3.95	5.17	5.42
Mx 1st premolars	0.00	0.00	2.96
Md 1st premolars	0.00	0.00	0.49

^a Mx indicates maxillary; Md, mandibular.

- More supernumerary teeth were found in this population than in CUCLP and noncleft populations.

ACKNOWLEDGMENTS

The authors wish to thank Dr Bernie Chodirker, Dr Robert Schroth, Dr Bruce Ross, Dr Howard Cross, and Ms Cynthia Bonneteau.

REFERENCES

1. Tsai TP, Huang CS, Huang CC, See LC. Distribution patterns of primary and permanent dentition in children with unilateral complete cleft lip and palate. *Cleft Palate Craniofac J.* 1998;35:154–160.
2. Cassolato SF, Ross B, Daskalogiannakis J, Noble J, Tompson B. Treatment of dental anomalies in children with complete unilateral cleft lip and palate at SickKids hospital, Toronto. *Cleft Palate Craniofac J.* 2009;46:166–172.
3. Ribeiro LL, das Neves LT, Costa B, Gomide MR. Dental development of permanent lateral incisor in complete unilateral cleft lip and palate. *Cleft Palate Craniofac J.* 2002;39:193–196.
4. Ribeiro LL, das Neves LT, Costa B, Gomide MR. Dental anomalies of the permanent lateral incisors and prevalence of hypodontia outside the cleft area in complete unilateral cleft lip and palate. *Cleft Palate Craniofac J.* 2003;40:172–175.
5. Jordan RE, Kraus BS, Neptune CM. Dental abnormalities associated with cleft lip and/or palate. *Cleft Palate J.* 1966;3: 22–55.
6. Nagai I, Fujiki Y, Fuchihata H, Yoshimoto T. Supernumerary tooth associated with cleft lip and palate. *J Am Dent Assoc.* 1965;70:642–647.
7. Ranta R. A review of tooth formation in children with cleft lip/palate. *Am J Orthod Dentofacial Orthop.* 1986;90:11–18.
8. Suzuki A, Watanabe M, Nakano M, Takahama Y. Maxillary lateral incisors of subjects with cleft lip and/or palate: part 2. *Cleft Palate Craniofac J.* 1992;29:380–384.
9. Tortora C, Meazzini MC, Garattini G, Brusati R. Prevalence of abnormalities in dental structure, position, and eruption pattern in a population of unilateral and bilateral cleft lip and palate patients. *Cleft Palate Craniofac J.* 2008;45:154–162.
10. Aizenbud D, Camasuvi S, Peled M, Brin I. Congenitally missing teeth in the Israeli cleft population. *Cleft Palate Craniofac J.* 2005;42:314–317.
11. Jones KL. *Smith's Recognizable Patterns of Human Malformation.* 6th ed. Philadelphia, Pa: Saunders; 2006.
12. Thaller SR, Lee TJ. Microform cleft lip associated with a complete cleft palate. *Cleft Palate Craniofac J.* 1995;32:247–250.
13. Smahel Z, Brejcha M. Differences in craniofacial morphology between complete and incomplete unilateral cleft lip and palate in adults. *Cleft Palate J.* 1983;20:113–127.
14. Shashua D, Omnell ML. Radiographic determination of the position of the maxillary lateral incisor in the cleft alveolus and parameters for assessing its habilitation prospects. *Cleft Palate Craniofac J.* 2000;37:21–25.
15. Ringqvist M, Thilander B. The frequency of hypodontia in an orthodontic material. *Sven Tandlak Tidskr.* 1969;62:535–541.
16. Nolla CM. The development of the permanent teeth. *J Dent Child.* 1960;27:254–266.
17. Semb G, Shaw WC. Simonart's band and facial growth in unilateral clefts of the lip and palate. *Cleft Palate Craniofac J.* 1991;28:40–46.
18. Da Silva Filho OG, Santamaria M Jr, da Silva Dalben G, Semb G. Prevalence of a Simonart's band in patients with

- complete cleft lip and alveolus and complete cleft lip and palate. *Cleft Palate Craniofac J*. 2006;43:442–445.
19. Ranta R. Hypodontia and delayed development of the second premolars in cleft palate children. *Eur J Orthod*. 1983;5:145–148.
 20. Daskalogiannakis J, Ross RB. Effect of alveolar bone grafting in the mixed dentition on maxillary growth in complete unilateral cleft lip and palate patients. *Cleft Palate Craniofac J*. 1997;34:455–458.
 21. Letra A, Menezes R, Granjeiro JM, Vieira AR. Defining subphenotypes for oral clefts based on dental development. *J Dent Res*. 2007;86:986–991.
 22. Baek SH, Kim NY. Congenital missing permanent teeth in Korean unilateral cleft lip and alveolus and unilateral cleft lip and palate patients. *Angle Orthod*. 2007;77:88–93.
 23. Haavikko K. Hypodontia of permanent teeth—an orthopantomographic study. *Suom Hammaslaak Toim (Proceedings of the Finnish Dental Society)*. 1971;67:219–225.
 24. Symons AL, Stritzel F, Stamation J. Anomalies associated with hypodontia of the permanent lateral incisor and second premolar. *J Clin Pediatr Dent*. 1993;17:109–111.
 25. Ferenczy K. The relationship of globulomaxillary cysts to the fusion of embryonal processes and to cleft palates. *Oral Surg Oral Med Oral Pathol*. 1958;11:1388–1393.
 26. Wei X, Senders C, Owiti GO, Liu X, Wei ZN, Dillard-Telm L, McClure HM, Hendrickx AG. The origin and development of the upper lateral incisor and premaxilla in normal and cleft lip/palate monkeys induced with cyclophosphamide. *Cleft Palate Craniofac J*. 2000;37:571–583.
 27. Neville BW, Damm DD, Allen CM, Bouquot JE. *Oral and Maxillofacial Pathology*. Philadelphia, Pa: Saunders; 2002.
 28. Polder BJ, Van't Hof MA, Van der Linden FP, Kuijpers-Jagtman AM. A meta-analysis of the prevalence of dental agenesis of permanent teeth. *Community Dent Oral Epidemiol*. 2004;32:217–226.
 29. Hunstadbraten K. Hypodontia in the permanent dentition. *ASDC J Dent Child*. 1973;40:115–117.